



Hallucinatory choking from slow wave sleep Choking during sleep: can it be expression of arousal disorder?

Mathilde Flamand, Bastien Herlin, Smaranda Leu-Semenescu, Valérie Attali, Claire Launois, Isabelle Arnulf

► To cite this version:

Mathilde Flamand, Bastien Herlin, Smaranda Leu-Semenescu, Valérie Attali, Claire Launois, et al.. Hallucinatory choking from slow wave sleep Choking during sleep: can it be expression of arousal disorder?. *Sleep Medicine*, 2015, 16 (11), pp.1441-1447. 10.1016/j.sleep.2015.03.023 . hal-01159315

HAL Id: hal-01159315

<https://hal.sorbonne-universite.fr/hal-01159315>

Submitted on 3 Jun 2015

HAL is a multi-disciplinary open access archive for the deposit and dissemination of scientific research documents, whether they are published or not. The documents may come from teaching and research institutions in France or abroad, or from public or private research centers.

L'archive ouverte pluridisciplinaire **HAL**, est destinée au dépôt et à la diffusion de documents scientifiques de niveau recherche, publiés ou non, émanant des établissements d'enseignement et de recherche français ou étrangers, des laboratoires publics ou privés.

Choking during sleep: can it be expression of arousal disorder?

Mathilde Flamand, MD,^a Bastien Herlin,^a Smaranda Leu-Semenescu, MD,^{a,b} Valérie Attali, MD,^{a,c,d}

Claire Launois, MD,^{a,c,d} Isabelle Arnulf, MD, PhD^{a,b,e}

^a*Sleep Disorders Unit, Chest and Sleep Department, Hôpital Pitié-Salpêtrière, APHP, France*

^b*Centre de Recherche de l'Institut du Cerveau et de la Moelle épinière - Université Pierre et Marie Curie-Paris 6 – Inserm U 1127-CNRS UMR 722, Paris, France*

^c*Sorbonne Universités, UPMC Univ Paris 06, UMR_S 1158, Neurophysiologie Respiratoire Expérimentale et Clinique, F-75005, Paris, France*

^d*INSERM, UMR_S 1158, Neurophysiologie Respiratoire Expérimentale et Clinique, F-75005, Paris, France*

^e*Sorbonne Universités, UPMC Univ Paris 06, F-75013, Paris, France*

Article submitted to: Sleep Medicine, version 1

Running title: Hallucinatory choking from slow-wave sleep

Address for correspondence: Isabelle Arnulf, service des pathologies du sommeil, Hôpital Pitié

Salpêtrière, 47-83 boulevard de l'Hôpital, 75651 Paris Cedex 13, France. Phone: +33 1 42 16 77 01

Fax: +33 1 42 16 77 00; Mail: isabelle.arnulf@psl.aphp.fr

Conflict of interest and financial disclosure: This is not an industry-sponsored study. The authors have no conflict of interest related to the study. Pr. Arnulf has been consultant and paid speaker for UCB-Pharma. Dr Leu-Semenescu has been paid speaker for UCB-Pharma. The other authors have no other conflict of interest to disclose.

Word counts: Manuscript: 4103 words; Tables: 2; Figures: 2; Video clips: 4. Supplemental Figure: 1

Abstract

Background: Choking during sleep may be caused by various respiratory and non-respiratory problems.

Objective: We aimed at documenting a new, rare cause of hallucinatory choking.

Methods. We documented the clinical and video-polysomnographic features of 11 adult patients referred for swallowing and choking during sleep. We conducted a systematic search for similar sensations in 68 consecutive adult patients with sleepwalking/sleep terrors and in 37 patients with obstructive sleep apnea.

Results. The 11 patients with sleep-related swallowing and choking were all current or former sleepwalkers. The symptoms occurred during the first third of the night. Patients consistently reported the frequent hallucinatory feeling of swallowing an unusual object (ring, nails, pebble, chewing gum, spoon, fork, electrical cables, lizard tail, needles, brush, computer, gas container) that blocked the upper airways during sleep, followed by attempts to unblock them by spitting or swallowing water. When monitored, the choking sensations were not stereotypic, and occurred exclusively during arousals from N3 sleep, despite normal airway patency and absence of epileptic activity. The patients demonstrated simultaneous intense adrenergic stimulation and emotional distress. Of the 68 sleepwalkers, 13% had occasional choking sensations and 4% once inhaled a fictitious object. In the sleep apnea group, choking was never the motive of referral, but 38% of patients had occasional choking sensations, and 5% once inhaled something fictitious.

Conclusion. While insular seizure could also be discussed, these results suggest that sleep-related swallowing and choking syndrome may be in some cases a rare, specialized variant of the arousal disorders.

INTRODUCTION

Choking or aspiration of a foreign object is a life-threatening event, requiring immediate opening of the airways (remove the object, intubate or perform tracheotomy) to prevent anoxia and death. In sleep medicine, the complaint of paroxysmal sleep-associated choking, suffocating or feeling of imminent death during the night raises a broad spectrum of diagnoses, including respiratory (laryngospasm, stridor, nighttime asthma, acute respiratory failure, sleep apnea), cardiac (arrhythmia, acute heart insufficiency), gastric (esophageal reflux), neurological (frontal or insular lobe epilepsy), and psychiatric (panic attack) causes. In addition to these diagnoses, sleep-related swallowing and sleep-related choking were mentioned in the section "Sleep disorders associated with conditions classifiable elsewhere" of the *International Classification of Sleep Disorders 2005-revised*.¹ The sleep-related swallowing and choking syndrome is described as an occult cause of insomnia with inadequate swallowing during sleep resulting in aspiration of saliva, coughing, and choking.² The condition is intermittently associated with brief arousals or awakenings. Patients report the subjective sense in sleep of choking and blocked breathing, but polysomnographic recordings demonstrate no pathological sleep apnea, rather only short-lived episodes of coughing and gagging following periods of "gurgling" sounds (the latter likely due to pooling of saliva in the hypopharynx).² Swallowing is a normal reflex that persists during all sleep stages at a lower frequency (2-9/h) than during daytime.³ The reflex is delayed during sleep in elderly patients with lacunar infarction (promoting the risk of aspiration pneumonia)⁴ and is blunted during daytime in patients with obstructive sleep apnea syndrome.⁵ The sleep-related choking syndrome was described as a disorder of unknown etiology characterized by frequent episodes of awakening with a choking sensation and an inability to breathe, associated with intense anxiety, rapid heart rate or a sensation of impending death, and contrasting with the absence of stridor or abnormalities of breathing witnessed by the bed partner and absence of sleep-disordered breathing in polysomnography.¹ In these unclassified disorders, the literature is scarce and has been mostly focused on laryngospasm (a different, well-defined disorder)⁶ or on saliva aspiration problems.² Notably, the

sleep-related swallowing and choking syndrome was removed from the more recent *International Classification of Sleep Disorder, third edition*.⁷ Rather, the term “choking” during sleep is mentioned as a symptom of obstructive sleep apnea syndrome, of apparent life-threatening events in infants, and of sleep related gastroesophageal reflux and laryngospasm. Of interest, among differential diagnoses of sleep related laryngospasm, it is noted that: “sleep terrors may be associated with sensations of impaired breathing or choking, rapid heartbeat, and agitation. However, sleep terrors are most common in children, and most patients do not focus on upper airway choking”. For the first time in the *International Classification of Sleep Disorder*, it appears that some patients with sleep terrors may feel the episode as a respiratory distress.

In order to contribute to the idea that some arousal disorders may present as swallowing and choking, we analyzed a consecutive series of patients referred for abnormal swallowing and choking during the night and described their symptoms and video-polysomnography characteristics. Since these patients had evidences of arousal disorders rather than other causes, we further looked for similar symptoms in patients with arousal disorders and with sleep apnea syndrome.

METHODS

Subjects

Prompted by a patient with a nocturnal swallowing and choking syndrome, we retrospectively looked for similar cases in the sleep unit clinical database (an adult sleep unit in a university hospital with 2500 new cases/y, half of them with sleep-disordered breathing, and half with neurological sleep disorders; patients with insomnia were referred elsewhere) during the last 7 years. A total of 11 cases were identified, which represented 0.12% of the patients seen in the sleep unit. In addition, we prospectively conducted systematic interviews about possible choking and swallowing symptoms in 68 consecutive untreated patients referred for sleepwalking or sleep terrors, and in 37 consecutive untreated patients referred for sleep apnea. The patients agreed to take part in the study. As this is an observational study,

the ethical committee waived written consent. The patients also provided agreements for displaying the video clips.

Interview

The patients underwent a medical interview regarding sleep, focused on parasomnia, including family history of parasomnia, age at onset, frequency, behaviors associated with the parasomniac episodes, triggering or relieving factors, as well as risk for potentially dangerous behaviors (presence of sexsomnia or behaviors such as opening windows, manipulating blunt objects or flammable objects, getting out of the home, hurting themselves or relatives). The patients' bed sharers were also interviewed when present. The interviews were conducted by neurologists and sleep medicine specialists (IA, SL) and concluded with an interview with a psychiatrist and sleep medicine specialist (MF). Patients also completed the Epworth sleepiness score.⁸

Patients provided a free, then systematic description of any symptoms related to their pharyngeal sensations when emerging from sleep, including the time of occurrence in the night, the frequency of such sensations, if they felt that they first swallowed or inhaled something, the nature of the swallowed/inhaled object, if they felt any dyspnea and choking, the duration of the sensations, the associated emotion and mental images, and the nature of the maneuvers they used to stop the sensation. The adults with sleepwalking and sleep terrors and those with sleep apnea were asked the following question: "Have you ever felt as if you were choking during your sleep, or that you could not breathe, or that you swallowed or inhaled something obstructing your airways?"

Sleep monitoring

The patients with nocturnal swallowing/choking symptoms, sleepwalking and sleep terrors underwent a video-polysomnography (V-PSG) on two consecutive nights, the first one following a sleep deprivation at home ranging from 20 to 24 hours. The monitoring included eight bipolar EEG channels (Fp1-C3, C3-

O1, C3-T3, T3-O1, Fp2-C4, C4-O2, C4-T4, T4-O2) to exclude any concurrent nocturnal frontal or temporal lobe epilepsy, a right and left electro-oculogram, surface electromyograms of the levator menti as well as right and left tibialis anterior muscles, nasal pressure measurement through a cannula, tracheal sound recording through a microphone placed on the surface of the trachea, thoracic and abdominal belts to assess respiratory efforts, electrocardiography, pulse oximetry, EEG-synchronized infrared video-monitoring and ambient sound recording. The patients with sleep apnea had the same sleep monitoring (but no concomitant video) limited to a single night. The nurses were instructed not to disturb sleep and to only intervene to prevent any injury or replace electrodes. There was no systematic collection of dream recall after N3 arousals or in the morning, but some patients spontaneously reported their mental content. Sleep stages, EEG arousals, respiratory events, periodic leg movements and muscle activity were scored by experienced neurologists after visual inspection of the recordings, using standard criteria and previously described definitions.^{9, 10} Special attention was paid to counting the sudden arousals from slow-wave sleep (events frequently associated with arousal disorders), which occurred from N3 (and here precisely the former non-REM sleep stage 4) and were defined as an abrupt shift from a diffuse delta EEG rhythm to a diffuse alpha EEG rhythm lasting more than 15 s (to distinguish them from brief arousals).

Statistical analysis

Measures were compared between groups using the chi-square test for categories (corrected when appropriate) and Student's t test for continuous measures, with a *p* level classified as significant when less than 0.05.

RESULTS

Patients with swallowing and choking syndrome

Patient 1. A 26-year-old woman had a personal and family (brother, cousin) history of sleepwalking and sleep talking in childhood, of four general anesthesia with intubation, and of moderate, intermittent

asthma. Concerning the night-time episodes (with an irregular frequency ranging from every night for a week to once a month), she described the feeling of abnormal swallowing associated with the sensation of swallowing an abnormal object (a coin or a little rock) that stuck in her throat and prevented her from breathing, so that she often ran out of her bed and called for help. During the V-PSG, she had 5 sudden arousals from N3 (Figure 1): During 4 arousals, she raised her head and explored around with a surprised gaze, and during one arousal, she swallowed several times with a scared gaze and a sustained sudden tachycardia (Video clip 1). She reported after this episode that she felt choked with a little coin. She later underwent another nocturnal polysomnography with a 19-channels EEG which showed 4 arousals from slow wave sleep, one of them associated with the swallowing and choking sensations, and no epileptic figures.

Patient 2. A 33-year old man had a personal and family (mother) history of sleepwalking and sleep terrors during childhood that attenuated during his teenage years. At the age of 18, the patient inhaled a piece of chewing gum, choked and was saved by a Heimlich maneuver performed by a friend. At the age of 33, he began to have nightmares with the sensation of swallowing an unusual object (chewing gum, several nails and a coin), which stayed stuck in his throat and prevented him from breathing. During these episodes, he woke up yelling for help with a feeling of imminent death, ran to the kitchen to spit in the sink and had to wait a few seconds before being totally awake and realizing that he was safe. These episodes occurred almost every night. During the non-choking sleepwalking episodes, he darted out of the bed and was injured by knocking into the table and breaking a vase. There were a mild anxiety disorder since childhood, but no panic attacks during the daytime or at sleep onset, no post-traumatic stress disorder and no symptoms of gastro-esophageal reflux and asthma. On the V-PSGs, the patient had 8 sudden arousals from N3 stage during the first night and 12 during the second night (Figure 1). These arousals were associated with motor symptoms including opening the eyes, raising the head and trunk, and exploring the surroundings with a surprised gaze. Once, the patient ran out of

his bed yelling "Help! Help! Help!", as he concomitantly had the vision of a truck swooping down on him (Video clip 2). In another episode, he suddenly raised his head, trunk and arms, and briefly wiped his mouth, swallowed and lied down again (Video clip 3). In addition, the associated autonomous reaction in these 20 arousals included a sudden and sustained tachycardia (the heart rate rose from 60 to 130-180 bpm), indices of vasoconstriction on the pulse oximeter signal (a sudden decrease of the signal), as well as increased amplitude of the thoraco-abdominal volume and increased respiration rate. Several sudden arousals were preceded by a peculiar pattern associated with swallowing (a brief increase of chin EMG signal during stage N3, associated with a blink, as checked by making a swallowing maneuver during wakefulness) (Figure 2).

Other patients Among the 11 patients (Table 1), a patient felt a cold tea spoon stuck in his throat. He ran from his bed to the bathroom while screaming that he could not breathe, and swallowed fresh water until the horrible feeling disappeared. A 32-year old woman had choked as a child with a marble stuck in her throat. At the age of 30 (and not before), she had recurrent nocturnal awakenings while choking, with a clear sensation of a marble stuck in her throat and of the teacher's fingers in her throat trying to remove it (Patient 9). None of the 11 cases exhibited: (i) any episodes during sleep stages other than N3; (ii) any episodes of a choking sensation during the daytime; (iii) any personal or family history of seizures or loss of consciousness, and any epileptic activity on V-PSG; (iv) any swallowing or respiratory problem during daytime; or (v) any sleep-disordered breathing or flow limitation before the episodes. Their demographic and clinical characteristics, as well as sleep measures are shown in Tables 1 and 2. All has multiple awakenings from N3 with a concomitant increase in heart rate (at least 30% greater than the pre-awakening heart rate), vasoconstriction and increased respiratory frequency. One of them had

three sudden arousals from stage N3, one of them being associated with spitting in his hand (Video clip 4).

Pharyngeal sensations in regular sleepwalkers

Among the 68 consecutive patients with sleepwalking or sleep terrors, none of them was specifically referred for nocturnal choking, but 9 had the occasional sensation of choking during nocturnal episodes, and this sensation was associated with abnormal pharyngeal sensations in 3 of them (Tables 1, 2).

Among these 3 patients, a woman with severe sleepwalking only once had the feeling of having inhaled a butterfly through the nose, but not in the pharynx. We previously reported this video-clinical case including several home videos and this specific event.¹¹ The other sleepwalkers had no pharyngeal, choking or suffocating feelings during the night.

Pharyngeal sensations in patients with sleep apnea

Among 41 patients referred for suspected sleep apnea (on the basis of daytime sleepiness, obesity and, in two cases, coronary heart disease), 37 had an apnea-hypopnea index greater than 5 (Tables 1 and 2). In this group, 14 reported choking sensations during the night, with a wide frequency variation (from twice in their life to several times per night). The group with choking sensations did not differ from the group without choking in terms of gender ratio (71% vs. 78% male, $p = 0.94$), age (54 ± 16 vs. 59 ± 11 years old, $p = 0.34$) and apnea-hypopnea index (34 ± 19 vs. 36 ± 17 , $p = 0.73$). Of the 14 patients with a choking sensation, 2 (5%) occasionally had the sensation of something blocked in the throat (a piece of apple or pear in one patient and an unidentified object in the other patient). The other patients reported sleep-associated choking as a *"shortness of breath plus dry mouth"* ($n=1$), *"a need to take a large inspiration after a prolonged snoring"* ($n=1$), *"a need to deeply inspire"* ($n=1$), and just choking ($n=9$).

Comparisons between patient groups

The patients with swallowing and choking syndrome all had, as expected, swallowing and choking symptoms during sleep and a higher frequency of these symptoms than the sleepwalkers, but similar age, gender ratio, body mass index, level of daytime sleepiness and history of arousal disorders (Table 1). The sleep characteristics were not different between these two groups, including a mean number of 5 awakenings in stage N3 (Table 2). The patients with swallowing and choking disorder were younger and thinner than those with sleep apnea, presented more frequently with swallowing and choking symptoms, with a higher weekly frequency, and a similar level of daytime sleepiness (Table 1). All had a history of arousal disorders, while it was infrequent in patients with sleep apnea. They had a better sleep quality than the patients with sleep apnea, as indicated by lower wakefulness after sleep onset time, shorter N1-N2 time, longer N3 time, as well as lower arousal index and apnea-hypopnea index (Table 2).

DISCUSSION

We described 11 adults referred for recurrent sleep-related episodes of paroxysmal choking, mostly due to the subjective sensation of having swallowed invisible foreign objects. The V-PSG demonstrated that the episodes occurred during sudden motor arousals from N3 sleep, associated with surface EEG arousal (alpha rhythm), no epileptic activity and an intense adrenergic activity, reminiscent of arousal disorders. Distressed emotional behavior with predominantly fearful behavior (including a scared facial expression and speech), sitting, standing, screaming, and spitting behaviors were prominent, but they were not stereotypic in the same patient. In addition, the timing of abnormal behavior peaked during the first third of the night. All patients had in common a current or former history of arousal disorders (sleepwalking, sleep terrors and sleep talking). In all, these findings sustain the idea that their sleep-related swallowing and choking syndrome belongs to the spectrum of arousal disorders.

The sensory aspect of the syndrome was peculiar, as most patients described an identifiable object stuck in their throat. The objects were mostly rigid (except for the chewing gum, lizard tail and tongue), metallic or cold (ring, spoon, coin, pebble, nails, electrical cables), usually of small size (except for the computer, scrubbing brush and gas container), and foreign (except for the tongue). Their shape, nature and size were not stereotyped and clearly identified by most patients, suggesting that they composed a formed, complex sensory hallucination. The hallucination was brief (several seconds) and disappeared after the patients had made some sensory and motor maneuvers such as pulling the tongue with their hand, shaking the head, spitting or swallowing water. It seemed that the hallucinatory pharyngeal sensations disappeared when a normal input sensation (swallowing real water, or spitting real saliva) was elicited or when the patients became completely conscious. Some patients were able to speak or shout during the pharyngeal sensation, but this obvious evidence of open airways before shouting was transiently insufficient to convince them of the airway patency. Most hallucinations were isolated, but in one case (the ideation of swallowing a potion that made the patient mute), the abnormal swallowing was the last fragment of a dreamed scenario. These sensory hallucinations had the brevity of a single scene or image (collapsing ceiling, insects) reported by patients with sleepwalking and sleep terrors.¹² The concomitant emotional content was fear, with the autonomic and behavioral manifestations of intense fear. All patients had the feeling of imminent death, which would have made sense had the airways actually been obstructed. We observed intense autonomic discharge, with tachycardia, tachypnea, vasoconstriction and increased muscle tone. The patients usually opened the eyes with a scared look, sat up in bed and were poorly responsive to external stimuli. Bolting out of bed and running was observed as well.

Many differential diagnoses can be considered in the presence of nocturnal choking. The most difficult differential diagnosis of disorder of arousals is epilepsy. In this direction, one may note that seizures originating in the mesial frontal cortex or insula can also present with choking episodes. The insula receives visceral sensation of the gastrointestinal tract, from the tongue extending at least to the

esophagus. Electrical stimulation of the insular cortex in epilepsy patients undergoing stereotactic depth electrode recording can evoke pharyngeal or laryngeal sensations of constriction ranging from breathing discomfort to a sensation of strangulation, but does not trigger any hallucinations of formal objects to our knowledge. Auras of insular seizures often start with unpleasant sensations in the throat of variable intensity, followed by facial paresthesias, loss of awareness, and oro-alimentary automatisms as seizures spread to mesial temporal regions.¹³ Because of the deep location of the insula, ictal scalp EEG is usually also unrevealing, as only 20-30% of such seizures have an ictal correlate on surface EEG. A deep electrode montage could help clarify this case and possibly others here, as well as ictal single photon emission computed tomography (SPECT) and drug challenges. Indeed, a patient was reported with initial recurrent choking spells at night, which developed with years towards nocturnal generalized seizures as well as daytime choking spells.¹⁴ Although surface video-EEG during events was unrevealing, an ictal SPECT showed an hyperperfusion of the left insular region which was, in addition to the clinical development and improvement with oxcarbamazepin, suggestive of simple partial insular seizure. In our series, we could not obtain ictal SPECT during the night. Another case of gasping, choking, motor-behavioral events (shouting repeatedly "help") during three arousals from N3 in a 33 y old man was recently reported as probable seizures from nocturnal frontal lobe epilepsy, because the paroxysmal manifestations were quite stereotypic and remitted when the patient took carbamazepine.¹⁵ Hypothetically, therapeutic challenges with anti-epileptic drugs (especially sedative anti-epileptic drugs) cannot help to differentiate between a disorder of arousal and an insular seizure, because they **could** alleviate both disorders. Rather, the non-stereotypic aspects of motor behavioral manifestation and feelings, the absence of daytime symptoms, of partial or generalized seizures, and the timely association with arousal from N3 (plus the absence of events during wake-sleep transition and arousals from N1 or N2, while this is mostly the case in sleep related epilepsy) are evidences against an epileptic origin. Compulsive spitting is also a rare but documented symptom in temporal lobe epilepsy.^{16, 17} Patient 3 spat during one motor episode, but not during other, various motor behaviors

upon arousing from N3. The non-stereotypic aspect of the object sensation in the same patients and the timely association with stage N3 arousals argues against a temporal discharge too. Indeed, during nocturnal frontal lobe epilepsy, seizures most occur from N1 and N2 sleep (and not exclusively from the N3 stage) and the behaviors and sensations during seizures are stereotypic.^{18, 19} In a previous series of patients with non REM parasomnia, swallowing was noticed in 7% of motor events associated with the arousals from N3, vs. 0% in patients with nocturnal frontal lobe epilepsy.¹⁸ Other differential diagnoses such as panic attack, paroxysmal heart arrhythmia, esophageal reflux and nocturnal paroxysmal asthma were easily ruled out when observing the events during sleep monitoring because of the time occurrence of episodes on N3 arousals, recurrent N3 arousals, absence of burning sensations, and absence of arrhythmia.

Airway patency was also maintained during the episodes, with no evidence of flow limitation as the cause of both the N3 arousal and the abnormal choking sensation. Of interest, more than one third of patients with sleep apnea experienced occasional and sometimes frequent sensations of choking during the night, but it was almost never associated with a concomitant sensation of an object stuck in the throat. Plus, it was never the primary motive for consulting a physician. The pharyngeal sensations associated with obstructive sleep apnea have been infrequently studied, although choking is reported as one of the symptoms of the syndrome.¹ It is a surprising but common clinical experience to observe patients with more than 200 complete obstructions of the pharynx by aspiration of the tongue, uvula or soft palate per night who never complain of any obstruction feeling during the night, as seen here in 62% of patients with sleep apnea. This discrepancy between patients with swallowing and choking syndrome who had a normal airway patency but still felt they swallowed an object or their tongue and choke, and patients with sleep apnea who really choked and did not feel it or panic may be explained by a different timing of the arousal; the arousal causes an immediate opening of the upper airways in patients with sleep apnea, while the false sensation of obstructed airways in patients with swallowing and choking syndrome takes several seconds to disappear while the patient has a partial awareness.

All patients with sleep-related swallowing and choking syndrome had former or current classical sleepwalking/sleep terror. They developed the swallowing and choking syndrome at ages 25-35, i.e., in adulthood. Observed episodes occurred with concomitant EEG, EKG and respiratory hallmarks of non-REM parasomnia (mostly sleep terrors). Taken together, these results support the concept that the sleep-related swallowing and choking syndrome is a subsequent specialization of sleepwalking/sleep terror. Among a consecutive series of 68 adults with sleepwalking and/or sleep terrors (both conditions are frequently concomitant in adults), 13% had occasional choking and 4% felt they were swallowing something during parasomniac episodes. It suggests that 4% of adults with parasomnia have occasional symptoms of swallowing and choking, which constitutes a rare occurrence within the spectrum. Indeed, we found only 11 cases of swallowing and choking syndrome among the patients referred to our sleep disorder unit during the last 7 years, although we are overspecialized in treating abnormal behaviors during sleep in adults.^{20, 21} One may wonder if some patients with previous sleepwalking would specialize their nocturnal behavior in the form of swallowing and choking (as observed in Sleepwalker 3), some of them because they previously had a real choking episode following inhalation of chewing gum and a marble (n=2), drowning (n =1) and after intubation for surgery (n = 2). On one hand, the prolonged latency between the choking episode and the syndrome, plus the absence of daytime revival of the choking does not favor the hypothesis of a post-traumatic stress disorder. On the other hand, revivals of stressful events during parasomniac episodes are common.^{11, 21} One may also suspect that the interest of the patients was biased toward finding an explanation in their history for these pharyngeal sensations.

In conclusion, several findings suggest that the sleep-related swallowing and choking syndrome is, at least in some cases, a specialized variant of the arousal disorders. It would be however prudent to keep an open mind as to the possibility that some of these events may represent seizures. The overlap

between disorders of arousal and nocturnal seizures may be greater than generally appreciated.

Eventually, swallowing and choking syndrome as an arousal disorder is worthy of recognition as a differential diagnosis of other common (sleep apnea, esophageal reflux, asthma, panic attack) and uncommon (insular seizure) causes of nocturnal choking.

Acknowledgments: The authors thank the Neuroscience Institute (IHU de Neurosciences Pitié-Salpêtrière) for its support.

REFERENCES

1. American Academy of Sleep Medicine. The international Classification of Sleep Disorders - Revised. Chicago, IL: American Academy of Sleep Medicine,, 2005.
2. Guilleminault C, Eldridge FL, Phillips JR, Dement WC. Two occult causes of insomnia and their therapeutic problems. *Arch Gen Psychiatry* 1976;33:1241-5.
3. Miller AJ. Deglutition. *Physiol Rev* 1982;62:129-84.
4. Pinto A, Yanai M, Nakagawa T, Sekizawa K, Sasaki H. Swallowing reflex in the night. *Lancet* 1994;344:820-1.
5. Teramoto S, Sudo E, Matsuse T, et al. Impaired swallowing reflex in patients with obstructive sleep apnea syndrome. *Chest* 1999;116:17-21.
6. Campbell AH, Pierce R. Brief upper airway dysfunction. *Respir Med* 1994;88:125-9.
7. American Academy of Sleep Medicine. The international Classification of Sleep Disorders, 3rd edition. Darien, IL: American Academy of Sleep Medicine,, 2014.
8. Johns MH. A new method for measuring daytime sleepiness: the Epworth Sleepiness Scale. *Sleep* 1991;14:540-5.

9. Rechtschaffen A, Kales A. A manual of standardized terminology, techniques and scoring system for sleep stages of human subjects. Los Angeles: UCLA Brain Information Service/Brain Research Institute., 1968.
10. Iber C, Ancoli-Israel S, Chesson A, Quan S. The AASM Manual for the Scoring of Sleep and Associated Events: Rules, Terminology and Technical Specifications, 1st Ed. Westchester, IL: American Academy of Sleep Medicine, 2007.
11. Mwenge B, Brion A, Uguccioni G, Arnulf I. Sleepwalking: long-term home video monitoring *Sleep Medicine* 2013;14:1226-8.
12. Oudiette D, Leu S, Pottier M, Buzare MA, Brion A, Arnulf I. Dreamlike mentations during sleepwalking and sleep terrors in adults. *Sleep* 2009;32:1621-7.
13. Isnard J, Guenot M, Sindou M, Mauguier F. Clinical manifestations of insular lobe seizures: a stereo-electroencephalographic study. *Epilepsia* 2004;45:1079-90.
14. Davis KA, Cantor C, Maus D, Herman ST. A neurological cause of recurrent choking during sleep. *J Clin Sleep Med* 2008;4:586-7.
15. Terzaghi M, Sartori I, Cremascoli R, Rustioni V, Manni R. Choking in the night due to NFLE seizures in a patient with comorbid OSA. *J Clin Sleep Med* 2014;10:1149-52.
16. Kaplan PW, Kerr DA, Olivi A. Ictus expectoratus: a sign of complex partial seizures usually of non-dominant temporal lobe origin. *Seizure* 1999;8:480-4.
17. Renier WO. Compulsive spitting as manifestation of temporal lobe epilepsy. *Eur J Paediatr Neurol* 2004;8:61-2.
18. Derry C, Harvey A, Walker M, Duncan J, Berkovic S. NREM arousal parasomnias and their distinction from nocturnal frontal lobe epilepsy: A video EEG analysis. *Sleep* 2009;32:1637-44.
19. Tinuper P, Provini F, Bisulli F, et al. Movement disorders in sleep: guidelines for differentiating epileptic from non-epileptic motor phenomena arising from sleep. *Sleep Med Rev* 2007;11:255-67.

20. Brion A, Flamand M, Oudiette D, Voillery D, Golmard JL, Arnulf I. Sleep-related eating disorder versus sleepwalking: a controlled study. *Sleep Med* 2012;13:1094-101.
21. Arnulf I, Bin Z, Uguccioni G, et al. A scale for assessing the severity of arousal disorders. *Sleep* 2013.

Legend of the figures

Figure 1: Hypnograms of Patient 1 (upper panel) and 2 (lower panel), indicating with arrows repeated awakenings from NREM sleep stage 4 (now N3 sleep). The arrow with a C indicates the choking behavior, while the arrows with an A indicates awakenings concomitant with other, non-stereotyped kind of behaviors (opening eyes, looking around, speaking, raising head, raising trunk, touching the electrodes) or without any motor arousals (quiet arousal).

Figure 2: Sleep recordings in Patient 2 during the second awakening from N3 sleep, showing normal EEG delta figures (without spikes or hypersynchronous delta) before the awakening, as well as normal upper airway patency. Note the muscle twitch on the chin EMG channel, synchronous with an eye blink, which accompanies the swallowing behavior, followed 200 ms after by a complete motor arousal. This chin/eye signal was associated only with swallowing behavior, but not with the 7 other awakenings from N3 sleep which were associated to confusional arousals (opening eyes, raising head, exploring around with the gaze) or to more complex behaviors (vocalization, sitting on bed or running out of bed while shouting for help).

Supplemental Figure. Image by image details of the onset (first second) of the two motor events arising from N3 awakening in Patient 2, illustrating the different motor sequences (raising arms behind the head as if stretching, upper panel, vs. catching the shit and darting out of the bed, lower panel). These differences are not supportive of an epileptic discharge as causing the behavior, because the onset would be stereotypic.

Legends of the video

Video clip 1: Patient 1 sleeps in N3 stage when she suddenly turns, opens her eyes and has repeated mouth/chin movements with attempts to swallow. The gaze is apparently scared with an increased respiratory rate and a sustained tachycardia. She later reported feeling a little stone stuck in her throat and trying to swallow it.

Video clip 2: Patient 2 is sleeping in N3 stage. He suddenly raises his head, trunk and arms, then briefly wipes his mouth, swallows and lies down again. Note that the behavior is different from the motor episode in video clip 3, indicating that he has non-stereotypic episodes. The image-by-image details of the onset of the motor events are shown in supplemental figure to illustrate that the two behaviors cannot have the same ictal-like onset.

Video clip 3: Patient 2 is sleeping in N3 stage. He suddenly runs out of his bed yelling "Help! Help! Help!", as he concomitantly has the vision of a truck swooping down on him. He then calms down and goes back to bed.

Video clip 4: Patient 3 is sleeping in N3 stage. He suddenly opens eyes, turns, raises his hand to his mouth (which has a snout like attitude) and spits inside.

Table 1. Demographic and clinical characteristics of patients with swallowing and choking syndrome vs. patients with sleepwalking/sleep terrors and patients with sleep apnea

Patient groups	Swallowing and choking syndrome	Sleepwalking/ Sleep terror	Sleep apnea
Number	11	68	37
Age, y	37.5 ± 12.2 ^b	32.1 ± 10.1	58.0 ± 10.6
Sex, % men	73	50	73
Body mass index, kg/m ²	25.0 ± 2.9 ^b	23.2 ± 3.9	31.6 ± 6.3
Epworth sleepiness score, 0-24	11.5 ± 4.4	9.3 ± 5.1	10.2 ± 4.5
History of arousal disorders, n (%)*	11 (100) ^b	68 (100)	2 (5)
Swallowing and choking symptoms			
Sleep-associated choking, n (%)	11 (100) ^{a,b}	9 (13)	14 (38)
Age at choking onset, y	34.7 ± 4.5	MD	MD
Choking frequency/week	3.7 ± 2.8 ^a	0.05 ± 0.05	7 ± 10.8
Sleep-associated swallowing an object, n (%)	10 (91) ^{a,b}	3 (4)	2 (5)
Swallowing frequency/week	3.7 ± 2.8 ^{a,b}	0.004 ± 0.006	0.05 ± 0.02
Type of object stuck in the throat	Nails, coin, ring, pebble, tea spoon, fork, electrical cable, honey candy, lighter, scrubbing brush, gas cylinder, computer, one's tongue, fingers,	Needles, chewing gum, fork, papier- mâché	Apple or pear slice, unidentified object

Hallucinatory choking from slow wave sleep

chewing gum, lizard

tail, unidentified

foreign object, gag

*Including sleepwalking, sleep terrors and frequent sleep talking. ^ap<0.05 for a difference with the sleepwalking/sleep terror group, ^bp<0.05 for a difference with the sleep apnea group, Student's t test.

Table 2. Sleep measures in patients with swallowing and choking syndrome, vs. patients with sleepwalking/sleep terrors and patients with sleep apnea

Patient groups	Swallowing and choking syndrome	Sleepwalking/ Sleep terror	Sleep apnea
Number	12	68	37
Total sleep time, min	425 ± 130	465 ± 100	417 ± 85
REM sleep latency, min	121 ± 44	130 ± 74	94 ± 43
Wakefulness after sleep onset, min	58 ± 22 ^b	64 ± 39	108 ± 73
Sleep stages, % of total sleep time			
N1	4.8 ± 3	4.8 ± 4.3	4.9 ± 3.4
N2	48.1 ± 5.1 ^b	49.8 ± 9.2	62 ± 8.2
N3	25.4 ± 10.2 ^b	23.7 ± 8.7	17.1 ± 6.2
REM sleep	20.8 ± 5.7	20.0 ± 5.8	16.7 ± 5.6
Number of awakenings in N3 (range)	5.3 ± 2.5 ^b (2-9)	5.2 ± 3.6 (0-16)	1.9 ± 1.5 (0-5)
Arousal index	11.7 ± 6.5 ^b	11.0 ± 6.0	30.3 ± 12.9
Apnea-hypopnea index	2.0 ± 2.8 ^b	3.4 ± 7.0	34.5 ± 17.9

^ap<0.05 for a difference with sleepwalking/sleep terror group, ^bp<0.05 for a difference with the sleep apnea group, Student's t test.

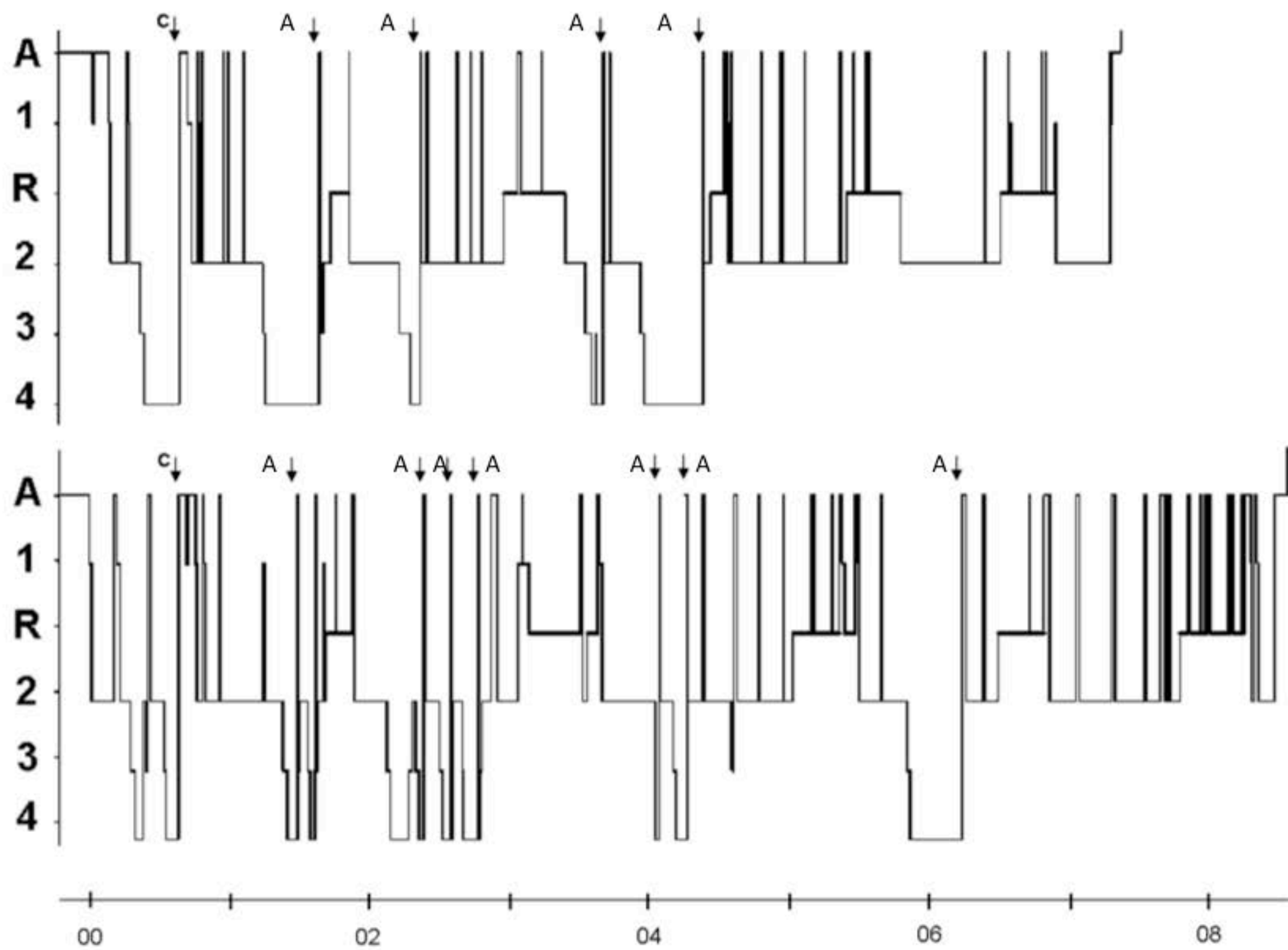


Fig. 1

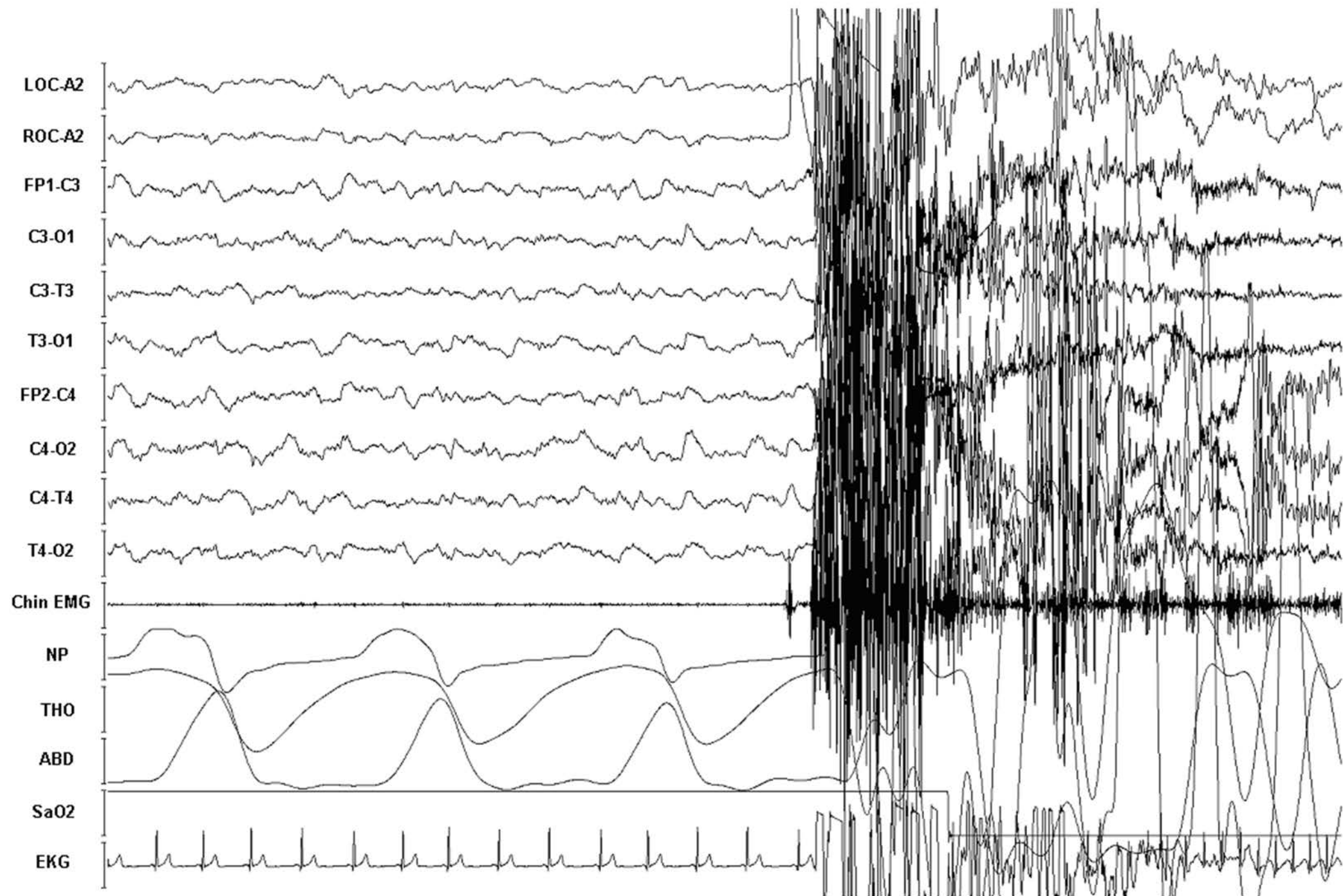


Fig. 2

