



HAL
open science

Heterophile Antibody Interference led to Unneeded Chemotherapy in a Testicular Cancer Patient

Daniele G. Soares, Françoise Millot, Isabelle Lacroix, Jean-Pierre Lotz

► To cite this version:

Daniele G. Soares, Françoise Millot, Isabelle Lacroix, Jean-Pierre Lotz. Heterophile Antibody Interference led to Unneeded Chemotherapy in a Testicular Cancer Patient. *Urology Case Reports*, 2016, 9, pp.1-3. 10.1016/j.eucr.2016.07.006 . hal-01366795

HAL Id: hal-01366795

<https://hal.sorbonne-universite.fr/hal-01366795>


Submitted on 15 Sep 2016

HAL is a multi-disciplinary open access archive for the deposit and dissemination of scientific research documents, whether they are published or not. The documents may come from teaching and research institutions in France or abroad, or from public or private research centers.

L'archive ouverte pluridisciplinaire **HAL**, est destinée au dépôt et à la diffusion de documents scientifiques de niveau recherche, publiés ou non, émanant des établissements d'enseignement et de recherche français ou étrangers, des laboratoires publics ou privés.



Distributed under a Creative Commons Attribution - NonCommercial - NoDerivatives | 4.0 International License



Oncology

Heterophile Antibody Interference led to Unneeded Chemotherapy in a Testicular Cancer Patient



Daniele G. Soares ^{a,*}, Françoise Millot ^b, Isabelle Lacroix ^c, Jean-Pierre Lotz ^{a,d}

^a Department of Medical Oncology, APREC (Alliance Pour la Recherche En Cancérologie), Hospital Tenon (Public Assistance – Paris Hospitals, AP-HP), 4, rue de la Chine, 75970 Paris Cedex 20, France

^b Department of Biochemistry, Hospital Tenon (Public Assistance – Paris Hospitals, AP-HP), 4, rue de la Chine, 75970 Paris Cedex 20, France

^c Cerba laboratory, 95066 Cergy Pontoise Cedex 9, France

^d Sorbonne Universities, University Pierre et Marie Curie (IUC-UPMC Univ. Paris 06), France

ARTICLE INFO

Article history:

Received 17 July 2016

Accepted 26 July 2016

Keywords:

Germ cell tumors

Testicular cancer

Heterophile antibodies

Human chorionic gonadotropin

Chemotherapy

ABSTRACT

Human heterophile antibodies may develop after infection or contact with animal tissues or animal serum products. These antibodies have the capacity to bind to the animal immunoglobulins used in immunoassays leading to erroneous results. We here report a case of a testicular germ cell tumor patient who developed heterophile antibodies during the surveillance period of his disease. Following false-positive results of human chorionic gonadotropin (hCG) he received unneeded chemotherapy. This article also stresses the problem of using serum tumor markers without no major imaging abnormalities to diagnose a patients' relapse.

© 2016 The Authors. Published by Elsevier Inc. This is an open access article under the CC BY-NC-ND license (<http://creativecommons.org/licenses/by-nc-nd/4.0/>).

Introduction

Germ cell tumors (GCTs), and in particular testicular germ cell tumors, are relatively rare. They mainly affect young men, being mostly prevalent around the age of 30 years old.

Histopathologically, testicular GCTs can be classified into two major groups, seminomas and non-seminomas, each comprising 50% of cases. Non-seminomatous germ cell tumors (NSGCTs) are often more aggressive than seminomas, and more likely to spread beyond the testicle. These two subtypes share several risk factors but have distinct clinical characteristics and treatment modalities.¹

Since many years, the serum tumor markers alpha-fetoprotein (AFP), lactate dehydrogenase (LDH) and human chorionic gonadotropin (hCG) are considered as essential tools to both diagnose and monitor GCTs.

The degree of hCG elevation is directly proportional to tumor burden. Increased levels of hCG after orchiectomy reveals residual tumor. In metastatic patients, the levels of hCG before chemotherapy starts are used to correctly allocate the IGCCCG (International Germ Cell Consensus Classification) prognostic category.²

Elevated levels of hCG after chemotherapy may indicate incomplete response to therapy and relapsed or refractory disease.

Case presentation

In October 2012, a 31-year-old patient, HIV-negative, underwent a unilateral orchiectomy because of a right testicular mass. The patient presented with a germ cell tumor hCG-secreting. Histological examination of the tumor revealed a mixed NSGCT with components of seminoma and embryonal carcinoma. He had enlarged retroperitoneal nodes and a pulmonary metastatic lesion.

Elevated levels of serum dimer-hCG (RIA-gnost HCG Cisbio Bioassay) were observed post-orchiectomy. Thus, he received systemic treatment consisting of four chemotherapy courses based on bleomycin-etoposide-cisplatin (BEP).

Following BEP, a clear decline in serum dimer-hCG levels was noticed (Fig. 1). He also had normal serum levels of free β -subunits-hCG, AFP and LDH. Chest and abdominal computed tomography (CT) scans revealed normal images and led to an attitude of surveillance.

Four months later (August 2013), CT scanning revealed signs of pulmonary nodes progression. An increased in number and size together with elevated dimer-hCG levels justified a surgical intervention. Microscopic examination of the resected nodes showed no

* Corresponding author.

E-mail address: daniele.grazz@cancer-aprec.com (D.G. Soares).

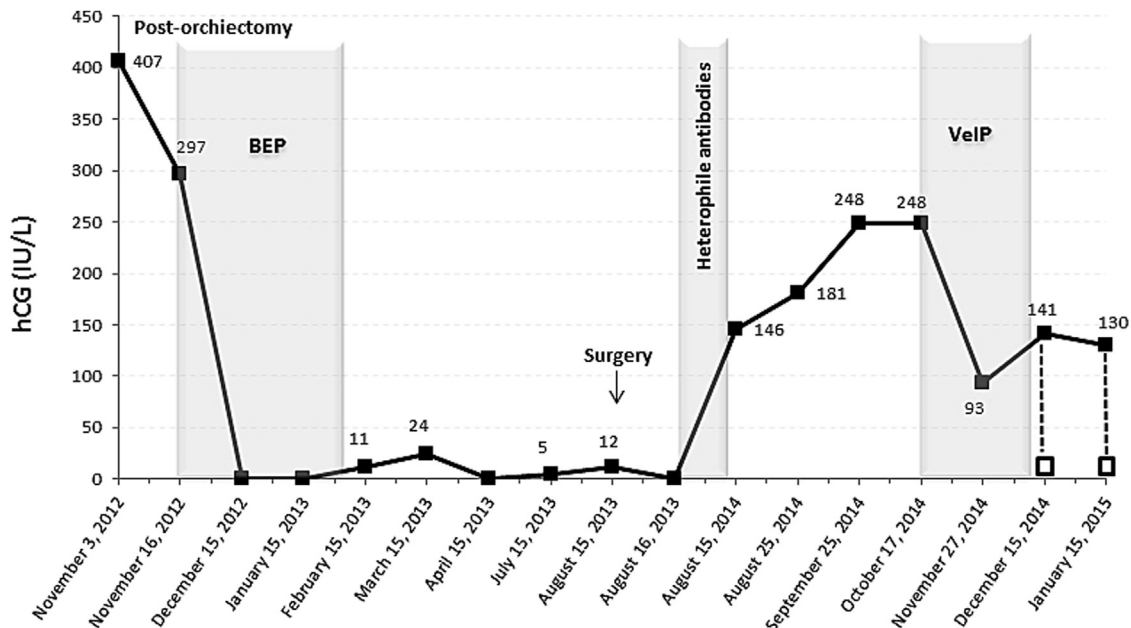


Figure 1. Human chorionic gonadotropin levels and treatment interventions during patients' management. All values measured dimer-hCG, except points showed by a white square which indicates total hCG. hCG: human chorionic gonadotropin; BEP: bleomycin-etoposide-cisplatin; VeIP: vinblastine-ifosfamide-cisplatin.

viable cancer cells and concluded to a pulmonary fibrosis post-chemotherapy. No further treatment was provided.

During surveillance, one year later (August 2014), serum tumor marker analysis revealed elevated dimer-hCG concentrations (146 IU/L), following by two additional positive results of 181 IU/L determined 10 days later, and 248 IU/L determined 6 weeks later. A complete imaging assessment was then undertaken and included a CT scan, a positron-emission tomography (PET), a magnetic resonance imaging (MRI) of the brain, a testicular ultrasound and an endoscopy. No major abnormalities were detected, but the existence of a duodenal lesion was suggested. Given the constantly increasing in dimer-hCG levels, we diagnosed a relapse of the patient and decided to treat him with second-line chemotherapy consisting in 4 cycles of vinblastine-ifosfamide-cisplatin (VeIP).

From October to December 2014, during chemotherapy, variations of dimer-hCG levels were observed. Surprisingly, when total hCG (including dimers and free beta-subunits, Architect Abbott) was compared with dimer-hCG we found a discrepancy: total hCG at 12 IU/L and dimer-hCG at 130 IU/L. This results were inconsistent since the sum of dimer-hCG + free β -subunits-hCG was lower than dimer-hCG alone.

The discordant results among hCG levels led us to consider the possibility of interference in the immunoassays reaction. Indeed, serial dilutions of the serum resulted in abnormal values of dimer-hCG. Moreover, after using a blocking agent for heterophile antibody (HTB: Heterophilic Blocking Tubes, Scantibodies³), no measurable dimer-hCG was detected and moderate impact on the results of total hCG was observed.

To confirm these results, the patients' sample was then reanalyzed using other methods. Again, total hCG (Cobas Roche) revealed to be negative (<2 IU/L). It is interesting to mention that the interference found in total hCG assay was also observed when free β -subunits were determined using two different methods. The ELSA-FB HCG Cisbio Bioassay revealed a negative result while the Kryptor Brahms showed elevated levels. Once more, the presence of heterophile antibodies was highlighted using HTB.

In addition, an HIV test revealed false-positive results suggesting that the patient was infected during the surveillance period.

Since all assay used to monitor hCG levels during the surveillance period employ murine antibodies we measured human anti-mouse antibodies (HAMA) on the previously collected patients' blood samples using an enzyme-linked immunosorbent assay kit (IBA HAMA ELISA MEDAC). The presence of circulating antibodies produced against animal immunoglobulins was confirmed.

Under these circumstances, the treatment was discontinued and the patient did not receive the fourth cycle of VeIP chemotherapy. The patient is currently alive and remains in complete remission.

Discussion

Heterophile antibodies are human antibodies with the capacity to bind to animal immunoglobulins. These antibodies may develop after infection or contact with animal tissues or animal serum products. As a result, significant interference in assays that employ nonhuman immunoglobulins can be occasionally observed.⁴

In testicular GCT patients, false-positive serum hCG have been reported by few case reports. Elevated levels due to heterophile antibodies interference led, in some cases, to unnecessary surgery or unappropriated systemic treatment.

Different causes of false hCG elevation have been described in the literature, including: heterophile antibody interference; reinfusion of peripheral blood stem cells containing high concentrations of hCG; irregular forms of hCG produced by malignant tumors such as nicked or hyperglycosylated hCG; IgA deficiency; marijuana use; abnormal renal function and acute HIV infection.

Our patient had normal renal function, normal serum IgA levels and denied marijuana use. However, we found positive results for an HIV test performed at that time. This finding led us to raise the question of an acute HIV infection which could be resulted in the production of heterophile antibodies.⁵ Then, the patients' blood samples were recollected and reanalyzed for HIV, revealing negative

results. This implies that heterophile antibodies caused false-positive HIV ELISA results.

Measures of hCG and other markers alone is not a sufficient tool to monitor for relapse. However, rising markers are often the earliest evidence of relapse. In our patient, three consecutive increased in hCG levels concurrent with a possible duodenal lesion led us to diagnose a relapse of the patient. Fortunately, further hCG oscillations and the stability of the suspected lesion led us to discover the presence of heterophile antibodies.

Conclusion

Heterophile antibodies can interfere with hCG immunoassays leading to false-positive results. The situation reported herein is insufficiently recognized by clinicians and otherwise should help to protect patients from unnecessary interventions.

Disclosure

The authors declare no conflict of interest.

References

1. Albers P, Albrecht W, Algaba F, et al. Guidelines on testicular Cancer: 2015 update. *Eur Urol.* 2015;68:1054–1068.
2. International germ cell consensus classification: A prognostic factor-based staging system for metastatic germ cell cancers. International germ cell cancer collaborative group. *J Clin Oncol.* 1997;15:594–603.
3. Esfandiari N, Goldberg JM. Heterophile antibody blocking agent to confirm false positive serum human chorionic gonadotropin assay. *Obstet Gynecol.* 2003;101:1144–1146.
4. Bjerner J, Bormer OP, Nustad K. The war on heterophilic antibody interference. *Clin Chem.* 2005;51:9–11.
5. Walensky RP, Rosenberg ES, Ferraro MJ, et al. Investigation of primary human immunodeficiency virus infection in patients who test positive for heterophile antibody. *Clin Infect Dis.* 2001;33:570–572.