



HAL
open science

Helical tomotherapy of spinal chordomas: French Multicentric, retrospective study of a cohort of 30 cases

Maxime Bobin, Christina Zacharatou, Paul Sargos, Véronique Brouste, Albert Lisbona, Marc-André Mahé, Georges Noël, Amandine Halley, Loïc Feuvret, Louis Gras, et al.

► To cite this version:

Maxime Bobin, Christina Zacharatou, Paul Sargos, Véronique Brouste, Albert Lisbona, et al.. Helical tomotherapy of spinal chordomas: French Multicentric, retrospective study of a cohort of 30 cases. Radiation Oncology, 2017, 12, pp.32. 10.1186/s13014-017-0768-1 . hal-01483638

HAL Id: hal-01483638

<https://hal.sorbonne-universite.fr/hal-01483638>

Submitted on 6 Mar 2017

HAL is a multi-disciplinary open access archive for the deposit and dissemination of scientific research documents, whether they are published or not. The documents may come from teaching and research institutions in France or abroad, or from public or private research centers.

L'archive ouverte pluridisciplinaire **HAL**, est destinée au dépôt et à la diffusion de documents scientifiques de niveau recherche, publiés ou non, émanant des établissements d'enseignement et de recherche français ou étrangers, des laboratoires publics ou privés.



Distributed under a Creative Commons Attribution 4.0 International License

RESEARCH

Open Access



Helical tomotherapy of spinal chordomas: French Multicentric, retrospective study of a cohort of 30 cases

Maxime Bobin^{1,7*}, Christina Zacharitou¹, Paul Sargos¹, Véronique Brouste², Albert Lisbona³, Marc-André Mahé³, Georges Noël⁴, Amandine Halley⁵, Loïc Feuvret⁵, Louis Gras⁶, Stéphanie Hoppe², Bénédicte Henriques de Figueiredo¹ and Guy Kantor^{1,7}

Abstract

Purpose: To evaluate the efficacy and toxicity of helical tomotherapy (HT) in the management of spine chordomas when proton therapy is unavailable or non-feasible.

Methods and materials: Between 2007 and 2013, 30 patients with biopsy-proven chordomas were treated by HT in five French institutions. Information regarding local control (LC), overall survival (OS), progression-free survival (PFS) and metastasis-free survival (MFS) was collected. Clinical efficacy, toxicity and treatment quality were evaluated.

Results: Two-year actuarial LC, OS, PFS and MFS were 69.9%, 96.7%, 61.2% and 76.4%, respectively. HT treatments were well tolerated and no Grade 4–5 toxicities were observed. HT permitted the delivery of a mean dose of 68 Gy while respecting organ at risk (OAR) dose constraints, in particular in the spinal cord and cauda equina.

Conclusions: This multicentric, retrospective study demonstrated the feasibility of HT in the treatment of spine chordomas, in the absence of hadron therapy.

Keywords: Helical tomotherapy, Spinal chordomas, Survival rates, Local control

Introduction

Chordomas are rare cancers, representing 1–4% of primary bone cancers, with a global incidence of 8.4 in 10 million persons [1]. Chordomas are aggressive tumors with a strong tendency to recur locally after surgical resection and with a known resistance to radiotherapy and chemotherapy [2]. Radical en bloc resection with healthy tissue margins is currently the preferred treatment as it delivers best local control (LC) rates. However, this procedure is rarely possible because of the proximity of the tumor to neurological structures (spinal cord, cauda equina, nerve roots) or infiltration in soft tissue and vasculo-nervous axis or digestive and urinary system vicinity [3].

High-dose radiation therapy (RT), in particular proton and carbon ion therapy, leads to an increase in LC of the disease [4–6]. Unfortunately, these techniques remain very costly and are not readily available. Helical tomotherapy (HT) is a RT technique that combines intensity modulated RT (IMRT) and image guided RT (IGRT), thereby allowing dose escalation to the tumor while reducing doses to adjacent organs at risk (OARs). HT has shown, in our experience, dosimetric advantages to other forms of IMRT as it allows for steeper dose gradients at the border of the tumor than other radiation delivery techniques.

We report here the results of a French multicentric, retrospective study in which we address the technical feasibility, treatment quality and toxicity of HT in the treatment of 30 spinal cord and sacral chordomas. National recommendations for clinical indication target volume and OAR definitions were previously detailed and published before this study [7, 8].

* Correspondence: m.bobin@bordeaux.unicaner.fr

¹Department of Radiotherapy, Institut Bergonié, Comprehensive Cancer Center, 229 cours de l'Argonne, 33076 Bordeaux, France

⁷University of Bordeaux, Bordeaux Cedex, France

Full list of author information is available at the end of the article

Primary objective of the study was to assess the LC of the disease. Secondary objectives were overall survival (OS), progression-free survival (PFS), metastasis-free survival (MFS) and clinical efficacy and toxicity of tomotherapy treatments.

Methods and materials

Ethics approval

This study was performed with the permission of the Consultative Commission of the Treatment of Information in Research for Health (CCTIRS, Comité Consultatif sur le Traitement de l'Information en matière de Recherche dans le domaine de la Santé) and the National Commission of Information Technology and Freedom (CNIL, Commission Nationale de l'Informatique et des Libertés). Institutional Board approvals were also obtained. The study was performed in the context of a national program, previously defined and published [7, 8].

Patient selection

Between 2007 and 2013, 30 patients diagnosed with biopsy-proven non-metastatic chordoma of mobile spine and sacrum were treated with HT in 5 different comprehensive cancer centers (Institut Bergonié Comprehensive Cancer Center, Bordeaux $n = 14$; René Gauducheau Comprehensive Cancer Center, Nantes $n = 7$; Paul Strauss Comprehensive Cancer Center, Strasbourg $n = 6$; Hôpital de la Pitié-Salpêtrière-Charles-Foix, Paris $n = 2$; Oscar Lambret, Comprehensive Cancer Center, Lille $n = 1$).

Tomotherapy

When planning radiation therapy, Tomotherapy offered advantages over other techniques including IMRT, VMAT for clues of conformity, homogeneity and coverage. Furthermore, it facilitated a better dose gradient compared to other techniques, allowing maximum reduction of the dose to OARs. Hence, it was chosen as the preferred IMRT technique and all participating centers used the same Tomotherapy equipment. HT was performed by a Tomotherapy accelerator (Accuray® Inc.) using IMRT and IGRT techniques and 6 MV photons. Treatment planning used a dose calculation algorithm based on the convolution of pre-calculated photon kernels [9] and a dose optimization algorithm based on χ^2 minimization [10, 11]. Daily Megavoltage Computed Tomography (MVCT) was performed for patient positioning. Magnetic Resonance Imaging (MRI) examinations were used to define the target volume. Margins from Clinical Target Volume to Planning Target Volumes (PTVs) used were 3 or 5 mm. Nine tomotherapy plans with a simultaneous integrated boost technique were delivered.

Statistical analysis

The analysis of survival rates was performed using the STATA v.11 software (Stata Corp., College Station, TX). The median follow-up of the series was calculated according to the inverse Kaplan-Meier method [12], with the deaths being censored [13]. OS, LC, PFS and MFS were calculated using the Kaplan-Meier method. OS was based on the date of first histological diagnosis to the date of analysis or time to death. LC, PFS and MFS were based on the date of the start of the tomotherapy.

Simulation of proton therapy plans

Proton dosimetry plans were calculated with the treatment planning system Eclipse v.11 (Varian Medical Systems, Palo Alto, CA). The fluence of spot-scanning beams was optimized using the algorithm developed by Lomax [7] and the dose was calculated with a pencil beam convolution-superposition algorithm [6]. As treatment planning with protons does not require the use of opposed beams as in the case of photon beam therapy, we tried to reduce the number of beams as much as possible. In a total of 29 proton dosimetries (28 patients, one with a separate boost), 17 proton plans had 2 fields, 8 plans had 3 fields, 4 plans had 4 fields and one plan had 6 fields. All proton plans had at least two fields to reduce the dose to the skin, a third field was introduced to compensate for the more complicated anatomies (for better OAR sparing), and finally, 4 or more fields were necessary in the case of osteosynthesis material within the target volume to further homogenize the dose distribution.

Dosimetric data collection

All dosimetric data were collected according to the International Commission on Radiation Units and Measurements, ICRU 83 criteria [14]. For the PTVs, the conformity indices (CoI) of the 95% (CoI_{95%}) and 98% (CoI_{98%}) isodoses (volume of 95% or 98% isodose divided by PTV volume, respectively), and the homogeneity indices (HI = $(D_{2\%} - D_{98\%}) / D_{50\%}$, where $D_{x\%}$ is the dose covering $x\%$ of the PTV volume) were recorded. For the OARs, we noted the maximal doses to the spinal cord, medullary canal, cauda equina, sacral nerve roots, rectum, bladder and bowels (including small intestine and colon). Healthy tissue was the volume defined by the external contour excluding the PTVs and we calculated and collected its average dose (in Gy) and integral dose (in J). Dosimetric data were collected in the same way for tomotherapy plans and for proton therapy plans.

Results

Patient characteristics

Table 1 summarizes the characteristics of the patient cohort. Mean patient age at the start of the treatment

Table 1 Patient characteristics

Characteristic	<i>n</i>
No. of patients	30
Male	18
Female	12
Age during RT	
< 40 years	2
< 60 years	11
Location	
Cervical spine	3
Lumbar spine	5
Sacrum and coccyx	22
Presentation	
Primary	24
Locally recurrent	6
Follow-up (25 patients alive)	
< 12 months	2
< 24 months	6
< 36 months	8
Surgery	22
R0	5
R1	11
R2	5
Implants	10

was 62.7 years (range, 36.7–83.1 years). Eighteen men and 12 women were treated. Three patients had cervical, 5 had lumbar and 22 had sacro-coccygeal chordomas. Mean interval between symptom expression and anatomical or pathological diagnosis was 19.2 months (range, 0–175 months). The disease manifested as isolated pain in 18 patients (60%), vesical-sphincterian dysfunctions in 4 patients, a combination of the two in 2 patients and one sacral chordoma was detected as a result of sub-acute cauda equina syndrome; upon diagnosis, 35% of the 23 evaluated patients were WHO 0 (8 patients), 52% were WHO 1 (12 patients), 9% were WHO 2 (2 patients) and 4% were WHO 3 (1 patient) [15].

Twenty-two patients (73%) had an operation, of which 10 (45%) had osteosynthesis implants. The remaining eight patients (27%) had only biopsy. Surgical resection was evaluated as R0 (no microscopic residual disease) in 5 patients (23%), R1 (microscopic residual disease) in 11 patients (50%), R2 (macroscopic residual disease) in 5 patients (23%) and not classified in one patient (4%). Six patients (27%) had second surgery evaluated as R0 for one patient, R1 for 2 patients and R2 for 3 patients. Two patients received neo-adjuvant treatment, one with Imatinib and one with a combination of Imatinib and Cyclophosphamide.

Furthermore, when our cohort was treated, proton therapy for spinal and sacral chordomas was not available in France. Referrals for proton therapy abroad were refused because of accessibility or delay issues and technical reasons related to localization. The reasons for refusal were often multiple for a single patient. Our patient cohort was not optimal for proton therapy as several patients were in bad overall condition, had a very large PTV (mean 610 cc) and/or osteosynthesis implants. Proton therapy is readily available for patients in better general condition, and in particular for patients that are younger than our patient cohort (children and young adults having priority for proton therapy as a general rule).

Tomotherapy treatment

Radiation therapy was proposed for 12 post-operative patients (40%) with residual disease (microscopic residual R1 for 7 patients and macroscopic residual R2 for 5 patients), for 8 patients (27%) with not-operated primary tumor, for 6 patients (20%) with relapse tumor and for 4 patients (13%) with operated primary tumor without residual disease R0. The median interval between pathology and beginning of HT was 4.6 months (range, 1.7–93.7).

Dose was prescribed to the median of the PTV, according to the ICRU 83 recommendations [14]. OAR dose constraints conformed to published recommendations [7, 8, 16–19]. For technical reasons, the dosimetric treatment plans of 2 patients were not recovered and therefore the dosimetric analysis was performed on the remaining 28 patients. Ten patients had two PTVs: PTV1 was the macroscopic target volume prescribed a boost dose in addition to the dose prescribed to the microscopic target volume PTV2. The boost volume was defined on post-operative MRI by the residual tumor volume. The use of simultaneous integrated boost plans depended on the individual center's practices. Eighteen patients had a single PTV (PTV1). Median prescribed doses for PTV1 were 68 Gy (range, 61.2–74 Gy) in 35 fractions (range, 25–39) with a median fraction dose of 2 Gy (range, 1.8–2.5 Gy) and for PTV2 they were 59.6 Gy (range, 46–66.5 Gy) in 31 fractions (range, 23–35) with a median fraction dose of 1.9 Gy (range, 1.8–2). All patients were able to complete their treatment. The total and fraction doses were center-dependent.

No specific adjuvant treatments were performed following HT. At relapse, patients received different salvage including surgery, RT and general targeted therapy (Imatinib, Sorafenib, and Gefitinib) or chemotherapy (Doxorubicin).

Analysis of survival

The median follow-up time was 30 months (95% CI, 19.8–40). Ten patients (33%) developed a local failure. Actuarial 1- and 2-year LC rates were 92.7% (95% CI,

73.7–98.13) and 69.9% (95% CI, 46–84.8), respectively. At the time of the analysis, 5 patients died due to chondroma evolution. Two- and 3-year OS rates were 96.7% (95% CI, 78.6–99.5) and 90.6% (95% CI, 65.7–97.7), respectively. The 1- and 2-year MFS rates were 96.5% (95% CI, 77.9–99.5) and 76.4% (95% CI, 51.2–89.7), respectively (Fig. 1).

Eight patients (27%) developed a metastasis (in the order of highest to lowest frequency): bone, epiduritis, pulmonary/pleural, cutaneous or sub-cutaneous and muscular, inguinal and/or mediastinal adenopathies, liver, and one exceptional salivary glands metastasis confirmed by pathological examination.

Clinical follow-up

All patients remained clinically stable during HT. At the time of diagnosis, 85% of the evaluated patients (23 out of 27) experienced pain, with 70% (7 out of 10) reporting pain $\leq 5/10$ and three patients reporting pain between 6 and 7/10. At the completion of HT, 6 out of the 17 evaluated patients experienced no pain, 6 presented a pain from 1 to 5/10 and 5 reported a pain between 6 and 9/10. Retrospective data on analgesics (only available for a few patients) showed a minor increase to level 3 analgesics at the conclusion of treatment (from 2 out of 8 evaluated patients at diagnosis to 6 out of 14 evaluated patients at the end of HT).

Post-operatively, of the 21 evaluated patients, 6 (29%) and 3 (14%) exhibited complications of Grade 2 and 3, respectively. These complications were not aggravated

by HT. One year after HT treatment, 16 and 11% of the evaluated patients presented vesical sphincter disorders of Grade 2 and 3, respectively. An example of clinical and radiological case is shown in Fig. 2.

Toxicity of tomotherapy

Radiation treatment toxicities are summarized in Table 2. There were thirty instances of acute Grade 1 and 2 cutaneous and digestive toxicities. Four early Grade 3 toxicities were reported. Three of them were cutaneous and one was digestive, involving mucoid diarrhea and dehydration requiring hospitalization. Two late Grade 3 toxicities were reported. One case of cutaneous necrosis and one case of radiation proctitis were observed. The latter was responsible for rectal bleeding which required hospitalization and endoscopic treatment by Plasma Argon. No radiation myelitis or radiation neuropathy cases were reported. No Grade 4 or 5 toxicities were observed. No definitive interruption of treatment due to toxicity was observed.

Dosimetric data

For PTV1, the mean volume was 610 cc (range, 7–2211), median $CoI_{95\%}$ was 1.25 (range, 0.83–4.13) for tomotherapy and 1.08 (range, 0.88–5.97) for proton therapy, median $CoI_{98\%}$ was 1.05 (range, 0.64–2.12) for tomotherapy and 0.93 (range, 0.71–1.62) for proton therapy, and median HI was 0.13 (range, 0.03–0.62) for tomotherapy and 0.07 (range, 0.03–0.91) for proton therapy. For PTV2, the mean volume was 659 cc (range, 27–1894), median

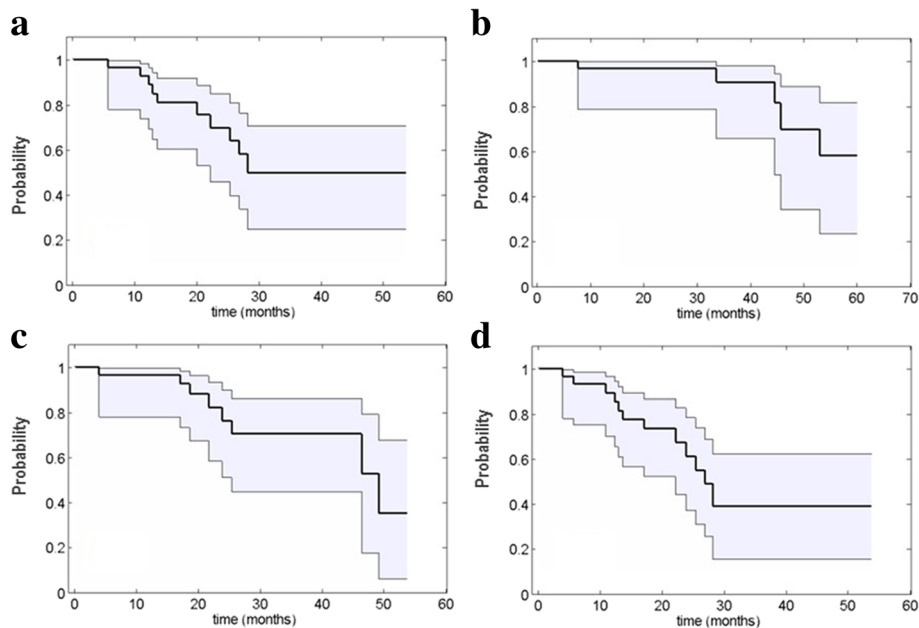


Fig. 1 Survival probabilities with the 95% CI shown as the shaded area: (a) local control, (b) overall survival, (c) metastasis free survival and (d) progression free survival

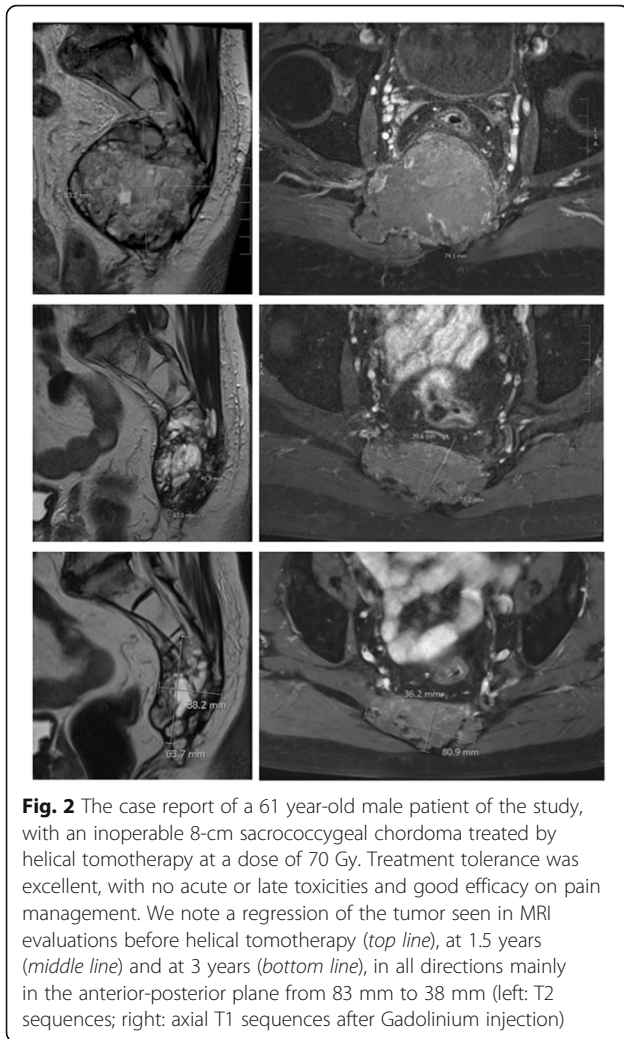


Fig. 2 The case report of a 61 year-old male patient of the study, with an inoperable 8-cm sacrococcygeal chordoma treated by helical tomotherapy at a dose of 70 Gy. Treatment tolerance was excellent, with no acute or late toxicities and good efficacy on pain management. We note a regression of the tumor seen in MRI evaluations before helical tomotherapy (*top line*), at 1.5 years (*middle line*) and at 3 years (*bottom line*), in all directions mainly in the anterior-posterior plane from 83 mm to 38 mm (left: T2 sequences; right: axial T1 sequences after Gadolinium injection)

CoI_{95%} was 1.49 (range, 0.89–4.12) for tomotherapy and 1.1 (range, 0.87–3.34) for proton therapy, median CoI_{98%} was 1.23 (range, 0.63–3.59) for tomotherapy and 0.98 (range, 0.42–3.15) for proton therapy, and median HI was 0.18 (range, 0.06–0.49) for tomotherapy and 0.09 (range, 0.03–0.27) for proton therapy. Median values of the minimal, maximal and mean doses to OARs are given in Table 3 for tomotherapy and proton therapy plans. In general, we observed that minimal and mean doses were lower in proton therapy. This is due to the lower number

Table 2 Radiation treatment toxicities

	Acute toxicities			Late toxicities		
	Grade 1	Grade 2	Grade 3	Grade 1	Grade 2	Grade 3
Skin	9	9	3	5	1	1
GI ^a	9	3	1	0	0	1
Urinary	4	0	0	0	0	0
Neurological	1	1	0	0	2	0

^aGI gastro-intestinal

Table 3 Median values of minimal, maximal and average OAR doses for tomotherapy (T) and proton therapy (P)

	D _{min} (Gy)	D _{mean} (Gy)	D _{max} (Gy)
Spinal cord, T	2.3	11.3	30.6
Spinal cord, P	0	15.1	42.8
Medullary canal, T	1.8	13.4	50.9
Medullary canal, P	0	8.1	57.7
Lumbosacral canal, T	1.8	25.0	49.4
Lumbosacral canal, P	0	13.3	51.9
Bladder, T	5.4	23.3	54.8
Bladder, P	0	0.1	15.4
Rectum, T	3.6	31.5	66.2
Rectum, P	0	13.2	69.1
Digestive system, T	1.1	17.4	63.4
Digestive system, P	0	1.5	64.2

of beams that are needed for sufficient coverage of the target volume with the prescribed dose (Fig. 3).

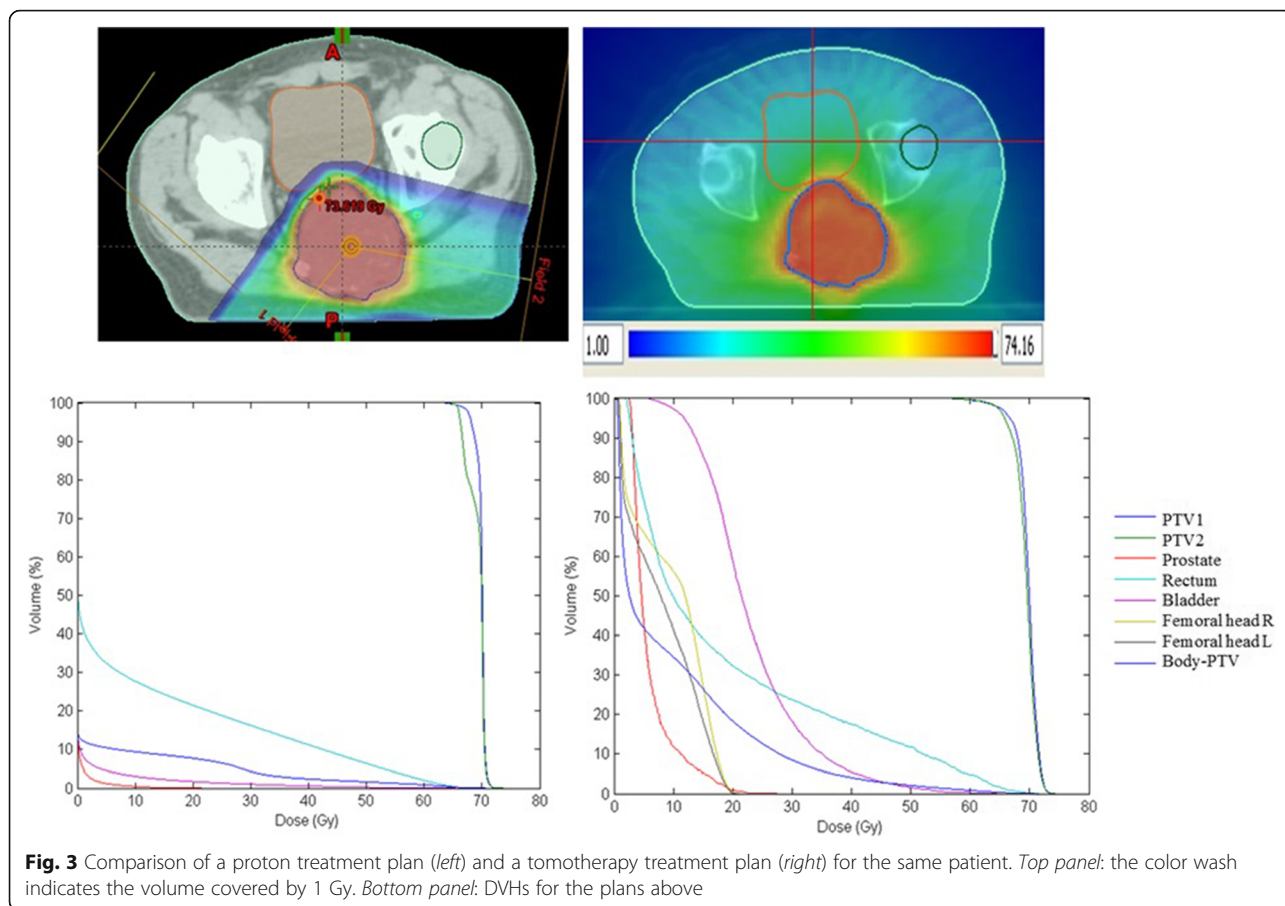
Integral dose is significantly lower in proton treatment plans, as illustrated in Fig. 4. The median integral dose for the 28 patients considered in the dosimetric comparative study was 70 J for proton plans and 240 J for tomotherapy plans. Overall, proton dosimetries are superior to tomotherapy dosimetries, if one ignores the presence of metal implants, which tend to create hot and cold spots inside the PTV in proton plans. The only other exception we found to this conclusion were cases where the PTV completely encloses the spinal cord and in our experience, tomotherapy plans seem to better spare the spinal cord in those situations.

Discussion

Different RT techniques have been evaluated for the treatment of spine chordomas and are listed in Table 4. In the case of photon beams, these included 3D conformal RT (3DCR) [20, 21], IMRT [22, 23] and stereotactic [24, 25] delivery. When compared to these techniques, hadron therapy with protons [4, 5, 26–30] or carbon ions [6, 31] showed better results in LC and survival.

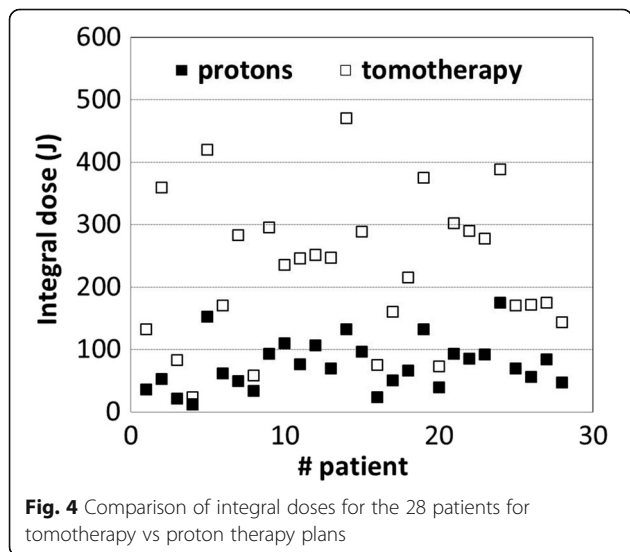
The present study has a median follow-up of 30 months. A subsequent updating of data will allow a longer median follow-up and better knowledge of the effectiveness and longer-term toxicity of the technique. Our 2-year LC rate of 70% is inferior to the rates reported in the best series of proton or carbon ion therapy, which have 3-year and 5-year rates of 90 and 85%, respectively. Our 3-year OS rate of 90.6% is comparable to proton and carbon ion series (Table 4).

Twenty seven percent of the patients in our study presented a metastatic evolution of their disease. This result is comparable to other series in the literature with longer median follow-up times.



Conventional RT, up to 40–60 Gy doses, results in a 5-year LC rate of only 10–60% [3]. Terezakis et al. [23] reported that IMRT photon RT of 66 Gy resulted in a 2-year LC of 65% and a 2-year global survival of 79%, which is comparable to our results. Yamada et al. [24]

used stereotactic RT in a single fraction of 24 Gy and obtained tumor regression or stability in 95% of patients at 2 years. Delaney et al. delivered up to 77.4 Gy relative biological effectiveness (RBE) to gross disease [4, 5] and found that proton therapy resulted in a 5-year and 8-year LC rates of 81 and 74%, respectively. Imai et al. [6] treated 38 inoperable sacral chordomas with carbon ions and observed a 5-year LC rate of 89%.



For various reasons, our LC rate is lower than reported in other series. Firstly, 73% of our cases were voluminous sacral localizations and this is associated with a less favorable prognosis. Secondly, 87% of our patients had residual disease when treated by HT. Staab et al. [30] reported that the 5-year LC rate decreased from 66 to 47% in the macroscopic residual cases. Similarly, Rutz et al. [28] reported that when the tumor residual exceeded 30 cc, the global- and progression-free survival results were statistically lower than in the case of smaller volumes. Thirdly, our patients had large target volumes (mean and median PTV values were 640 cc and 421 cc, respectively). Fourthly, osteosynthesis material was present in one-third of the patients. Out of the 10 local failure patients, one patient had a PTV larger than 610 cc and 2 patients presented osteosynthesis and 2 patients had both large PTV

Table 4 Results of the main series of radiotherapy of chordomas of the mobile spine and the sacrum

Beam	# Pts (location)	Dose Gy (RBE)	Dose/Fx Gy (RBE)	Median follow-up (years)	Local control at years	Global non-specific (specific) survival at years	Presence of metastasis	Reference
X	48: 23 (S) 20 (SB) 5 (MS)	50/40/24	2/1/8			54% at 5 20% at 10		Catton et al. [19]
X	26: 12 (S) 10 (SB) 4 (MS)	[30–66.6]	[1.8–2.5]			62% at 5 (83% at 5) 28% at 10		Cummings et al. [20]
X (IMRT)	34 (S)	66	[1.8–2]	4.5	27% at 5	70% at 5 (80% at 5)	9%	Zabel-du Bois et al. [21]
X (IMRT)	7 (MS)	66	[1.8–2]	1.45	65% at 2			Terezakis et al. [22]
X (SRS)	24: 10 (S) 7 (C) 4 (T) 3 (L)	18–24	[18–24]	2	95% at 4	67% at 4	12.5%	Yamada et al. [23]
X (SBRT)	18: 8 (MS) 7 (SB) 3 (S)	35	[6–8]	3.8	59.1% at 5	74.3% at 5		Henderson et al. [24]
¹ H +/-X	29 (MS)	76.6	1.8	7.3	84% at 5	87% at 5		Delaney et al. [4, 5]
	24: 19 (S) 2 (C) 1 (T) 2 (L)	77.4	[1.8–2.5]	4.7	90.4% at 3 79.8% at 5	78.1% at 5		Chen et al. [25]
	25 (MS, S)	70.4	1.8	2.65	73.3% at 5	64.3% at 5		Wagner et al. [26]
	26: 9 (C) 2 (T) 8 (L) 7 (S)	72	[1.8–2.5]	2.9	86% at 3	84% at 3		Rutz et al. [27]
	19: 12 (SB) 5 (C) 1 (L) 1 (S)	74	[1.8–2]	3.8	81% at 5	89% at 5		Rombi et al. [28]
	40: 16 (C) 4 (T) 10 (L) 11 (S)	72.5	[1.8–2]	3.6	62% at 5	80% at 5		Staab et al. [29]
12C	38 (S)	70.4	[4.4–4.6]	6.7	95% at 3 89% at 5	95% at 3 86% at 5		Imai et al. [6]
	17 (S)	70.4	[4.4–4.6]	4.1	100% at 5	53.3% at 5	14%	Nishida et al. [30]

SB skull base, T thoracic, L lumbar, S sacral, MS mobile spine, C cervical

and osteosynthesis. Finally, we note that two-thirds of our patients were not eligible for proton therapy because of their altered clinical condition mainly due to the evolution of their disease. The retrospective nature of data collection did not allow us to obtain any specific clinical data which, therefore, limits the clinical description of patients.

Of note, osteosynthesis material could be an important limitation for proton therapy. For instance, Staab et al. [30] report on proton therapy showed the 5-year LC rate decrease from 100 to 30% when osteosynthesis material was present. Similarly, in Rutz et al. study [28], implants were also associated with a lower LC rate ($p = 0.034$). The authors proposed several factors that may explain the decrease in LC. Among major concerns, they noted that protons create important dose heterogeneity in the vicinity of the material with cold and hot spots, which requires a reduction of the fraction dose and/or total dose [28]. In addition, Verburg et al. [32] have demonstrated that osteosynthesis material can introduce

uncertainties of up to 1 cm in proton range. Finally, osteosynthesis material complicates the delineation of volumes because of artifacts in the planning CT.

The clinical characteristics of our patients were comparable to those stated in the literature [1, 2]. Symptoms were dominated by pain, similar to other series [33]. We recorded partial or total pain alleviation in the available data. However, some data were missing as pain was not always reported. Vesical-sphincterian dysfunctions were not aggravated by HT.

In the majority of cases, HT was delivered without interruption due to toxicity. Only six cases of Grade 3 toxicity were recorded. In our cohort, we did not observe any Grade 4 or 5 toxicity, radiation myelitis or radiation neuropathy (including the roots of cauda equina). In general, more severe toxicities are reported in proton and carbon ion series. Delaney et al. [4, 5] observed three sacral neuropathies, following 76.6–77.4 Gy RBE and reported a complication risk of 13%

for Grade 3–4 at 8 years. Chen et al. [26] found 8 sacral fractures, one secondary cancer, one foot drop, one erectile dysfunction and one loss of perineal sensation. Rutz et al. [28] reported four severe complications: one Grade 2 sensory neuropathy, one Grade 3 subcutaneous necrosis, one Grade 3 osteonecrosis and one Grade 5 secondary cancer. Imai et al. [6] described two late Grade 4 cutaneous reactions which required skin grafts, and six neurological complications, of which one was an incomplete transient aggravation of sciatic nerve paralysis. The small number of patients did not allow us to show significantly that the dose per fraction or the total dose were factors for local control, toxicity risk or relapse.

Conclusion

This multicentric, retrospective study included an important series of patients, considering the rarity of the pathology and the cohorts discussed in other series. To our knowledge, this is the largest series of chordomas treated by HT. A longer follow-up is necessary to assess long-term survival and late toxicities. Hence, we conclude that HT permitted the delivery of high tumor doses with acceptable toxicities and can be used in the management of spine chordomas when hadron therapy is not possible.

Abbreviations

3DCR: Three dimensional conformal radiation therapy; CI: Confidence interval; Col: Conformity index; HT: Helical tomotherapy; IGRT: Image guided radiation therapy; IMRT: Intensity modulated radiation therapy; LC: Local control; MFS: Metastasis-free survival; MRI: Magnetic resonance imaging; MVCT: Megavoltage computed tomography; OAR: Organ at risk; OS: Overall survival; PFS: Progression-free survival; PVT: Planning target volumes; RBE: Relative biological effectiveness; RT: Radiation therapy

Acknowledgements

The authors would like to thank Dr. Ravi Nookala of Institut Bergonié for medical writing services.

Funding

This study was partly funded by the POPRA program (Conceil Régional Aquitaine and European Fonds FEDER).

Availability of data and materials

Due to internal regulations at the Institut Bergonié, we are currently unable to share the data.

Authors' contributions

MB collected all clinical and dosimetric data at each center, studied the result sets and wrote the article. CZ calculated the tomotherapy dosimetry plans for some patients, simulated the proton plans for all patients and analyzed their dosimetric characteristics, and co-wrote the article. PS was the doctor for some of the patients. VB performed the statistical studies. AL planned some dosimetry plans. M-AM was the doctor for some of the patients. GN was the doctor for some of the patients. AH planned some dosimetry plans. LF was the doctor for some of the patients. LG was the doctor for some of the patients. SH helped editing the article. BFH helped editing the article. GK was the doctor for some of the patients and oversaw this work. All read and approved the final manuscript.

Competing interests

The authors declare that they have no competing interests.

Consent for publication

Not applicable.

Ethics approval and consent to participate

This study was performed with the permission of the Consultative Commission of the Treatment of Information in Research for Health (CCTIRS, Comité Consultatif sur le Traitement de l'Information en matière de Recherche dans le domaine de la Santé) and the National Commission of Information Technology and Freedom (CNIL, Commission Nationale de l'Informatique et des Libertés). Institutional Board approvals were also obtained. The study was performed in the context of a national program, previously defined and published [7, 8]. The Institutional Boards deemed consent from the participants is not required due to retrospective nature of the study.

Author details

¹Department of Radiotherapy, Institut Bergonié, Comprehensive Cancer Center, 229 cours de l'Argonne, 33076 Bordeaux, France. ²Clinical and Epidemiological Research Unit, Institut Bergonié, Comprehensive Cancer Center, 229 cours de l'Argonne, 33076 Bordeaux, France. ³Department of Radiation Oncology, Institut de Cancérologie de l'Ouest René Gauducheau, Comprehensive Cancer Center, Saint-Herblain Cedex, France. ⁴Department of Radiotherapy, Centre Paul Strauss, Comprehensive Cancer Center, 3 rue de la Porte-de-l'Hôpital, BP 4267065 Strasbourg, France. ⁵Department of Radiotherapy, Hôpital de la Pitié-Salpêtrière-Charles-Foix, Assistance Publique Hôpitaux de Paris, 47-83, boulevard de l'Hôpital, 75013 Paris, France. ⁶Academic Radiation Oncology Department, Centre Oscar Lambret, Comprehensive Cancer Center, 3 rue Frédéric Combemale, Lille, France. ⁷University of Bordeaux, Bordeaux Cedex, France.

Received: 13 May 2016 Accepted: 16 January 2017

Published online: 31 January 2017

References

1. Small NR, Gautschi OP, Radovanovic I, et al. Incidence and relative survival of chordomas: the standardized mortality ratio and the impact of chordomas on a population. *Cancer*. 2013;119:2029–37.
2. Walcott BP, Nahed BV, Mohyeldin A, et al. Chordoma: current concepts, management, and future directions. *Lancet Oncol*. 2012;13:e69–76.
3. Uhl M, Debus J. Chordoma: an assessment of future treatment and management strategies. *Exp Opin Orphan Drugs*. 2014;2:557–65.
4. DeLaney TF, Liebsch NJ, Pedlow FX, et al. Phase II study of high-dose photon/proton radiotherapy in the management of spine sarcomas. *Int J Radiat Oncol Biol Phys*. 2009;74:732–9.
5. DeLaney TF, Liebsch NJ, Pedlow FX, et al. Long-term results of Phase II study of high dose photon/proton radiotherapy in the management of spine chordomas, chondrosarcomas, and other sarcomas. *J Surg Oncol*. 2014;110:115–22.
6. Imai R, Kamada T, Tsuji H, et al. Effect of carbon ion radiotherapy for sacral chordoma: results of Phase I-II and Phase II clinical trials. *Int J Radiat Oncol Biol Phys*. 2010;77:1470–6.
7. Kantor G, Mahe MA, Giraud P, et al. Helical tomotherapy: general methodology for clinical and dosimetric evaluation (national French project). *Cancer Radiother*. 2006;10:488–91.
8. Kantor G, Mahe MA, Giraud P, et al. French national evaluation for helicoidal tomotherapy: description of indications, dose constraints and set-up margins. *Cancer Radiother*. 2007;11:331–7.
9. Mackie TR, Bielajew AF, Rogers DW, et al. Generation of photon energy deposition kernels using the EGS Monte Carlo code. *Phys Med Biol*. 1988;33:1–20.
10. Olivera GH, Shepard DM, Reckwerdt PJ, et al. Maximum likelihood as a common computational framework in tomotherapy. *Phys Med Biol*. 1998;43:3277–94.
11. Shepard DM, Olivera GH, Reckwerdt PJ, et al. Iterative approaches to dose optimization in tomotherapy. *Phys Med Biol*. 2000;45:69–90.
12. Kaplan EL, Meier P. Nonparametric estimation from incomplete observations. *J Am Stat Assoc*. 1958;53:457–81.
13. Shuster JJ. Median follow-up in clinical trials. *J Clin Oncol*. 1991;9:191–2.
14. Prescribing, Recording and Reporting Photon-Beam Intensity-Modulated Radiation Therapy (IMRT): Contents. *J ICRU* 2010;10.
15. Louis DN, Perry A, Reifemberger G, et al. *Acta Neuropathol*. 2016;131:803.

16. Kirkpatrick JP, van der Kogel AJ, Schultheiss TE. Radiation dose-volume effects in the spinal cord. *Int J Radiat Oncol Biol Phys.* 2010;76:S42–9.
17. Michalski JM, Gay H, Jackson A, et al. Radiation dose-volume effects in radiation-induced rectal injury. *Int J Radiat Oncol Biol Phys.* 2010;76:S123–9.
18. Viswanathan AN, Yorke ED, Marks LB, et al. Radiation dose-volume effects of the urinary bladder. *Int J Radiat Oncol Biol Phys.* 2010;76:S116–22.
19. Kavanagh BD, Pan CC, Dawson LA, et al. Radiation dose-volume effects in the stomach and small bowel. *Int J Radiat Oncol Biol Phys.* 2010;76:S101–7.
20. Catton C, O'Sullivan B, Bell R, et al. Chordoma: long-term follow-up after radical photon irradiation. *Radiother Oncol.* 1996;41:67–72.
21. Cummings BJ, Hodson DJ, Bush RS. Chordoma: the results of megavoltage radiation therapy. *Int J Radiat Oncol Biol Phys.* 1983;9:633–42.
22. Zabel-du-Bois A, Nikoghosyan A, Schwahofer A, et al. Intensity modulated radiotherapy in the management of sacral chordoma in primary versus recurrent disease. *Radiother Oncol.* 2010;97:408–12.
23. Terezakis SA, Lovelock DM, Bilsky MH, et al. Image-guided intensity-modulated photon radiotherapy using multifractionated regimen to paraspinous chordomas and rare sarcomas. *Int J Radiat Oncol Biol Phys.* 2007;69:1502–8.
24. Yamada Y, Laufer I, Cox BW, et al. Preliminary results of high-dose single-fraction radiotherapy for the management of chordomas of the spine and sacrum. *Neurosurgery.* 2013;73:673–80.
25. Henderson FC, McCool K, Seigle J, et al. Treatment of chordomas with CyberKnife: georgetown university experience and treatment recommendations. *Neurosurgery.* 2009;64:A44–53.
26. Chen YL, Liebsch N, Kobayashi W, et al. Definitive high-dose photon/proton radiotherapy for unresected mobile spine and sacral chordomas. *Spine.* 2013;38:E930–6.
27. Wagner TD, Kobayashi W, Dean S, et al. Combination short-course preoperative irradiation, surgical resection, and reduced-field high-dose postoperative irradiation in the treatment of tumors involving the bone. *Int J Radiat Oncol Biol Phys.* 2009;73:259–66.
28. Rutz HP, Weber DC, Sugahara S, et al. Extracranial chordoma: outcome in patients treated with function-preserving surgery followed by spot-scanning proton beam irradiation. *Int J Radiat Oncol Biol Phys.* 2007;67:512–20.
29. Rombi B, Ares C, Hug EB, et al. Spot-scanning proton radiation therapy for pediatric chordoma and chondrosarcoma: clinical outcome of 26 patients treated at paul scherrer institute. *Int J Radiat Oncol Biol Phys.* 2013;86:578–84.
30. Staab A, Rutz HP, Ares C, et al. Spot-scanning-based proton therapy for extracranial chordoma. *Int J Radiat Oncol Biol Phys.* 2011;81:e489–96.
31. Nishida Y, Kamada T, Imai R, et al. Clinical outcome of sacral chordoma with carbon ion radiotherapy compared with surgery. *Int J Radiat Oncol Biol Phys.* 2011;79:110–6.
32. Verburg JM, Seco J. Dosimetric accuracy of proton therapy for chordoma patients with titanium implants. *Med Phys.* 2013;40:071727.
33. Bergh P, Kindblom LG, Gunterberg B, et al. Prognostic factors in chordoma of the sacrum and mobile spine: a study of 39 patients. *Cancer.* 2000;88:2122–34.

Submit your next manuscript to BioMed Central and we will help you at every step:

- We accept pre-submission inquiries
- Our selector tool helps you to find the most relevant journal
- We provide round the clock customer support
- Convenient online submission
- Thorough peer review
- Inclusion in PubMed and all major indexing services
- Maximum visibility for your research

Submit your manuscript at
www.biomedcentral.com/submit

