



HAL
open science

Late-onset Rasmussen Encephalitis: A literature appraisal

Sophie Dupont, Ana Gales, Serge Sammey, Marie Vidailhet, Virginie Lambrecq

► **To cite this version:**

Sophie Dupont, Ana Gales, Serge Sammey, Marie Vidailhet, Virginie Lambrecq. Late-onset Rasmussen Encephalitis: A literature appraisal. *Autoimmunity Reviews*, 2017, 10.1016/j.autrev.2017.05.022 . hal-01533367

HAL Id: hal-01533367

<https://hal.sorbonne-universite.fr/hal-01533367>

Submitted on 6 Jun 2017

HAL is a multi-disciplinary open access archive for the deposit and dissemination of scientific research documents, whether they are published or not. The documents may come from teaching and research institutions in France or abroad, or from public or private research centers.

L'archive ouverte pluridisciplinaire **HAL**, est destinée au dépôt et à la diffusion de documents scientifiques de niveau recherche, publiés ou non, émanant des établissements d'enseignement et de recherche français ou étrangers, des laboratoires publics ou privés.

Late-onset Rasmussen Encephalitis: A literature appraisal

Sophie Dupont^{a,b,c,d}; Ana Gales^a; Serge Sammei^b; Marie Vidailhet^e; Virginie Lambrecq^{a,c}

^a APHP Pitié-Salpêtrière-Charles-Foix, Epileptology Unit, Paris, France

^b APHP Pitié-Salpêtrière-Charles-Foix, Rehabilitation Unit, Paris, France

^c Brain and Spine Institute (INSERM UMRS1127, CNRS UMR7225, UPMC), Paris, France

^d Sorbonne University, UPMC Paris, France

^e APHP Pitié-Salpêtrière-Charles-Foix, Movement disorders Unit, Paris, France

Address correspondence to:

Pr S Dupont

Epileptology Unit

Pitié-Salpêtrière Hospital

47, boulevard de l'Hôpital

75013 Paris, France

Phone/FAX: (33) 1 42 16 03 01/1 42 16 03 03

E-mail : sophie.dupont@aphp.fr

Contents

1. Introduction
 2. Classical childhood-onset RE: a brief overview
 3. Classical childhood-onset RE: evidence for an underlying immune process
 4. Methods
 5. Results
 - 5.1 Results of the search
 - 5.2 RE diagnostic criteria
 - 5.3 Clinical data
 - 5.4 EEG findings
 - 5.5 Association with autoimmune markers or diseases
 - 5.6 MRI findings
 - 5.7 Anatomopathological examination
 - 5.8 Therapies and outcome
 6. Discussion
 - 6.1 Late-onset RE: a reality
 - 6.2 Late-onset RE: distinctive features
 - 6.3 Late onset RE: further arguments for an immunopathological basis
 - 6.3.1 Late-onset RE: arguments against an antibody mediated autoimmune encephalitis
 - 6.3.2 Late-onset RE: therapeutic insights for an autoimmune pathophysiology
 7. Conclusions
- Take-home messages
Disclosure of interests
Contribution to authorship
Ethics approval
Funding
Acknowledgements
References

Abstract

Rasmussen Encephalitis (RE) is classically described as a childhood encephalopathy due to a unilateral inflammation of the cerebral cortex with a presumed immune-mediated pathophysiological basis. Unusual variant forms, including adolescent and adult-onset RE have been described but there is still a doubt whether these atypical cases correspond to classical RE patients. To review evidence, a systematic PubMed search was conducted to retrieve papers addressing late onset RE to assess (i) the positivity rate of classical childhood-onset diagnostic criteria for RE in late-onset RE, (ii) the specific clinical and radiological features that could help earlier diagnosis and therapeutic interventions, (iii) the arguments for an autoimmune pathophysiology including (iiia) the association with autoimmune markers or diseases and (iiib) the effects of immunomodulatory or immunosuppressive treatments. A total of 50 papers were considered. We identified 102 late-onset RE patients with a sex ratio of 8 women for 2 men. 67% fulfilled the consensus diagnostic criteria for RE. As compared to classical RE, the late-onset RE patients exhibited: i) more frequent focal complex partial seizures, ii) less frequent epilepsy partialis continua throughout evolution, iii) a slower evolution with a delayed occurrence of cortical deficit, iv) less cognitive deterioration and v) a better outcome. A specific association with autoimmune markers or diseases was not found. Immunomodulatory therapies, even performed in a late stage, improved late-onset RE patients in 61% of cases. This review proves that late-onset RE is a reality with specific clinical and radiological features. The good response to immunomodulatory treatments brings further arguments for an immune-regulated process.

Key words: Rasmussen encephalitis, systematic review, late-onset Rasmussen encephalitis, seizures, immune-mediated disease

1. Introduction

Rasmussen's encephalitis (RE) is a rare chronic neurological disorder, characterised by pharmaco-resistant epilepsy, and progressive neurological and cognitive deterioration due to a unilateral inflammation of the cerebral cortex [1]. The progressive course of inflammation is consistent with an immune-mediated disease but no serological or intrathecal markers have been evidenced. European consensus diagnostic criteria have been proposed in 2005 [2]. Three cardinal criteria are required to diagnose RE (part A): 1) focal seizures and unilateral cortical deficit(s), 2) unilateral EEG abnormalities, and 3) unihemispheric MRI focal cortical atrophy with at least grey or white matter hyperintense signal and/or hyperintense signal or atrophy of the ipsilateral caudate head. If one of these criteria is missing, diagnosis may be made with two of the alternative following criteria (part B): 1) *Epilepsia partialis continua* (EPC) or progressive unilateral cortical deficit, 2) progressive unihemispheric cortical atrophy, and 3) histopathological properties of RE on brain biopsy. A specific age at onset has not been proposed as diagnostic criteria for RE. Nevertheless, RE is classically described as a childhood encephalopathy with an average age at disease manifestation of 6 years [3]. Unusual variant forms, including adolescent and adult-onset RE have been described [4,5] but there is still a doubt whether these atypical cases correspond to classical RE patients. In order to gain further insight into this issue, we analyzed currently available papers reporting late-onset RE to assess: (i) the positivity rate of classical childhood-onset diagnostic criteria for RE in late-onset RE, (ii) the specific clinical and radiological features that could help earlier diagnosis and therapeutic interventions, (iii) the arguments for an autoimmune pathophysiology including (iiia) the association with autoimmune markers or diseases and (iiib) the effects of immunomodulatory or immunosuppressive treatments.

2. Classical childhood-onset RE: a brief overview

RE is a rare disease with an estimated incidence of 2.4 cases/107 people aged 18 years and younger per year [6]. No sex or ethnic predominance has been reported. The median age of onset is 6 years. Clinically, RE is characterized by intractable focal onset seizures and deterioration of functions associated with the affected hemisphere. In children, three stages of the disease are identified: i) a prodromal stage with mild hemiparesis or infrequent seizures that might precede the acute stage by up to several years, ii) an acute stage marked by very frequent focal seizures arising from one cerebral hemisphere, mainly simple partial motor seizures and EPC in at least half of cases and iii) a residual stage with severe fixed motor and cognitive deficits, and persisting refractory epilepsy [1-3]. In average, children with RE reach the residual stage in less than one year. Exceptionally, seizures may miss, with at onset movement disorders followed by progressive neurological deficits or even though with only progressive unilateral neurological deficits [7]. Neuroimaging in RE is an integral piece of diagnostic data. Cerebral MRI may be not relevant at the prodromal stage or only show a non specific unilateral enlargement of the ventricular system. A T2/Flair hypersignal is usually observed in cortical or subcortical regions during the acute stage. With the evolution, serial MRIs will typically show progression of signal change with the observation in the residual stage of a progressive focal cortical (predominating in the perisylvian region) or subcortical atrophy [8]. Treatment is based on antiepileptic drugs (with a limited effect on seizures and deterioration) and on surgery at the residual stage consisting in a disconnection of the affected hemisphere. In view of the belief that Rasmussen's encephalitis is an immune-regulated process, immunosuppressive or immunomodulatory treatments have being anecdotally assessed in the acute stage with encouraging results.

3. Classical childhood-onset RE: evidence for an underlying immune process

In classical RE, multiple arguments are already in favour of an auto immune process: i) the oligoclonal granzyme B-mediated T-cell immunoreaction against neurons and astrocytes on brain tissue studies [9-10]; ii) the microglial and astroglial activation, iii) the overexpression of

functionally-related genes that code for interferon- γ , CCL5, CCL22-23, CXCL9-10, Fas ligand and that are related to the activation of helper and inducer, and memory and effector T cells [11], and iv) the presence of significant numbers of resident memory T cells (TRM cells) in RE brain [11]. A plausible scenario relates the presence of resident memory T cells (TRM) on brain RE tissue studies to an immune response that may precede the clinical presentation of RE, with in a second step, a local reactivation of TRM cells, possibly triggered by seizure-induced inflammation, recruiting antigen-experienced or newly primed T cells into the brain, and thus perpetuating a chronic inflammatory condition, and progressive destruction of brain tissue [11].

. 4. Methods

The study was performed according to the recommendations of the Preferred Reporting Items for Systematic Reviews and Meta-Analyses statement [12]. A systematic literature search was conducted using MEDLINE to identify all studies published up to May 2016. This review was based on a keyword search with the terms "adult-onset Rasmussen Encephalitis, adolescent-onset Rasmussen Encephalitis, late-onset Rasmussen Encephalitis " in Medline. The reference lists of retrieved studies were reviewed to search for additional reports of relevant studies.

Studies were selected when they met the following entry criteria: English language, case reports or series of RE patients aged ≥ 12 years. Given the non parametric data distribution, results were expressed in percentages values calculated on the available data or in mean \pm standard deviation and range.

5. Results

5.1 Results of the search

The search yielded 220 publications. Among these 220 publications, exclusion of encephalitis unrelated to RE and of RE beginning at childhood led us to select 50 publications (figure 1) [4, 5, 9, 13-59]. Among the 50 publications, we finally identified 102 late-onset RE patients with a sex ratio of 8 women for 2 men.

5.2 RE diagnostic criteria (table 1)

Diagnosis was based on: i) part A criteria in 13 patients (13%), ii) part B criteria in 55 patients (54%), iii) histopathological examination in 19 patients (19%) and iv) electroclinical criteria that did not fulfil the consensus criteria in 15 patients (13%). Finally, 67% of patients fulfilled the European consensus diagnostic criteria for RE and 33% did not.

5.3 Clinical data (supplemental table)

Pre-existing events were reported in 23% of patients and consisted in infectious episodes in 9%.

Early neurological and psychomotor development was normal in all patients.

Mean age at seizure onset was 24 years \pm 12 (range: 12-61).

Seizures were the first sign at disease onset in 94% of patients, only 6% had a motor or cognitive deficit before seizure onset.

Initial seizures consisted in complex partial seizures in 50%, in simple partial seizures in 34% and in generalized tonic-clonic seizures in 8%. 7% of patients exhibited initial EPC, 5% a focal cortical myoclonus at the beginning of the disease and 1% presented with initial generalized tonic-clonic status epilepticus.

Over time, focal seizures evolved into another type in 80% of patients. Late EPC was present in 31% of patients.

A neurological deficit was noticed in 95% of patients in average 3 years after the seizure onset.

Cognitive deterioration was noticed in 37% of patients.

5.4 EEG-findings

Unilateral EEG abnormalities, when detailed, consisted in focal spikes and focal slow waves.

5.5 Association with autoimmune markers or diseases

Laboratory findings were detailed in 23% of patients and revealed abnormal findings in 48%.

Laboratory abnormalities consisted in anti-DNA, extractable nuclear antibodies and anti-nucleus antibodies (9 patients, 27%), serum GluR3 antibodies (5 patients, 15%), anti MAG antibodies (one

patient, 3%) and IgA deficit (one patient, 3%). CSF examinations were detailed in 49% of patients and were either normal or revealed non specific presence of oligoclonal bands (11 patients, 21%), hyperproteinorachia (4 patients, 8%) or cells (2 patients, 4%). Presence of GluR3 antibodies was noticed in the CSF of 3 patients (6%). CMV was found in the CSF of one patient (2%) and cytoalbumino-dissociation in another one (2%).

5.6 MRI findings

First patients with a diagnosis of late-onset RE underwent CT-scan, cerebral angiogram or ventriculography procedures.

Early MRI was performed in 55% of patients and revealed a focal T2 hyperintensity in 33 (48% of the patients who underwent MRI). Localization of the T2 hypersignal was mostly temporal or frontal. T2 hyperintensity extended initially to the hemisphere in 4% of cases.

Consecutive MRI were detailed in 64% of patients and revealed in 97% unilateral focal or hemispheric atrophy that progressed over time (84%) or remained stable (16%).

5.7 Anatomopathological examination

Anatomopathological examination was performed in 75 patients (74%) and revealed: RE changes in 89% of patients (typical in 72%, compatible in 17%), atypical findings in 3 patients (4%, including one biopsy in a normal MRI region), and non specified findings in 5 patients (7%).

5.8 Therapies and outcome

Immunomodulation therapy, including intravenous immunoglobulins, plasmapheresis, and steroid therapy, was performed in 36 patients (35%) with overall a good response in 61%. Surgery was performed in 40 patients (39%): cortectomy in 87,5%, hemispherectomy in 7,5%, deafferentation or subpial transaction in 5% with excellent results. 22,5% were seizure free, 40% had a marked improvement and only 22,5% had no improvement.

Diverse alternative therapies were performed: antiviral drugs, immunosuppressive drugs including tacrolimus, thalamic stimulation, TMS, with variable results.

Overall, a good outcome was reported in 72% of patients with a seizure freedom in 29% and a consistent improvement in 43%. Stabilization was obtained in 12% and a worsening was noted in 16% with death in 2 patients.

6. Discussion

Rasmussen encephalitis is a debilitating neurological disorder that develops as a slow progressive encephalopathy over several months or years. Its diagnosis is well-codified in children, but its existence in adolescents and adults remains debated. This systematic literature review proves that the majority of chronic encephalitis reported as late-onset RE fulfils diagnostic criteria of childhood RE and brings further arguments for an immune-mediated disease.

6.1 Late-onset RE: a reality

67% of all the late-onset RE cases reported in the literature fulfil the European Consensus diagnostic criteria. Interestingly, the vast majority of these patients (77%) fulfil part B criteria requiring a prolonged follow-up and only 23% fulfil part A criteria allowing an early diagnosis. This illustrates the usual delay to diagnose RE in adolescents or adults.

6.2 Late-onset RE: distinctive features

Criteria suggesting late-onset RE are: i) classical focal lobe epilepsy evolving into a multifocal epilepsy, ii) delayed occurrence of neurological deficit and iii) delayed focal cortical atrophy. At the opposite, the absence of the following criteria should not rule out the diagnosis: i) EPC, ii) cognitive deterioration, and iii) MRI initial T2 hyperintensity (table 2).

The evolution of late-onset RE seems rather different: i) a prodromal stage was not clearly identified since late-onset RE frequently exhibited refractory seizures at onset and only 6% had a motor or cognitive deficit before seizure onset, ii) a slower evolution is observed with a

neurological cortical deficit appearing in average from 3 to 9 years after the seizure onset and iii) a more favourable outcome is noted with 72% of good outcome.

This slower evolution and these delayed deficits may represent a confounding factor for an early diagnosis. Nevertheless, even if the diagnosis is delayed in the vast majority of late-onset RE, the outcome seems more favourable than in classical cases. Response to immunomodulatory therapies appears promising with 61% of good results, suggesting that the duration of the immunologic component of the disease is perhaps longer than expected in adolescents or adults with RE.

Unexpectedly, surgery may be considered in adults, with excellent results in 62,5% of patients undergoing a focal resection. Alternative therapies including immunosuppressive therapies and deep brain stimulation remained anecdotal with heterogeneous results.

6.3 Late onset RE: further arguments for an immunopathological basis

6.3.1 Late-onset RE: arguments against an antibody mediated autoimmune encephalitis

In the past 10 years an increasing number of autoimmune encephalitis cases have been identified [60, 61]. Diagnostic criteria for possible autoimmune encephalitis have been proposed and do not really fit with late-onset RE cases. According to Graus et al. [60], diagnosis of autoimmune encephalitis can be made when all three of the following criteria have been met: 1) sub acute onset (less than 3 months) of working memory deficits, altered mental status, or psychiatric symptoms; 2) at least one of the following items: new focal CNS findings, seizures not explained by a previously known seizure disorder, CSF pleocytosis, MRI features suggestive of encephalitis; and 3) reasonable exclusion of alternative causes. Concerning the first criteria, only 37% of the late-onset RE reported in the literature developed overt cognitive deficit with a slow progression and without psychiatric symptoms. Concerning the second criteria, CFS pleocytosis is exceptional (only three late-onset RE patients), initial MRI T2 hyperintensity is missing in one half of patients and autoantibodies, when researched, are missing or not specific. Furthermore, in classical childhood

onset RE, autoantibodies, particularly to the GluA3 subtype of the alpha-amino-3-hydroxy-5-methyl-isoxazole-4-propionic acid receptor (AMPA) [62] or to alpha-7 nicotinic acetylcholine receptors (or Munc-18-1) [63], were initially reported but not further confirmed [64] and finally interpreted as neuro-inflammatory damage in this highly destructive disease. As opposed to well-known [65-68] or more recent [69] autoimmune diseases with neuropsychiatric symptoms and specific circulating antibodies [70], specific autoimmune biomarkers are still missing in late-onset RE, despite the development of new performing serological testing in autoimmune encephalitis [71].

6.3.2 Late-onset RE: therapeutic insights for an autoimmune pathophysiology

The effects of long-term immunotherapy for Rasmussen's encephalitis have ever been described in case reports or small, uncontrolled patient series. A recent prospective randomised trial assessed the effect of long-term immunotherapy with tacrolimus or intravenous immunoglobulins. The authors showed a delayed deterioration compared to untreated historical controls but a poor effect on seizure control [6]. Interestingly in late-onset RE, immunomodulation therapy, including intravenous immunoglobulins, plasmapheresis, and steroid therapy achieved an overall good response in both epilepsy and neurological deterioration in 61% of the patients bringing further arguments for an immune-regulated process.

7. Conclusions

Our study demonstrates that late-onset RE fulfilled childhood-onset diagnostic criteria and share common clinico-radiological features and evolution profile. Diagnosis clues are: i) more frequent complex partial seizures at onset, ii) less frequent EPC with evolution, iii) slower evolution with a delayed occurrence of the cortical deficit, iv) less cognitive deterioration, and v) a better outcome. These specific features may represent confounding factors for early diagnosis and therapeutic interventions. Nevertheless, the good response to immunomodulatory treatments, even performed in a late stage, brings arguments for an immune-regulated process. Promising therapeutic candidates could come from compounds reducing the likelihood of T-cell entry into the CNS.

Take-home messages

- 67% of late onset Rasmussen Encephalitis patients fulfil the consensus diagnostic criteria for RE
- Late onset RE exhibit a slower course and a better outcome
- A specific association with autoimmune markers or diseases is lacking
- Immunomodulatory therapies, even performed in a late stage, improved late-onset RE patients in 61% of cases.

Disclosure of interests

The authors have nothing to disclose.

Contribution to authorship

Sophie Dupont conceived the study, reviewed all studies and individual cases, made the statistical analysis, drafted and revised the manuscript.

Ana Gales provided clinical data and revised the manuscript.

Serge Sammey reviewed all studies.

Marie Vidailhet provided clinical data and revised the manuscript.

Virginie Lambrecq revised the manuscript.

Ethics approval

No ethics approval was required for this study.

Funding

No specific funding was obtained for this study.

Acknowledgements

The authors are grateful to Drs Oguni and N'Guyen-Michel for their valuable help in retrieving papers.

References

- [1] Varadkar S, Bien CG, Kruse CA, Jensen FE, Bauer J, Pardo CA, et al. Rasmussen's encephalitis: clinical features, pathobiology, and treatment advances. *Lancet Neurol* 2014;13:195–205.
- [2] Bien CG, Granata T, Antozzi C, Cross JH, Dulac O, Kurthen M, et al. Pathogenesis, diagnosis and treatment of Rasmussen encephalitis: a European consensus statement. *Brain* 2005;128:454–471.
- [3] Oguni H, Andermann F, Rasmussen TB. The natural history of the syndrome of chronic encephalitis and epilepsy: a study of the MNI series of forty-eight cases. In: Andermann F, editor. *Chronic encephalitis and epilepsy. Rasmussen's syndrome*. Boston: Butterworth-Heinemann 1991;p.7–35.
- [4] Hart YM, Andermann F, Fish DR, Dubeau F, Robitaille Y, Rasmussen T, et al. Chronic encephalitis and epilepsy in adults and adolescents: a variant of Rasmussen's syndrome? *Neurology* 1997;48:418-424.
- [5] Villani F, Pincherle A, Antozzi C, Chiapparini L, Granata T, Michelucci R, et al. Adult-onset Rasmussen's encephalitis: anatomical-electrographic-clinical features of 7 Italian cases. *Epilepsia* 2006;47(Suppl. 5):41–46.
- [6] Bien CG, Tiemeier H, Sassen R, Kuczaty S, Urbach H, von Lehe M, et al. Rasmussen encephalitis: incidence and course under randomized therapy with tacrolimus or intravenous immunoglobulins. *Epilepsia* 2013;54(3):543-50.
- [7] Bien CG, Elger CE, Leitner Y, Gomori M, Ran B, Urbach H, et al. Slowly progressive hemiparesis in childhood as a consequence of Rasmussen encephalitis without or with delayed-onset seizures. *Eur J Neurol* 2007;14:387–90.

- [8] Pradeep K, Sinha S, Saini J, Mahadevan A, Arivazhagan A, Bharath RD. Evolution of MRI changes in Rasmussen's encephalitis. *Acta Neurol Scand* 2014;130:253–259.
- [9] Bien CG, Widman G, Urbach H, Sassen R, Kucsaty S, Wiestler OD, et al. The natural history of Rasmussen's encephalitis. *Brain* 2002;125(Pt 8):1751-1759.
- [10] Schwab N, Bien CG, Waschbisch A, Becker A, Vince GH, Dornmair K, et al. CD8+ T cell clones dominate brain infiltrates in Rasmussen encephalitis and persist in the periphery. *Brain* 2009;132:1236–1246.
- [11] Owens GC, Huynh M, Chang JW, McArthur DL, Hickey MJ, Vinters HV, et al. Differential expression of Interferon- α and chemokines genes distinguishes Rasmussen encephalitis from cortical dysplasia and provides evidence for an early Th1 immune response. *J Neuroinflammation* 2013;10:56-68.
- [12] Moher D, Liberati A, Tetzlaff J, Altman DG, PRISMA Group. Preferred reporting items for systematic reviews and meta-analyses: the PRISMA statement. *PLoS Med* 2009;6:e1000097.
- [13] Gray F, Serdaru M, Baron H, Daumas-Duport C, Loron P, Sauron B, et al. Chronic localised encephalitis (Rasmussen's) in an adult with epilepsy partialis continua. *J Neurol Neurosurg Psychiatry* 1987;50(6):747-751.
- [14] Robitaille Y. Neuropathologic aspects of chronic encephalitis. In: Andermann F, editor. *Chronic encephalitis and epilepsy Rasmussen's syndrome*. Boston: Butterworth-Heinemann 1991;p.79–110.
- [15] Oguni H, Andermann F, Rasmussen TB. The syndrome of chronic encephalitis and epilepsy. A study based on the MNI series of 48 cases. *Adv Neurol* 1992;57:419-433.
- [16] McLachlan RS, Girvin JP, Blume WT, Reichman H. Rasmussen's chronic encephalitis in adults. *Arch Neurol* 1993;50(3):269-274.
- [17] Larner AJ, Smith SJ, Duncan JS, Howard RS. Late-onset Rasmussen's syndrome with first seizure during pregnancy. *Eur Neurol* 1995;35(3):172.

- [18] Krauss GL, Campbell ML, Roche KW, Haganir RL, Niedermeyer E. Chronic steroid-responsive encephalitis without autoantibodies to glutamate receptor GluR3. *Neurology* 1996;46(1):247-249.
- [19] Bhatjiwale MG, Polkey C, Cox TC, Dean A, Deasy N. Rasmussen's encephalitis: neuroimaging findings in 21 patients with a closer look at the basal ganglia. *Pediatr Neurosurg* 1998;29(3):142-148.
- [20] Leach JP, Chadwick DW, Miles JB, Hart IK. Improvement in adult-onset Rasmussen's encephalitis with long-term immunomodulatory therapy. *Neurology* 1999;52(4):738-742.
- [21] Vadlamudi L, Galton CJ, Jeavons SJ, Tannenberg AE, Boyle RS. Rasmussen's syndrome in a 54 year old female: more support for an adult variant. *J Clin Neurosci* 2000;7(2):154-156.
- [22] Vinjamuri S, Leach JP, Hart IK. Serial perfusion brain tomographic scans detect reversible focal ischaemia in Rasmussen's encephalitis. *Postgrad Med J* 2000;76(891):33-35.
- [23] Hennessy MJ, Koutroumanidis M, Dean AF, Jarosz J, Elwes RD, Binnie CD, et al. Chronic encephalitis and temporal lobe epilepsy: a variant of Rasmussen's syndrome? *Neurology* 2001;56(5):678-681.
- [24] Frucht S. Dystonia, athetosis and epilepsia partialis continua in a patient with late-onset Rasmussen's encephalitis. *Mov Disord* 2002;17(3):609-612.
- [25] Wennberg R, Nag S, McAndrews MP, Lozano AM, Farb R, Mikulis D. Chronic (Rasmussen's) encephalitis in an adult. *Can J Neurol Sci* 2003;30(3):263-265.
- [26] Hunter GRW, Donat J, Pryse-Phillips W, Harder S, Robinson CA. Rasmussen's Encephalitis in a 58-Year-Old Female: Still a Variant? *Can J Neurol Sci* 2006; 33:302-305.
- [27] Larionov S, König R, Urbach H, Sassen R, Elger CE, Bien CG. MRI brain volumetry in Rasmussen encephalitis: the fate of affected and "unaffected" hemispheres. *Neurolog* 2005;64(5):885-887.

- [28] Di Bonaventura C, Carnfi M, Vaudano AE, Panatano P, Garreffa G, Le Piane E, et al. Ictal hemodynamic changes in late-onset Rasmussen encephalitis. *Ann Neurol* 2006;59(2):432-433.
- [29] De Leva MF, Varrone A, Filla A, Quarantelli M, Piscitelli V, Salvatore E, et al. Neuroimaging follow-up in a case of Rasmussen's encephalitis with dyskinesias. *Mov Disord* 2007;22(14):2117-2121.
- [30] Gambardella A, Andermann F, Shorvon S, Le Piane E, Aguglia U. Limited chronic focal encephalitis: another variant of Rasmussen syndrome? *Neurology* 2008;70(5):374-377.
- [31] Fattouch J, Di Bonaventura C, Di Gennaro G, Quarato PP, Petrucci S, Manferdi M, et al. Electrical status epilepticus "invisible" to surface EEG in late-onset Rasmussen encephalitis. *Epileptic Disord* 2008;10(3):219-222.
- [32] Rotenberg A, Depositario-Cabacar D, Bae EH, Harini C, Pascual-Leone A, Takeoka M. Transient suppression of seizures by repetitive transcranial magnetic stimulation in a case of Rasmussen's encephalitis. *Epilepsy Behav* 2008;13(1):260-262.
- [33] Quesada CM, Urbach H, Elger CE, Bien CG. Rasmussen encephalitis with ipsilateral brain stem involvement in an adult patient. *J Neurol Neurosurg Psychiatry* 2007;78(2):200-201.
- [34] Tessonier L, Thomas P, Benisvy D, Chanalet S, Chaborel JP, Bussière F, et al. Perfusion SPECT findings in a suspected case of Rasmussen encephalitis. *J Neuroimaging* 2009;19(4):378-380.
- [35] Cheong JY, Wong C, Bleasel A, Varikatt W, Ng T, Dexter MA. Late onset Rasmussen's encephalitis with triple pathology. *J Clin Neurosci* 2009;16(12):1677-1681.
- [36] Takei H, Wilfong A, Malphrus A, Yoshor D, Hunter JV, Armstrong DML, et al. Dual pathology in Rasmussen's encephalitis: a study of seven cases and review of the literature. *Neuropathology* 2010;30(4):381-391.
- [37] Kashihara K, Ohno M, Takahashi Y. Twenty-one-year course of adult-onset Rasmussen's encephalitis and bilateral uveitis: case report. *J Neurol Sci* 2010;294(1-2):127-130.

- [38] Grujic J, Bien CG, Pollo C, Rossetti AO. Vagus nerve stimulator treatment in adult-onset Rasmussen's encephalitis. *Epilepsy Behav* 2011;20(1):123-125.
- [39] San-Juan D, Calcáneo Jde D, González-Aragón MF, Bermudez Maldonado L, Avellan AM, Argumosa EV, et al. Transcranial direct current stimulation in adolescent and adult Rasmussen's encephalitis. *Epilepsy Behav* 2011;20(1):126-131.
- [40] Abd-El-Barr MM, Wu B, Rahman M, Yachnis AT, Roper SN, Eisenschenk S. Atypical Rasmussen's encephalitis treated with temporal lobectomy. *J Clin Neurosci* 2011;18(2):287-290.
- [41] McLachlan RS, Diosy D, Levin S. Early treatment of a progressive Rasmussen's like syndrome with ganciclovir. *Can J Neurol Sci* 2011;38(2):296-298.
- [42] Irislimane M, Guilbert F, Leroux JM, Carmant L, Nguyen DK. Serial MR imaging of adult-onset Rasmussen's encephalitis. *Can J Neurol Sci* 2011;38(1):141-142.
- [43] Schramm J, Delev D, Wagner J, Elger CE, von Lehe M. Seizure outcome, functional outcome, and quality of life after hemispherectomy in adults. *Acta Neurochir (Wien)* 2012;154(9):1603-1612.
- [44] Benavente E, Paira S, Roverano S, Saredo G. Encephalitis and status epilepticus in a patient with systemic lupus erythematosus. *Reumatologia Clinica* 2013;9(2):123-127.
- [45] Caraballo RH, Fortini S, Cersósimo R, Monges S, Pasteris MC, Gomez M, et al. Rasmussen syndrome: an Argentinean experience in 32 patients. *Seizure* 2013;22(5):360-367.
- [46] Peariso K, Standridge SM, Hallinan BE, Leach JL, Miles L, Mangano FT, et al. Presentation, diagnosis and treatment of bilateral Rasmussen's encephalitis in a 12-year-old female. *Epileptic Disord* 2013;15(3):324-332.

- [47] Dawodu CO, Akinbo DD. Rasmussen's encephalitis. *Niger J Clin Pract* 2013;16(1):113-115.
- [48] Cosgrove J, Busby M. Hemiatrophy and seizures: a case of adult-onset Rasmussen encephalitis. *Pract Neurol* 2013;13(1):54-5.
- [49] Casciato S, Di Bonaventura C, Fattouch J, Lapenta L, Di Gennaro G, Quarato PP, et al. Extrarolandic electroclinical findings in the evolution of adult-onset Rasmussen's encephalitis. *Epilepsy Behav* 2013;28(3):467-473.
- [50] Rizek P, Cheung C, McLachlan RS, Hayman-Abello B, Lee DH, Hammond RR, et al. Childhood-onset nonprogressive chronic encephalitis. *Epilepsy Behav* 2014;31:85-90.
- [51] Iodice F, Luigetti M, Colosimo C, Servidei S, Mirabella M. Rasmussen encephalitis: an unusual cause for intractable seizures in elderly. *Neurol Sci* 2014;35(1):143-145.
- [52] Villani F, Didato G, Deleo F, Tringali G, Garbelli R, Granata T, et al. Long-term outcome after limited cortical resections in two cases of adult-onset Rasmussen encephalitis. *Epilepsia* 2014 ;55(5):38-43.
- [53] Amrom D, Kinay D, Hart Y, Berkovic SF, Laxer K, Andermann F, et al. Rasmussen encephalitis and comorbid autoimmune diseases: a window into disease mechanism? *Neurology* 2014;83(12):1049-1055.
- [54] Kumar S, Ahmed S, Ayub S, Motiwala FB, Ahmed N, Ahmed V, et al. Rasmussen's encephalitis: a case report. *J Neurol Disord* 2014; 2:145.
- [55] Vimal J, Nagarajan R, Sriram D. Rasmussen's encephalitis: a case report. *Australas Med J* 2015;8(3):80-84.
- [56] Poloni TE, Galli A, Pichiecchio A, di Lodovico L, Ceroni M. Good outcome in adult-onset Rasmussen's encephalitis syndrome: is recovery possible? *Epileptic Disord* 2015;17(2):204-208.

- [57] Ravindra VM, Mazur MD, Mohila CA, Sweney MT, Hersh A, Bollo RJ. Rasmussen encephalitis with dual pathology in a patient without seizures: case report and literature review. *Childs Nerv Syst* 2015;31(11):2165-2171.
- [58] Sanfilippo C, Giuliano L, Fatuzzo D, Sortino G, Le Pira F, Sofia V, et al. Late onset Rasmussen encephalitis: complete remission after one session of plasmapheresis. *Eur J Neurol* 2016;23(3):15-16.
- [59] Pradeep K, Sinha S, Mahadevan A, Saini J, Arivazhagan A, Bharath RD, et al. Clinical, electrophysiological, imaging, pathological and therapeutic observations among 18 patients with Rasmussen's encephalitis. *J Clin Neurosci* 2016;25:96-104.
- [60] Graus F, Titulaer MJ, Balu R, Benseler S, Bien CG, Cellucci T, et al. A clinical approach to diagnosis of autoimmune encephalitis. *Lancet Neurol* 2016;15(4):391-404.
- [61] van Sonderen A, Schreurs MW, Wirtz PW, Sillevs Smitt PA, Titulaer MJ. From VGKC to LGI1 and Caspr2 encephalitis: the evolution of a disease entity over time. *Autoimmun Rev* 2016;15(10):970-974.
- [62] Rogers SW, Andrews PI, Gahring LC, Whisenand T, Cauley K, Crain B, et al. Autoantibodies to glutamate receptor GluR3 in Rasmussen's encephalitis. *Science* 1994;265:648-651.
- [63] Yang R, Puranam RS, Butler LS, Qian WH, He XP, Moyer MB, et al. Autoimmunity to munc-18 in Rasmussen's encephalitis. *Neuron* 2000; 28:375-83.
- [64] Watson R, Jiang Y, Bermudez I, Houlihan N, Clover L, McKnight K, et al. Absence of antibodies to glutamate receptor type 3 (GluR3) in Rasmussen encephalitis. *Neurology* 2004;63(43):43-50.
- [65] Ho RC, Thiaghu C, Ong H, Lu Y, Ho CS, Tam WW, Zhang MW. A meta-analysis of serum and cerebrospinal fluid autoantibodies in neuropsychiatric systemic lupus erythematosus. *Autoimmun Rev* 2016;15(2):124-138.

- [66] Shimizu Y, Yasuda S, Kako Y, Nakagawa S, Kanda M, Hisada R, et al. Post-steroid neuropsychiatric manifestations are significantly more frequent in SLE compared with other systemic autoimmune diseases and predict better prognosis compared with de novo neuropsychiatric SLE. *Autoimmun Rev* 2016;15(8):786-794.
- [67] Bernard C, Frih H, Pasquet F, Kerever S, Jamilloux Y, Tronc F, et al. Thymoma associated with autoimmune diseases: 85 cases and literature review. *Autoimmun Rev* 2016;15(1):82-92.
- [68] Montagna G, Imperiali M, Agazzi P, D'Aurizio F, Tozzoli R, Feldt-Rasmussen U, et al. Hashimoto's encephalopathy: A rare proteiform disorder. *Autoimmun Rev* 2016;15(5):466-476.
- [69] Laurent C, Capron J, Quillerou B, Thomas G, Alamowitch S, Fain O, et al. Steroid-responsive encephalopathy associated with autoimmune thyroiditis (SREAT): Characteristics, treatment and outcome in 251 cases from the literature. *Autoimmun Rev* 2016;15(12):1129-1133.
- [70] Tay SH, Fairhurst AM, Mak A. Clinical utility of circulating anti-N-methyl-D-aspartate receptor subunits NR2A/B antibody for the diagnosis of neuropsychiatric syndromes in systemic lupus erythematosus and Sjögren's syndrome: an updated meta-analysis. *Autoimmun Rev* 2017;16(2):114-122.
- [71] Fraune J, Gerlach S, Rentzsch K, Teegen B, Lederer S, Affeldt K, et al. Multiparametric serological testing in autoimmune encephalitis using computer-aided immunofluorescence microscopy (CAIFM). *Autoimmun Rev* 2016;15(10):937-42.

Table legends

Table 1 : RE diagnosis according to European consensus diagnostic criteria

Table 2 : Comparison of late-onset and classical RE patients

Figure legends

Figure 1: Flow diagram of systematic review

ACCEPTED MANUSCRIPT

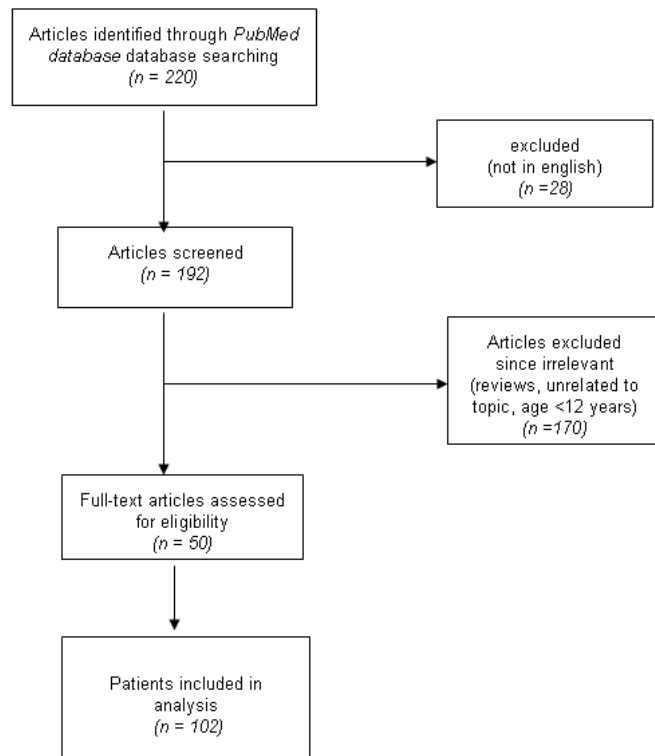


Figure 1 Flow diagram of systematic review

ACCEPTED

Table 1 : RE diagnosis according to European consensus diagnostic criteria ²

	Gray et al. 1987	Robitaille 1991	Oguni et al. 1992	McLachlan et al. 1993	Larner et al. 1995	Kraus et al. 1996	Hart et al. 1997	Bhatjwale et al. 1998	Leach et al. 1999	Vadlamudi et al. 2000	Vinjamuri et al. 2000	Hennessy et al. 2001	Frucht 2002	Bien et al. 2002	Wennberg et al. 2003	Larionov et al. 2005	Hunter et al. 2006	Villani et al. 2006	Di bonaventura et al. 2007	DeLeva et al. 2007	Gambardella et al. 2008	Fattouch et al. 2008	Rotenberg et al. 2008	Quesada et al. 2009	Tessonnier et al. 2009	Cheong et al. 2009	Takei et al. 2010	Kashihara et al. 2010	Grujic et al. 2011	San-Juan et al. 2011	Abd-El-Barr et al. 2011	McLachlan et al. 2011		
Diagnosis on part A criteria									*		*							*	*				*	*					*					
Diagnosis on part B criteria	*		*	*	*	*	*		*	*			*	*			*				*	*		*	*	*	*		*	*	*			
Diagnosis on histopathology							*				*			*	*																	*		
Diagnosis with missing criteria		*					*												*								*						*	

* one patient

Table 1 (continued)

	Irislimane et al.2011	Schramm et al.2012	Caraballo et al.2013	Benavente et al. 2013	Dawodu et al.2013	Peariso et al.2013	Cosgrove et al.2013	Casciato et al.2013	Rizek et al.2014	Iodice et al.2014	Villani et al.2014	Amrom et al.2014	Kumar et al.2014	Vimal et al.2015	Poloni et al.2015	Ravindra et al.2015	Sanfilippo et al.2016	Pradeep et al.2016
Diagnosis on part A criteria														✱			✱	
Diagnosis on part B criteria	✱			✱		✱	✱	✱		✱						✱		
Diagnosis on histopathology									✱		✱	✱						
Diagnosis with missing criteria		✱	✱		✱								✱		✱			✱

Table 2 Summary of findings concerning late-onset RE and classical RE patients

	late-onset RE (systematic review)	classical RE (1-3)
n	102	childhood cases
sex	women :79%	no sex ratio
affected side	equally both sides	equally both sides
preexisting event	23%	50% of cases*
early development	normal	normal
median age at epilepsy onset	24 years±12	6 years
seizures type at onset	mostly CPS and motor SPS	mostly motor SPS
delay between sz & deficit onset	3 years	very rare CPS
neurological deficit	95%	several month-1 year
cognitive deterioration	37%	100%
seizures at evolution	multifocal sz	yes
EPC	31%	multifocal sz
evolution stages	2 stages (acute, residual) within 3 years	56-92%
EEG	unilateral slow abnormalities	3 stages (prodromal, acute, residual) within one year
comorbid autoimmune disease	48%	unilateral slow abnormalities
CSF	non specific	not known
MRI initial white matter hyperintensity	48%	non specific
MRI late atrophy	97%	100%
MRI evolution	slow hemispheric atrophy or atrophy stabilization	100%
cerebral biopsy	74%	slow hemispheric atrophy or atrophy stabilization
treatment		T-cell-dominated encephalitis with activated microglial cells
response to AEDs	refractory	refractory
response to immunomodulatory therapy	efficacy in 61%	early efficacy
surgery	good response to focal surgery	variable results to hemispherectomy or deafferentation

history of upper respiratory tract infection, otitis media or tonsillitis which precedes the seizures by about 6 months
y=years, FC= febrile convulsion, HP= hyperproteinorachia, OCB=oligoclonal bands, FSW = focal slow waves, FS= focal spikes, sz=seizure, nd=not done, SPS=simple partial seizures, CPS= complex partial seizures, GTCS=generalized tonic-clonic seizures