



**HAL**  
open science

## Enterocytozoon bienewsi Microsporidiosis in Stem Cell Transplant Recipients Treated with Fumagillin

Iryna Bukreyeva, Adela Angoulvant, Inès Bendib, Jean-Charles Gagnard, Jean-Henri Bourhis, Sylvie Dargère, Julie Bonhomme, Marc Thellier, Bertrand Gachot, Benjamin Wyplosz

► **To cite this version:**

Iryna Bukreyeva, Adela Angoulvant, Inès Bendib, Jean-Charles Gagnard, Jean-Henri Bourhis, et al.. Enterocytozoon bienewsi Microsporidiosis in Stem Cell Transplant Recipients Treated with Fumagillin. Emerging Infectious Diseases, 2017, 23 (6), pp.1039-1041. 10.3201/eid2306.161825 . hal-01541632

**HAL Id: hal-01541632**

**<https://hal.sorbonne-universite.fr/hal-01541632>**

Submitted on 19 Jun 2017

**HAL** is a multi-disciplinary open access archive for the deposit and dissemination of scientific research documents, whether they are published or not. The documents may come from teaching and research institutions in France or abroad, or from public or private research centers.

L'archive ouverte pluridisciplinaire **HAL**, est destinée au dépôt et à la diffusion de documents scientifiques de niveau recherche, publiés ou non, émanant des établissements d'enseignement et de recherche français ou étrangers, des laboratoires publics ou privés.



Distributed under a Creative Commons Attribution 4.0 International License

# ***Enterocytozoon bienewsi* Microsporidiosis in Stem Cell Transplant Recipients Treated with Fumagillin<sup>1</sup>**

**Iryna Bukreyeva, Adela Angoulvant, Inès Bendib, Jean-Charles Gagnard, Jean-Henri Bourhis, Sylvie Dargère, Julie Bonhomme, Marc Thellier, Bertrand Gachot, Benjamin Wyplosz**

Author affiliations: Centre Hospitalier Universitaire de Bicêtre, Le Kremlin-Bicêtre, France (I. Bukreyeva, A. Angoulvant, I. Bendib, J.-C. Gagnard, B. Wyplosz); Université Paris-Sud, Le Moulon, France (A. Angoulvant); Institut Gustave Roussy, Villejuif, France (J.-H. Bourhis, B. Gachot); Centre Hospitalier Universitaire de Caen, Caen, France (S. Dargère, J. Bonhomme); Centre Hospitalier Universitaire Pitié-Salpêtrière, Paris, France (M. Thellier); Université Pierre et Marie Curie, Paris (M. Thellier)

DOI: <https://dx.doi.org/10.3201/eid2306.161825>

*Enterocytozoon bienewsi* microsporidiosis is an emerging disease in immunocompromised patients. We report 2 cases of this disease in allogeneic hematopoietic stem cell transplant patients successfully treated with fumagillin. Thrombocytopenia occurred but without major adverse events. Modifications of immunosuppression could be avoided when *E. bienewsi* is rapidly identified and fumagillin therapy is started promptly.

*Enterocytozoon bienewsi*, the most common cause of microsporidiosis in humans (1), causes chronic diarrhea and severe wasting syndrome in immunocompromised patients (2). In 2002, oral fumagillin was established as an effective treatment for *E. bienewsi* microsporidiosis in HIV-infected and solid organ transplant (SOT) patients (3). In contrast to previous treatments that did not result in parasitologic clearance or clinical remission, fumagillin showed a cure rate of 100%, even for severely immunocompromised patients (2,4–10).

Thrombocytopenia is the main adverse event of fumagillin therapy, occurring in up to 33% of patients (3) and raising concerns about fumagillin use in patients with hematologic disorders. We report 2 cases of *E. bienewsi* microsporidiosis in allogeneic hematopoietic stem cell transplant (HSCT) recipients who were treated with fumagillin and experienced thrombocytopenia.

Patient 1 was a 50-year-old woman admitted to Centre Hospitalier Universitaire de Caen (Caen, France) after

profuse watery diarrhea and abdominal discomfort for 3 weeks. She had not traveled abroad. Three years earlier, she received a genotypical allogeneic HSCT for myeloid leukemia. She recently had cutaneous chronic graft-versus-host disease. Her immunosuppression regimen used was prednisone and mycophenolate mofetil.

At admission, the patient was dehydrated and had a weight loss of 3 kg. Laboratory analyses showed lymphocytopenia (960 lymphocytes/mm<sup>3</sup>), reference neutrophil (5,100 cells/mm<sup>3</sup>) and platelet (408,000 platelets/mm<sup>3</sup>) counts, and a C-reactive protein level <5 mg/L.

Results of fecal sample analyses were negative for pathogenic bacteria and viruses. Microscopic examination of fecal smears stained with Weber-Green–modified trichrome showed microsporidia. *E. bienewsi* was identified by using monoclonal antibodies (IFA-MAbs; Bordier Affinity Products, Crissier, Switzerland).

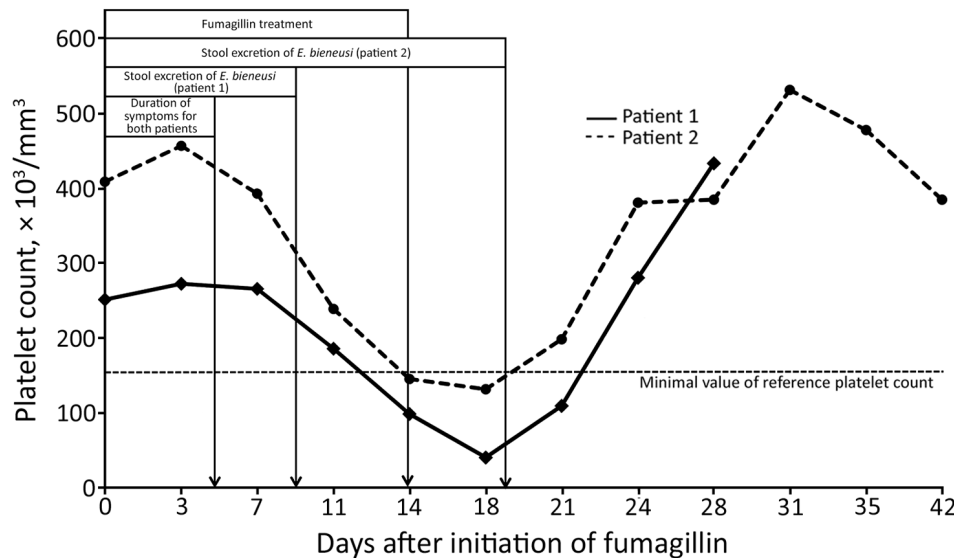
The mycophenolate mofetil dose was reduced by 50% for 8 days but no benefit was shown. Resolution of symptoms occurred ≤5 days after initiating fumagillin therapy (60 mg/d for 14 d); fecal smears were negative for microsporidia on day 9, and transient thrombocytopenia (131,000 platelets/mm<sup>3</sup>) was observed on day 18 (Figure). Fecal smears remained negative for *E. bienewsi* during the 6-month follow-up. No clinical relapse occurred.

Patient 2 was a 42-year-old man referred to Centre Hospitalier Universitaire de Bicêtre (Le Kremlin-Bicêtre, France) after profuse acute diarrhea for 2 weeks and a weight loss of 10 kg. He had not traveled abroad. Four years earlier, he received a genotypical allogeneic HSCT for acute leukemia. During the follow-up period, he was given a diagnosis of chronic graft-versus-host disease. He was given extracorporeal phototherapy with mycophenolate mofetil, sirolimus, and prednisolone.

At admission, the patient was afebrile and dehydrated. Blood analyses showed severe lymphocytopenia (400 lymphocytes/mm<sup>3</sup>), reference neutrophil (4,680 cells/mm<sup>3</sup>) and platelet (251,000 platelets/mm<sup>3</sup>) counts, and a C-reactive protein level <5 mg/L. Results of microbiological analyses of fecal samples were negative for viruses and pathogenic bacteria. Microscopic examination of fecal smears stained with Weber-Green–modified trichrome showed microsporidia. *E. bienewsi* was identified by using monoclonal antibodies.

The patient was treated with fumagillin (60 mg/d for 14 d) (Figure). Immunosuppressive therapy was not modified. Clinical symptoms resolved within 5 days. Platelet counts progressively decreased. Fumagillin was withdrawn on day 14, but thrombocytopenia worsened (40,000 platelets/mm<sup>3</sup>) by day 18. However, the patient spontaneously recovered in 10 days without any bleeding. No relapses were observed. Microsporidia were not detected in fecal samples during the 6-month follow-up.

<sup>1</sup>Results from this study were presented at the 26th European Congress of Clinical Microbiology and Infection Diseases; April 9–12, 2016; Amsterdam, the Netherlands.



**Figure.** Platelet counts and clinical and parasitologic characteristics during fumagillin therapy and a 1-month follow-up of 2 allogeneic hematopoietic stem cell recipients with *Enterocytozoon bienewsi* microsporidiosis.

*E. bienewsi* is an emerging pathogen in immunocompromised patients (1). Increasing numbers of cases have been reported in SOT patients. We report 2 cases of *E. bienewsi* microsporidiosis in allogeneic HSCT recipients who were treated with fumagillin without modifying the immunosuppressive regimen for 1 recipient. In France, fumagillin can be obtained from the French National Agency for Medicines and Health Products Safety (Saint-Denis, France) after an individual patient expanded-access request is submitted.

Clinical and microbiological responses for the 2 case-patients were similar to those reported for other immunocompromised patients (3). No relapses were observed for 4 HIV-infected patients whose CD4 cell counts remained low, or for 2 SOT recipients who did not receive tapering immunosuppressive therapy (3). In other studies, 15 (70%) of 21 patients treated with fumagillin were cured without modifying immunosuppression regimens (2,6,10); for 6 other patients, immunosuppressive therapy was tapered (n = 4) or withdrawn (n = 2), but reasons for modifying immunosuppression were not specified. For 1 of our patients, the mycophenolate mofetil dose was reduced by 50% to decrease the immunosuppression level. However, no benefit was observed. In contrast, fumagillin led to clinical remission within 5 days.

We observed thrombocytopenia (platelet count <40,000/mm<sup>3</sup>) in both patients but no evidence of bleeding. In other non-AIDS patients, thrombocytopenia was reported in 11 (52%) SOT patients receiving fumagillin, including 4 patients with severely low platelet counts (<25,000/mm<sup>3</sup>) (1,4,6). For these patients, including those we report, thrombocytopenia occurred during the second week of treatment; a minimum value was observed a few days after completing fumagillin therapy. Spontaneous recovery occurred within 2 weeks. Bleeding, hematoma, or requirements for platelet transfusions were not reported. For both

patients we report, microsporidia were not detected in fecal samples of both patients during the 6-month follow-up.

In conclusion, fumagillin was highly efficient in curing *E. bienewsi* microsporidiosis in 2 allogeneic HSCT recipients. Thrombocytopenia occurred but without major adverse events. Modifications to immunosuppression could be avoided when *E. bienewsi* is rapidly identified and fumagillin therapy is started promptly.

Dr. Bukreyeva is a physician in the Infectious and Tropical Diseases Unit at the Bicêtre University Hospital, Kremlin-Bicêtre, France. Her research interests include prevention and treatment of infections in immunocompromised patients.

## References

- Didier ES, Weiss LM. Microsporidiosis: current status. *Curr Opin Infect Dis.* 2006;19:485–92. <http://dx.doi.org/10.1097/01.qco.0000244055.46382.23>
- Lanternier F, Boutboul D, Menotti J, Chandesris MO, Sarfati C, Mamzer Bruneel MF, et al. Microsporidiosis in solid organ transplant recipients: two *Enterocytozoon bienewsi* cases and review. *Transpl Infect Dis.* 2009;11:83–8. <http://dx.doi.org/10.1111/j.1399-3062.2008.00347.x>
- Molina JM, Tourneur M, Sarfati C, Chevret S, de Gouvello A, Gobert JG, et al.; Agence Nationale de Recherches sur le SIDA 090 Study Group. Fumagillin treatment of intestinal microsporidiosis. *N Engl J Med.* 2002;346:1963–9. <http://dx.doi.org/10.1056/NEJMoa012924>
- Desoubreaux G, Maakaroun-Vermeze Z, Lier C, Bailly E, Morio F, Labarthe F, et al. Successful treatment with fumagillin of the first pediatric case of digestive microsporidiosis in a liver-kidney transplant. *Transpl Infect Dis.* 2013;15:E250–9. <http://dx.doi.org/10.1111/tid.12158>
- Pomares C, Santin M, Miegerville M, Espern A, Albano L, Marty P, et al. A new and highly divergent *Enterocytozoon bienewsi* genotype isolated from a renal transplant recipient. *J Clin Microbiol.* 2012;50:2176–8. <http://dx.doi.org/10.1128/JCM.06791-11>
- Godron A, Accoceberry I, Couret A, Llanas B, Harambat J. Intestinal microsporidiosis due to *Enterocytozoon bienewsi* in

- a pediatric kidney transplant recipient successfully treated with fumagillin. *Transplantation*. 2013;96:e66–7. <http://dx.doi.org/10.1097/TP.0b013e3182a902e7>
7. Kicia M, Wesolowska M, Jakuszko K, Kopacz Z, Sak B, Kvétonova D, et al. Concurrent infection of the urinary tract with *Encephalitozoon cuniculi* and *Enterocytozoon bieneusi* in a renal transplant recipient. *J Clin Microbiol*. 2014;52:1780–2. <http://dx.doi.org/10.1128/JCM.03328-13>
  8. Ghoshal U, Khanduja S, Pant P, Prasad KN, Dhole TN, Sharma RK, et al. Intestinal microsporidiosis in renal transplant recipients: prevalence, predictors of occurrence and genetic characterization. *Indian J Med Microbiol*. 2015;33:357–63. <http://dx.doi.org/10.4103/0255-0857.158551>
  9. Bednarska M, Bajer A, Welc-Faleciak R, Czubkowski P, Teisseyre M, Graczyk TK, et al. The first case of *Enterocytozoon bieneusi* infection in Poland. *Ann Agric Environ Med*. 2013; 20:287–8.
  10. Champion L, Durrbach A, Lang P, Delahousse M, Chauvet C, Sarfati C, et al. Fumagillin for treatment of intestinal microsporidiosis in renal transplant recipients. *Am J Transplant*. 2010;10:1925–30. <http://dx.doi.org/10.1111/j.1600-6143.2010.03166.x>

---

Address for correspondence: Benjamin Wyplosz, Service de Maladies Infectieuses et Tropicales, Centre Hospitalier Universitaire de Bicêtre, 78 Rue du Général Leclerc, 94275 Le Kremlin-Bicêtre, France; email: benjamin.wyplosz@aphp.fr

---

## Influenza A(H9N2) Virus, Myanmar, 2014–2015

**Thant Nyi Lin, Nutthawan Nonthabenjawan, Supassama Chaiyawong, Napawan Bunpapong, Supanat Boonyapisitsopa, Taveesak Janetanakit, Pont Pont Mon, Hla Hla Mon, Kyaw Naing Oo, Sandi Myint Oo, Mar Mar Win, Alongkorn Amonsin**

Author affiliations: Chulalongkorn University, Bangkok, Thailand (T.N. Lin, N. Nonthabenjawan, S. Chaiyawong, N. Bunpapong, S. Boonyapisitsopa, T. Janetanakit, A. Amonsin); University of Veterinary Science, Nay Pyi Taw, Myanmar (T.N. Lin, S.M Oo, M.M. Win); Ministry of Agriculture, Livestock and Irrigation, Insein, Yangon, Myanmar (P.P. Mon); Ministry of Agriculture, Livestock and Irrigation, Sintgaing, Mandalay, Myanmar (H.H. Mon); Ministry of Agriculture, Livestock and Irrigation, Nay Pyi Taw (K.N. Oo)

DOI: <https://dx.doi.org/10.3201/eid2306.161902>

Routine surveillance of influenza A virus was conducted in Myanmar during 2014–2015. Influenza A(H9N2) virus was isolated in Shan State, upper Myanmar. Whole-genome sequencing showed that H9N2 virus from Myanmar was closely related to H9N2 virus of clade 4.2.5 from China.

Influenza A(H9N2) virus has been found in several avian species. Despite low pathogenicity in poultry, H9N2 viruses are important to public health because of their high adaptability and frequent infection in humans. Clinical cases of H9N2 human infection have been reported in China (including Hong Kong) and Bangladesh (1,2). H9N2 viruses are constantly evolving and can reassort with other influenza A virus subtypes, resulting in novel influenza viruses. H9N2 was the likely donor of internal genes for the H5N1, H7N9, and H10N8 viruses (3,4).

During December 2014–August 2015, we conducted an influenza A surveillance program in Shan State, Myanmar. An outbreak of highly infectious avian influenza A(H5N1) in November 2007 has been the only outbreak reported in this state. For this study, we collected 648 samples from live-bird markets (LBMs) in Muse, Namkham, Laukkai, and Chinshwehaw, Shan State townships on the China–Myanmar border (online Technical Appendix 1, <https://wwwnc.cdc.gov/EID/article/23/6/16-1902-Techapp1.pdf>). We collected oropharyngeal swab specimens from chickens (n = 273) and ducks (n = 180) as well as environmental samples (n = 195). Identification and isolation were performed at the Livestock Breeding and Veterinary Department, Yangon, Myanmar (online Technical Appendix).

Of the 648 samples subjected to virus isolation by egg inoculation, 10 were hemagglutinin (HA) positive. We further confirmed 3 samples as influenza A virus by using real-time reverse transcription PCR (RT-PCR), and we subtyped and confirmed all 3 as H9N2 (online Technical Appendix Table 1). However, the overall occurrence of H9N2 in the LBMs in this study was relatively low. The 3 H9N2 isolates, A/chicken/Myanmar/NK-2/2015(H9N2), A/chicken/Myanmar/NK-4/2015(H9N2), and A/chicken/Myanmar/NK-5/2015(H9N2), were from chickens in LBMs in Namkham Township in June 2015.

To characterize the Myanmar H9N2 virus, we performed whole-genome sequencing of these 3 isolates and submitted nucleotide sequences GenBank (accession nos. KY115364–KY115387). Although an international standard for clade nomenclature of the H9 subtype has not been well established, phylogenetic analysis showed that all 3 Myanmar H9N2 isolates were grouped into clade 4.2.5 (HA gene) and BJ94-like (neuraminidase [NA] gene) (Figure; and online Technical Appendix Figure 2) (5). The Myanmar H9N2 viruses clustered with avian and human H9N2 virus recovered in China in 2015. The phylogenetic analyses of internal protein genes showed similar findings; the Myanmar H9N2 viruses were also closely related to avian H9N2 viruses from China. Five internal protein genes, polymerase basic protein 2 (PB2), polymerase basic protein 1 (PB1), polymerase acidic protein (PA), nucleoprotein (NP), and membrane protein (M), were grouped with the viruses of G1 lineage, and the nonstructural (NS)