



**HAL**  
open science

# An uncommon case of symptomatic multiple meningiomas with bilateral compressive optic neuropathy rapidly induced under cyproterone acetate treatment

Chafik Keilani, Samir Abada

► **To cite this version:**

Chafik Keilani, Samir Abada. An uncommon case of symptomatic multiple meningiomas with bilateral compressive optic neuropathy rapidly induced under cyproterone acetate treatment. *Current Drug Safety*, 2017, 12, 10.2174/1574886312666170523154548 . hal-01547079

**HAL Id: hal-01547079**

**<https://hal.sorbonne-universite.fr/hal-01547079>**

Submitted on 26 Jun 2017

**HAL** is a multi-disciplinary open access archive for the deposit and dissemination of scientific research documents, whether they are published or not. The documents may come from teaching and research institutions in France or abroad, or from public or private research centers.

L'archive ouverte pluridisciplinaire **HAL**, est destinée au dépôt et à la diffusion de documents scientifiques de niveau recherche, publiés ou non, émanant des établissements d'enseignement et de recherche français ou étrangers, des laboratoires publics ou privés.

**An Uncommon Case of Symptomatic Multiple Meningiomas  
with Bilateral Compressive Optic Neuropathy Rapidly  
Induced Under Cyproterone Acetate Treatment**

KEILANI C (1), ABADA S (2)

(1) Department of Ophthalmology IV, Centre Hospitalier National d'Ophtalmologie (CHNO) des Quinze-Vingts, Faculty of Medicine Pierre et Marie Curie (Paris VI), 28 Rue de Charenton, 75 571 Paris, France

(2) Department of Ophthalmology, Hôpital François Quesnay, 2 boulevard Sully, 78201 Mantes-la-Jolie CEDEX, France

## **ABSTRACT**

Multiple meningiomas growth in patients under cyproterone acetate (CPA) is now well known. However, time between initial CPA intake and diagnosis remains unclear. The exposure time differs in each reported case: from 2 to 10 years. We present the case of an old man with acute visual impairment caused by an unusual bilateral optic nerve compression by three likely planum sphenoidale meningiomas rapidly induced by the administration of CPA for prostatic adenocarcinoma. This case is the first reported with a short exposure time (7 months) to CPA treatment before diagnosis of multiple meningiomas and stabilization on clinical follow-up after CPA treatment discontinuation.

**Keywords:** Papilledema; bilateral optic nerve compression; multiple meningiomas; cyproterone acetate; pharmacovigilance; exposure time

## INTRODUCTION

Cyproterone acetate (CPA) has an anti-androgenic, progestagenic and antigonadotropic effect. CPA can induce meningioma growth. In fact, meningiomas are known to be hormone-sensitive tumors expressing progesterone receptors [1-2]. Meningiomas are mostly benign tumors with meningothelial cells originating from the arachnoid tissue. Few cases have been reported and showed an increased risk of meningioma growth in patients treated with high doses of CPA [3-6]. The most recent case in the relevant field was in 2016 [7].

The review by the European Pharmacovigilance Working Party in 2009 concluded to a causal relationship between high dose CPA ( $\geq 25$  mg) and the occurrence of multiple meningiomas.

It has therefore resulted in formal contraindication of CPA treatment in patients with meningioma or a history of meningioma. Recently, in 2011 a population-based cohort study among 2474 patients showed that the exposure to high dose of CPA increases the risk of meningioma occurrence : 2474 users of high-dose cyproterone (6663 person-years), among whom four cases of meningioma were identified, with an incidence rate of 11 (95% CI: 16, 154) per 100,000 person-years after adjusting for age and sex, which was significantly higher than that observed among non-users (IR: 6.6; 95% CI: 6.0, 7.3) and among female users of low-dose cyproterone (IR: 0.0; 95% CI upper limit 5.5) [8]. Nevertheless the most detailed study of this question was a much larger cohort study in a population of 2,171,287 (14,059,934 person-years), among whom 745 patients with meningioma were identified and compared with 10,000 age- and sex-matched controls [9]. There was a significantly increased risk of meningioma among men who used androgen analogues (OR: 19.09; CI: 2.81-129.74) and among users of high-dose cyproterone acetate ( $>50$  mg/day; OR: 6.30; CI: 1.37-29) compared with non-users. It was the first cohort-study studying the causal relationship between CPA treatment and multiple meningiomas.

However, time between initial CPA intake and diagnosis is long. According to most studies, this period is at least two years.

Here, we present the case of an 83-year old man with acute visual impairment caused by three likely planum sphenoidale meningiomas with bilateral optic nerve compression induced after 7 months of CPA treatment. As far as we know, this case is the first with a short CPA exposure time before diagnosis. In addition, bilateral cases of optic nerve compression like this case are rare.

## CASE PRESENTATION

An 83-year old man presented to the emergency department of François Quesnay hospital (Mantes-la-Jolie, France) for sudden bilateral vision loss. The patient was referred to our department of ophthalmology for examination. His family history was unremarkable. His past medical history was significant for high blood pressure treated by angiotensin converting enzyme inhibitors (enalapril 20 mg per day) and thiazide diuretic (hydrochlorothiazide 12,5 mg per day) since two years, arthrosis treated by analgesic (paracetamol 1 g three times per day) since 10 years and prostate cancer treated by cyproterone acetate (100 mg twice a day) for seven months. Ocular examination revealed light perception acuity in his right eye and 6/10 on Monoyer scale in his left eye. There was a right relative afferent pupillary defect. Fundus examination and optical coherence tomography showed generalized, marked bilateral papilledema with peripapillary hemorrhages (figure 1 and 2). Goldmann visual field exam showed an inferior altitudinal scotoma (figure 3). Systemic examination was within normal limits with no evidence of neurofibromatosis type 2. A brain and orbit magnetic resonance imaging (MRI) was performed. We have highlighted three voluminous expansive tumoral processes of the planum of the sphenoid respectively weighted 18, 11, 9 mm. T1 and T2-weighted showed three iso-intense tumoral processes. T1-weighted with gadolinium injection showed diffuse enlargement and contrast enhancement (figure 4). One of the tumoral processes seemed to fill the right optical hole and compress the right optic nerve without infiltrating it. All these findings were consistent with meningiomas. The main hypothesis was that the recent administration of cyproterone acetate induced multiple meningiomas. These meningiomas caused bilateral optic nerve compression explaining acute visual impairment. The patient was referred to neurosurgeons. Neurosurgeons decided a therapeutic abstention

considering the advanced age and the past medical history. In the context of prostate cancer a cerebral biopsy should have been performed to formally eliminate metastases. However, MRI findings were typically consistent with meningiomas and neurosurgeons decided not to perform biopsy because the patient was bedridden and because of the old age. In addition, a work-up for spread of prostate cancer had been carried out by a cerebral MRI before CPA treatment and was normal. This finding provided an additional argument for diagnosis of multiples meningiomas. Cyproterone acetate was discontinued. The patient had a prescription of corticoid (Predinsone 60 mg per day) and carbonic anhydrase inhibitor (Acetazolamid 500 mg per day) for the bilateral papiledema. These treatments were introduced on the advice of the neurosurgeons. Corticoid and carbonic anhydrase inhibitor were withdrawn after ten days because effectiveness of these treatments on optic nerve compression had never been proved by studies and no clinical improvement was noticed at ten days. The follow-up period after treatment withdrawal was more than twelve months with no clinical progression. After twelve months of CPA treatment withdrawal left visual acuity was improved at 7/10 on Monoyer scale and right eye visual acuity was unchanged. Left eye fundus examination was within the limits of normal. Radiological follow-up by MRI has not been performed because one month later the patient had cardiac rhythm disorders and he needed a pacemaker. Therefore, MRI was contraindicated. We decided an only clinical follow-up every 6 months.

## DISCUSSION

After informing the pharmacology department of the hospital, we tried to establish a statement with the Pharmacovigilance causality assessment. The causality assessment can be defined as an estimation of the putative causal relationship between a drug treatment and the occurrence of an adverse event, for a given person at a given time. There were indicators to consider a direct accountability of CPA to explain the multiple meningiomas growth. Causality was assessed using the Naranjo Algorithm. Our case had a score of 5 (probable adverse drug reaction).

In our case, cerebral MRI findings are consistent with meningiomas despite we have no histological certainty and metastases of prostate cancer could not be formally eliminated. Cerebral MRI before CPA treatment was normal and this finding provided an additional argument for diagnosis of multiple meningiomas under CPA treatment.

To our knowledge, this case is the first reporting rapidly induced multiple meningiomas by CPA treatment. There have not been case studies with such a short exposure time. Usually, this period ranges from 2 to 10 years before diagnosis (Table 1). We have no explanation to this rapidly induced phenomenon. A hypothesis could be the higher exposure dose to CPA treatment (200 mg per day) than other past cases (50 mg to 100 mg per day) (table 1). Another hypothesis could be a more pronounced progesterone and estrogen receptors. We suppose that these hormones may influence the growth in tumor size by increasing blood volume and extracellular and intracellular fluid as well as by increasing proliferation of the tumor tissue [10, 11].

After 6 months of CPA treatment discontinuation, clinical follow-up showed an improvement in visual acuity and fundus examination. In absence of radiological follow-up we could not observe a tumor regression but we can talk at least of stabilization. Given the clinical



improvement of this case, it is unlikely that corticoid and carbonic anhydrase inhibitor had any influence. These treatments are subject to controversy. Effectiveness of corticoid and anhydrase inhibitor on optic nerve compression had never been proved by studies. Few reviews showed that CPA discontinuation leads to a rapid regression of meningiomas [12-16] (table 2). In these studies, only one reported case had meningioma stabilization like in our patient. These indicators seem to be evidences of the link between meningiomas growth and cyproterone acetate. Therefore, in front of induced CPA meningiomas, waiting before a surgery could be suitable because spontaneous regression or stabilization can occur.

Meningioma induced by CPA therapy is now a well-known phenomenon that has been put forward by five clinical cases and one observational study (Table 1). Our clinical presentation case was similar to last reported cases: visual impairment.

Our review of literature showed that most reported cases were younger than our patient. We have no explanation for this difference. However, one cohort study has reported 4 cases older than 60 years with multiple meningiomas induced under CPA treatment (Table 1). These cases had short exposure time: around 2 years (table 1). We suspect a link between CPA exposure time and patient age. It seems that in elderly patients, time between initial CPA intake and diagnosis of multiple meningiomas is short.

Multiple meningiomas represent only 5 % of all reported cases. Moreover, meningiomas account for 5-10 % of all orbital tumors [17] and bilateral cases of optic nerve compression like our case are rare and represent just 5 % of all reported cases [18]. In our case, the unchanged visual acuity on right eye is probably due to irreversible damage caused by the compression of the right optic nerve.

Most reported cases undergoing CPA treatment have skull base location meningiomas like in our case. Therefore, we suspect a particular histopathologic entity considering the

preferential skull base location of this type of meningiomas (table 2). We suppose that these meningiomas present overexpressed progesterone and estrogen receptors. Post mortem biopsy for histopathologic analyze could be interesting.

## CONCLUSION

Published cases of meningiomas under CPA treatment are low. We present this report to show that meningiomas can occur rapidly under CPA treatment. Thus, we suggest an ophthalmologic examination including a fundus examination and a visual field every 6 months for patients undergoing CPA treatment to prevent a delay in diagnosis (figure 5).

Finally, if a meningioma is found with a patient under CPA medication, conservative tumor management with clinical and imaging follow-up could be an option as stabilization may occur after treatment discontinuation (figure 5).

## **ACKNOWLEDGMENTS**

Dr. K. KEILANI, E. ROBBEN, S. EVEILLARD, N. JOUZIER, C. REGNAT.

## **Declaration of interests**

The authors declare that they have no conflicts of interest related to this article.

## **REFERENCES**

1. Marosi C, Hassler M, Roessler K, Reni M, Sant M, Mazza E, Vecht C. Meningioma. *Crit Rev Oncol Hematol* 2008; 67: 153–71.
2. Pravdenkova S, Al-Mefty O, Sawyer J, Husain M. Progesterone and estrogen receptors: opposing prognostic indicators in meningiomas. *J Neurosurg.* 2006 Aug;105(2):163-73.
3. Gazzeri R, Galarza M, Gazzeri G. Growth of a meningioma in a transsexual patient after estrogen-progestin therapy. *N Engl J Med.* 2007 Dec 6;357(23):2411-2.
4. Froelich S, et al. Endocrine abstracts (Proceedings of the 10<sup>th</sup> European Congress of Endocrinology; Berlin, Germany). 2008; 16:158.
5. Bergoglio MT, et al. Symptomatic meningioma induced by cross-sex hormone treatment in a male-to-female transsexual. *Endocrinol Nutr.* 2013 May;60(5):264-7.
6. Sys C, Kestelyn P. Unilateral proptosis and blindness caused by meningioma in a patient treated with cyproterone acetate. *GMS Ophthalmol Cases* 2015; 5: Doc05.
7. Alderman CP. Probable drug-related meningioma detected during the course of medication review services. *Consult Pharm* 2016; 31(9): 500-4.
8. Gil M et al. Risk of meningioma among users of high doses of cyproterone acetate as compared with the general population: evidence from a population-based cohort study. *Br J Clin Pharmacol.* 2011 Dec;72(6):965-8.
9. Cea-Soriano L, Blenk T, Wallander MA, Rodríguez LA. Hormonal therapies and meningioma: is there a link? *Cancer Epidemiol* 2012; 36(2): 198-205.
10. Blankenstein MA, Verheijen FM, Jacobs JM, et al. Occurrence, regulation, and significance of progesterone receptors in human meningioma. *Steroids* 2000;65:795–800

11. Adams EF, Schrell UM, Fahlbusch R, Thierauf P. Hormonal dependency of cerebral meningiomas. Part 2: In vitro effect of steroids, bromocriptine, and epidermal growth factor on growth of meningiomas. *J Neurosurg* 1990; 73(5): 750-5.
12. Cebula H, Pham TQ, Boyer P, Froelich S. Regression of meningiomas after discontinuation of cyproterone acetate in a transsexual patient. *Acta Neurochir (Wien)*. 2010 Nov;152(11):1955-6.
13. Gonçalves AM, Page P, Domigo V, Méder JF, Oppenheim C. Abrupt regression of a meningioma after discontinuation of cyproterone treatment. *AJNR Am J Neuroradiol*. 2010 Sep;31(8):1504-5.
14. Bernat AL, Oyama K, Hamdi S, Mandonnet E, Vexiau D, Pocard M, George B, Froelich S. Growth stabilization and regression of meningiomas after discontinuation of cyproterone acetate: a case series of 12 patients. *Acta Neurochir (Wien)*. 2015 Oct;157(10):1741-6.
15. Botella C, Coll G, Lemaire JJ, Irthum B. Méningiomes intracrâniens et utilisation prolongée d'acétate de cyprotérone à dose conventionnelle chez la femme: à propos de deux cas de régression tumorale après arrêt du traitement. *Neurochirurgie* 2015; 61(5): 339-42.
16. Zairi F, Aboukais R, LE Rhun E, Marinho P, Maurage CA, Lejeune JP. Close follow-up after discontinuation of cyproterone acetate: a possible option to defer surgery in patients with voluminous intracranial meningioma. *J Neurosurg Sci* 2017; 61(1): 98-101.
17. Saeed P, Rootman J, Nugent RA, White VA, Mackenzie IR, Koornneef L. Optic nerve sheath meningiomas. *Ophthalmology*. 2003;110:2019–30.
18. Miller NR. The evolving management of optic nerve sheath meningiomas. *Br J Ophthalmol*. 2002;86:1198.

**Figures.**

**Figure 1. Bilateral papilledema : left eye (right) and right eye (left).**

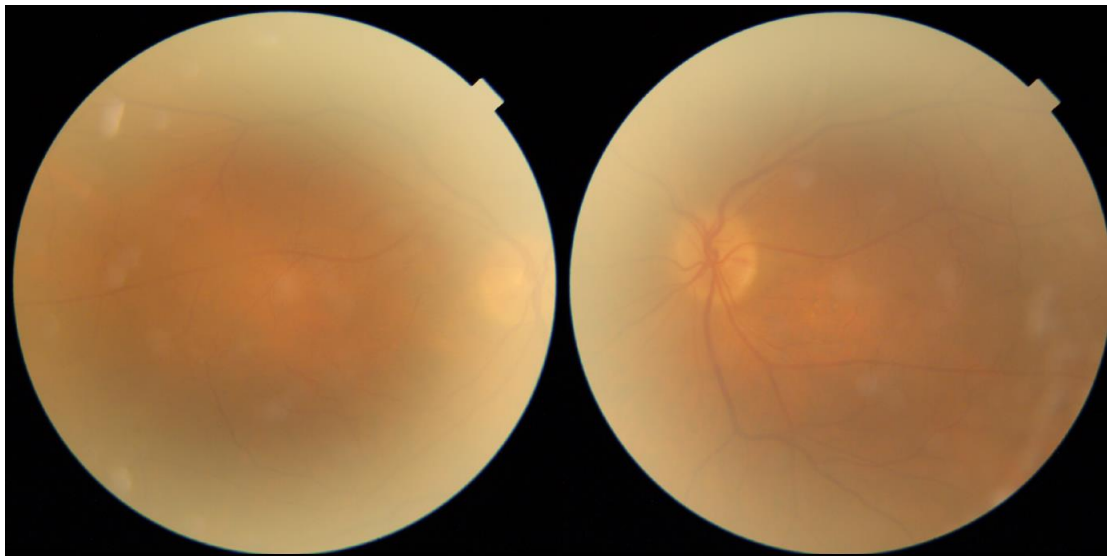
**Figure 2. OCT of left eye (right) and right eye (left)**

**Figure 3. Visual field of left eye**

**Figure 4. T1-weighted with gadolinium injection showed diffuse enlargement and contrast enhancement of three voluminous expansive tumoral processes of the planum of the sphenoid bone**

**Figure 5. Decision tree : clinical monitoring under CPA treatment and clinical strategy after discontinuation**

**Figure 1.**



**Figure 2.**

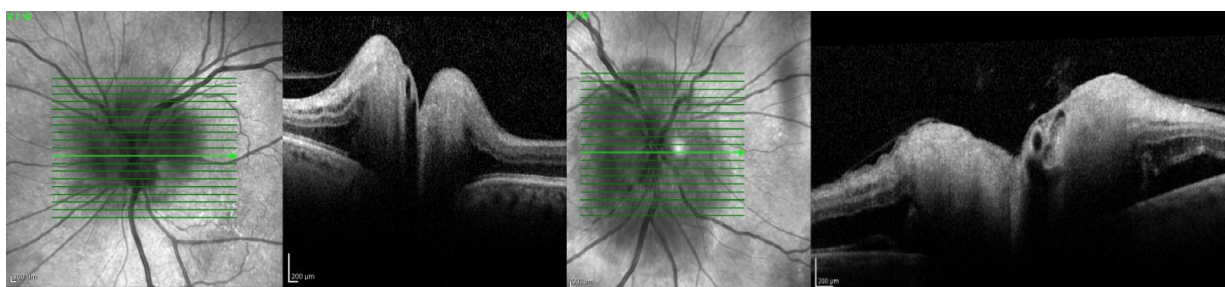


Figure 3.

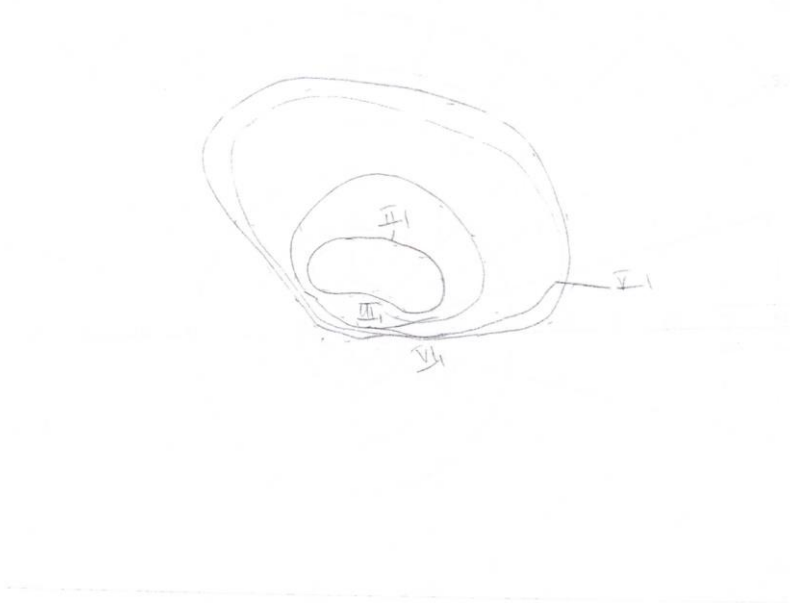


Figure 4.

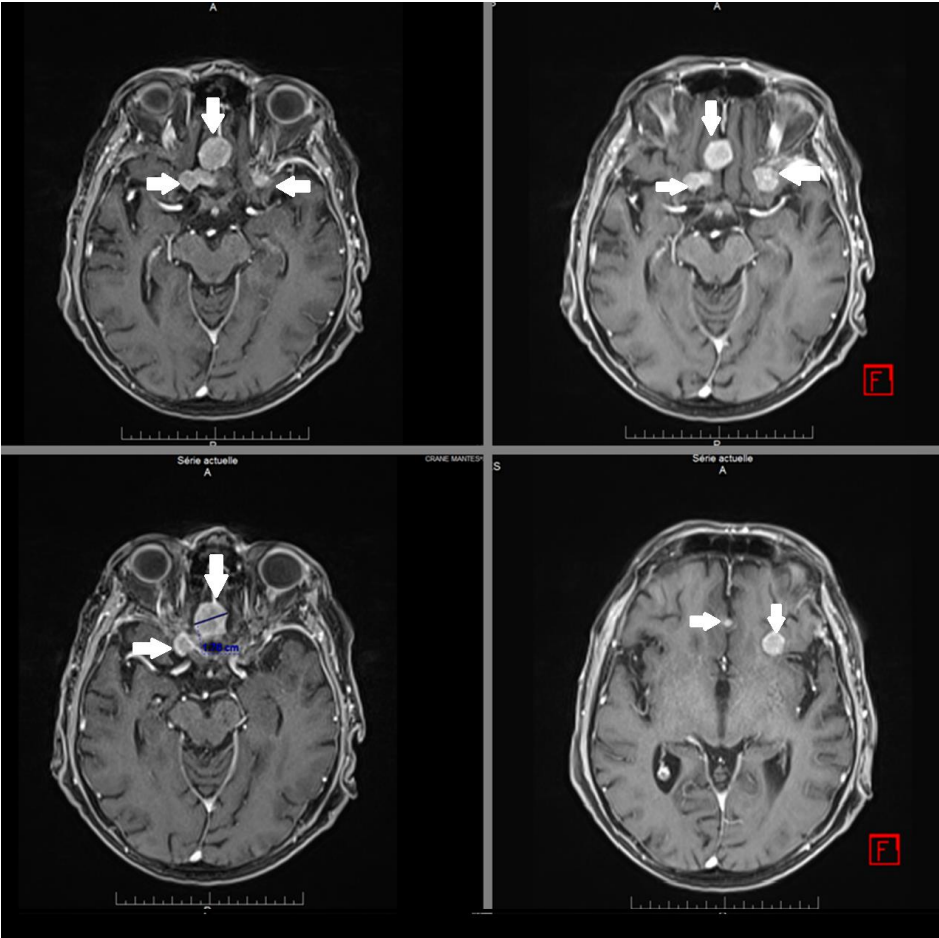
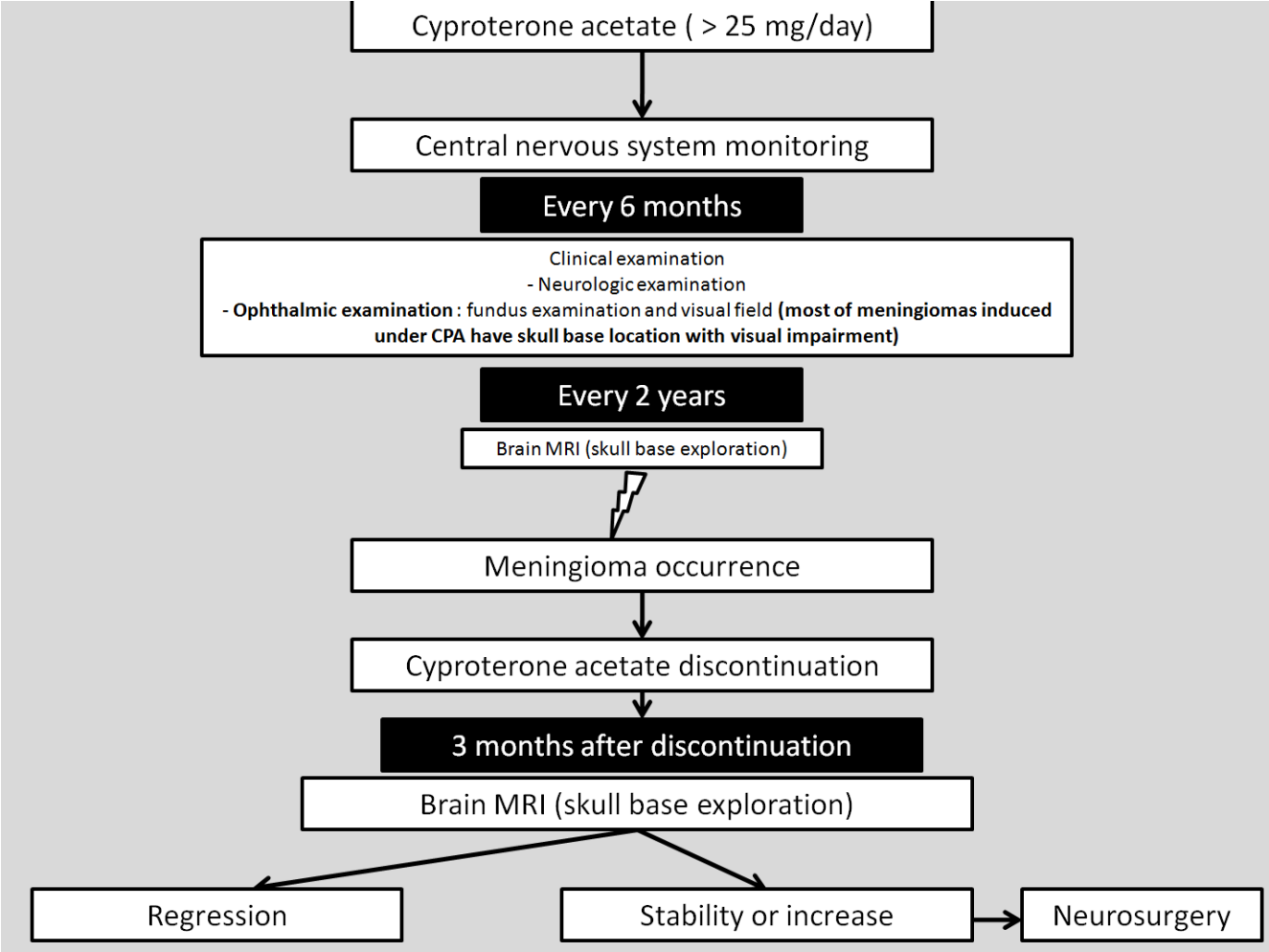




Figure 5.



**Tables.**

**Table 1. Reported clinical cases of multiple meningiomas induced by cyproterone acetate**

**Table 2. Reported cases of multiple meningiomas regression and stabilization after cyproterone acetate withdrawal**

**Table 1. Reported clinical cases of multiple meningiomas induced by cyproterone acetate**

Study	Type of study	Number of case(s)	Mean age (years)	Gender	Duration of exposure to CPA treatment	Dose of CPA treatment	Indication	Localization of tumour	Symtoms
<u>Gazzeri R, Galarza M, Gazzeri G.</u> Growth of a meningioma in a transsexual patient after estrogen-progestin therapy. <u>N Engl J Med.</u> 2007 Dec 6;357(23):2411-2.	Case report	1	28	Male	5 years	100 mg per day	Feminizing endocrine regimen (transsexual patient)	Olfactory groove meningioma	Headache and visual impairment
Froelich S, et al. Endocrine abstracts (Proceedings of the 10 <sup>th</sup> European Congress of Endocrinology; Berlin,Germany). 2008; 16:158.	Case reports	9	46	9 females	10 to 20 years	50 mg per day	Not specified	Skull base location	6 visual impairment 3 no symtoms
<u>Cebula H, Pham TQ, Boyer P, Froelich S.</u> Regression of meningiomas after discontinuation of cyproterone acetate in a transsexual patient. <u>Acta Neurochir (Wien).</u> 2010 Nov;152(11):1955-6.	Case report	1	48	Male	10 years	100 mg per day	Feminizing endocrine regimen (transsexual patient)	Left temporal convexity meningioma	Headache
<u>Goncalves AM, Page P, Domigo V, Méder JF, Oppenheim C.</u> Abrupt regression of a meningioma after discontinuation of cyproterone treatment. <u>AJNR Am J Neuroradiol.</u> 2010 Sep;31(8):1504-5.	Case report	1	46	Female	10 years	50 mg per day	Androgenetic alopecia	Right frontal meningioma	Left upper limb paresthesia (stroke)
<u>Gil M</u> et al. Risk of meningioma among users of high doses of cyproterone acetate as compared with the general population: evidence from a population-based cohort study. <u>Br J Clin Pharmacol.</u> 2011 Dec;72(6):965-8.	Cohort study	4	65,7 ±16,7*	2 Females 2 Males	2,45 ± 0,17* years	50 mg per day	2 prostate cancers 1 not specified 1 Androgenetic alopecia	1 cavernous sinus 2 olfactory groove 1 left cerebral hemisphere	Not specified
Cea-Soriano L et al. Hormonal therapies and meningioma: is there a link? <u>Cancer Epidemiol</u> 2012; 36(2): 198-205.	Cohort study	4	40	Male	6 years	50 mg per day	Feminizing endocrine regimen (transsexual patient)	Tuberculum sellae	Visual impairment
<u>Bergoglio MT,</u> et al. Symptomatic meningioma induced by cross-sex hormone treatment in a male-to-female transsexual. <u>Endocrinol Nutr.</u> 2013 May;60(5):264-7.	Case report	1	35	Male	4 years	50 mg per day	Feminizing endocrine regimen (transsexual patient)	Tuberculum sellae	Headache and visual impairment
<u>Botella C</u> et al. Méningiomes intracrâniens et utilisation prolongée d'acétate de cyprotérone à dose conventionnelle chez la femme: à propos de deux cas de régression tumorale après arrêt du traitement. <u>Neurochirurgie</u> 2015; 61(5): 339-42.	Case reports	2	47,5	Females	14,5 years	50 mg per day	Not specified	1 Left frontal convexity meningioma and right infra chiasma meningioma 1 Tuberculum sellae	Headache and visual impairment
<u>Sys C</u> et al. Unilateral proptosis and blindness caused by meningioma in a patient treated with cyproterone acetate. <u>GMS Ophthalmol Cases</u> 2015; 5: Doc05.	Case report	1	42	Female	23 years	100 mg per day	Reduce undesirable sexual behavior	<b>Anterior temporal lobe extending into the left orbit with optic nerve compression</b>	Visual impairment

\* The more or less correspond to mean values +/- standard deviation

**Table 2. Reported cases of multiple meningiomas regression and stabilization after cyproterone acetate withdrawal**

Study	Type of study	Number of case(s)	Mean age (years)	Gender	Effect after CPA withdrawal	Follow-up after treatment withdrawal (months)
<u>Cebula H, Pham TQ, Boyer P, Froelich S.</u> Regression of meningiomas after discontinuation of cyproterone acetate in a transsexual patient. <u>Acta Neurochir (Wien)</u> . 2010 Nov;152(11):1955-6.	Case report	1	48	Male	Regression (6 months) and then stabilization (14 months)	20 months
<u>Gonçalves AM, Page P, Domingo V, Médér JF, Oppenheim C.</u> Abrupt regression of a meningioma after discontinuation of cyproterone treatment. <u>AJNR Am J Neuroradiol</u> . 2010 Sep;31(8):1504-5.	Case report	1	46	Female	Regression	6 months
<u>Bernat AL, Oyama K, Hamdi S, Mandonnet E, Vexiau D, Pocard M, George B, Froelich S.</u> Growth stabilization and regression of meningiomas after discontinuation of cyproterone acetate: a case series of 12 patients. <u>Acta Neurochir (Wien)</u> . 2015 Oct;157(10):1741-6.	Case reports	12	49 ± 7	2 Females 2 Males	11 cases of regression 1 case of stabilization	12 months
<u>Botella C et al.</u> Méningiomes intracrâniens et utilisation prolongée d'acétate de cyprotérone à dose conventionnelle chez la femme: à propos de deux cas de régression tumorale après arrêt du traitement. <u>Neurochirurgie</u> 2015; 61(5): 339-42.	Case reports	2	47,5	2 Females	Regression	63 months

° The more or less correspond to mean values +/- standard deviation