



**HAL**  
open science

## **A novel missense mutation of GJA8 causes congenital cataract in a large Mauritanian family**

Mouna Hadrami, Crystel Bonnet, Fatimetou Vetén, Christina Zeitz, Christel Condroyer, Panfeng Wang, Sidi Cheikh, Mohamed Biya, Med Ahmed Sidi Ahmed, Qingjiong Zhang, et al.

### ► To cite this version:

Mouna Hadrami, Crystel Bonnet, Fatimetou Vetén, Christina Zeitz, Christel Condroyer, et al.. A novel missense mutation of GJA8 causes congenital cataract in a large Mauritanian family. *European Journal of Ophthalmology*, 2019, 29 (6), pp.621-628. 10.1177/1120672118804757 . hal-01990091

**HAL Id: hal-01990091**

**<https://hal.sorbonne-universite.fr/hal-01990091>**

Submitted on 29 Aug 2019

**HAL** is a multi-disciplinary open access archive for the deposit and dissemination of scientific research documents, whether they are published or not. The documents may come from teaching and research institutions in France or abroad, or from public or private research centers.

L'archive ouverte pluridisciplinaire **HAL**, est destinée au dépôt et à la diffusion de documents scientifiques de niveau recherche, publiés ou non, émanant des établissements d'enseignement et de recherche français ou étrangers, des laboratoires publics ou privés.

# **A novel missense mutation of *GJA8* causes congenital cataract in a large**

## **Mauritanian family**

Mouna Hadrami<sup>1</sup> • Crystel Bonnet<sup>2,3,4</sup> • Fatimetou Veten<sup>1</sup> • Christina Zeitz<sup>5</sup> • Christel Condroyer<sup>5</sup>,  
Panfeng Wang<sup>7</sup> • Sidi cheikh<sup>6</sup> • Mohamed Biya<sup>1</sup> • Med Ahmed Sidi Ahmed<sup>6,12</sup> • Qingjiong Zhang<sup>7</sup> •  
Isabelle Audo<sup>5,8,9</sup> • Christine Petit<sup>2,3,4 10,11</sup> • Ahmed Houmeida<sup>1</sup>

1 Unité de Recherche sur les Biomarqueurs dans la Population Mauritanienne, Université des Sciences de Technologies et de médecine (USTM), Nouakchott, Mauritanie.

2 Syndrome de Usher et Autres Atteintes Rétino-Cochléaires, Institut de la Vision, Paris, France.

3 UMRS 1120, Institut National de la Santé et de la Recherche Médicale, Paris, France.

4 Sorbonne Universités, UPMC Université Paris 06, Complexité du Vivant, Paris, France.

5 Sorbonne Universités, UPMC Univ Paris 06, INSERM, CNRS, Paris, France.

6 Service Ophtalmologie, Centre Hospitalier National, Nouakchott, Mauritanie.

7 Zhongshan Ophthalmic Center, Sun Yat-sen University, China

8 Centre Hospitalier National d'Ophtalmologie des Quinze-Vingts, DHU Sight Restore, INSERM-DHOS CIC 1423, Paris, France.

9 Institute of Ophthalmology, University College of London, London, UK.

10 Unité de Génétique et Physiologie de l'Audition, Institut Pasteur, Paris, France.

11 Collège de France, Paris, France.

12 Programme national de lutte contre cécités; Nouakchott ; Mauritanie

Corresponding author: Ahmed Houmeida : [houmeida@hotmail.com](mailto:houmeida@hotmail.com)

Keywords: *GJA8*, Connexin 50, cataract, Mauritania, Targeted next-generation sequencing

running title: Cataract in Mauritania

## **Abstract**

**Background:** Congenital cataract is the most frequent cause of childhood blindness. To date, more than 40 loci associated with cataract have been identified, including at least 26 genes on different chromosomes associated with inherited cataract. Here, we describe nine generations of a Mauritanian consanguineous family affected with congenital cataract. This study aimed to identify the genetic mutation in this Mauritanian family.

**Methods:** A detailed nine-generation autosomal dominant Mauritanian cataract family history and clinical data of the family members were recorded. A total of 14 family members, including 10 affected and 4 unaffected individuals were recruited. Targeted next-generation sequencing was performed to determine the disease-causing mutation. Sanger sequencing was used to confirm the results.

**Results:** A novel heterozygous missense mutation, c.166A>C (p.Thr56Pro), in *GJA8* was identified. This mutation co-segregated with all affected individuals and was not observed in the unaffected family members. The prediction of secondary structure from the protein sequence showed that the structure of the mutant protein was different with that wild-type *GJA8*.

**Conclusions:** We describe for the first time a missense mutation, c.166A>C in *GJA8*, which is associated with autosomal dominant congenital cataract in a Mauritanian family.

## **Introduction:**

Cataract is commonly considered as an age related condition. This pathology may also be secondary to various after birth events or inborn[1-2]. Blindness from congenital cataract is indeed estimated to affect about 1-15 per 10,000 children in the developing world as the disease goes often undetected in early childhood resulting in most cases in permanent visual loss[3-4]. Hereditary congenital cataracts account for at least a third of all congenital cataract forms with the autosomal dominant being the most common familial form. They can also be transmitted as autosomal recessive or X-linked[4].

Of the thirty four genetic loci to which congenial cataracts, isolated or primary, have been mapped, a quarter of the known mutant genes are gap junction channel protein (connexins) encoding genes. Two of these genes code for  $\alpha$ -connexins Cx46 (GJA3) and Cx50 (GJA8) which are the most abundant proteins in lens fiber cells and essential, respectively, in the lens transparency and development [5].

Although about 50% of blindness in African populations is resulting from cataract, studies on the etiologies of this often avoidable disorder are very limited. Besides, there is no data, to our knowledge, on the genes implicated in hereditary cataract in these populations.

Here, we described the segregation profile of a congenital nuclear cataract in a nine generation Mauritanian family living in an isolated village located in the south of Mauritania. Using next-generation sequencing of whole exome, we also investigated the underlying genetic defect and analyzed the potential structural organization of the mutant region.

## **Materials and methods**

This Mauritanian family living in the village of Dali Gumba, in the Hodh region of southern Mauritania has been affected, over nine generations, by a blindness which develops in early years following a congenital cataract. A team of eye specialists from the CNH (Centre National Hospitalier) and biologists from the University of Sciences technologies and medicine has clinically examined and interviewed the members of the living family members. A pedigree and family medical history were recorded. Ophthalmological assessment including slit lamp was carried out for all family members. Fourteen individuals (10 patients and 4 unaffected subjects) were recruited for molecular investigation (figure 1a).

### ***Targeted next-generation sequencing***

DNA extraction, from peripheral blood collected in EDTA tubes, was carried out using QIAampDNA Blood Midi Kit (Qiagen, Hilden, Germany). Next-generation sequencing (NGS) was selectively conducted on the index case (figure 1a), using a custom-designed in-solution capture array targeting a panel of 116 cataract underlying genes. Details of the relevant genes are provided in **Appendix1**. Library preparation, qualification and NGS on the HiSeq2000 platform (Illumina, Inc., San Diego, CA) were performed as described previously [6]. The patient DNA, along other DNA samples, was multiplexed then randomly fragmented, ligated and amplified via ligation-mediated polymerase chain reaction (LM-PCR) [7]. After purification and hybridization, a quantitative PCR was then performed on LM-PCR products to assess the level of enrichment.

### ***Bioinformatic analyses***

Sequence reads alignment to the reference human genome 19 (hg19) with UCSC and nucleotide variation annotations were performed using single nucleotide polymorphism (SNP) databases, including HapMap project (<http://hapmap.ncbi.nlm.nih.gov/>), 1000 Genome Project (<http://www.1000genomes.org/>), Exome Variant Server (EVS, <http://evs.gs.washington.edu/EVS/>), and Exome Aggregation Consortium (EXAC, <http://exac.broadinstitute.org/>). In the Pathogenicity evaluation, amino acid change was considered as potentially disease causing if predicted by at least one of the programs (PolyPhen2, <http://genetics.bwh.harvard.edu/pph2/>), Sorting Intolerant From Tolerant (SIFT, <http://sift.jcvi.org/>) and Mutation Taster (<http://www.mutationtaster.org/>). (**Appendix2**) Amino acid conservation across species was studied with UCSC Genome Browser (<https://genome.ucsc.edu/>). (figure2). The conformational change induced by the DNA variation on the mutant protein was analyzed and compared to wild-type protein structure using CFSSP server (<http://www.biogem.org/tool/chou-fasman/>).

### ***Sanger sequencing***

The protein variant identification, following NGS, was confirmed in the index proband and thirteen other affected family members by Sanger sequencing (ref) using (human GJA8 reference sequence NM\_005267.4, Forward: 5'- GCTCTTGCCTTCTCCCTCAT -3' and

Reverse: 5'- TGGCTTTCTGGATGGAGGAG-3'). The primers were designed using Primer3 (<http://bioinfo.ut.ee/primer3-0.4.0/>).

Approval to this study was given by the ethics committee of the University of Sciences, Technologies and Medicine, Nouakchott, Mauritania. The purpose of the study was explained to the participants and their informed and signed consent was obtained. For children, the parents approval was obtained.

## **Results**

### ***Clinical exploration***

Inborn cloudiness of the eye natural lens was reported in all the interviewed patients. Following clinical examination, nuclear congenital bilateral cataract was confirmed in all suspected cases from both genders. Initial signs of interference with the vision were reported to be in the first two years of life. The disease progression varied slightly among patients. Preliminary examination did not reveal association with any common ocular anomalies or systemic condition. Cataract was observed in each generation and all affected individuals had at least one parent who carries the disease. These characteristics were consistent with an autosomal dominant inheritance.

### ***Genetic screening***

Next generation sequencing performed on the proband's DNA (Fig 1.a, \*) and selectively targeting the coding exons of 116 congenital cataract associated genes showed, after filtration and validation, a pathogenic DNA missense variation, A>C at position 166 (c.166 A>C) in the Cx50  $\alpha$ -connexin gene (*GJA8*). (**Appendix1**).

This mutation, not reported before, resulted in the substitution of an evolutionarily highly conserved threonine at position 56 by a proline (p. T56P) (figure 1.c). This change was not observed in any of DNA samples from 15 individuals affected by other ocular pathologies and sequenced along the proband's DNA using the same NGS approach.

Sanger sequencing of the exon 2 of *GJA8* in the fourteen affected family members, including the proband, showed the same A>C mutation, at position 166 from the translation start site (figure 1.b). This co-segregation with the disease was found only in the cataract patients as none of the unaffected family members or the healthy controls showed this mutation.

### ***Bioinformatics analysis***

Using the wild type Cx-50 protein as template, the predicted three-dimensional structure impacted by the amino acid point mutation p.T56P showed a localized alteration, with a score of 1.00 using CFSSP, in the first extra membrane loop which consisted of the disruption of the wild-type sheet and its replacement, in the mutant protein, by a turn then coil (figure 2). This conformational change was assessed functionally as probably damaging with a score of 1.0 by SIFT and PolyPhen-2, respectively.

### **Discussion**

Although blindness resulting from cataract is a primary health issue, data on the etiologies of this disease remained very limited in developing countries. In this study, we reported a bilateral nuclear cataract present at birth in a nine generation family living in a remote village of Southern Mauritania. The age of onset varied but in most patients, the vision impairment was noticed within the two first years with a progressive evolution. Surgery did not confer a visual benefit more likely due to the relatively advanced age, mostly above 6 years, of the patients at presentation. The timing of extraction in congenital cataract is indeed critical in ensuring visual rehabilitation as the ideal recommended age of its removal is about ten weeks to one year at the latest if the lens opacification is bilateral (8). These poor outcomes have greatly affected the trust of the family rulers in the medical benefit of the operation which resulted in that nearly all cataract-affected children became blind or greatly visually impaired.

Although the age at onset does not necessarily indicate the etiology, the presence of this cataract at birth and in several family members was evocative of an inherited cause. Besides, physical examination and personal medical history of patients did not reveal any underlying defined metabolic or infectious disorder. As in most inherited cataracts, the medical pedigree of the cataract phenotype in this family was consistent with an autosomal dominant pattern (9).

About 10 to 25 % of all cataracts are inherited and most of the genetically categorized congenital forms of this disorder were associated with known candidate genes (10-11). However, as no data were available on the specific implication of these cataract-related genes in any African or Arab population, we opted for a comprehensive NGS screening approach

using a large panel of 116 cataract underlying genes (6-12). This sequencing, confirmed by direct Sanger sequencing, showed a new missense variation at position 166 (c.166 A>C) in *GJA8* gene, on chromosome 1, which resulted, at protein level, in a p.T56P substitution in Cx50  $\alpha$ -connexin, a well known gap junction channel forming protein (13). This change was not observed in non affected family members or the healthy controls which supported the potential disease contributing effect of this mutation. This likely effect was also consistent with the position-specific independent count (PSIC) score of 1.000, as “probably damaging”, produced by PolyPhen-2, a well approved pathogenicity predicting software (**Appendix 2**). The effect of the substitution on the protein function was also signified using the CFSSP server (figure 2).

Different functional studies on expressed *GJA3* and *GJA8* mutant proteins have shown abnormalities likely to affect intercellular communication through channel alteration or cellular trafficking impairment resulting in the reduction of the number of efficient gap junction channels within the plasma membrane. Thus, in mouse lines, targeted deletions of Cx50 protein have been linked to inheritance of cataract through their effect on lens size and onset of disease phenotype (14). Data from transgenic mice also showed that alteration of the level of Cx50 production could result in lens opacification (15). Expressed human connexin mutants associated with congenital cataract have too showed biochemical and cellular aberration ranging from substantial reduction in gap junction plaques, generation of non-functional intercellular channels and formation of hemichannels with altered gating or charge selectivity properties (16-17).

In human families, more than forty missense Cx50 mutations, all transmitted in autosomal dominant mode, have so far been linked to congenital cataract on the basis of their disease segregation pattern and clinical appearance (table 1). The protein tertiary structure of Connexin 50, like other connexin family members, showed, besides the four highly ordered transmembrane segments TM1-TM4, the C and N cytoplasmic termini, three loops (two extra-cellular: EL1 - EL2 and one cytoplasmic: CL) (18). Nearly 50 % of all cataract related mutations have been mapped to E1 and E2 loops which, by several analysis, were found to be structurally fundamental for gap junction generation (19). Although we did not perform a protein stability or cell localization testing on the mutant protein found in this family, the positions of four mutation with respect to the membrane topology of the wild type C50 connexin showed that the replacement (p. T56P) concerned a highly conserved amino acid. This mutation, in loop E1, is also positioned in a site where numerous other congenital cataract



linked mutations have been identified (Table1). For instance, Cx50-S50P mutation (figure 1.c), close to our mutation T56P and also involving the introduction of a proline amino acid has been shown to affect lens physiopathology (21). The site of p.T56P substitution may therefore be determinant in the physiological contribution of connexin Cx50 and its integrity could affect the lens normal survival. In that respect, the conformational disruption predicted here i.e. the replacement of a  $\beta$  sheet in the wild type Cx50 connexin by the turn then coil in the mutant protein, is reasonable giving the known distinctive rigidity of the proline's side chain. Proline is indeed the only proteogenic amino acid with a constrained  $\phi$  angle (approximately at  $-65^\circ$ ) due to the covalent locking of the nitrogen atom in the side chain five-membered ring. As a result of this angular restriction, interference of proline amino acid with the regular protein neighboring secondary structure ( $\alpha$  helix or  $\beta$  sheet) is well documented (22).

As highlighted above, cataract phenotypes have been linked to several candidate genes. Although the mutations were largely in the same gene (*GJA8*), their respective occurrence appeared to reflect a population related distribution as most of these variants were reported in population of different origin (table1). A similar population allocation pattern has been reported for another heterogeneous monogenic disease i.e. beta thalassemia. This inherited blood disorder is indeed often caused, in a defined group, by a very limited number of  $\beta$ -gene mutations. For instance, in North African populations, nonsense mutation such as codon 39 (A >T) and splice junction IVSI-1 were the most common cause of  $\beta$  thal cases (23). In sub-Saharan African populations, Substitution (A >G) at position -29 in the Tata box and IVS2-849 have been reported respectively in  $\beta^+$  and  $\beta^0$  U.S. black African patients (24). Giving the absence of any data on inherited cataract in African populations, we could not relate our mutation to an existing cataract variant in these populations. However, the affected family belongs to the Moors (Maures) which is the predominant ethnic group of the Mauritanian population. This group of berber-arab origin ethnically self-identifies with the neighboring North Africa populations (25). Although no cataract associated mutation has so far been reported in this region and the specific ethnic occurrence of 166 (c.166 A>C) remains to be ascertained, this finding may be relevant in the population distribution analysis of future cataract related gene mutations in these populations.

Looking at the broader contribution of variant c.166 A>C, this new mutation expands the spectrum of cataract associated DNA variants (table1). Besides, it was found in a remotely located family. Characterization of biomarkers in ethnically or geographically restricted

groups has indeed been reported to be more pertinent, than in general population studies, in understanding the heritability of population common genetic traits and diseases associated variants. This mutation, giving its protein location and specific ethnic occurrence may therefore contribute in assessing the physiopathology of inherited cataract.

## **Conclusion**

In this study, we identified a family new mutation (c.166 A>C) in GJA8 segregating with a nuclear congenital cataract. Giving that no other associated mutation was found in the proband's DNA using the powerful screening technique of NGS and its segregation with the phenotype, this mutation might be useful as a predicting marker of the disease onset before the clinical manifestation of the lens opacification.

1. Haargaard B, Wohlfahrt J, Fledelius HC, Rosenberg T, Melbye M. A nationwide Danish study of 1027 cases of congenital/infantile cataracts: etiological and clinical classifications. *Ophthalmology*. 2004;111:2292–8.
2. Rao, GN; Khanna, R; Payal, A (January 2011). The global burden of cataract. *Current Opinion in Ophthalmology*. 22 (1): 4– 9231.
3. J. Fielding Hejtmancik, Congenital Cataracts and their Molecular Genetics. *Semin Cell Dev Biol*. 2008 Apr; 19(2): 134–149.
4. Reddy MA, Francis PJ, Berry V, Bhattacharya SS, Moore AT. Molecular genetic basis of inherited cataract and associated phenotypes. *Surv Ophthalmol*. 2004;49(3):300–15.
5. A Shielsa and JF Hejtmancik b Genetics of human cataract *Clin Genet*. 2013 Aug; 84(2): 120–127.
6. Chen X, Zhao K, Sheng X, Li Y, Gao X, Zhang X, Kang X, Pan 16. X, Liu Y, Jiang C, Shi H, Rong W, Chen LJ, Lai TY, Wang X, Yuan S, Liu Q, Vollrath D, Pang CP, Zhao C. Targeted sequencing of genes associated with hereditary retinal dystrophies

and 10 candidate genes identifies novel and known mutations in patients with various retinal diseases. *Invest Ophthalmol Vis Sci* 2013; 54:2186-97.

7. Angers M, Cloutier JF, Castonguay A, Drouin R. Optimal conditions to use Pfuexo(-) DNA polymerase for highly efficient ligation-mediated polymerase chain reaction protocols. *Nucleic Acids Res* 2001; 29:E83.
8. Mackay DS, Bennett TM, Culican SM, Shiels A. Exome sequencing identifies novel and recurrent mutations in GJA8 and CRYGD associated with inherited cataract. *Hum Genomics*. 2014, 18; 8:19.
9. Willoughby CE1, Arab S, Gandhi R, Zeinali S, Arab S, Luk D, Billingsley G, Munier FL, Héon E. A novel GJA8 mutation in an Iranian family with progressive autosomal dominant congenital nuclear cataract. *J Med Genet*. 2003;40(11):e124.
10. Ma AS, Grigg JR, Ho G, Prokudin I, Farnsworth E, Holman K, Cheng A, Billson FA, Martin F, Fraser C, Mowat D, Smith J, Christodoulou J, Flaherty M, Bennetts B, Jamieson RV. Sporadic and Familial Congenital Cataracts: Mutational Spectrum and New Diagnoses Using Next-Generation Sequencing. *Hum Mutat*. 2016; 37 (4):371-84.
11. Wang K, Wang B, Wang J, Zhou S, Yun B, Suo P, Cheng J, Ma X, Zhu S. A novel GJA8 mutation (p.I31T) causing autosomal dominant congenital cataract in a Chinese family. *Mol Vis*. 2009;15:2813–20.
12. Sun W, Xiao X, Li S, Guo X, Zhang Q. Mutation analysis of 12 genes in Chinese families with congenital cataracts. *Mol Vis*. 2011;17:2197-206.
13. Apple DJ, Ram J, Foster A, Peng Q. Elimination of cataract blindness: a global perspective entering the new millenium. *SurvOphthalmol*. 2000; 45(Suppl 1):S1–196.
14. Gerido, D. A. and White, T. W. Connexin disorders of the ear, skin, and lens. *Biochim. Biophys. Acta*. 2004; 1662:159-170.

15. Pfenniger, A., Wohlwend, A. & Kwak, B. R. Mutations in connexin genes and disease. *Eur J Clin Invest* 2011; 41, 103–16.
16. Pal JD, Berthoud VM, Beyer EC, Mackay DS, Shiels AE, Bihara L. Molecular mechanism underlying a Cx50-linked congenital cataract. *Am J Physiol* 1999; 276:C1443- C1446.
17. Pal JD, Liu X, Mackay D. Connexin46 mutations linked to congenital cataract show loss of gap junction channel function. *Am J Physiol Cell Physiol* 2000; C596- C602.
18. Valiunas, V., Beyer, E. C. and Brink, P. R. Cardiac gap junction channels show quantitative differences in selectivity. *Circ. Res.* 2002, 91, 104-111.
19. Spray, D. C., Harris, A. L. and Bennett, M. V. Equilibrium properties of a voltage-dependent junctional conductance. *J. Gen. Physiol.* 1981; 77, 77-93.
20. Beahm, D. L. and Hall, J. E. Hemichannel and junctional properties of connexin 50. *Biophys. J.* 2002, 2016-2031.
21. Adam M, DeRosa AM, Meşe G, Li L, Sellitto C, Brink PR, Gong X, White TW. The cataract causing Cx50-S50P mutant inhibits Cx43 and intercellular communication in the lens epithelium. *Exp Cell Res.* 2009 Apr 1; 315(6):1063-75.
22. Alexander A M, Edward R and Dulce E C. Proline: The Distribution, Frequency, Positioning, and Common Functional Roles of Proline and Polyproline Sequences in the Human Proteome. *PLoS One* 2013; 8(1): e53785.
23. Agouti I, Badens C, Abouyoub A, Levy N, Bennani M. Molecular basis of beta-thalassemia in Morocco: possible origins of the molecular heterogeneity. *Genet Test.* 2008; 12(4):563-8.

24. Antonarakis SE, Irkin SH, Cheng TC, Scott AF, Sexton JP, Trusko SP, Charache S, Kazazian HH Jr. beta-Thalassemia in American Blacks: novel mutations in the "TATA" box and an acceptor splice site. *Proc Natl Acad Sci U S A*. 1984;81(4):1154
25. Vernet R. *La Mauritanie, des Origines au Début de l'Histoire*, Centre Cultural Francais, Nouakchott. 1986.

1. XXXX

2. XXXX

3. Mohebi M, Chenari S, Akbari A, Ghassemi F, Zarei-Ghanavati M, Fakhraie G, Babaie N, Heidari M. Mutation analysis of connexin 50 gene among Iranian families with autosomal dominant cataracts. *Iran J Basic Med Sci*. 2017; 20 (3):288-293.
4. Devi RR, Vijayalakshmi P. Novel mutations in GJA8 associated with autosomal dominant congenital cataract and microcornea. *Mol Vis* 2006; 12:190-5.
5. Zhu Y, Yu H, Wang W, Gong X, Yao K. A novel GJA8 mutation (p.V44A) causing autosomal dominant congenital cataract. *PLoS One*. 2014; 9(12):e115406.
6. Vanita V, Singh JR, Singh D, Varon R, Sperling K. A novel mutation in GJA8 associated with jellyfish-like cataract in a family of Indian origin. *Mol Vis* 2008; 14:323-6.
7. Minogue PJ, Tong JJ, Arora A, Russell-Eggitt I, Hunt DM, Moore AT, Ebihara L, Beyer EC, Berthoud VM. A mutant connexin50 with enhanced hemichannel function leads to cell death. *Invest Ophthalmol Vis Sci*. 2009; 50(12):5837-45.

8. Arora A, Minogue PJ, Liu X, Addison PK, Russel-Eggitt I, Webster AR, Hunt DM, Ebihara L, Beyer EC, Berthoud VM, Moore AT. A novel connexin50 mutation associated with congenital nuclear pulverulent cataracts. *J Med Genet* 2008; 45:155-60.
9. Li J, Wang Q, Fu Q, Zhu Y, Zhai Y, Yu Y, Zhang K, Yao K. A novel connexin 50 gene (gap junction protein, alpha 8) mutation associated with congenital nuclear and zonular pulverulent cataract. *Mol Vis*. 2013; 19:767-74.
10. Lin Y, Liu NN, Lei CT, Fan YC, Liu XQ, Yang Y, Wang JF, Liu B, Yang ZL. A novel GJA8 mutation in a Chinese family with autosomal dominant congenital cataract. *Zhonghua Yi Xue Yi ChuanXueZaZhi*. 2008; 25(1):59–62.
11. Berry V, Mackay D, Khaliq S, Francis PJ, Hameed A, Anwar K, Mehdi SQ, Newbold RJ, Ionides A, Shiels A, Moore T, Bhattacharya SS. Connexin 50 mutation in a family with congenital “zonular nuclear” pulverulent cataract of Pakistani origin. *Hum Genet* 1999; 105:168-70.
12. Yu Y, Wu M, Chen X, Zhu Y, Gong X, Yao K. Identification and functional analysis of two novel connexin 50 mutations associated with autosome dominant congenital cataracts. *SciRep*. 2016, 24; 6:26551.
13. Ma ZW, Zheng J, Yang F, Ji J, Li X, Tang X, Yuan X, Zhang X, Sun H. Two novel mutations of connexin genes in Chinese families with autosomal dominant congenital nuclear cataract. *Br J Ophthalmol* 2005; 89:1535-7.
14. Hansen L, Eiberg H, Rosenberg T. Novel MAF mutation in a family with congenital cataract-microcornea syndrome. *Mol Vis* 2007; 13:2019-22.
15. Reis LM, Tyler RC, Muheisen S, Raggio V, Salviati L, Han DP, Costakos D, Yonath H, Hall S, Power P, Semina EV. Whole exome sequencing in dominant cataract identifies a new causative factor, CRYBA2, and a variety of novel alleles in known genes. *Hum Genet*. 2013; 132(7):761-70.

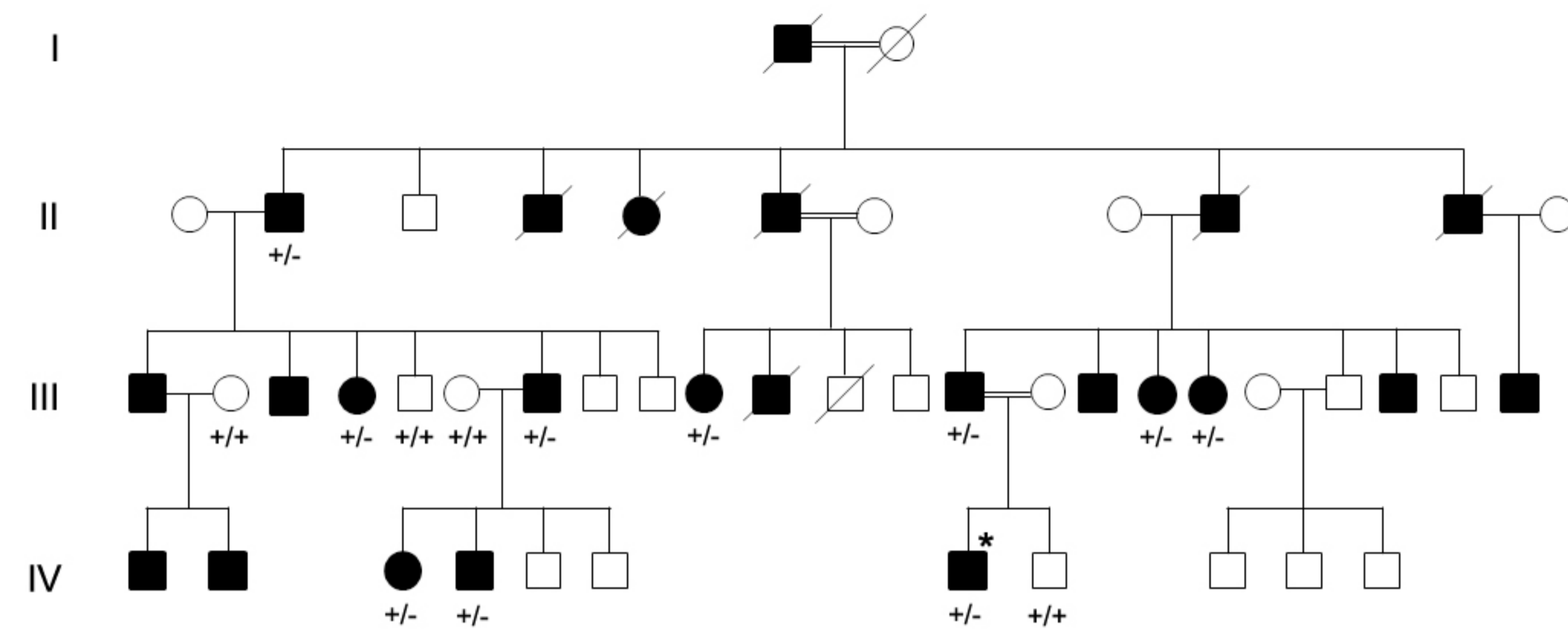
16. Vanita V, Hennies HC, Singh D, Nuernberg P, Sperling K, Singh JR. Novel mutation in GJA8 associated with autosomal dominant congenital cataract in a family of Indian origin. *Mol Vis* 2006; 12:1217-22.
17. Shiels A, Mackay D, Ionides A, Berry V, Moore A, Bhattacharya S. A missense mutation in the human connexin50 gene (GJA8) underlies autosomal dominant “zonular pulverulent” cataract, on chromosome 1q. *Am J Hum Genet* 1998; 62:526-32.
18. Arora A, Minogue PJ, Liu X, Reddy MA, Ainsworth JR, Bhattacharya SS, Webster AR, Hunt DM, Ebihara L, Moore AT, Beyer EC, Berthoud VM. A novel GJA8 mutation is associated with autosomal dominant lamellar pulverulent cataract: further evidence for gap junction dysfunction in human cataract. *J Med Genet* 2006; 43:e2.
19. Ge XL, Zhang Y, Wu Y, Lv J, Zhang W, Jin ZB, Qu J, Gu F. Identification of a novel GJA8 (Cx50) point mutation causes human dominant congenital cataracts. *Sci Rep*. 2014;4:4121.
20. Gillespie RL, O'Sullivan J, Ashworth J, Bhaskar S, Williams S, Biswas S2, Kehdi E, Ramsden SC, Clayton-Smith J, Black GC, Lloyd IC. Personalized diagnosis and management of congenital cataract by next-generation sequencing. *Ophthalmology*. 2014;121(11):2124-37.e1-2.
21. Sun W, Xiao X, Li S, Guo X, Zhang Q. Exome sequencing of 18 Chinese families with congenital cataracts: a new sight of the NHS gene. *PLoS One*. 2014; 9(6):e100455.
22. Patel N, Anand D, Monies D, Maddirevula S, Khan AO, Aldahmesh MA, Lachke SA, Alkuraya FS. Novel phenotypes and loci identified through clinical genomics approaches to pediatric cataract. *Hum Genet*. 2017;136(2):205-225.
23. Santana A, Waiswo M. The genetic and molecular basis of congenital cataract. *Arq Bras Oftalmol*. 2011;74(2):136–42.

24. Huang B, He W. Molecular characteristics of inherited congenital cataracts. *Eur J Med Genet.* 2010; 53(6):347–57.
25. Ponnampalani SP, Ramesha K, Matalia J, Tejwani S, Ramamurthy B, Kannabiran C. Mutational screening of Indian families with hereditary congenital cataract. *Mol Vis.* 2013, 29; 19:1141-8.
26. Hu S, Wang B, Zhou Z, Zhou G, Wang J, Ma X, Qi Y. A novel mutation in GJA8 causing congenital cataract-microcornea syndrome in a Chinese pedigree. *Mol Vis.* 2010;16:1585-92.
27. Ponnampalani SP, Ramesha K, Tejwani S, Ramamurthy B, Kannabiran C. Mutation of the gap junction protein alpha 8 (GJA8) gene causes autosomal recessive cataract. *J Med Genet* 2007; 44:e85.
28. Su D, Yang Z, Li Q, Guan L, Zhang H, Dandan E, Zhang L, Zhu S, Ma X. Identification and functional analysis of GJA8 mutation in a Chinese family with autosomal dominant perinuclear cataracts. *PLoS One.* 2013; 8(3):e59926.
29. Polyakov AV, Shagina IA, Khlebnikova OV, Evgrafov OV. Mutation in the connexin 50 gene (GJA8) in a Russian family with zonular pulverulent cataract. *Clin Genet.* 2001; 60(6):476-8.
30. Gao X, Cheng J, Lu C, Li X, Li F, Liu C, Zhang M, Zhu S, Ma X. A novel mutation in the connexin 50 gene (GJA8) associated with autosomal dominant congenital nuclear cataract in a Chinese family. *Curr Eye Res.* 2010;35(7):597- 604.
31. Schmidt W, Klopp N, Lillig T, Graw J. A novel GJA8 mutation causing a recessive triangular cataract. *Mol Vis* 2008; 14:851-6.
32. Zhou Z, Wang B, Hu S, Zhang C, Ma X, Qi Y. Genetic variations in GJA3, GJA8, LIM2, and age-related cataract in the Chinese population: a mutation screening study. *Mol Vis.* 2011;17:621-6.

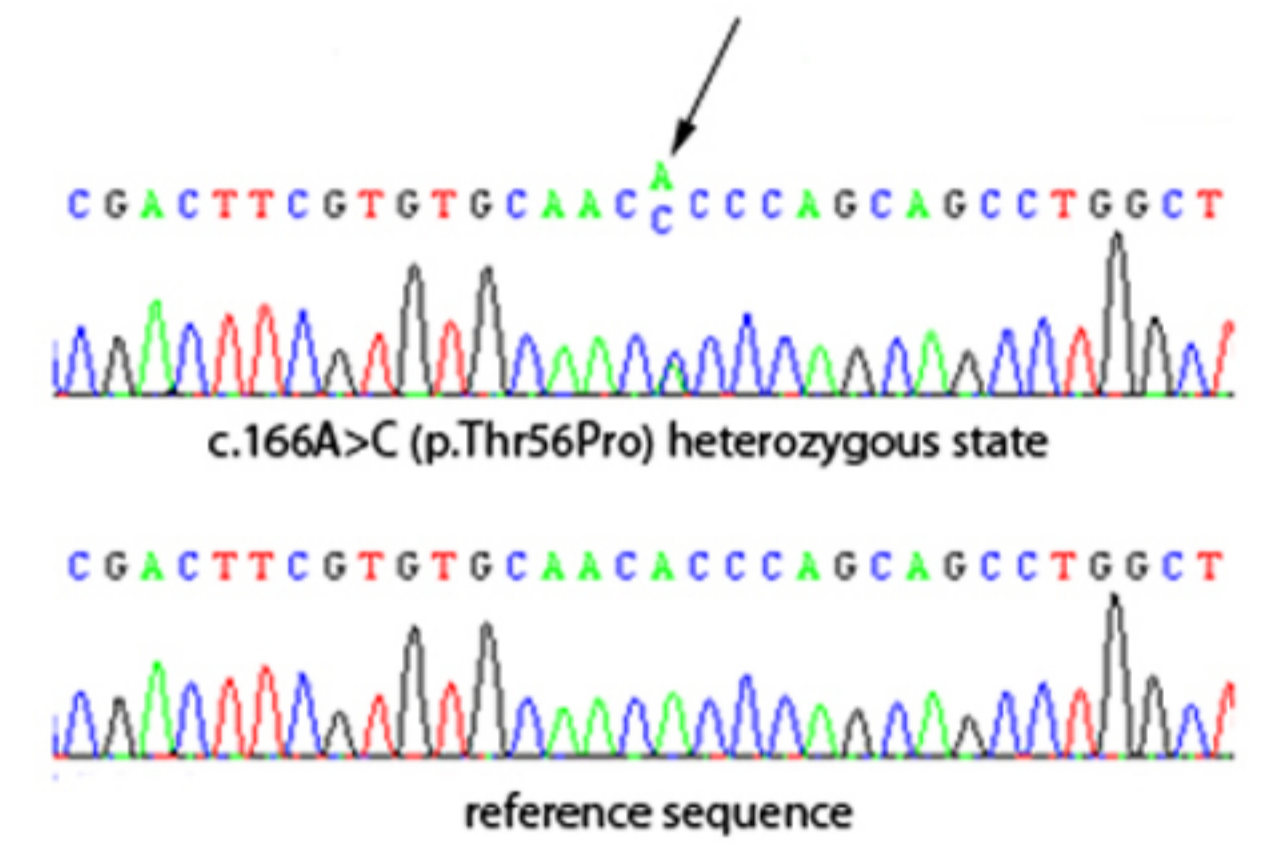


33. Yan M, Xiong C, Ye SQ, Chen Y, Ke M, Zheng F, Zhou X. A novel connexin 50 (GJA8) mutation in a Chinese family with a dominant congenital pulverulent nuclear cataract. *Mol Vis* 2008; 14:418-24.
34. Chen C, Sun Q, Gu M, Liu K, Sun Y, Xu X. A novel Cx50 (GJA8) p.H277Y mutation associated with autosomal dominant congenital cataract identified with targeted next-generation sequencing. *Graefes Arch ClinExpOphthalmol*. 2015; 253(6):915-24.
35. Kumar M1, Agarwal T, Khokhar S, Kumar M, Kaur P, Roy TS, Dada R. Mutation screening and genotype phenotype correlation of  $\alpha$ -crystallin,  $\gamma$ -crystallin and GJA8 gene in congenital cataract. *Mol Vis*. 2011 ;17:693-707.

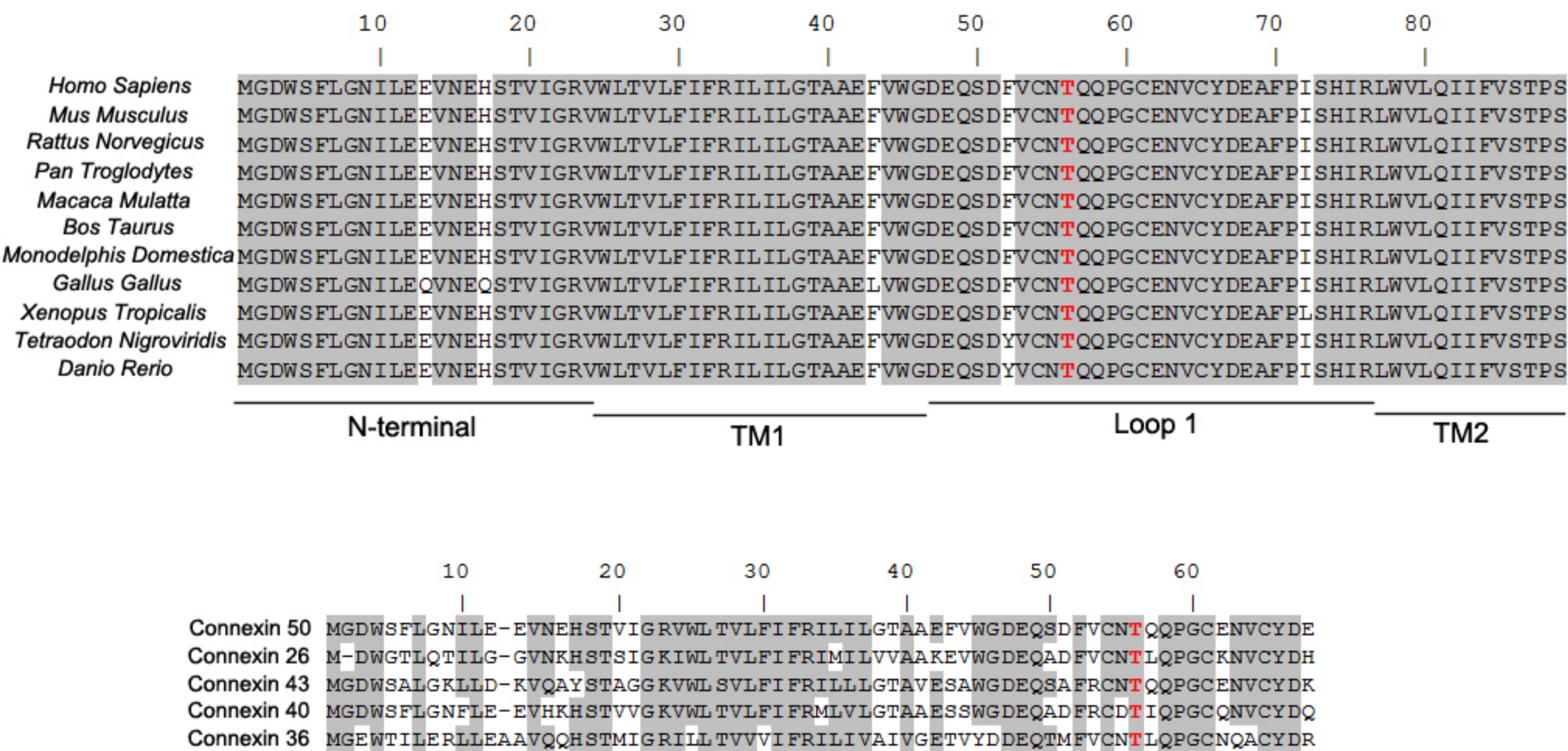
A



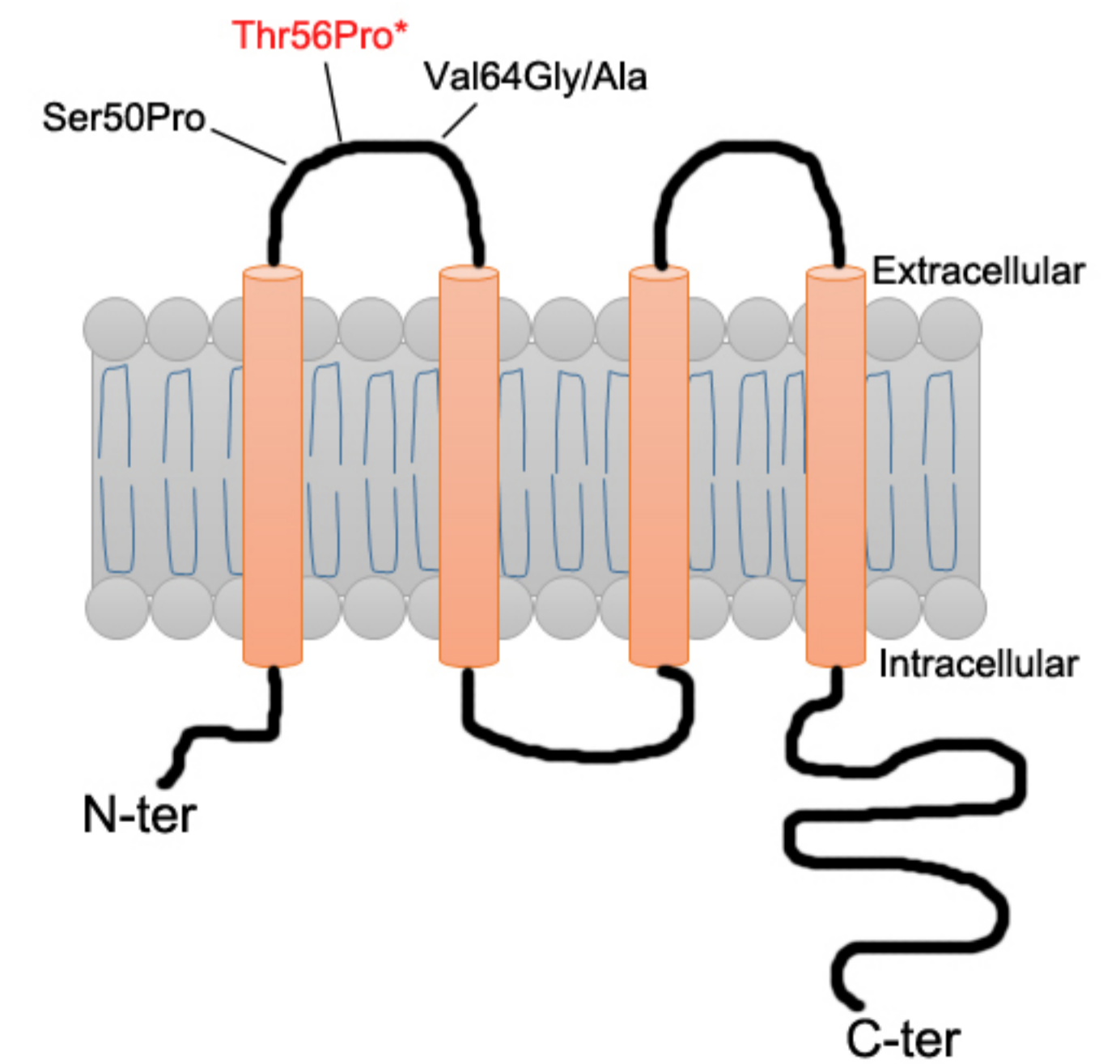
B



C

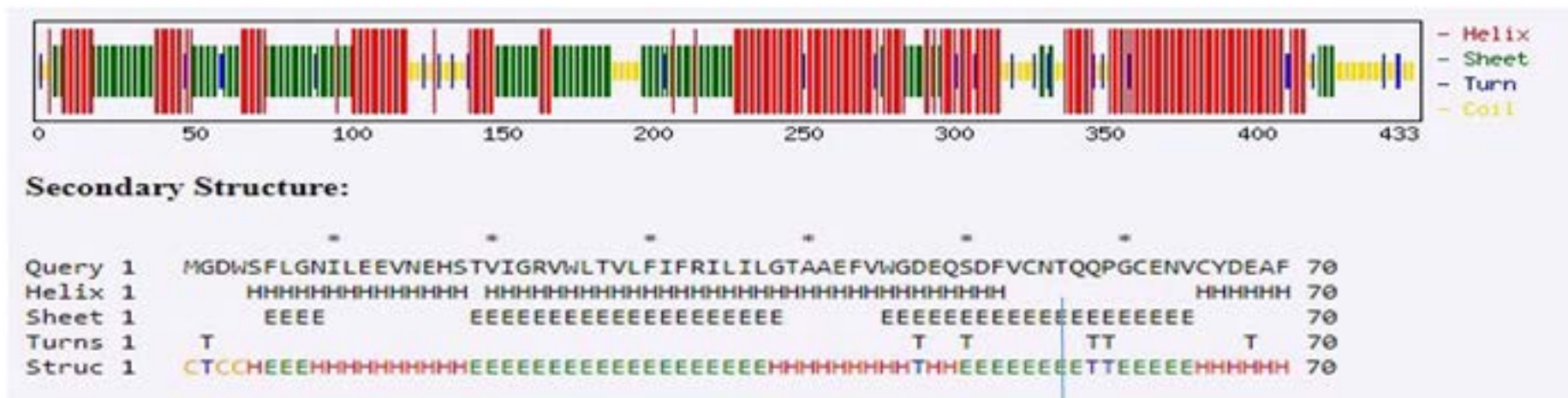


D





Wildtype



Mutant

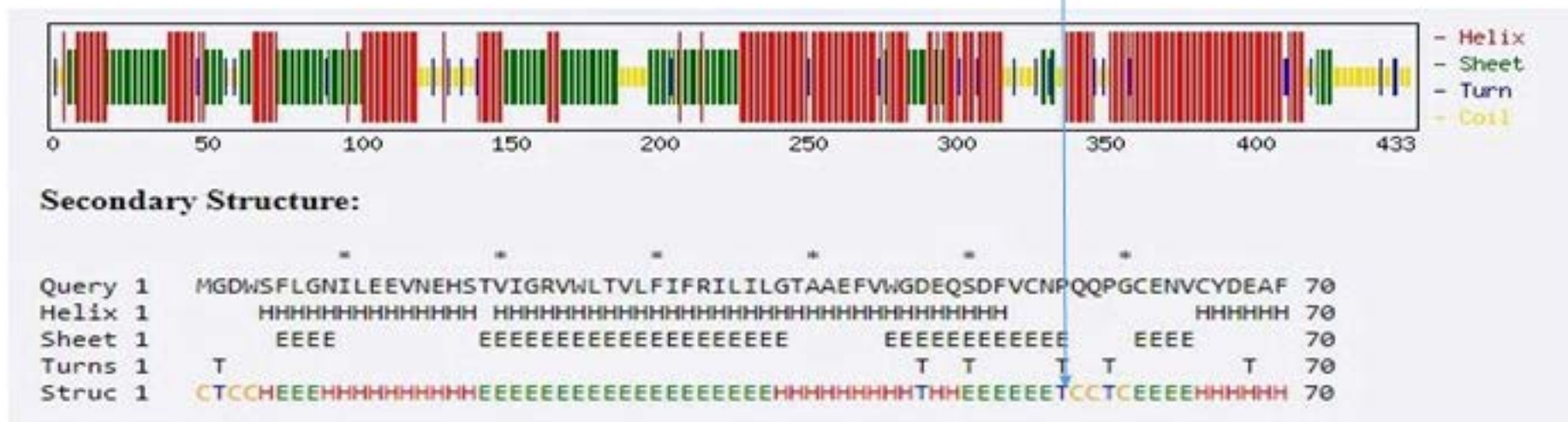


Figure 2

**Table 1:** List of novel and reported *GJA8* mutations associated with congenital cataract

Mutation	Amino acid change	Location	Cataract types	Inheritory	Family origin	Reference
c.20T>C	p.L7P	NT	Nuclear	AD	Caucasian	[8]
c.68G>C	p.R23T	NT	Nuclear	AD	Iranian	[9]
c.89dupT	p.fs	NT	Nuclear	AD	Caucasian	[10]
c.92T>C	p.I31T	M1	Nuclear	AD	Chinese	[11]
c.116C>G	p.T39R	M1	and microcoma and iris hypoplasia Cataract, microphthalmia, and sclerocornea	AD	Chinese	[12]
c.119C>T	p.Ala40Val	M1	Nuclear	AD	Caucasian	[10]
c.130G>A	p.V44M		Nuclear Cataract and microcoma	AD	Iranian	[26]
c.131T>A	p.V44E	M1	Suture-sparing nuclear	AD	Indian	[27]
c.131T>C	p.V44A	M1	Jellyfish-like bilateral and microcornea	AD	Chinese	[28]
c.134G>C	p.W45S	M1	cataract	AD	Indian	[29]
c.134G>T	p.W45L	M1	Complete and microcornea	AD	Iranian	[13]
c.136G>A	p.G46R	M1	Total cataract	AD	Chinese	[12]
c.137G>T	p.G46V	M1	Nuclear pulverulent	AD	Pakistani	[30]
c.139G>A	p.D47N	E1	Nuclear	AD	British	[31]
c.139G>T	p.D47Y	E1	Nuclear	AD	Chinese	[32]
c.139G>C	p.D47H	E1	Nuclear	AD	Chinese	[33]
c.142G>A	p.E48K	E1	Zonular nuclear pulverulent Cataract, microphthalmia, and sclerocornea	AD	Pakistani	[34]
c.151G>A	p.Asp51Asn	M1	Nuclear	AD	Caucasian	[10]
<b>c.166A&gt;C</b>	<b>p.T56P</b>	<b>E1</b>	<b>Nuclear</b>	<b>AD</b>	<b>Mauritania</b>	<b>This study</b>
c.175C > G	p.P59A	E1	Nuclear	AD	Chinese	[35]
c.191T>G	p.V64G	E1	Nuclear Various locations in the nucleus or the poles	AD	Chinese	[36]
c.218C>T	p.S73F	E1	Zonular pulverulent	AD	Danish	[37]
c.227G > A	p.R76 C	M2	Zonular pulverulent	AD	Chinese	[38]
c.227G > A	p.R76 H	M2	Zonular pulverulent " Full moon " Y-sutural opacity	AD	Chinese	[35]
c.235G>C	p.V79L	M2	Zonular pulverulent	AD	Indian	[39]
c.262C>T	p.P88S	M2	Lamellar pulverulent	AD	British	[40]
c.262C>A	p.P88Q	M2	Total cataract	AD	British	[41]
c.264C>T	p.P88T	M2	Cataract	AD	Chinese	[42]
c.293A>G	p.H98R	E2	Cataract	AD	UK	[43]
c.293A>C	p.H98P	E2	Cataract	AD	American	[8]
c.301G>T	p.R101L	E2	posterior polar cataract	AD	Iranian	[13]
c.367G>A	p.G123S	E2	Nuclear	AD	Chinese	[44]
c.460C>G	p.H154D	E2	Cataract	AD		[45]

c.565C>T	p.P189S	E2	Cataract and microcornea	AD	Brasil	[46]
c.566C>T	p.P189L	E2	Cataract and microcornea	AD	Danish	[37]
c.569A>G	p.N190S	E2	Cataract and microcornea	AD	Chinese	[47]
c.586G>A	p.V196M	E2	Cataract	AD	Indian	[48]
c.93G>A	p.R198Q	E2	Cataract and microcornea	AD	Indian	[27]
c.592C>T	p.R198W	E2	Cataract and microcornea	AD	Chinese	[49]
c.595C>T	p.P199S	E2	Cataract	AD	Indian	[50]
c.601G>A	p.E201K	E2	Perinuclear cataracts	AD	Chinese	[51]
c.607insA	p.203fs	E2	Cataract	AR	Indian	[48]
c.741T>G	p.I247M	CT	zonular pulverulent	AD	Russian	[52]
c.773C>T	p.S258F	CT	Nuclear	AD	Chinese	[53]
c.776insG	p.fs	CT	Triangular	AD	Germany	[54]
c.836C>A	p.S259Y	CT	Nuclear pulverulent	AD	Danish	[37]
c.823G>A	p.V275I		Cataract		Chinese	[55]
c.827C>T	p.S276F	CT	Nuclear pulverulent	AD	Chinese	[56]
c.829C>T	p.H277Y	CT	Nuclear pulverulent	AD	Chinese	[57]
c.905T>C	p.L278C	CT	Lamellar zonular	AD	Indian	[58]
c.842T>C	p.L281S	CT	Cataract, congenital		Indian	[58]
c.1273C>T	p.R425*	CT	Nuclear	AD	UK	[43]

Annotation variation

ID	concentration	ID-ZOC	possible diagnosis	1260	1280	260/280
D24	50,6ng/ul	QT2137	Cataracte	1,011	0,553	1,83

NGS informations

Sequencing depth	150 folders
Supporting Reads	%≥30%
Total Reads	≥10
dbSNP Allele Frequency	≤0.01

gene	Chromosome	position	variants	consequence	Zygosity	EXAC	HGMD	SIFT_prediction
GJA8	chr1	147380248	c.166A>C	p.(Thr56Pro)	hetero	no record	novel	Damaging

Polyphen2	Polyphen2	LRT_pred (	MutationTaster_pred
Possibly_d	Possibly_d	Deleterious	Disease_causing



<b>congenital cataract gene</b>	GJA8	CRYGC	CRYBB2
<b>gene that mutation caused phenotype accompany cataract</b>	ABHD12	ABHD5	ACTA2

**Appendix1. Genes associated with congenital cataract**

CRYGD	HSF4	EPHA2	CRYAA	CRYBA1	PITX3	BFSP2	GCNT2	GJA3
ADAMTS10	ADAMTS17	ADAMTSL4	AGK	ALDH18A1	ALDH1A3	APOA1	ASPH	B3GALT1

MIP	CRYAB	CRYBB1	FYCO1	LIM2	CRYGS	MAF	CRYBB3	CRYBA4
BCOR	BFSP1	BFSP2	BMP4	BUB1B	CHMP4B	CHRD1	CNBP	COL11A1

VIM	CHMP4B	BFSP1	TDRD7	AGK	CRYGB	NHS	WFS1	CRYBA2
COL11A2	COL18A1	COL2A1	COX14	COX7B	CRYAA	CRYAB	CRYBA1	CRYBA2

UNC45B	LSS							
CRYBA4	CRYBB1	CRYBB2	CRYBB3	CRYGB	CRYGC	CRYGD	CTDP1	CYP27A1

DPAGT1	EBP	ELP4	EPG5	EPHA2	ERCC5	ERCC6	ESCO2	EYA1

FAM111A	FAM126A	FBN1	FKRP	FLNB	FOXE3	FREM1	FTL	FYCO1

GALK1	GALT	GCNT2	GDF3	GFER	GJA3	GJA8	HCCS	HDAC6



HMGB3	HSF4	ISPD	JAM3	LIM2	LOXL1	MAF	MIP	NAA10

NHS	P3H2	PDE6D	PEX16	PEX7	PITX3	PTCH1	PTH	RARB

RDH11	RECQL4	SDHB	SDHD	SEC23A	SIL1	SIX3	SIX5	SLC16A12

SLC33A1	SLC4A4	SMOC1	SORD	SOX2	SRD5A3	TBC1D20	TBC1D32	TDRD7

TENM3	TMEM114	TMEM127	TMEM5	TMEM98	TMX3	UNC45B	VAX1	VIM

VLDLR	VSX2	WNT3	WRN	WT1