



**HAL**  
open science

## Reversible mechanical atrioventricular block during cryoablation for paroxysmal atrial fibrillation with a 28 mm balloon

Joel Fedida, Nicolas Badenco, Estelle Gandjbakhch, Xavier Waintraub, Françoise Hidden-Lucet, Guillaume Duthoit

### ► To cite this version:

Joel Fedida, Nicolas Badenco, Estelle Gandjbakhch, Xavier Waintraub, Françoise Hidden-Lucet, et al.. Reversible mechanical atrioventricular block during cryoablation for paroxysmal atrial fibrillation with a 28 mm balloon. *HeartRhythm Case Reports*, 2019, 5 (1), pp.15-16. 10.1016/j.hrcre.2018.09.009 . hal-02018048

**HAL Id: hal-02018048**

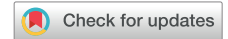**<https://hal.sorbonne-universite.fr/hal-02018048>**

Submitted on 13 Feb 2019

**HAL** is a multi-disciplinary open access archive for the deposit and dissemination of scientific research documents, whether they are published or not. The documents may come from teaching and research institutions in France or abroad, or from public or private research centers.

L'archive ouverte pluridisciplinaire **HAL**, est destinée au dépôt et à la diffusion de documents scientifiques de niveau recherche, publiés ou non, émanant des établissements d'enseignement et de recherche français ou étrangers, des laboratoires publics ou privés.

# Reversible mechanical atrioventricular block during cryoablation for paroxysmal atrial fibrillation with a 28 mm balloon



Joël Fedida, MD,<sup>\*†</sup> Nicolas Badenco, MD,<sup>\*</sup> Estelle Gandjbakhch, MD, PhD,<sup>\*†</sup>  
Xavier Waintraub, MD,<sup>\*</sup> Françoise Hidden-Lucet, MD,<sup>\*</sup> Guillaume Duthoit, MD<sup>\*</sup>

From the <sup>\*</sup>Institut de Cardiologie, AP-HP, Groupe Hospitalier Pitié-Salpêtrière, Paris, France, and <sup>†</sup>UPMC Univ Paris 06, Sorbonne Universités, Paris, France.

## Introduction

Cryoablation of paroxysmal atrial fibrillation is an increasingly common procedure for treatment of symptomatic patients after failure of or intolerance to antiarrhythmic drug therapy. Atrioventricular (AV) block during cryoablation therapy is an uncommon complication. We present a case of a transient mechanical AV block occurring during manipulation of a 28 mm cryoballoon catheter before cryoenergy delivery around the right inferior pulmonary vein (RIPV). The main hypothesis is a mechanical bump of the AV node.

## Case report

A 52-year-old woman was referred to our center for cryoablation under general anesthesia for symptomatic paroxysmal atrial fibrillation ablation with history of documented atrial flutter. Preablation computed tomography (CT) scan showed normal pulmonary vein distribution (Figure 1A) and electrocardiography showed complete right bundle branch block.

After transeptal puncture, left pulmonary vein isolation was performed using a 28 mm cryoballoon (Arctic Front Advance, Medtronic, Minneapolis, MN), after a single application for each vein. Then, the catheter was advanced to the RIPV with the support of an Achieve catheter (Medtronic). The balloon was inflated in order to isolate the RIPV, but total RIPV occlusion with selective contrast injection was difficult to obtain with persistence of an inferior RIPV leak. A pull-back maneuver allowed to obtain a total occlusion (Figure 1A). During this manipulation, and before cryoablation, a complete AV block occurred with an escape rhythm of 40 beats per minute with pre-existing right bundle branch block (Figure 1B, top). Despite a 30-minute waiting time and intravenous injection of 100 mg hydrocortisone, AV block remained complete. The procedure was continued to

## KEY TEACHING POINTS

- Atrioventricular (AV) block is a rare complication of cryoablation for paroxysmal atrial fibrillation.
- It can occur with manipulation of a 28 mm cryoballoon around the right inferior pulmonary vein (RIPV) in a small left atrium. Careful electrocardiogram monitoring during manipulation or cryoablation delivery around the RIPV is necessary to watch for occurrence of AV block.
- Other possible mechanisms of AV block during cryoablation procedure are vagal reaction due to freezing/thawing; inadvertent ganglionated plexus cryoablation/modulation; AV node artery vasospasm or coronary embolism due to air bubble migration, either in the right coronary or in the left circumflex artery, induced by sheath or balloon flushing; and mechanical bump of the AV node, as reported here.

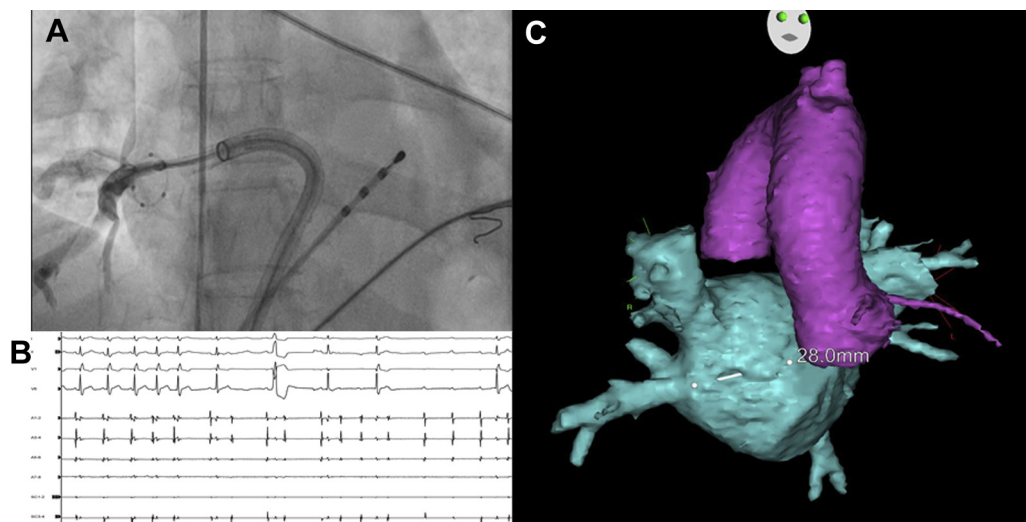
isolate the right superior pulmonary vein, but neither cavotricuspid isthmus line with radiofrequency energy nor RIPV isolation was retried for safety reasons, to avoid delivery of permanent lesions in the AV node region owing to absence of AV conduction monitoring. Forty-five minutes later AV block spontaneously resolved when the patient woke up, during extubation.

## Discussion

AV block during cryoablation is a rare complication. Fonseca and colleagues<sup>1</sup> described the only actual case of AV block, but it occurred during delivery of cryoenergy in the RIPV with a 28-mm balloon. They hypothesized that AV node ischemia was the most probable mechanism, as artery coronary angiography performed 30 minutes after AV block

**KEYWORDS** Atrial fibrillation; Ablation; AV block; Cryoballoon; Cryoenergy; Left atrium; Right inferior pulmonary vein (Heart Rhythm Case Reports 2019;5:15–16)

**Address reprint requests and correspondence:** Dr Joël Fedida, Département de Cardiologie, AP-HP, Hôpital Pitié-Salpêtrière, 47-83 bld de l'Hôpital, 75013, Paris, France. E-mail address: [fedidajoel@gmail.com](mailto:fedidajoel@gmail.com).



**Figure 1** **A:** Anteroposterior fluoroscopy view showing total occlusion of the right inferior pulmonary vein (RIPV) during selective angiography. **B:** Electrocardiogram and electrogram of the RIPV (A1–2 to A7–8) and the coronary sinus (SC 1–2, SC 3–4) showing atrioventricular (AV) block during manipulation of the 28 mm cryoballoon catheter as shown in panel A. **C:** Computed tomography scan reconstruction showing a short distance between the RIPV ostium and aortic annulus at proximity of the AV node region.

showed a patent AV node artery originating from the right coronary artery. In our case, the short distance between the RIPV ostium and aortic annulus at proximity of the AV node region, shown by CT scan reconstruction, could explain mechanical AV block during manipulation of the 28 mm cryoballoon catheter (13F) (Figure 1C). This could be due to a mechanical bump of the interatrial septum and crux cordis, but also to the left-sided pathway of the AV node. Data for comparison with CT scan reconstruction are needed to confirm this hypothesis.

Others possible mechanisms of AV block during cryoablation procedure are summarized as follows: (1) vagal reaction owing to freezing/thawing; (2) inadvertent ganglionated plexus cryoablation/modulation; (3) AV node artery vasospasm (as described by Fonseca and colleagues<sup>1</sup>) or coronary embolism owing to air bubble migration, either in the right

coronary or in the left circumflex artery,<sup>2</sup> induced by sheath or balloon flushing; and (4) mechanical bump of the AV node, as reported here.

## Conclusion

Our case highlights the importance of carefully monitoring AV conduction during cryoablation, especially with the use of a 28 mm cryoballoon catheter during RIPV isolation in small atria.

## References

1. Fonseca WP, Pisani CF, Lara S, Scanavacca M. Transient complete atrioventricular block during catheter balloon cryoablation of atrial fibrillation: a case report. *Europace* 2017;19:1943.
2. Kawashima T, Sato F. Clarifying the anatomy of the atrioventricular node artery. *Int J Cardiol* 2018;269:158–164.