



HAL
open science

Surgical internal iliac artery preservation associated with endovascular repair of infrarenal aortoiliac aneurysms to avoid buttock claudication and distal type I endoleaks

Julien Gaudric, Philippe Tresson, Lucie Derycke, Sophie Tezenas Du Montcel, Thibault Couture, Jean-Michel Davaine, Mahine Kashi, James Lawton, Laurent Chiche, Fabien Koskas

► To cite this version:

Julien Gaudric, Philippe Tresson, Lucie Derycke, Sophie Tezenas Du Montcel, Thibault Couture, et al.. Surgical internal iliac artery preservation associated with endovascular repair of infrarenal aortoiliac aneurysms to avoid buttock claudication and distal type I endoleaks. *Journal of Vascular Surgery*, 2018, 68 (6), pp.1736-1743. 10.1016/j.jvs.2018.03.416 . hal-02093948

HAL Id: hal-02093948

<https://hal.sorbonne-universite.fr/hal-02093948>

Submitted on 9 Apr 2019

HAL is a multi-disciplinary open access archive for the deposit and dissemination of scientific research documents, whether they are published or not. The documents may come from teaching and research institutions in France or abroad, or from public or private research centers.

L'archive ouverte pluridisciplinaire **HAL**, est destinée au dépôt et à la diffusion de documents scientifiques de niveau recherche, publiés ou non, émanant des établissements d'enseignement et de recherche français ou étrangers, des laboratoires publics ou privés.

1 **Surgical internal iliac artery preservation associated to endovascular repair of infrarenal**
2 **aortoiliac aneurysms to avoid buttock claudication and distal type I endoleaks.**

3

4

5 Julien Gaudric^a, Philippe Tresson^a, Lucie Derycke^a, Sophie Tezenas Du Montcel^b, Thibault
6 Couture^a, Jean-Michel Davaine^a, Mahine Kashi^a, James Lawton^a, Laurent Chiche^a, Fabien
7 Koskas^a.

8

9 From the ^aDepartment of Vascular Surgery, Pitié-Salpêtrière Hospital, UPMC Paris 06, Paris,
10 France and ^b Biostatistics Department, Pitié-Salpêtrière Hospital, UPMC Paris 06, UMR_S1136 ;
11 INSERM UMR_S1136, Institut Pierre Louis d'Epidémiologie et de Santé Publique, Paris,
12 France.

13

14

15 **Corresponding author:** Julien Gaudric. Service de Chirurgie Vasculaire, Hôpital Pitié-Salpêtrière,
16 47-83, bd de l'Hôpital, 75013 Paris, France.
17 E-mail : jgaudric@gmail.com

18

19 **Abstract**

20 Objectives

21 To assess outcomes of a hybrid technique consisting in treating abdominal aortic aneurysm
22 (AAA) associated with iliac aneurysm without distal neck, by combining an AAA endovascular
23 repair approach with open surgery for preserving internal iliac artery (IIA).

1 Methods

2 The files of 51 patients operated between 1998 and 2017 in a single vascular surgery department
3 were retrospectively analyzed. Inclusion criteria were patients with AAA associated with uni- or
4 bi-iliac aneurysm without suitable distal sealing zone. Surgery consisted in deploying an aorto-
5 uni-iliac stent-graft combined with an extra-anatomical crossover prosthetic bypass. Using a
6 limited retroperitoneal approach, the contralateral proximal common iliac aneurysm was
7 surgically excluded and the IIA revascularized by direct ilio-iliac anastomosis or terminal
8 common iliac suture preserving the iliac bifurcation.

9 Results

10 Patient mean age was 74 years (58-88) and 92% were men. The mean follow-up was 5.8 years
11 (0.1-18). Twenty-nine patients (57%) had one or more high-risk criteria for open surgery.
12 Nineteen patients (37.3%) had aorto-uni-iliac aneurysms, 19 (37.3%) aorto-bi-iliac aneurysms, 5
13 (10%) isolated iliac aneurysms and 8 (15.7%) bi-iliac aneurysms without aortic location. Four
14 patients (7.8%) also had IIA aneurysms. Surgery was successful in all cases. Two patients (4%)
15 died during the 30 days after surgery. One surgically-preserved IIA occluded within the first
16 month resulting in buttock claudication. The 5-year IIA primary patency rate was 96%. Type I
17 proximal endoleaks occurred in 2 patients requiring additional surgery 3 and 13 years after the
18 initial surgery, respectively.

19 Conclusion

20 This hybrid technique, consisting in AAA endovascular exclusion combined with open IIA
21 revascularization, is safe and effective to preserve pelvic vascularization. It is associated with
22 long-term patency and low morbidity rates. We have been using this technique before the advent
23 of branched dedicated devices allowing to the preservation of IIA with good results. And this

1 technique should continue to be proposed, especially in patients not eligible for endovascular
2 iliac branch repair due to anatomical contraindications, to avoid pelvic ischemia if IIA has to be
3 sacrificed.

4

5 **Introduction**

6 Endovascular repair of abdominal aortic aneurysms (AAA) results in a lower early morbidity in
7 high-risk patients compared to open surgery¹⁻³. However, endovascular repair is sometimes
8 limited by anatomical constraints resulting in the inability of the stent-graft to properly exclude
9 the AAA because of high-flow endoleaks. AAA endovascular repair extended to common iliac
10 arteries requires dedicated devices to preserve internal iliac arteries (IIA) or IIA embolization to
11 avoid distal type I endoleaks. The loss of one or both IIA exposes to a higher risk of pelvis
12 ischemia such as colonic ischemia, buttock claudication and erectile dysfunction⁴. The hybrid
13 technique we present combines an endovascular approach to treat the AAA and an open
14 technique to preserve at least one IIA. The aim of this study was to assess the morbidity and
15 mortality associated with the use of this hybrid technique and its efficacy in maintaining IIA
16 long-term patency.

17

18 **Material and methods**

19 A retrospective study was conducted to analyze outcomes of endovascular repair in a series of
20 patients who underwent AAA endovascular repair combined with surgical preservation of at
21 least one IIA. Surgery was performed in a single tertiary vascular surgery referral center. Clinical
22 and demographic data as well as aneurysm features and surgical techniques were analyzed.

1 Indication for aneurysm surgery was either an AAA diameter larger than 50 mm or a common
2 iliac artery diameter larger than 30 mm. No emergency cases were included.
3 Follow-up visits were planned 1 and 6 months after surgery and annually thereafter. They
4 included clinical examination, CT-scan and Doppler ultrasonography. Technical success rate and
5 early or late complications were reported according to reporting standards of the Ad Hoc
6 committee for Standardized Reporting Practices in Vascular Surgery/International Society for
7 Cardiovascular Surgery^{5,6}. In this reporting, mortality was defined as "early" when it occurred
8 before day 30. Three types of complications were defined (systemic, local non-vascular or
9 vascular and implant-related) and three severity grades were used (mild, moderate or severe).
10 Statistical analyzes were carried out using SAS 9.4 software. All tests were two-sided and P-
11 values less than 0.05 were considered statistically significant. Descriptive analysis was
12 performed and data are presented as a mean \pm standard deviation or frequencies (percent)
13 depending of variable nature. Survival data were assessed using Kaplan Meier curves.

14

15 **Surgical technique**

16 When one of the two distal iliac necks was unfit for bifurcated endograft use, AAA endovascular
17 exclusion was performed with aorto uni-iliac stent-graft. The stent-graft was always inserted on
18 the side which had an adequate common iliac sealing zone (iliac neck length greater than 10 mm,
19 non-conical and with a maximum diameter less than 20 mm), using a short longitudinal groin
20 incision, allowing preserving the ipsilateral IIA. The contralateral limb was revascularized
21 through a prosthetic crossover femoro-femoral or femoro-external iliac bypass. In case of iliac
22 anastomosis, graft was tunneled through the Retzius space and described a large loop in the
23 retroperitoneum to avoid kinking. In order to preserve contralateral IIA, a retroperitoneal

1 approach was used on the other side. The contralateral femoral approach was extended to a
2 pararectal incision without transecting the inguinal ligament. Then, the iliac bifurcation was
3 controlled (figure 1). The proximal common iliac clamping was facilitated by the low pressure
4 inside the aneurysmal sac obtained after proximal exclusion by the stentgraft. And the common
5 iliac aneurysm was transversally cut off above the bifurcation. The proximal end was sutured
6 with 3/0 back-and-forth suture on a felt strip (figure 2). When the iliac bifurcation was spared by
7 aneurysm dilation, a simple suture of the distal end was performed (AAA class D, according to
8 EUROSTAR classification⁷) (figure 3). When the iliac bifurcation was included in the aneurysm
9 dilation (AAA class E), the external iliac and IIA were divided and end-to-end anastomozed
10 (figure 4a and b).

11 Ethical Approval for Research and informed consent were obtained for the whole series as well
12 as for every individual patient.

13

14 **Results**

15 From 1998 to 2017, 51 patients (92% of men) with a mean age of 74 years (58-88) were
16 included. During the study period, 3173 AAA were treated at our centre, including 2230 treated
17 with open repair and 943 with endovascular repair. Clinical and demographic data are shown in
18 table I.

19 Twenty-nine patients (57%) had one or more high-risk criteria for open surgery. Thirteen
20 patients (25%) were more than 80 years old. Twenty-three patients (45%) had preoperative renal
21 failure with an estimated glomerular filtration rate less than 60 mL/min (Cockroft formula).
22 Nineteen patients (37.3%) had aorto-uni-iliac aneurysm, 19 (37.3%) aorto-bi-iliac aneurysm, 5
23 (10%) isolated iliac aneurysm and 8 (15.7%) bi-iliac aneurysm without aortic location. The mean

1 abdominal aortic diameter was 47.5 mm (range 16 to 71). The mean diameter of the common
2 iliac artery, ipsilateral to the stent-graft, was 17.9 mm (range 10 to 26). All ipsilateral common
3 iliac arteries had a distal landing zone of more than 10 mm. The mean diameter of the
4 contralateral common iliac artery, that was surgically excluded, was 29.5 mm (range 18 to 62).
5 Four patients (7.8%) also had proximal IIA aneurysm and in these cases the crossover prosthetic
6 bypass was directly anastomosed on the distal IIA after aneurysm exclusion and the external iliac
7 artery was re-implanted into the crossover bypass. Only one patient had a non-patent ipsilateral
8 IIA prior to surgery; in this later case, the contralateral IIA was surgically preserved.

9 Home-made devices have been developed in our unit since the beginning of the endovascular
10 experience. Briefly the device consisted in aorto mono iliac stentgraft including stents and textile
11 of variable diameter designed to fit with the aneurysmal sac⁸. These homemade endografts used
12 commercially available textile and stents. The aim was to use surgical-like textile to avoid
13 porosity of thinner ones and to provide a morpho-adjusted device to fill the empty space of the
14 aneurysmal sac, as last generations of endovascular aneurysm sealing system do. Forty-two
15 stent-grafts were home-made devices based on Gianturco Z stents (Z stent, Cook Inc,
16 Bloomington, Ind) coated with vascutek Gelweave fabric (Terumo company, Glasgow, United
17 Kingdom). These devices were used until year 2010. Then, seven aorto-uni iliac Endurant and 2
18 aorto-uni iliac Talent stent-grafts (Medtronic, Dublin, Ireland) devices were used during the last
19 period (from 2010 to 2017) (figure 5). The mean proximal stent-graft diameter was 26 mm (20-
20 36) and the mean distal stent-graft diameter was 18 mm (9-24). An extra-anatomical bypass was
21 performed in all patients: ilio-external iliac in 11 patients, femoro-femoral in 14, femoro-external
22 iliac in 24, and femoro-IIA in 2. A Dacron tube with a mean diameter of 10 mm (8-12) was used
23 for the bypass.

1 In 27 cases (53%), the iliac bifurcation was preserved and the distal common iliac artery was
2 only sutured. In the remaining 24 cases (47%), the iliac bifurcation was aneurysmal and an end-
3 to-end anastomosis was performed between the external iliac artery and the IIA prior to the
4 extra-anatomical bypass.

5 Surgery was successful in all cases. On completion angiography, the IIA was patent in all cases.

6

7 **Short-term complications (day 30)**

8 The 30-day postoperative mortality rate was 4%: 2 patients died from massive heart attack within
9 2 days of surgery, one after a pace-maker dysfunction and one after acute respiratory failure
10 secondary to complete lung atelectasis.

11 One patient developed acute mesenteric ischemia due to a cholesterol embolization syndrome
12 and required cholecystectomy and colectomy with ileostomy at day 7. Two patients had a wound
13 infection requiring secondary surgical intervention for drainage and Sartorius myoplasty. In
14 another patient, a preserved IIA occluded within the first month resulting in buttock claudication.
15 Finally, 2 patients (4,1%) experienced type II endoleak identified on post op CT scan.

16

17 **Long-term follow-up and patient evolution**

18 The mean follow-up was 5.8 years (0.1-18). The 5-year IIA primary patency rate was 96%.

19 No secondary dilation was observed in the neo-iliac bifurcation during follow-up.

20 One aortic stent-graft occluded 15 years after surgery and was treated with an axillo-bifemoral
21 bypass.

22 An endoleak occurred in 7 patients (14.3%) at various time points after surgery. Five endoleaks
23 were type II, of which 4 were successfully embolized. Embolization was indicated when

1 aneurysm diameter increased by more than 1 cm or more than 5mm per 6 months. Two type I
2 proximal endoleaks occurred in 2 patients and required additional surgery. In one patient, the
3 stent-graft was only partially removed and an aortic bypass between the infra-renal aortic neck
4 and the previous stent-graft was performed 3 years after implantation. In the other patient, the
5 stent-graft was totally removed and an open surgical aorto bi-iliac bypass was performed 13
6 years after the initial surgery. In these two cases no endovascular conversion was available.
7 During follow-up, 31 patients (60.1%) died from non-vascular causes in addition to the 2 patients
8 who died during the peri-operative period. The 5-year survival rate was 52.1% (figure 6). Four
9 patients were lost to follow-up at 0.1, 3.4, 3.6 and 3.9 years.

10

11 **Discussion**

12 In this study, we used a hybrid technique combining AAA endovascular exclusion to IIA open
13 revascularization and demonstrated its long-term efficacy on patency and safety on pelvic
14 revascularization.

15 It is usually accepted that endovascular treatment is less invasive than open surgical repair⁹⁻¹¹,
16 especially when iliac arteries are involved¹². However, the endovascular treatment of AAA
17 extended to iliac aneurysms may be responsible for inadequate distal sealing resulting in high-
18 flow endoleaks precluding AAA exclusion success. This issue is not uncommon since iliac
19 aneurysms are associated with AAA in 20-30% of cases¹³. Several studies have shown that an
20 inadequate distal sealing zone was responsible for a high re-operation rate during follow-up of
21 patients who underwent endovascular aneurysm repair (EVAR). For instance, when common
22 iliac aneurysm extends to the bifurcation, AAA-related complications occur more commonly and

1 secondary interventions are more frequently needed. Distal type I endoleak and stent-graft
2 thrombosis are more common in these patients^{14,15}.

3 Moreover even when the aneurysm does not involve the iliac bifurcation, the common iliac
4 artery tends to significantly dilate after EVAR, especially in case of ectatic iliac arteries¹⁶.

5 Other endovascular techniques have been proposed to overcome the risk of endoleak in case of
6 inadequate sealing zone, including short, tortuous or conical distal neck.

7 The most common technique consists in embolizing and then covering IIA with stent-graft to
8 reach an external iliac sealing zone. This technique has well-known complications. Buttock
9 claudication occurs in about 28% of cases^{4,17} and its resolution has been reported in only 48.0%
10 of cases after 21.8 months in a recent meta-analysis⁴. The proportion of buttock claudication may
11 reach 42% in case of bilateral embolization¹⁷.

12 To prevent IIA occlusion, other techniques have been developed but endoleaks may still occur in
13 some cases: the Bell-bottom technique consists in deploying an iliac flared endograft limb in
14 large common iliac arteries. But it may only be performed in case of moderately dilated common
15 iliac arteries (20 mm for the Cook Zenith Flex® and 25 mm for the Gore Excluder® and
16 Endurant II®). Although ectatic iliac arteries appear to be suitable sealing zones in the short
17 term, the long-term follow-up is of concern. Indeed, the dilation of ectatic common iliac arteries
18 is frequent after EVAR¹⁶. Recent studies have shown that these techniques are associated with a
19 significant risk of iliac limb complication (type I or III endoleaks: 4%)¹⁸ and the long-term
20 outcomes are uncertain.

21 Other totally endovascular techniques using non specific dedicated devices have been described.
22 For instance, retrograde endovascular IIA preservation is a hybrid technique consisting in
23 performing an endovascular external-to-internal iliac artery bypass with a covered stent

1 associated with an aorto-mono-iliac stentgraft procedure and a femfem bypass. It has been shown
2 to be associated with a 4-year rate of endoleaks or occlusion of 14.3%¹⁹. A limited number of
3 cases are described in the literature and the long term outcomes are of concern.

4 New dedicated devices are commercially available to ensure a good distal sealing zone while
5 preserving IIA patency, including the Zenith Branch Endovascular Graft Iliac Bifurcation device
6 (Zbis, Cook medical Boominghton, Ind) and the Iliac branch Excluder (IBE, Gore, Flagstaff,
7 AZ).

8 These two devices are strongly dependent on iliac aneurysm morphology as described in the
9 instructions for use (IFU). They are indicated in aorto-iliac aneurysms without distal neck. In
10 France, their indication is restricted to the preservation of only one IIA when both IIA may
11 undergo occlusion.

12 The Z-bis stent-graft (Cook) requires a non-aneurysmal external iliac artery with a diameter large
13 enough (8-11 mm) to get through a 20 Fr sheath and a landing zone length of at least 20 mm.

14 The IIA should have a distal neck of at least 10 mm and a diameter compatible with the
15 commercially available bridging stents. Moreover, the iliac bifurcation should be larger than 16
16 mm to avoid a conflict between the two legs of the bifurcated stent-graft.

17 The IBE (Gore) requires a common iliac artery diameter larger than 17 mm, an external iliac
18 artery with a diameter ranging between 6.5 and 13.5 mm, and an IIA diameter ranging between
19 6.5 and 13.5 mm. The IIA and external iliac artery landing zone should be longer than 10 mm.

20 The exclusive endovascular approach is thus restricted to selected cases²⁰ to be effective
21 ((minimal iliac tortuosity, minimum length and diameter of the common iliac artery, non stenotic
22 IIA).

1 Indeed, two studies have reported that the anatomical suitability for one of the two iliac branched
2 devices available was limited to 35-39.8% of patients based on the IFU^{21,22}. For IBE (Gore) or
3 Zbis (Cook) stent-graft alone, the anatomical suitability was of 25.3% and 18.2%, respectively²².
4 However in patients who could receive this branched stent-graft, the technical success reached
5 85-100%^{20,23-25}. This technique has good initial results when anatomical recommendations are
6 respected. But when the IFU are not respected, in case of peroperative technical difficulties or
7 IIA proximal stenosis, Delay et al have shown that thrombosis may occur²⁶. In the long term, IIA
8 branch occlusion has been reported in 9.3% of patients after a mean follow-up of 26.6 months
9 and secondary surgery was needed in 24.1% of cases at 5 years²⁴. In another study, a
10 significant rate of limb occlusion of 12% was reported during follow-up, responsible for
11 buttock claudication in half of the cases²⁰.

12 It thus appears that although the importance of preserving the IIA while preventing the
13 occurrence of endoleaks has been shown²⁷, there is no consensus about the best technique
14 (endovascular or open repair) to be used to achieve these results.

15 The strategy we describe was implemented before emergence of branched devices dedicated to
16 IIA. Branched devices have been available in France with reimbursement only since March
17 2013, that is why the majority of cases were fulfilled before this date. The acceptable results we
18 obtained led us to continue to use this technique when anatomical contraindications avoided us to
19 use branched devices. Its use has made it possible to develop a simple technique. It requires 2
20 vascular approaches: a scarpa approach and a retroperitoneal iliac pathway. These classical
21 vascular approaches are regularly used in open surgery and make them a reproducible technique.
22 Considering the good results of dedicated branched devices we should advise to use
23 endovascular technique first when IFU are respected, and to consider hybrid surgical

1 preservation technique when they are not, instead of embolization or non dedicated devices use.
2 The technique we describe showed a mortality rate of 4% but the patient we treated were high
3 risk patients: 51% were ASA 3 or more, mean age was 74 (+/-8) y and 25% were older than 80 y.
4 In this context, we considered that this technique resulted in a low morbidity rate and appeared to
5 be especially indicated in patients who are not eligible for endovascular iliac repair due to
6 anatomical contraindications.
7 Our hybrid procedure consisted in simple common iliac closure in half of cases where aneurysm
8 ended just above the iliac bifurcation (figure 3). In the other cases, the external iliac and IIA
9 were divided and end-to-end anastomozed with minimal IIA mobilization (figure 4b) in order to
10 exclude any pathologic tissue. With this technique, no secondary iliac bifurcation dilation
11 occurred.
12 Our study has some limitations, including its retrospective design, and the fact that we did not
13 verify a posteriori which cases would have benefited from an iliac bifurcated device. This
14 experience was initiated before the advent of iliac branched stent-grafts for which the results now
15 appear to be promising, although their long-term patency should be assessed and compared to
16 that achieved with open repair in further studies.
17 However, our follow-up was long (5.8 years), only four patients were lost to follow-up and the
18 rate of non-aorto-iliac complication-related mortality was in the normal range in this specific
19 population after surgery and reflected the disease severity of our patients. Furthermore, unlike
20 iliac bifurcated stent-graft, our hybrid technique allowed revascularizing the IIA regardless of the
21 anatomical pattern of iliac arteries.

22

23 **Conclusion**

1 The hybrid technique we described, consisting in AAA endovascular exclusion combined with
2 open IIA revascularization, is safe and effective on pelvic vascularization. It results in a high
3 long-term patency rate and low morbidity. This technique is a simple alternative. It is accessible
4 to any vascular center and should continue to be proposed in patients who are not eligible for
5 endovascular treatment due to anatomical contraindications to preserve both IIA.

6

7 **Conflict of interest**

8

9 None

10

11 **References**

- 12 1. Prinszen M, Verhoeven EL, Buth J, Cuypers PW, van Sambeek MR, Balm R, et al. A
13 randomized trial comparing conventional and endovascular repair of abdominal aortic
14 aneurysms. *N Engl J Med* 2004;351:1607–18.
- 15 2. Greenhalgh RM, Brown LC, Kwong GP, Powell JT, Thompson SG, EVAR trial
16 participants. Comparison of endovascular aneurysm repair with open repair in patients
17 with abdominal aortic aneurysm (EVAR trial 1), 30-day operative mortality results:
18 randomised controlled trial. *Lancet* 2004;364:843–8.
- 19 3. EVAR trial participants. Endovascular aneurysm repair and outcome in patients unfit for
20 open repair of abdominal aortic aneurysm (EVAR trial 2): randomised controlled trial.
21 *Lancet* 2005;365:2187–92.
- 22 4. Bosanquet DC, Wilcox C, Whitehurst L, Cox A, Williams IM, Twine CP, et al.
23 Systematic review and meta-analysis of the effect of internal iliac artery exclusion for

- 1 patients undergoing EVAR. *Eur J Vasc Endovasc Surg* 2017;53:534–48.
- 2 5. Ahn SS, Rutherford RB, Johnston KW, May J, Veith FJ, Baker JD, et al. Reporting
3 standards for infrarenal endovascular abdominal aortic aneurysm repair. *Ad Hoc*
4 *Committee for Standardized Reporting Practices in Vascular Surgery of The Society for*
5 *Vascular Surgery/International Society for Cardiovascular Surgery. J Vasc Surg*
6 *1997;25:405–10.*
- 7 6. Chaikof EL, Blankensteijn JD, Harris PL, White GH, Zarins CK, Bernhard VM, et al.
8 Reporting standards for endovascular aortic aneurysm repair. *J Vasc Surg* 2002;35:1048–
9 60.
- 10 7. Harris PL, Buth J, Mialhe C, Myhre HO, Norgren L. The need for clinical trials of
11 endovascular abdominal aortic aneurysm stent-graft repair: the EUROSTAR project. *J*
12 *Endovasc Surg* 1997;4:72–7.
- 13 8. Singland JD, Mitton D, Guillaume A, Cluzel P, Goasdoue P, Lavaste F, et al. Dynamics of
14 homemade aortic endografts: in vivo study in humans with computed tomography scanner
15 modeling. *Ann Vasc Surg* 2010;24:127–39.
- 16 9. Cochenec F, Marzelle J, Allaire E, Desgranges P, Becquemin JP. Open vs endovascular
17 repair of abdominal aortic aneurysm involving the iliac bifurcation. *J Vasc Surg*
18 *2010;51:1360–6.*
- 19 10. EVAR trial participants. Endovascular aneurysm repair versus open repair in patients with
20 abdominal aortic aneurysm (EVAR trial 1): randomised controlled trial. *Lancet*
21 *2005;365:2179–86.*
- 22 11. Lederle FA, Freischlag JA, Kyriakides TC, Padberg FT, Matsumura JS, Kohler TR, et al.
23 Outcomes following endovascular vs open repair of abdominal aortic aneurysm: a

- 1 randomized trial. JAMA 2009;302:1535–42.
- 2 12. Hobo R, Sybrandy JEM, Harris PL, Buth J, EUROSTAR Collaborators. Endovascular
3 repair of abdominal aortic aneurysms with concomitant common iliac artery aneurysm:
4 outcome analysis of the EUROSTAR Experience. J Endovasc Ther. 2008;15:12–22.
- 5 13. Ziegler P, Avgerinos ED, Umscheid T, Perdikides T, Erz K, Stelter WJ. Branched iliac
6 bifurcation: 6 years experience with endovascular preservation of internal iliac artery
7 flow. J Vasc Surg 2007;46:204–10.
- 8 14. Albertini JN, Favre JP, Bouziane Z, Haase C, Nourrissat G, Barral X. Aneurysmal
9 extension to the iliac bifurcation increases the risk of complications and secondary
10 procedures after endovascular repair of abdominal aortic aneurysms. Ann Vasc Surg
11 2010;24:663–9.
- 12 15. Gray D, Shahverdyan R, Reifferscheid V, Gawenda M, Brunkwall JS. EVAR with flared
13 iliac limbs has a high risk of late type 1b endoleak. Eur J Vasc Endovasc Surg
14 2017;54:170–6.
- 15 16. Falkensammer J, Hakaim AG, Andrew Oldenburg W, Neuhauser B, Paz-Fumagalli R,
16 McKinney JM, et al. Natural history of the iliac arteries after endovascular abdominal
17 aortic aneurysm repair and suitability of ectatic iliac arteries as a distal sealing zone. J
18 Endovasc Ther 2007;14:619–24.
- 19 17. Lin PH, Chen AY, Vij A. Hypogastric artery preservation during endovascular aortic
20 aneurysm repair: is it important? Sem Vasc Surg 2009;22:193–200.
- 21 18. Naughton PA, Park MS, Kheirelseid EA, O'Neill SM, Rodriguez HE, Morasch MD, et al.
22 A comparative study of the bell-bottom technique vs hypogastric exclusion for the
23 treatment of aneurysmal extension to the iliac bifurcation. J Vasc Surg 2012;55:956–62.

- 1 19. Massière B, Ristow von A, Vescovi A, Leal D, Barbosa da Fonseca LM. Ten-year
2 experience with management of aortoiliac aneurysms using retrograde endovascular
3 internal iliac artery preservation. *Ann Vasc Surg* 2016;35:163–7.
- 4 20. Karthikesalingam A, Hinchliffe RJ, Holt PJ, Boyle JR, Loftus IM, Thompson MM.
5 Endovascular aneurysm repair with preservation of the internal iliac artery using the iliac
6 branch graft device. *Eur J Vasc Endovasc Surg* 2010;39:285–94.
- 7 21. Gray D, Shahverdyan R, Jakobs C, Brunkwall J, Gawenda M. Endovascular aneurysm
8 repair of aortoiliac aneurysms with an iliac side-branched stent graft: studying the
9 morphological applicability of the Cook device. *Eur J Vasc Endovasc Surg* 2015;49:283–
10 8.
- 11 22. Pearce BJ, Varu VN, Glocker R, Novak Z, Jordan WD, Lee JT. Anatomic suitability of
12 aortoiliac aneurysms for next generation branched systems. *Ann Vasc Surg* 2015;29:69–
13 75.
- 14 23. Millon A, Schiava Della N, Arsicot M, De Lambert A, Feugier P, Magne J-L, et al.
15 Preliminary experience with the Gore(®) Excluder(®) iliac branch endoprosthesis for
16 common iliac aneurysm endovascular treatment. *Ann Vasc Surg* 2016;33:11–7.
- 17 24. Jongsma H, Bekken JA, Bekkers WJ, Zeebregts CJ, van Herwaarden J, Hoksbergen A, et
18 al. Endovascular treatment of common iliac artery aneurysms with an iliac branch device.
19 *J Endovasc Ther* 2017;24:239–45.
- 20 25. Simonte G, Parlani G, Farchioni L, Isernia G, Cieri E, Lenti M, et al. Lesson learned with
21 the use of iliac branch devices: single centre 10 year experience in 157 consecutive
22 procedures. *Eur J Vasc Endovasc Surg* 2017;54:95–103.
- 23 26. Delay C, Deglise S, Lejay A, Georg Y, Roussin M, Schaeffer M, et al. Zenith bifurcated

- 1 iliac side branch device: mid-term results and assessment of risk factors for intraoperative
2 thrombosis. *Ann Vasc Surg* 2017;41:1–10.
- 3 27. Arko FR, Lee WA, Hill BB, Fogarty TJ, Zarins CK. Hypogastric artery bypass to preserve
4 pelvic circulation: improved outcome after endovascular abdominal aortic aneurysm
5 repair. *J Vasc Surg* 2004;39:404–8.
- 6

1 **Legends for illustrations**

2

3 **Figure 1**

4 CT scan reconstruction (volume rendering technique) showing:

5 (a): femoral and iliac approaches (the midline scar corresponds to a previous approach for
6 visceral surgery performed several years ago)

7 (b): right aorto-mono-iliac stentgraft with femoro-femoral bypass and left iliac bifurcation
8 reconstruction.

9

10 **Figure 2**

11 Surgery overview. An aorto-mono-iliac stent-graft was deployed and a femoro-femoral crossover
12 bypass performed to revascularize the left limb and the left internal iliac artery. Left common
13 iliac artery aneurysm is clamped and divided after proximal exclusion by the stent graft.

14

15 **Figure 3**

16 In case of EUROSTAR class D aneurysm, common iliac aneurysm is proximally and distally
17 sutured just above the bifurcation, allowing to easily preserving the iliac bifurcation.

18

19 **Figure 4a**

20 In case of EUROSTAR class E aneurysm, the dilated iliac bifurcation must be divided.

21

22 **Figure 4b**

1 In case of EUROSTAR class E aneurysm, an end-to-end anastomosis between IIA and external
2 iliac artery is performed allowing maintaining the internal iliac artery patent, and avoiding to
3 maintain the distal aneurysmal arterial wall.

4

5 **Figure 5**

6 Year and number of endografts implantations with IIA preservation.

7

8 **Figure 6**

9 Long term survival rates (number at risk are mentioned above the horizontal axis)

10

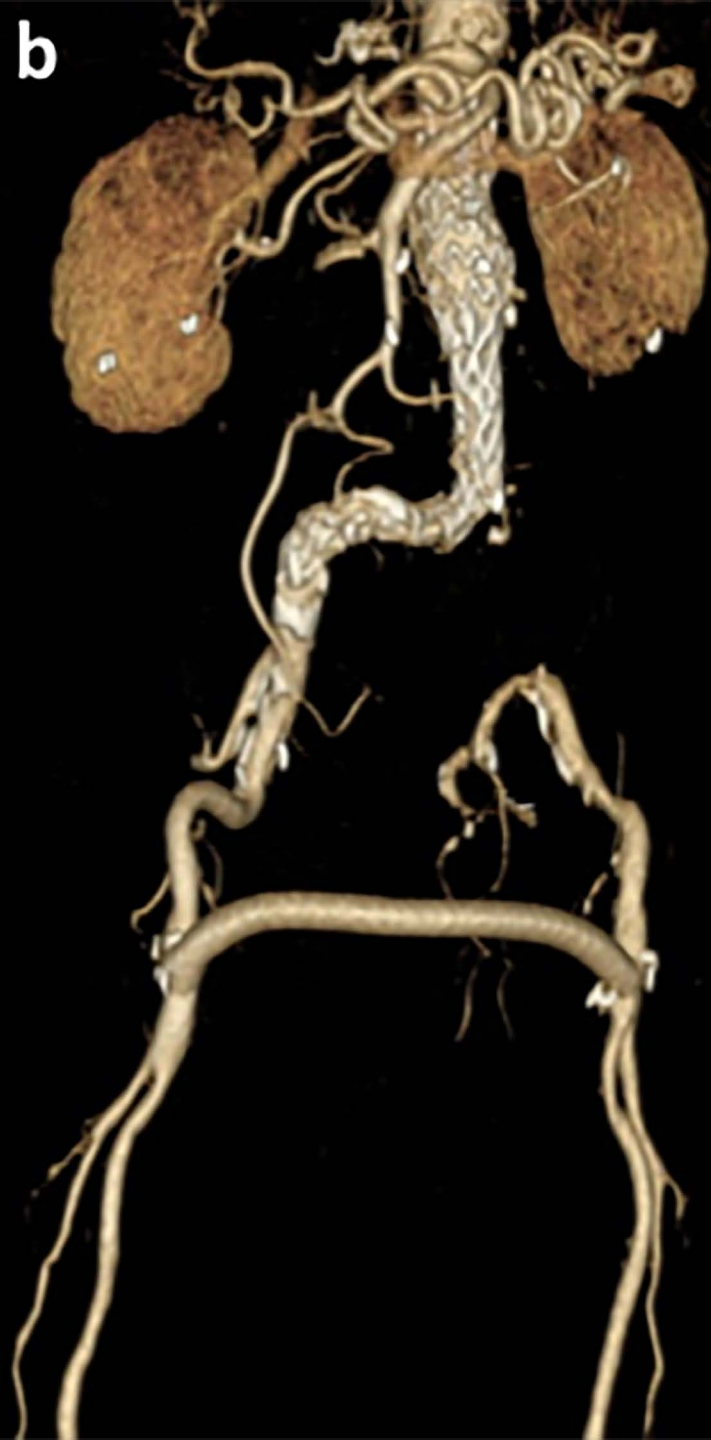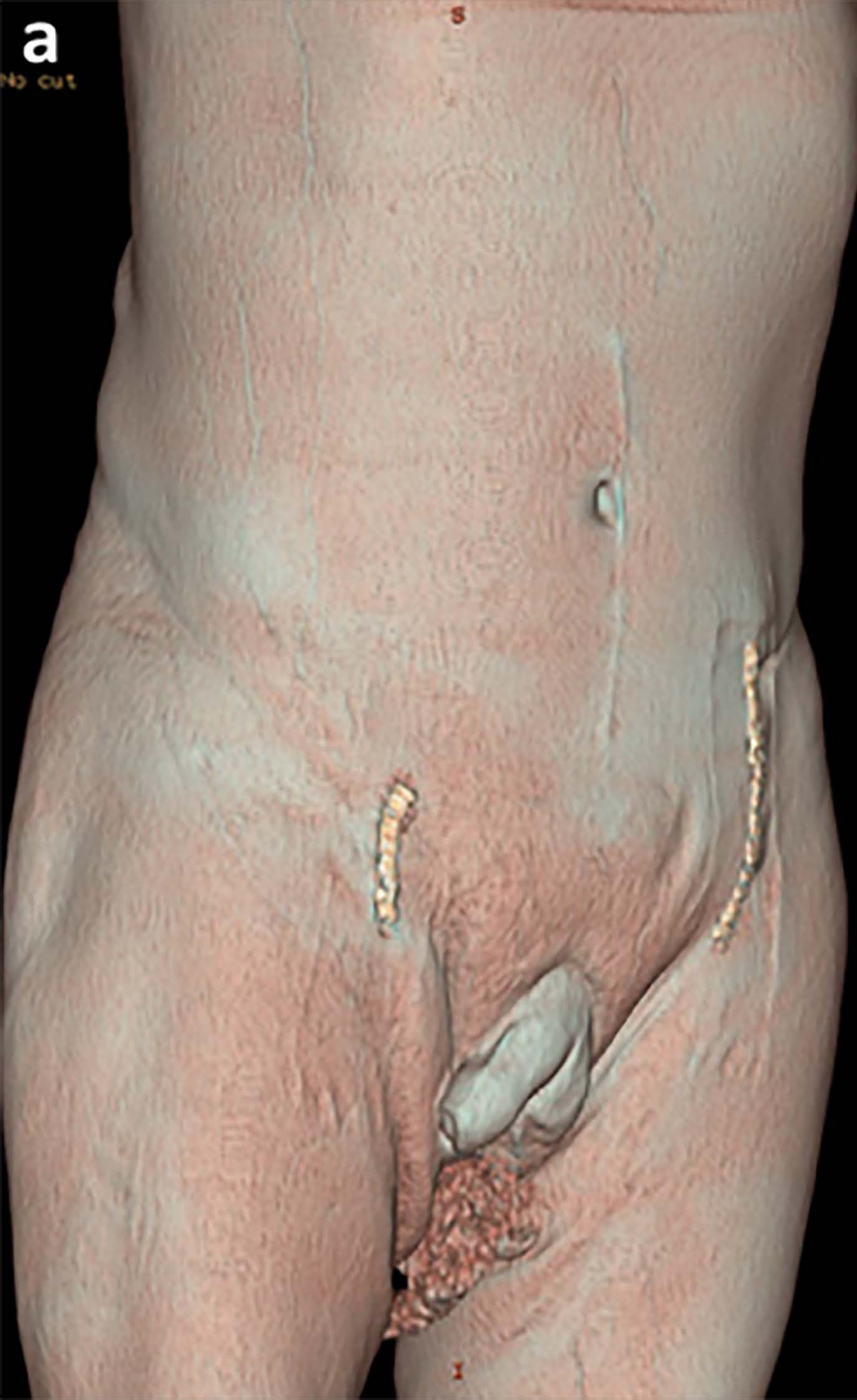11

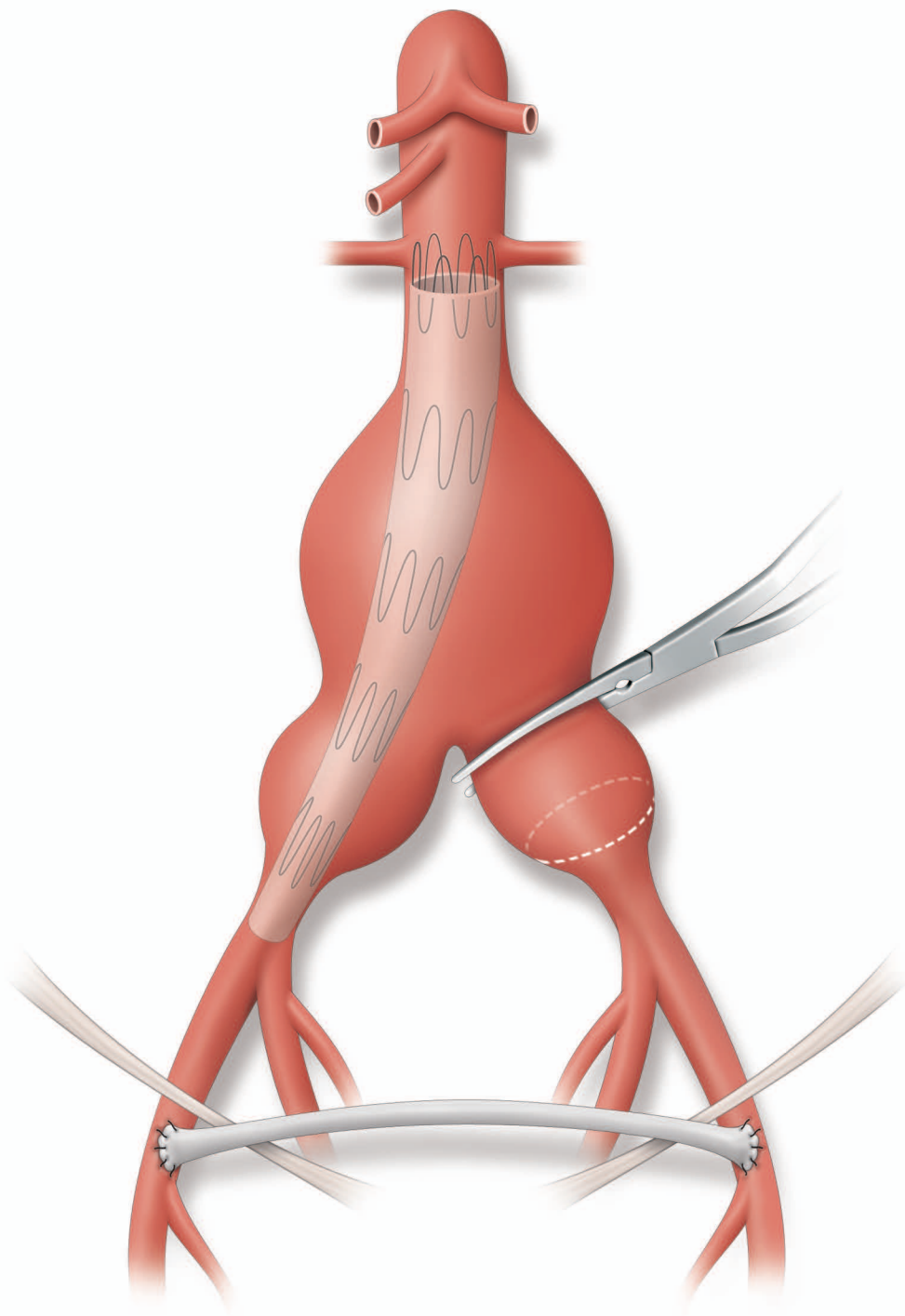
12 **Table 1**

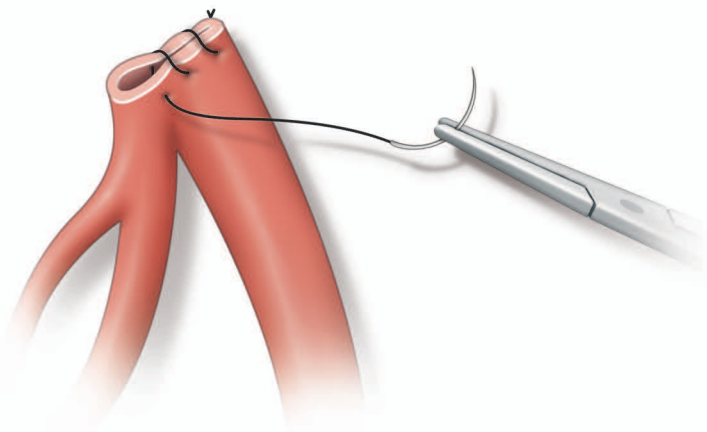
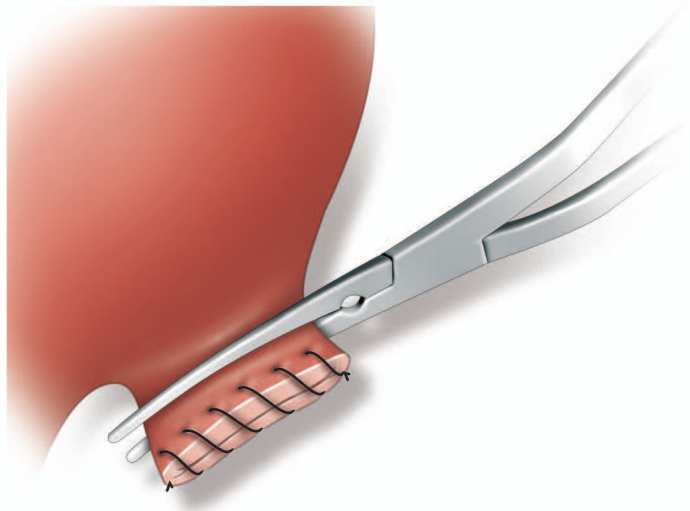
13 Clinical and anatomical characteristics of patients with internal iliac artery surgical preservation

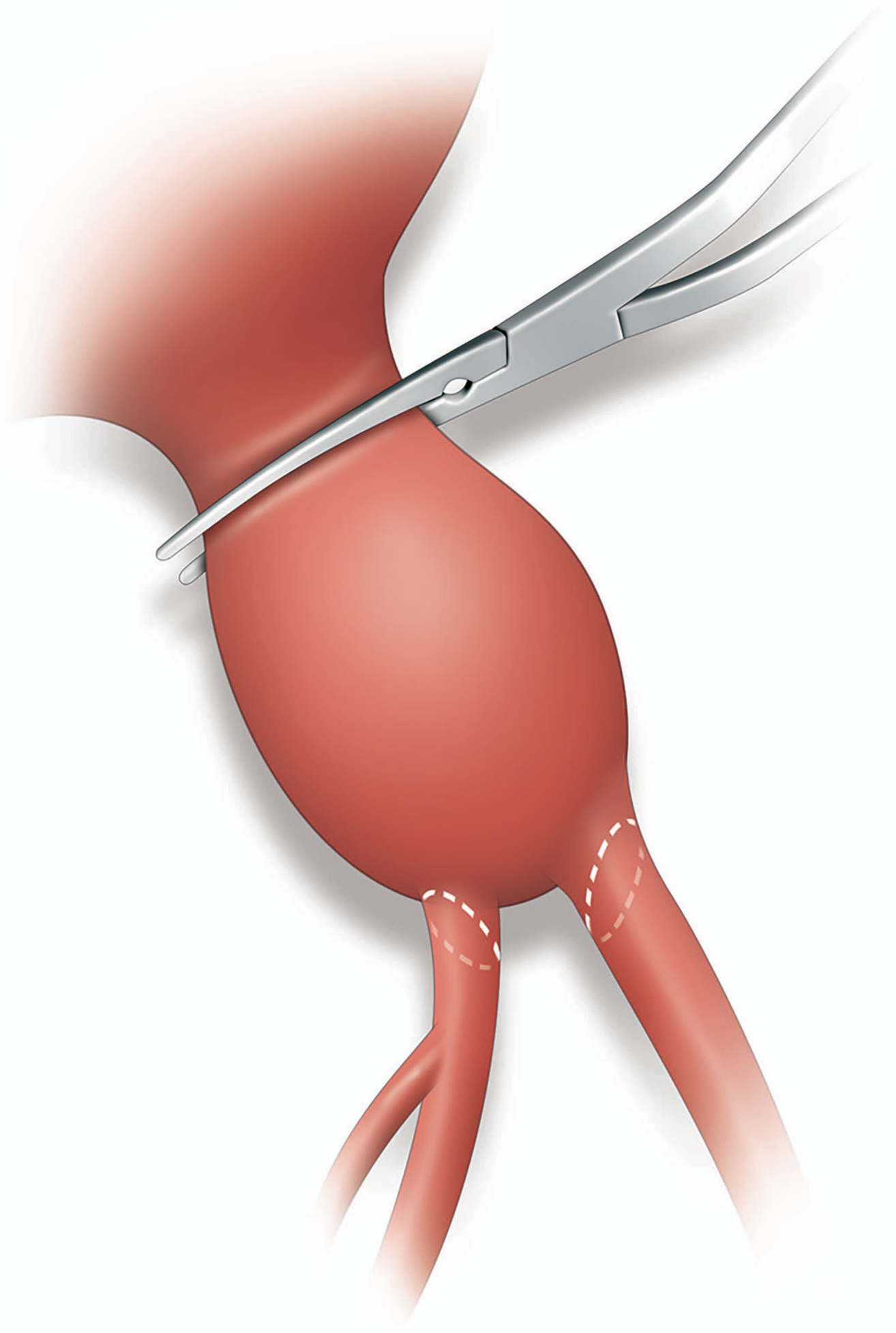
14

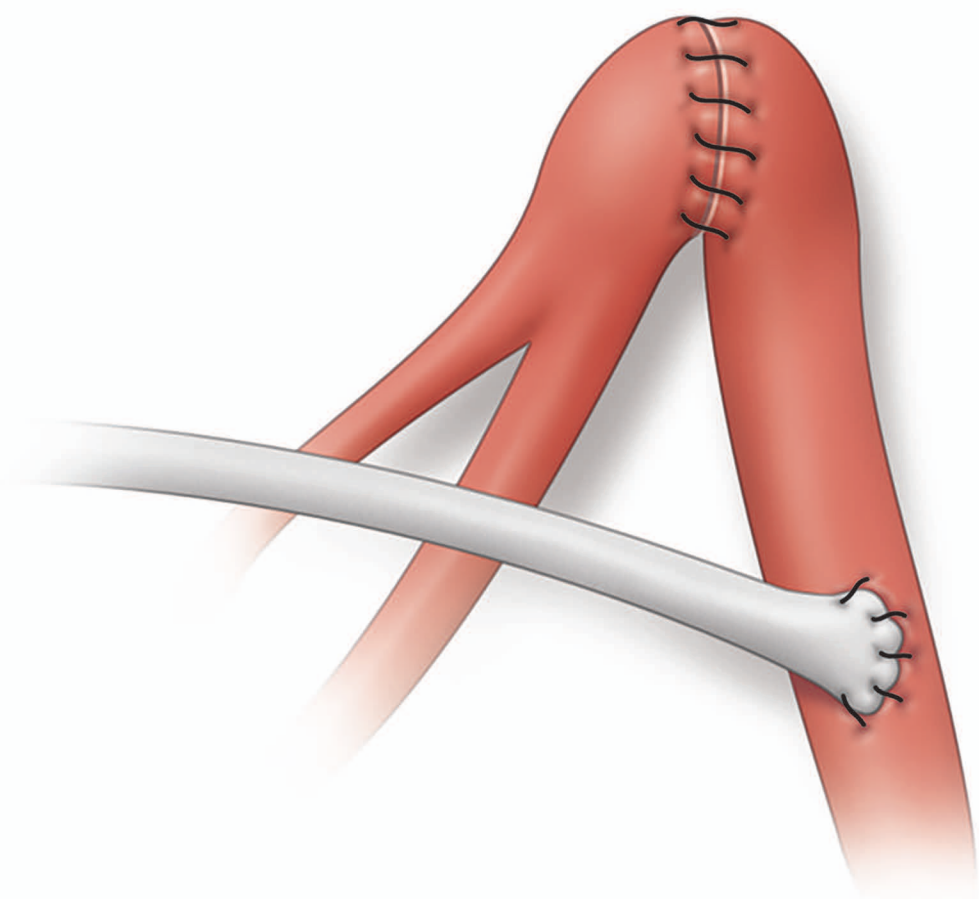
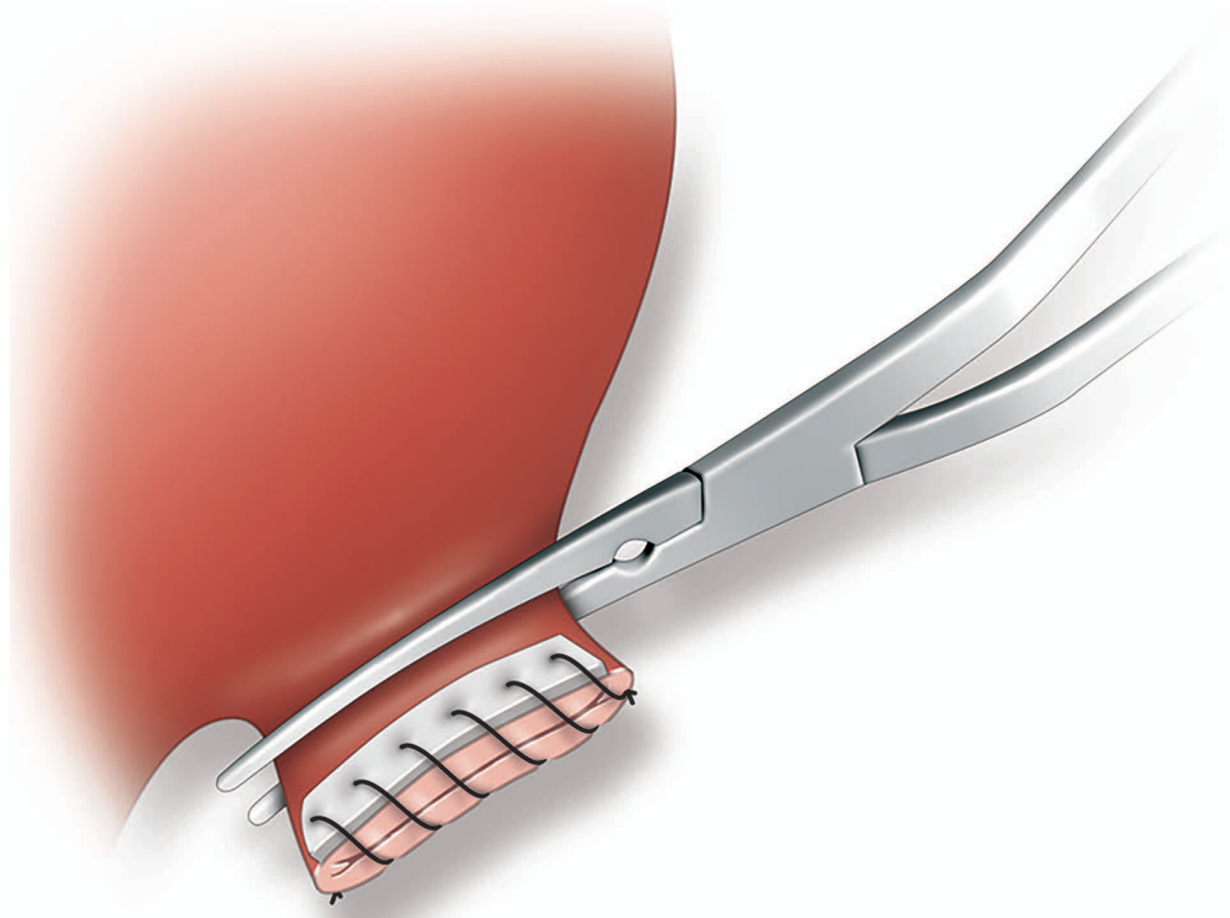
15











■ Number of patients

10

9

8

7

6

5

4

3

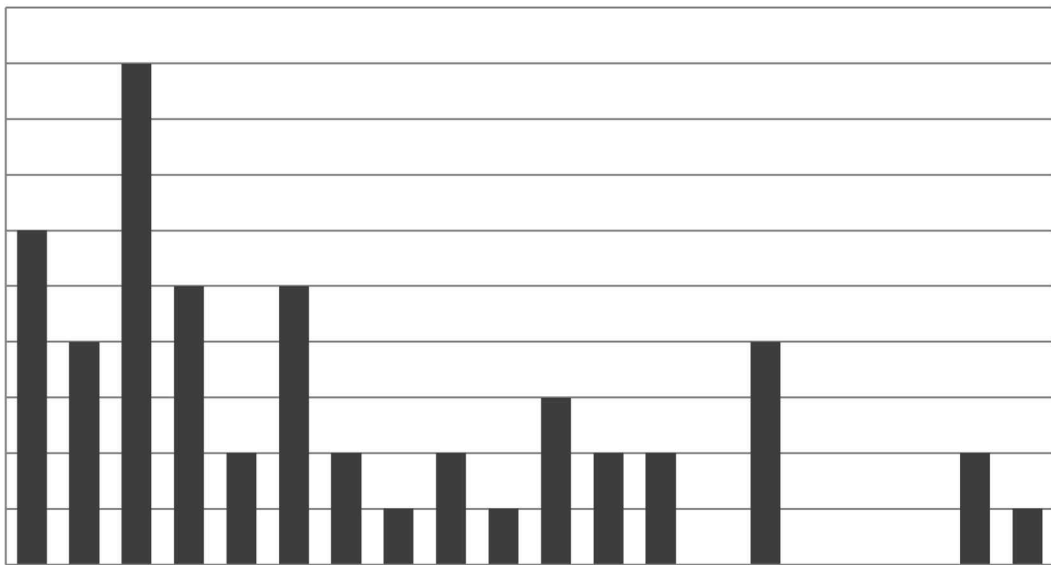
2

1

0

1998 1999 2000 2001 2002 2003 2004 2005 2006 2007 2008 2009 2010 2011 2012 2013 2014 2015 2016 2017

Year



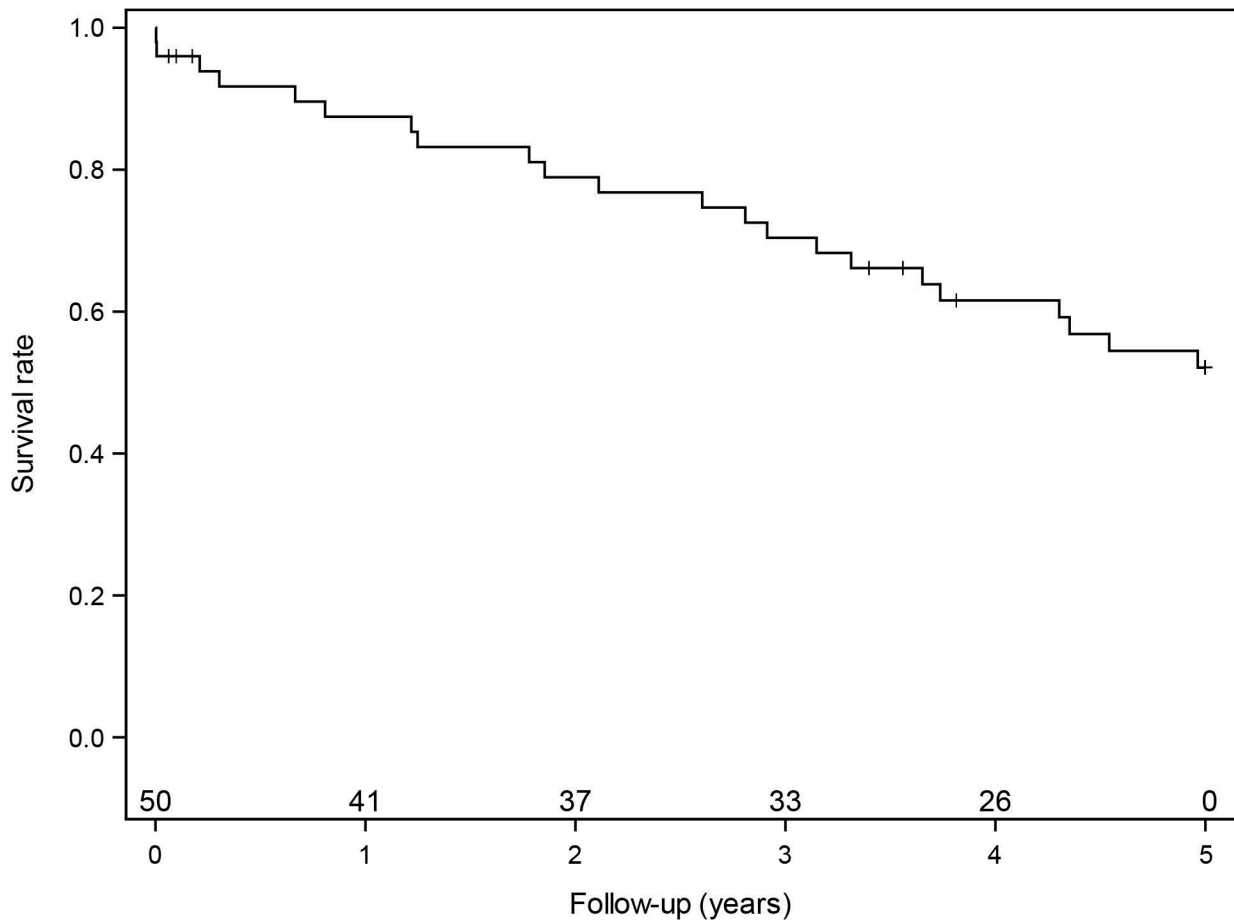


Table I

	n=51
Mean age, years (+/-SD)	74 (+/-8)
Age >80 years, n (%)	13 (25)
Men, n (%)	47 (92)
Diabetes, n (%)	8 (16)
Smoker, n (%)	41 (80)
Hypertension, n (%)	39 (77)
Coronary artery disease, n (%)	21 (41)
Mean LVEF, % (+/-SD)	59 (+/-8)
LVEF <40%, n (%)	2 (4)
Hostile abdomen*, n (%)	10 (20)
Mean BMI, kg/m ² (+/-SD)	28.7 (+/-2)
COPD, n (%)	16 (31)
Renal clearance, mL/min. (+/-SD)	66 (+/- 10)
ASA	
1 (%)	2
2 (%)	47
3 (%)	43
4 (%)	8
Mean common iliac diameter surgically excluded, mm (+/-SD)	29.5 (+/-9)
Mean common iliac diameter ipsilateral to the SG, mm (+/-SD)	17.9 (+/-9)
Uni-iliac aneurysm, n (%)	24 (47)
Bi-iliac aneurysm, n (%)	27 (53)

LVEF: Left Ventricle Ejection Fraction, BMI: Body Mass Index, COPD: Chronic Obstructive Pulmonary Disease, SG:stent graft.

*: history of laparotomy