



## New techniques on uropaleopathology

Maximillien Gilles Baron, Nadia Benmoussa, Dominique Bazin, Isabelle Abadie, Michel Daudon, Philippe Charlier

### ► To cite this version:

Maximillien Gilles Baron, Nadia Benmoussa, Dominique Bazin, Isabelle Abadie, Michel Daudon, et al.. New techniques on uropaleopathology. Urolithiasis -Springer-, 2019, 47 (5), pp.487-488. 10.1007/s00240-018-1062-x . hal-02160797

**HAL Id: hal-02160797**

**<https://hal.sorbonne-universite.fr/hal-02160797>**

Submitted on 23 Jan 2020

**HAL** is a multi-disciplinary open access archive for the deposit and dissemination of scientific research documents, whether they are published or not. The documents may come from teaching and research institutions in France or abroad, or from public or private research centers.

L'archive ouverte pluridisciplinaire **HAL**, est destinée au dépôt et à la diffusion de documents scientifiques de niveau recherche, publiés ou non, émanant des établissements d'enseignement et de recherche français ou étrangers, des laboratoires publics ou privés.

# New techniques on uropaleopathology

Maximilien Gilles Baron<sup>1</sup> · Nadia Benmoussa<sup>2,3</sup> · Dominique Bazin<sup>4</sup> · Isabelle Abadie<sup>5</sup> · Michel Daudon<sup>6</sup> · Philippe Charlier<sup>2,7</sup>

Paleopathology is the study of ancient diseases in past population. Understanding health and diseases of prehistoric and ancient population enhance our knowledge about the way they lived and died. We report the case of two giants bladder stones found in the pelvis of a sixteenth–seventeenth century adult found in the Saint-Pierre and Saint-Paul church in the city of Gonesse, 16 km north-east of Paris (France), during archaeological excavation (Fig. 1a, b). Crystalline composition, carbonation rate (CR) of calcium phosphates and morphology of the stones were analyzed by Fourier transformed infrared spectroscopy (FTIR), stereomicroscopy and scanning electron microscopy (SEM). The anthropological study of the skeletons allow us to affirm that it was a male subject, aged over 60 years old at the time of death. Both stones measured 40 × 21 and 57 × 35 mm respectively. Central core was absent and only outer layer was present. Transection show alternated crystalline and microcrystalline, heterogeneous, concentric layers that suggest a construction in circumferential “onion skin” layers which, associated with an oval shape, is typical of phosphate bladder urolithiasis (Fig. 1c). Morphological aspect was classified as IVb for

both stones. Lithiasis were composed of 83% carbapatite and 8% hydroxyapatite for the first stone and 87% carbapatite and 6% hydroxyapatite for the second. Carbonation rate were 14% in outer layers and 5% in inner layers for the first and 12% for the second stone. Bacterial imprints were seen at the mesoscopic scale suggestive for cocci prints (Fig. 1d). Another argument for infection lithiasis in our case is the absence of central core found in the stone. Even, if it might have been damaged during the excavation, infection stones are known to have a soft matrix stone made of bacterial proteins around which crystallization will happen [1].

Those elements evoke an infectious urolithiasis that might have led to chronic renal failure and death.

We are the first to use the association of FTIR, SEM and carbonation rate in paleopathology [2–3].

FTIR, stereomicroscopy and SEM imaging are very useful and complementary tools that should be used systematically when analyzing ancient urinary stones for a better understanding of pathophysiology.

**Funding** No funding.

## Compliance with ethical standards

**Conflict of interest** No conflict exists. Author Baron Maximilien Gilles declares that he has no conflict of interest. Author Benmoussa Nadia declares that she has no conflict of interest. Author Bazin Dominique declares that he has no conflict of interest. Author Abadie Isabelle declares that she has no conflict of interest. Author Daudon Michel declares that he has no conflict of interest. Author Charlier Philippe declares that he has no conflict of interest.

**Ethical approval** This article does not contain any studies with human participants or animals performed by any of the authors.

---

✉ Nadia Benmoussa  
nadia.benmoussa@yahoo.fr

<sup>1</sup> Department of Urology, Rouen University Hospital, Rouen, France

<sup>2</sup> Section of Medical and Forensic Anthropology (UVSQ/EA 4569 Paris Descartes University), UFR of Health Sciences, 2 Avenue de la Source de la Bièvre, 78180 Montigny-Le-Bretonneux, France

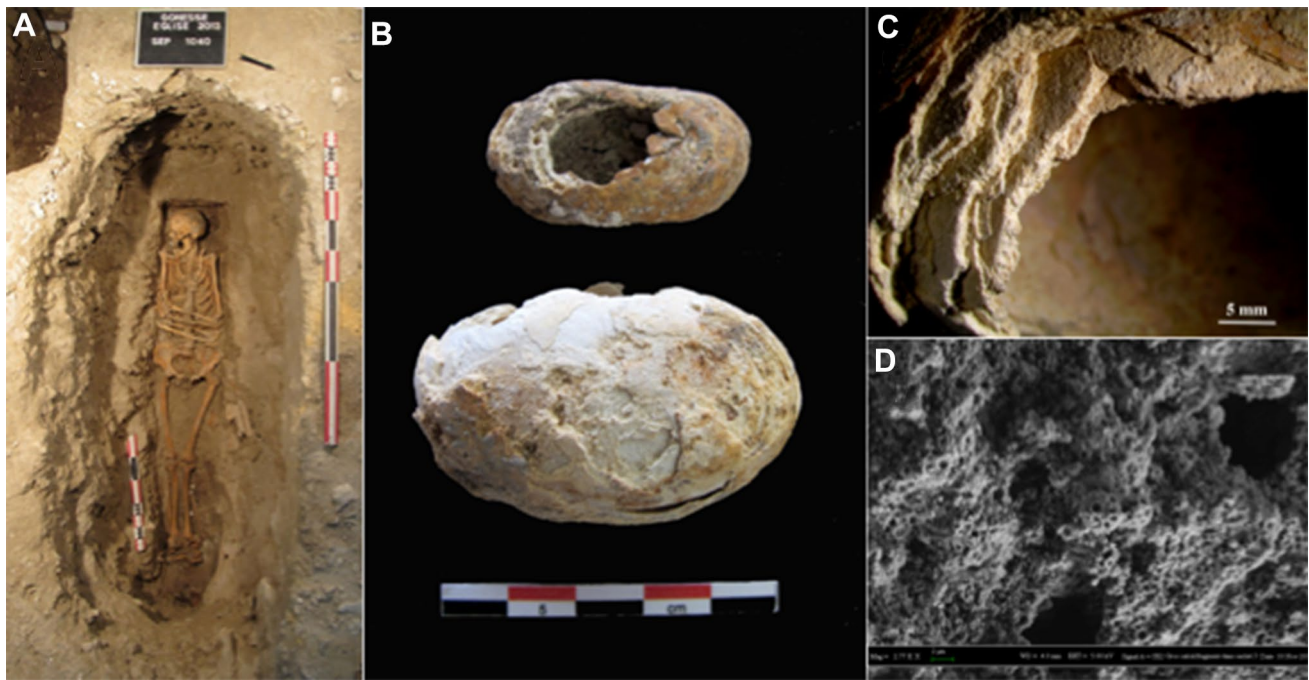
<sup>3</sup> Department of Otolaryngology, Head and Neck Surgery, Rouen University Hospital, Rouen, France

<sup>4</sup> CNRS-LCMCP-UPMC, Collège de France, 11 Place Marcelin Berthelot, 75231 Paris Cedex 05, France

<sup>5</sup> INRAP, CRAHAM UMR 6273, Paris, France

<sup>6</sup> Service d'Explorations Fonctionnelles, AP-HP, Hôpital Tenon, 4 Rue de la Chine, 75020 Paris, France

<sup>7</sup> CASH, 403 Avenue de la République, 92000 Nanterre, France



**Fig. 1** Analyzes of two ancient urinary stones. **a** General view of the grave 1040 found in the Saint-Pierre and Saint-Paul church in the city of Gonesse (France). There is two giants bladder stones in the pelvis of this sixteenth–seventeenth century adult. **b** External aspect of

the two bladder stones from the pelvis. **c** Detail of the concentric layers visible on one of the bladder stones. **d** SEM examination of the stones. Bacterial imprints at mesoscopic scale suggestive for a long-term infectious process by cocci germs

## References

1. Beltrami P et al (2014) The endourological treatment of renal matrix stones. *Urol Int* 93:394–398
2. D'alessio A et al (2005) An 8500-year-old bladder stone from Uzzo Cave (trapani): Fourier transform–infrared spectroscopy analysis. *Archaeometry* 47:127–136
3. Giuffra V, Costantini L, Costantini Biasini L, Caramella D, Fornaciari G (2008) Giant bladder stone in a natural mummy of the early 19th century. *Urology* 72:780–781