



HAL
open science

MSI/MMR-deficient tumor diagnosis: Which standard for screening and for diagnosis? Diagnostic modalities for the colon and other sites: Differences between tumors

Magali Svrcek, Olivier Lascols, Romain Cohen, Ada Collura, Vincent Jonchère, Jean-François Fléjou, Olivier Buhard, Alex Duval

► To cite this version:

Magali Svrcek, Olivier Lascols, Romain Cohen, Ada Collura, Vincent Jonchère, et al.. MSI/MMR-deficient tumor diagnosis: Which standard for screening and for diagnosis? Diagnostic modalities for the colon and other sites: Differences between tumors. *Bulletin du Cancer*, 2019, 106 (2), pp.119-128. 10.1016/j.bulcan.2018.12.008 . hal-02179325

HAL Id: hal-02179325

<https://hal.sorbonne-universite.fr/hal-02179325>

Submitted on 10 Jul 2019

HAL is a multi-disciplinary open access archive for the deposit and dissemination of scientific research documents, whether they are published or not. The documents may come from teaching and research institutions in France or abroad, or from public or private research centers.

L'archive ouverte pluridisciplinaire **HAL**, est destinée au dépôt et à la diffusion de documents scientifiques de niveau recherche, publiés ou non, émanant des établissements d'enseignement et de recherche français ou étrangers, des laboratoires publics ou privés.

Diagnostic de tumeur MSI/MMR déficiente : quel standard pour le screening et pour le diagnostic ?

Modalités diagnostiques pour le côlon et pour les autres localisations : les différences entre les tumeurs.

MSI/MMR deficient tumor diagnosis : which standard for screening and for diagnosis?

Diagnostic modalities for the colon and other sites: differences between tumors.

Short title: Standard for screening and diagnosis of MSI/MMR deficient tumor

Magali Svrcek* (1, 2), Olivier Lascols (3), Romain Cohen (2,4), Ada Collura (2), Vincent Jonchère (2), Jean-François Fléjou (1,2), Olivier Buhard (2), Alex Duval (2)

(1) Sorbonne Université, Department of Pathology, AP-HP, Hôpital Saint-Antoine, 75 012 PARIS, France;

(2) INSERM UMR_S 938, Centre de recherche Saint-Antoine, Equipe “Instabilité des Microsatellites et Cancers”

(3) Sorbonne Université, Department of Biochemistry, AP-HP, Hôpital Saint-Antoine, 75 012 PARIS, France;

(4) Sorbonne Université, Department of Medical Oncology, AP-HP, Hôpital Saint-Antoine, 75 012 PARIS, France;

Corresponding author: Magali Svrcek

* To whom correspondence should be addressed.

Pr Magali SVRCEK

Service d'Anatomie et Cytologie Pathologiques

AP-HP, Hôpital Saint-Antoine

184 rue du Faubourg Saint-Antoine

75 012 PARIS

Tel: +33 1 49 28 21 79

Fax: +33 1 49 28 28 78

Email: magali.svrcek@aphp.fr

[Manuscript word count : 4799](#)

Keywords: immunohistochemistry; Microsatellite instability; Mismatch Repair; Next Generation Sequencing; Lynch syndrome

Disclosures: The authors have no conflicts of interest to declare.

ABSTRACT (244 words)

Microsatellite instability (MSI), which is caused by deficiency of the DNA Mismatch repair (MMR) system, is the molecular abnormality observed in tumors associated with Lynch syndrome (LS). LS represents one of the most frequent conditions of cancer predisposition in human, thus requiring specific care and genetic counseling. Moreover, research has recently increasingly focused on MMR deficiency due to its positive predictive value for the efficacy of immune checkpoints inhibitors (ICKi) in metastatic tumors, regardless of their primary origin. MSI has also been demonstrated to constitute an independent prognostic factor in several tumor types, being also associated with alternative response to chemotherapy. These observations have led many professional medical organizations to recommend universal screening of all newly diagnosed colorectal cancers (CRC) for dMMR/MSI status and increasing evidence support the evaluation of MSI in all human tumors regardless of the cancer tissue of origin.

Currently, two standard reference methods, namely immunohistochemistry and PCR, are recommended for the detection of dMMR/MSI status. These methods are equally valid as the initial screening test for dMMR/MSI in CRC. To date, there is no recommendation for the detection of dMMR/MSI in other primary tumors. In this review, we will present a comprehensive overview of the methods used for evaluation of tumor dMMR/MSI status in CRC, as well as in other tumor sites. We will see that the evaluation of this status remains challenging in some clinical settings, with the need to improve the above methods in these specific contexts.

RESUME

L'instabilité des microsatellites (MSI), due à la déficience du système MMR (pour Mismatch Repair), est l'anomalie moléculaire observée dans les tumeurs du syndrome de Lynch. Le syndrome de Lynch représente le plus fréquent des syndromes de prédisposition aux cancers, ce qui nécessite une prise en charge spécifique et un avis du conseil génétique. Par ailleurs, la recherche s'est récemment beaucoup intéressée au statut MSI en raison de sa valeur prédictive quant à l'efficacité des inhibiteurs des immune checkpoints (ICKi) dans les tumeurs à un stade métastatique, quelle que soit leur origine. Le statut MSI constitue également un facteur pronostique indépendant dans plusieurs types tumoraux, du fait de son association à des réponses alternatives à la chimiothérapie. Ces données ont conduit un grand nombre de sociétés savantes à recommander un screening universel pour la détermination du statut dMMR/MSI de tout cancer colorectal (CCR), de même que de nombreux autres types tumoraux.

Deux méthodes de référence, qui sont l'immunohistochimie et la biologie moléculaire, sont recommandées pour la détermination du statut dMMR/MSI. Ces deux méthodes sont équivalentes pour le dépistage de ce statut dans le CCR. En revanche, il n'y a pas de recommandation dans d'autres sites tumoraux. Nous ferons un état des lieux des méthodes à disposition pour l'évaluation du statut dMMR/MSI, à la fois dans le CCR, mais également dans d'autres sites tumoraux. Nous verrons que l'évaluation de ce statut reste difficile dans certains contextes cliniques, avec la nécessité d'améliorer en conséquence les méthodes de détection dans ces contextes particuliers.

INTRODUCTION

Mismatch repair (MMR) deficient tumors harbor defects in major genes of the DNA MMR system (*MLH1*, *MSH2*, *MSH6*, *PMS2*). They display a molecular phenotype characterized by the genetic instability of numerous microsatellite repeat sequences throughout the genome referred to as MSI (for Microsatellite Instability). MSI was first described in inherited tumors associated with Lynch syndrome (LS). LS affects approximately 3% of all patients with colorectal cancer (CRC), making it the most common hereditary syndrome predisposing individuals to develop CRC [1]. These patients and their at-risk relatives can develop additional LS-related tumors, thus requiring specific care and genetic counseling. MSI can also result from an epigenetic biallelic silencing of *MLH1* expression by *de novo* methylation of the *MLH1* promoter (sporadic cancers) [2].

MSI has an independent prognostic value in several primary tumors and can be associated with alternative response to chemotherapy. Indeed, dMMR is a predictive marker for lack of efficacy of fluorouracil-based adjuvant therapy in CRC [3] and patients with stage II CRC are advised not to receive adjuvant chemotherapy in case of MSI/dMMR status. For patients with stage III CRC with an MSI/dMMR status, an indication for adjuvant chemotherapy with combination of oxaliplatin and fluoropyrimidines is given, while for non-MSI (or MSS)/MMR proficient elderly patients, oxaliplatin is not a standard treatment. Moreover, a dominant-negative form of heat shock protein (HSP)110 (HSP110DE9) expressed by cancer cells with MSI, resulting from exon skipping caused by somatic deletions in the T17 intron repeat, sensitizes the cells to 5-fluorouracil and oxaliplatin *in vitro* [4]. About 25% of patients with stages II–III colorectal tumors with MSI have an excellent response to chemotherapy, due to large, biallelic deletions in the T17 intron repeat of HSP110 in the tumor DNA [5].

Finally, for patients with metastatic CRC (mCRC), MSI/dMMR status constitutes a mandatory biomarker to be included in immunotherapy clinical trials (anti-PD1, anti PD-L1 ± anti-CTLA-4), due to the positive predictive value of this status for the efficacy of these treatments [6-9]. These observations have led many professional medical organizations to recommend universal screening of all newly diagnosed CRC for dMMR/MSI status [10, 11].

Further evaluation of the efficacy of PD-1 blockade in patients with advanced MMR-deficient cancers across 12 different tumor types suggested that MSI may be an actionable marker for immune-checkpoint (ICK) blockade therapy, regardless of the cancer tissue of origin [7]. For these reasons, in 2017, the U.S. Food and Drug Administration granted accelerated approval for nivolumab and pembrolizumab, the latter for dMMR and/or MSI tumors, regardless of tumor type. Moreover, recent exploration of the landscape of MSI in a broader panel of tumor types, particularly by using large-scale analysis, led to the confirmation of infrequently (1-5%) occurring MSI tumors in cancer types not conventionally associated with MSI [12]. MSI can therefore be considered as a generalized cancer phenotype. Furthermore, recent data provide a different perspective of LS than previous reports and add to the literature describing genotype-phenotype correlations within LS, thus redefining the spectrum of tumors belonging to this syndrome and the frequencies and the type of MMR mutations [13-15]. Consequently, testing for dMMR/MSI is now increasingly being incorporated into routine oncological care of patients with solid tumors across a broad spectrum of cancers.

Two standard reference methods are currently recommended for the detection of dMMR/MSI in CRC: testing for MSI using Polymerase Chain Reaction (PCR), according to international criteria, and screening for loss of MMR protein expression using immunohistochemistry with antibodies directed against MLH1, MSH2, MSH6 and PMS2. These methods are equally valid as the initial screening test for dMMR/MSI in CRC. By

contrast, there is no recommendation for detection of the dMMR/MSI phenotype in the great majority of other tumor types. In this review, we will present a comprehensive overview of the methods used for the evaluation of tumor dMMR/MSI status in CRC, as well as in other tumor types. We will see that the evaluation of this status remains challenging in some clinical settings and that the accuracy of standard IHC and PCR methods for detection of this phenotype has to be further investigated. Finally, we will talk about emerging techniques developed for improving MSI detection in some specific contexts.

1. Determination of MicroSatellite Instability (MSI) and MisMatch repair deficiency (dMMR) in colorectal cancers (CRC):

1.1. Immunohistochemistry:

Immunohistochemistry (IHC) allows studying the expression of MMR proteins on histological sections. Physiologically, these proteins are ubiquitous and are located in the nucleus. They are particularly expressed in cells of the lower third of the crypts of mucosae, and in stromal elements such as inflammatory cells and/or endothelial cells. Immunohistochemical testing consists in looking for a complete loss of expression of the studied protein by tumor cells, the two copies of the gene being inactivated in MSI tumors. The presence of nuclear staining in the tumor cells, even when it is focal and weak, is good evidence of intact MMR protein expression. Each protein is considered lost if there is complete loss of nuclear staining in the tumor cells. An internal positive control (intact nuclear staining of stromal elements such as inflammatory cells and/or endothelial cells) is required for adequate evaluation. Cases showing a complete absence of nuclear staining of both tumor cells and stromal elements are deemed uninterpretable. In that latter case, repeating the staining in search for positive non-neoplastic stromal or inflammatory cells is absolutely required before confirming diagnosis [16]. In some cases, staining of the internal

controls can be stronger than that of positive tumor cells; this particular staining has to be followed by molecular microsatellite instability analysis to confirm the presence of a defective DNA MMR system [17].

In their functional state, the MMR proteins form heterodimers: MLH1 builds a functional complex with PMS2 (MutLalpha) and MSH2 dimerizes with MSH6, forming MutSalphalpha [18, 19]. MLH1 and MSH2 proteins are the obligatory partners of their respective heterodimers. Mutations in the *MLH1* or *MSH2* gene result in proteolytic degradation of the respective dimer and consequent loss of both the obligatory and the secondary partner proteins. Loss of MLH1 and MSH2 proteins is exclusive. In case of loss of MLH1 protein expression in the primary tumor, a concurrent loss of PMS2 protein expression is also observed (**Figure 1**). In the same way, the extinction of MSH2 protein in the tumor leads to concurrent extinction of MSH6. On the contrary, a mutation in one of the secondary genes, i.e. *PMS2* or *MSH6*, does not usually lead to concurrent loss of the obligatory proteins expression in the tumor (MLH1 or MSH2, respectively), probably due to interactions with other components of the MMR system such as MSH3, MLH3, and PMS1.

In patients suspected of being at risk for LS but without a personal history of CRC, evaluation of colorectal adenomas can be helpful in establishing the diagnosis of LS [10]. Walsh et al. identified loss of MMR protein expression in 72% (78/109) of adenomas analyzed in patients with known deleterious germline mutations in MMR genes [20]. It is however worth noting that the preservation of MMR protein expression in an adenoma does not exclude the possibility of a LS, particularly for patients with germline *MSH6* mutations.

1.2 PCR:

MSI in tumor DNA is defined as the presence of alternate-sized repetitive DNA sequences that are not seen in the corresponding germline DNA. In 1997, an international

consensus meeting proposed a panel of 5 markers, referred to as the Bethesda panel, for the uniform analysis of MSI [21]. It included 2 mononucleotide repeats (BAT-25 and BAT-26) and 3 dinucleotide repeats (D5S346, D2S123, and D17S250). When comparing marker length between normal and tumor tissue, tumors with instability at 2 or more of these markers were defined as being MSI-H, whereas those with instability at 1 repeat or showing no instability were defined as low-microsatellite instability (MSI-L) or microsatellite stable (MSS) tumors, respectively. The Bethesda panel is still one of the most widely used panels of microsatellites, particularly in the USA. However, mononucleotide markers are more sensitive than dinucleotide markers for the detection of MSI. Thus, in 2002, a panel of 5 mononucleotidic repeats has been proposed, referred to as the Pentaplex panel, that obviated the necessity to analyze simultaneously non-tumor DNA [22]. This panel was recognized by the NCI as the international gold standard for identifying the MSI phenotype in human tumors, due to its better specificity and sensitivity [23]. With this method, 2 unstable markers are sufficient to classify tumors as MSI [24] (**Figure 2A**). It is worthy to note that the probability of misinterpreting an MSI result (false positive) due to the presence of concurrent polymorphisms in 3 or more of the 5 markers in an individual, although rare, can appear in the case of African subjects. The PCR method displays poor sensitivity in cases of very important contamination of DNA tumor samples by DNA from normal tissue (> 90%) and low levels of tumor cells, and false negatives can thus be observed, notably in the context of biopsies, mucinous tumors, and cancers nearly sterilized by neo-adjuvant radiotherapy [21]. Our group recently reported a high mutation frequency of the T17 mononucleotide repeat of the chaperone HSP110 (HT17) in MSI CRC [4]. Deletion of the HT17 repeat in tumor DNA leads to increased synthesis of a variant HSP110 isoform due to exon 9 skipping (HSP110DE9) [4, 5]. HSP110 HT17 has been shown to constitute an improved biomarker for the diagnosis of MSI in CRC, including LS, as it displays a higher sensitivity (98.4%) than

the pentaplex panel, and is simpler to use as only one marker needs to be analyzed [25] (**Figure 2B**). Although the exceptional sensitivity of HT17 has been confirmed in another study [26], this marker remains to be further evaluated, in particular in cancers other than CRC.

1.3 Selecting a screening test in CRC: IHC versus PCR

Immunohistochemistry is an inexpensive and low time-consuming technique. It is routinely used in pathology departments. It is an extremely sensitive technique, useable even with very little tumor sample. Moreover, in contrast to MSI testing, immunohistochemistry can help identifying the affected gene, therefore directing germline mutation analysis to one gene, saving unnecessary analysis of other mismatch repair genes [1]. Immunohistochemistry is reliable in screening for mutations that result in truncation or degradation of the protein. However, false negatives remain possible in case of missense mutations which result in mutant proteins that are catalytically inactive, but antigenically intact [27]. Moreover, a reduction in the intensity of staining for MSH6 has been described in rectal cancers after neoadjuvant chemoradiation [28]. In these cases, pre-treatment endoscopic biopsies rather than operative material may be used as the primary material for immunohistochemistry.

Heterogeneity in the methods of fixation of tissue samples decreases the sensitivity of the technique. In our experience, the best results are obtained with samples fixed in 10% formalin. But one should bear in mind that immunohistochemical techniques are not standardized enough and are not perfectly reproducible. Thus, immunohistochemistry should only be performed in a specialized setting by experienced pathologists and staining results have to be evaluated with feedback of the molecular background of the tumor [17]. A French association of quality control (AFAQAP, for Association Française d'Assurance Qualité en Anatomie Pathologique) offers tests on MMR proteins immunostaining (MLH1 and MSH2

since 2009 and MSH6 and PMS2 since 2016). Training events are also offered to pathologists, with practical cases.

Earlier studies focusing on MLH1 and MSH2 suggested that IHC has a lower sensitivity (85%) than MSI testing (93%) in predicting germline mutation [16]. When the four MMR proteins are tested, the correlation between loss of MMR protein expression and MSI testing is excellent. In the three main series including 1,144, 1,066 and 1,119 patients suffering from colorectal cancers, sensitivity of MSI tumors detection by immunohistochemistry was 92 %, 93 % and 94 % respectively [1, 29, 30]. In order to reduce costs, some screen using only MSH6 and PMS2, with additional staining of their partner if either are absent (two-stain method) [31]. An expression pattern revealing absent MSH2 and intact MSH6 is not expected, but could result in failed LS detection. In a recent study, Pearlman et al. analyzed tumors with absent MSH2 but any degree of MSH6 expression to determine if the 2-stain method could miss MSH2 mutations. It appeared that the 2-stain immunohistochemical screening for LS in CRC may fail to detect some patients and the authors recommend accordingly the 4-stain method be used for optimal LS screening detection. Interestingly, none of these cases showed diffuse MSH6 staining [32].

To conclude, it can be said that MMR protein analysis by IHC and MSI detection by PCR are equally valid initial screening tests for the detection of a dMMR/MSI phenotype in biological tumor samples. Hence the decision about which screening test to use depends primarily on the availability of resources and expertise [10]. However, we should bear in mind that neither IHC nor PCR is completely sensitive, specific and feasible, as seen previously.

Furthermore, standardization and validation of the accepted reference methods for MSI and dMMR testing in CRC have been mainly done in non-metastatic patients [23, 25, 33, 34]. Information regarding routine clinical use of these methods is lacking, notably in mCRC. This

is despite the fact that novel immunotherapeutic strategies rely upon accurate MSI and/or dMMR testing, since these biomarkers now allow using ICKi in mCRC patients following recent accelerated FDA approvals in the USA. A positive MSI or dMMR status established using only one diagnostic method (PCR or IHC) is currently sufficient for enrollment of advanced cancer patients into most clinical trials using ICKi. Interestingly, by investigating possible mechanisms underlying primary resistance of mCRC patients diagnosed as MSI or dMMR by local laboratories and entered into ICKi trials (NCT02460198 and NCT02060188) at Saint-Antoine hospital (Paris, France), we have recently shown that misdiagnosis of MSI/dMMR status may be responsible for the majority of primary resistant cases [35]. In that study, primary resistance to ICKi was observed in 5 out of 38 MSI/dMMR mCRC patients (13.2%). Re-assessment of the MSI/dMMR status in our laboratory revealed that 3 (60%) of these 5 resistant tumors were MSS/pMMR (microsatellite stable; MMR-proficient). Of the 3 misdiagnosed cases, one was due to misinterpreted IHC results and two due to misinterpreted pentaplex PCR results. One of the 3 mCRC patients whose tumor was mistakenly diagnosed as MSI had been screened with both IHC and PCR, whereas the other two misdiagnosed patients showing primary resistance to ICKi had been tested with only one method. We confirmed these results with one of the largest retrospective tumor collection of MSI mCRC without ICKi treatment (N=93), in which a misdiagnosis of the MSI/dMMR status by local assessment was found in 9.7% (N=9) of patients. It is worth noting that MSI testing with the HT17 assay confirmed the MSI/dMMR status in 2 out of 4 cases showing discrepant results between IHC and pentaplex PCR (*i.e.* dMMR but MSS). Finally, we observed that the combined use of ICH and PCR resulted in a 100% detection rate and 100% sensitivity. We therefore recommend dual testing using both IHC and PCR before ICKi treatment, with referral to expert diagnostic centers in case of discrepant results. The diagnostic performance of the *HSP110* HT17 assay was compared with the other two assays (MMR IHC and

pentaplex MSI) in our mCRC cohort. Of interest, due to the poor quality of some tumor samples in the retrospective cohort, the diagnostic performances of both *HSP110* HT17 and pentaplex PCR were lower than expected. However, among 4 samples exhibiting an MSS phenotype using Pentaplex PCR but a dMMR status with IHC (false negatives), the HT17 assay confirmed an MSI phenotype for 2 cases (from the retrospective cohort). Thus, using the HT17 assay as an additional marker has to be taken into consideration because of its superior sensitivity.

1.4 Emerging techniques

There is a need to for developing specific methods for improving the detection of MSI in some biological contexts. Next-generation sequencing (NGS) is becoming a widespread tool in profiling tumor genomic. NGS has been proposed as a diagnostic method to detect MSI tumors, hypothesizing that the mutational load of a multigene panel may accurately exclude pMMR cancers [36]. With increasing use of NGS for detection of molecular mutations in CRC to predict response to certain therapy, such as mutational status of *BRAF*, *KRAS* and other cancer-associated genes, NGS may replace conventional PCR techniques for MSI detection [37]. However, additional studies should assess the performance of these newer methods for detecting MSI, as recommended by the STARD (STAndards for the Reporting of Diagnostic accuracy studies) statement [38]. Importantly, the FDA recently approved the NGS-based FoundationOne CDx (F1CDx) test to detect multiple genetic mutations as well as microsatellite instability and tumor mutation burden in any solid tumor type. Nevertheless, NGS requires good quality DNA samples from both tumor and normal tissues and is currently restricted to highly specialized laboratories. In this context, the recent development of rapid, cost-effective, and easy to implement new PCR approaches for the ultra-sensitive detection of MSI in CRC and other tumors is of particular interest [39, 40]. They are improvements of the

MSI PCR protocols, *e.g.* the E-ice-COLD-PCR using HT17 where an LNA blocker probe complementary to wild-type HT17 genotypes is used to help the specific amplification of MSI alleles during the polymerase chain reaction. Our group has recently shown their ability to greatly improve MSI detection in CRC samples highly contaminated with normal DNA, which could significantly improve MSI detection in routine clinical testing.

1.5 Algorithm for identification of sporadic CRC and tumors associated with LS:

Identifying LS in patients with CRC is essential and allows them to benefit from close surveillance and risk-reducing surgical procedures. dMMR/MSI sporadic CRC follows epigenetic, biallelic silencing of *MLH1* expression by *de novo* methylation of its promoter. The *BRAF V600E* mutation is seen in approximately 50 to 70% of CRC with *MLH1* promoter methylation [41]. It is important to note that a subset of patients with LS has been reported with a *BRAF V600E* mutation [42].

The extinction of MSH2, MSH6 or PMS2 is rather an argument in favor of LS, although biallelic somatic events affecting these MMR proteins in the absence of germline mutation have been recurrently reported in sporadic setting [43, 44]. In contrast, loss of MLH1 protein expression can be observed in both LS and sporadic colon tumors depending on the mechanism underlying its inactivation in cancer cells, *i.e.* mainly a two-hit genetic mechanism where germline inactivation of one *MLH1* allele is the first hit, or a biallelic epigenetic hypermethylation of the *MLH1* promoter in cancer cells, respectively. Thus, identification of sporadic CRC and tumors associated with LS is based on the loss of MMR proteins, *BRAF* mutational status and *MLH1* promoter methylation status. Briefly, dMMR CRC with MSH2/MSH6 loss of expression, or isolated MSH6 or PMS2 loss of expression should be considered as LS-related tumors, regardless of *BRAF* mutational status, and patients should be referred to oncogenetic testing.

For cases showing loss of MLH1 protein expression by IHC, the DNA methylation pattern of the *MLH1* promoter region is determined by methylation-specific PCR of bisulfite-treated DNA to correctly identify methylated (sporadic) and unmethylated (Lynch-like MSI/dMMR) cases [45]. Tumors are also screened for *BRAF* mutation since this alteration is almost only observed in sporadic MSI CRC.

BRAF mutation analysis is only helpful in the LS screening algorithm of CRC and is not useful for extra-colonic cancers. Extra-colonic cancers may harbor an MLH1 promoter methylation that is not associated with a BRAF V600E mutation.

Constitutional deletion of the *EPCAM* (*TACSTD1*) gene 3' end, which is immediately upstream of the *MSH2* gene, may cause LS through epigenetic silencing of the *MSH2* gene by hypermethylation of its promoter, thus leading to a loss of MSH2 protein expression. This mechanism is thought to account for up to 20% to 25% of LS tumors with loss of MSH2 and MSH6 [46]. Thus, patients whose tumors display loss of MSH2 and MSH6 with no identified *MSH2* germline mutation should be tested for germline deletions in *EPCAM*.

Constitutional epimutation of *MLH1* has been described in a subset of LS patients. Constitutional epimutation refers to epigenetic hypermethylation of the promoter of a gene leading to silencing of expression from the allele in all normal somatic tissues. *MLH1* epimutations are identified by detecting *MLH1* promoter hypermethylation in DNA derived from normal tissue, such as peripheral blood or non-neoplastic colon. A subset of these patients have tumors harboring the *BRAF V600E* mutation [42]. There is no recommendation for the selection of patients requiring *MLH1* epimutation testing in the setting of positive MLH1 promoter hypermethylation. Some authors argue for evaluation of constitutional MLH1 epimutation if the patient is below 60 years of age and/or if there is a strong personal or familial history of LS-associated malignancy [42].

In some cases, patients have tumors with deficient MMR protein expression, but no evidence of a pathogenic germline variant in MMR genes or *EPCAM* and, if the tumor is MLH1-deficient, no evidence of a *BRAF V600E* mutation or *MLH1* promoter hypermethylation within the tumor. These patients are labeled as having “Lynch-like” syndrome. Potential explanations for “Lynch-like” syndrome include failure to detect germline MMR gene alterations using currently available testing methods. Discrepancies between MMR protein IHC analysis and germline testing may result from an incorrect interpretation of MMR IHC results and have to lead to reevaluation of the MMR protein IHC [47]. Some studies also reported biallelic mutations in most tumors in patients with “Lynch-like” syndrome [43, 44]. Finally, other germline gene defects, such as biallelic *MUTYH* mutation, as well as very rare somatic mosaicism can be responsible for “Lynch-like” syndrome [10]. Thus, after checking the original MMR protein IHC in order to confirm loss of MMR protein expression within the patient’s tumor, somatic MMR gene mutation testing of the tumor has to be performed. If a biallelic somatic MMR gene mutation is identified, the patient does not have LS and can likely be screened as for sporadic CRC. If there is no evidence of a biallelic somatic mutation, the patient is highly likely LS and is counseled to follow a screening protocol. Finally, the evaluation of MMR-deficient crypt foci (MMR-DCF), a recently described lesion that occurs in non-neoplastic intestinal mucosa and exhibits loss of MMR protein expression, may be a helpful addition to LS diagnostics particularly in the setting of “Lynch-like” syndrome [48]. Indeed, in this study, MMR-deficient crypt foci were identified only in patients with LS, in 35% of cases and in one patient with Lynch-like syndrome.

2. Determination of MicroSatellite Instability (MSI) and MisMatch repair deficiency (dMMR) in non-colorectal cancers:

2.1 Sporadic and Lynch-related non-colorectal cancers

Gastric cancers, endometrial cancers (EC) and CRC are the three main tumor types displaying a dMMR/MSI phenotype. Investigation of all endometrial carcinoma in individuals less than 70 years by immunohistochemistry or MSI can be considered to improve identification (grade of recommendation C) [49]. Universal screening for LS in EC patients has yielded positive results for identification of patients at risk for this inherited syndrome [50]. Immunohistochemistry is recommended as a primary screen for LS in patients with newly diagnosed EC [51]. The sensitivity of IHC using a panel of 4 MMR antibodies (against MLH1, MSH2, MSH6, and PMS2) is as high as that of MSI testing [51].

The French ‘Thésaurus national de gastroentérologie’, based on the secondary post-hoc analysis of the MAGIC trial, also suggests investigating all gastroesophageal cancers. In the MAGIC trial, a dMMR/MSI status was associated with a positive prognostic effect in patients treated with surgery alone and a differentially negative prognostic effect in patients treated with chemotherapy. If independently validated, MSI or MMR deficiency determined by preoperative biopsies could be used to select patients for perioperative chemotherapy [52]. The recent success of immunotherapy in high-frequency dMMR/MSI tumors now supports testing for MSI in all advanced solid tumors.

As seen previously, IHC and PCR methods are equally valid initial screening tests for dMMR/MSI in CRC. By contrast, there is no recommendation for detection of the dMMR/MSI phenotype in other primary tumor types. It is worth noting that these two methods have been mainly calibrated for CRC and endometrial cancers. However, it seems that the sensitivity and specificity of each of the two methods could be different according to the tissue. In gastric cancer for example, similarly to CRC, the two methods seem to be equally valid, and IHC (using antibodies directed against MLH1 and MSH2) predicts MSI

status with a high sensitivity and specificity [53]. On the contrary, for pancreatic ductal adenocarcinoma (PDAC), we recently showed that IHC using antibodies against the four MMR proteins was more sensitive for the assessment of dMMR/MSI status than PCR-based methods. Indeed, among the 9 cases identified as dMMR/MSI, 8 showed loss of MMR protein expression by IHC whereas only 5 were found to harbor MSI by PCR [14]. These results were in line with data from a recent publication that used whole genome and exome sequencing [54]. The explanation for the discordant results between IHC and PCR in PDAC is very likely the high amount of desmoplastic stroma typically found in this carcinoma. This can lead to false negative results with molecular methods due to the dilution of tumor DNA with large amounts of normal DNA derived from peri- and intra-tumoral stroma. The HT17 marker was used here for the first time for the detection of MSI in PDAC. HT17 appears to be a superior marker for diagnosis of the MSI phenotype in PDAC compared with the standard panel of Pentaplex markers.

As for CRC, NGS methods to detect MSI may replace the current method of MSI detection by conventional PCR techniques [37]. However, before generalizing NGS as a diagnostic method to detect MSI tumors, the best method (IHC and/or PCR) for dMMR/MSI testing remains to be determined – and is probably different - for each tissue. Interestingly, in a very recent paper, the MSI status was determined using targeted NGS, with tumors classified as MSI-H, MSI-indeterminate, or microsatellite-stable (more than 50 cancer types among 15,045 patients). Matched germline DNA was analyzed for mutations in LS-associated mismatch repair genes (MLH1, MSH2, MSH6, PMS2, EPCAM). Immunohistochemical staining of LS-positive MSI-H/I tumors, including besides CRC and EC urothelial, prostate, pancreatic, adrenocortical, small bowel, sarcoma, mesothelioma, melanoma, gastric, and germ cell tumors, demonstrated MMR deficiency in 98.2% (56 of 57) of available cases, suggesting that dMMR IHC may also be a suitable screen in non-canonical tumors [15]. Finally,

similarly to metastatic CRC, dual testing using both IHC and PCR should probably be performed before ICKi treatment, with referral to expert diagnostic centers in case of discrepant results.

2.2 Constitutional MMR deficiency (CMMRD)

Besides LS that occurs in patients harboring heterozygous germline MMR defects, the constitutional MMR deficiency (CMMRD) syndrome has been more recently reported. CMMRD occurs in patients with biallelic germline mutations and is characterized by the development of childhood tumors such as early-onset CRC, lymphomas/leukemias, and brain tumors (for review, Lavoine et al.) [55]. This diagnosis is made through the identification of biallelic deleterious mutations in MMR genes by germline DNA sequencing. This method is time-consuming and it lacks sensitivity, leading to non-informative results in one third of patients (detection of variants of unknown significance). In this clinical context, we have proposed in 2015 a functional test to diagnose CMMRD in at-risk individuals using peripheral blood lymphocytes [56]. This test consists in identifying in these cells two functional consequences of constitutive MMR-deficiency: (i) an MSI phenotype following EBV immortalization; (ii) a phenotype of cell tolerance to specific drugs (methylating agents). This method is now routinely used to prospectively identify patients at risk for CMMRD syndrome in the platform of Saint-Antoine hospital. Following these functional tests, NGS and/or new proposed PCR approaches for the ultra-sensitive detection of MSI such as ice-COLD-PCR and others [39, 40] should now be developed to make possible the detection of ultra low levels of MSI in the MMR-deficient primary blood cells from CMMRD patients. Since positive response to treatment with ICKi has recently been reported in children with CMMRD-related cancers, this should allow accurate and rapid diagnosis of CMMRD prior to

treatment with immunotherapy in children affected by such a rare but severe condition that predisposes them to cancer.

Conclusion

Universal screening of all newly diagnosed CRC for MMR deficiency is now recommended worldwide by the scientific and medical community. Moreover, there is increasing evidence supporting the systematic evaluation of dMMR/MSI in a broad spectrum of tumors, regardless of the cancer tissue of origin, for prognosis and therapy decisions. Both MMR protein analysis by IHC (by using 4 antibodies) and MSI detection by PCR are valid initial screening tests for the detection of a dMMR/MSI phenotype in tumor samples, the decision about which screening test to use depending primarily on the availability of resources and expertise. However, for patients with advanced tumors, dual testing using both IHC and PCR is recommended to avoid misdiagnosis prior to treatment with ICKi with referral to expert diagnostic centers in case of discrepant results. Emerging methods based on NGS or modifications of the PCR protocol should progressively become the gold standards to detect MSI in pan-cancer.

Figure legends:

Figure 1: MisMatch Repair (MMR) protein immunostaining in a colorectal cancer. This colorectal cancer is referred to as MLH1 deficient. (A) There is a loss of expression of MLH1 in neoplastic cells; (B) This tumor also shows loss of PMS2 protein expression; however, (C) MSH2 and (D) MSH6 are normally expressed.

Figure 2: Determination of the MSI status. A) Standard method, referred to as pentaplex PCR, requires five monomorphic mononucleotide microsatellite loci. Amplified sequences profiles produce multi-peaked profiles by commonly used fragment analysis, that are restricted to a narrow area in microsatellite scale (MSS, upper profiles). MSI samples exhibit new peaks away from the stable area, corresponding generally to the appearance of deleted somatic variants (MSI, lower profiles with mut areas). B) HT17, a seventeen thymines tract in intron 8 of *HSPH1* gene is almost always mutated in MSI tumors, and may greatly improve the diagnosis, in particular due to its very low natural variation in size.

REFERENCES

1. Hampel H, Frankel WL, Martin E, Arnold M, Khanduja K, Kuebler P, et al. . Screening for the Lynch syndrome (hereditary nonpolyposis colorectal cancer). *N Engl J Med* 2005;352:1851-60.
2. Veigl ML, Kasturi L, Olechnowicz J, Ma AH, Lutterbaugh JD, Periyasamy S, et al. . Biallelic inactivation of hMLH1 by epigenetic gene silencing, a novel mechanism causing human MSI cancers. *Proc Natl Acad Sci U S A*. 1998;95:8698-702.
3. Sargent DJ, Marsoni S, Monges G, Thibodeau SN, Labianca R, Hamilton SR, et al. Defective mismatch repair as a predictive marker for lack of efficacy of fluorouracil-based adjuvant therapy in colon cancer. *J Clin Oncol* 2010;28:3219-26.
4. Dorard C, de Thonel A, Collura A, Marisa L, Svrcek M, Lagrange A, Jegou G, et al. Expression of a mutant HSP110 sensitizes colorectal cancer cells to chemotherapy and improves disease prognosis. *Nat Med*. 2011;17:1283-9.
5. Collura A, Lagrange A, Svrcek M, Marisa L, Buhard O, Guilloux A, et al. . Patients with colorectal tumors with microsatellite instability and large deletions in HSP110 T17 have improved response to 5-fluorouracil-based chemotherapy. *Gastroenterology* 2014;146:401-11.e1
6. Le DT, Uram JN, Wang H, Bartlett BR, Kemberling H, Eyring AD, et al. PD-1 Blockade in Tumors with Mismatch-Repair Deficiency. *N Engl J Med* 2015;372:2509–24 20.
7. Le DT, Durham JN, Smith KN, Wang H, Bartlett BR, Aulakh LK, et al. Mismatch repair deficiency predicts response of solid tumors to PD-1 blockade. *Science*. 2017;357:409-413.
8. Overman MJ, McDermott R, Leach JL, Lonardi S, Lenz H-J, Morse MA, et al. Nivolumab in patients with metastatic DNA mismatch repair-deficient or microsatellite instability-high colorectal cancer (CheckMate 142): an open-label, multicentre, phase 2 study. *Lancet Oncol* 2017;18:1182–91.
9. Overman MJ, Lonardi S, Wong KYM, Lenz H-J, Gelsomino F, Aglietta M, et al. Durable Clinical Benefit With Nivolumab Plus Ipilimumab in DNA Mismatch Repair–Deficient/Microsatellite Instability–High Metastatic Colorectal Cancer. *J Clin Oncol*. 2018;36:773-779.
10. Pai RK, Pai RK. A Practical Approach to the Evaluation of Gastrointestinal Tract Carcinomas for Lynch Syndrome. *Am J Surg Pathol*. 2016;40:e17-34.
11. Van Cutsem E, Cervantes A, Adam R, Sobrero A, Van Krieken JH, Aderka D, et al. ESMO consensus guidelines for the management of patients with metastatic colorectal cancer. *Ann Oncol*. 2016;27:1386-422.

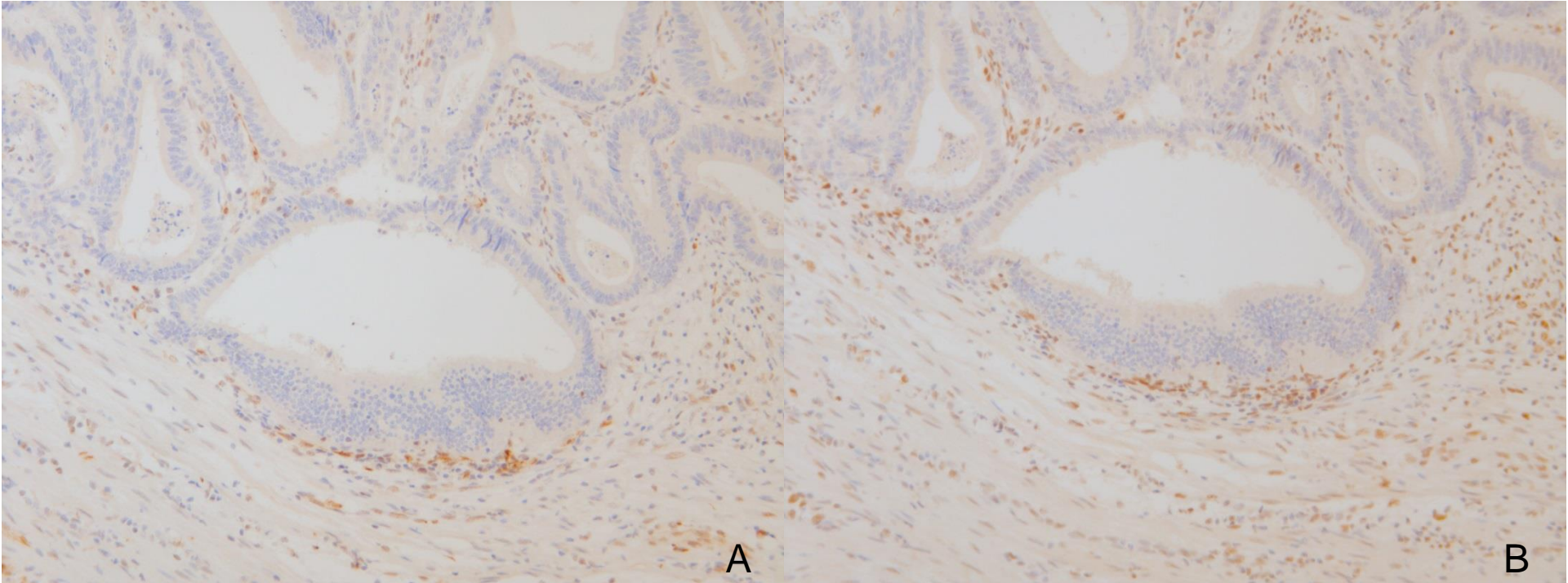
12. Hause RJ, Pritchard CC, Shendure J, Salipante SJ. Classification and characterization of microsatellite instability across 18 cancer types. *Nat Med.* 2016;22:1342-1350.
13. Espenschied CR, LaDuca H, Li S, McFarland R, Gau CL, Hampel H. Multigene Panel Testing Provides a New Perspective on Lynch Syndrome. *J Clin Oncol.* 2017;35:2568-2575.
14. Lupinacci RM, Goloudina A, Buhard O, Bachet JB, Maréchal R, Demetter P, et al. Prevalence of Microsatellite Instability in Intraductal Papillary Mucinous Neoplasms of the Pancreas. *Gastroenterology* 2018;154:1061-1065.
15. Latham A, Srinivasan P, Kemel Y, Shia J, Bandlamudi C, Mandelker D, et al. Microsatellite Instability Is Associated With the Presence of Lynch Syndrome Pan-Cancer. *J Clin Oncol.* 2018 Oct 30;JCO1800283. doi: 10.1200/JCO.18.00283. [Epub ahead of print]
16. Shia J. Immunohistochemistry versus microsatellite instability testing for screening colorectal cancer patients at risk for hereditary nonpolyposis colorectal cancer syndrome. Part I. The utility of immunohistochemistry. *J Mol Diagn.* 2008;10:293-300.
17. Overbeek LI, Ligtenberg MJ, Willems RW, Hermens RP, Blokx WA, Dubois SV, et al. Interpretation of immunohistochemistry for mismatch repair proteins is only reliable in a specialized setting. *Am J Surg Pathol* 2008;32:1246-51.
18. Kadyrov FA, Dzantiev L, Constantin N, Modrich P. Endonucleolytic function of MutLalpha in human mismatch repair. *Cell.* 2006;126:297-308.
19. Acharya S, Wilson T, Gradia S, Kane MF, Guerrette S, Marsischky GT, et al. hMSH2 forms specific mismatch-binding complexes with hMSH3 and hMSH6. *Proc Natl Acad Sci U S A.* 1996;93:13629-34.
20. Walsh MD, Buchanan DD, Pearson SA, Clendenning M, Jenkins MA, Win AK, et al. Immunohistochemical testing of conventional adenomas for loss of expression of mismatch repair proteins in Lynch syndrome mutation carriers: a case series from the Australasian site of the colon cancer family registry. *Mod Pathol* 2012;25:722-30.
21. Boland CR, Thibodeau SN, Hamilton SR, Sidransky D, Eshleman JR, Burt RW, et al. A National Cancer Institute Workshop on Microsatellite Instability for cancer detection and familial predisposition: development of international criteria for the determination of microsatellite instability in colorectal cancer. *Cancer Res.* 1998;58:5248-57.
22. Suraweera N, Duval A, Reperant M, Vaury C, Furlan D, Leroy K, et al. Evaluation of tumor microsatellite instability using five quasimonomorphic mononucleotide repeats and pentaplex PCR. *Gastroenterology* 2002;123:1804-11.
23. Umar A, Boland CR, Terdiman JP, Syngal S, Chappelle A d. l., Ruschhoff J, et al. Revised Bethesda Guidelines for Hereditary Nonpolyposis Colorectal Cancer (Lynch Syndrome) and Microsatellite Instability. *J Natl Cancer Inst* 2004;96:261-8.

24. Goel A, Nagasaka T, Hamelin R, Boland CR. An optimized pentaplex PCR for detecting DNA mismatch repair-deficient colorectal cancers. *PloS One* 2010;5:e9393.
25. Buhard O, Lagrange A, Guilloux A, Colas C, Chouchène M, Wanherdrick K, et al. HSP110 T17 simplifies and improves the microsatellite instability testing in patients with colorectal cancer. *J Med Genet*. 2016;53:377-84.
26. Berardinelli GN, Scapulatempo-Neto C, Durães R, Antônio de Oliveira M, Guimarães D, Reis RM. Advantage of *HSP110* (T17) marker inclusion for microsatellite instability (MSI) detection in colorectal cancer patients. *Oncotarget*. 2018;9:28691-28701.
27. Peltomäki P, Vasen H. Mutations associated with HNPCC predisposition -- Update of ICG-HNPCC/INSiGHT mutation database. *Dis Markers*. 2004;20:269-76.
28. Bao F, Panarelli NC, Rennert H, Sherr DL, Yantiss RK. Neoadjuvant therapy induces loss of MSH6 expression in colorectal carcinoma. *Am J Surg Pathol*. 2010;34:1798-804.
29. Lindor NM, Burgart LJ, Leontovich O, et al. Immunohistochemistry versus microsatellite instability testing in phenotyping colorectal tumors. *J Clin Oncol* 2002;20:1043-8.
30. Engel C, Forberg J, Holinski-Feder E, et al. Novel strategy for optimal sequential application of clinical criteria, immunohistochemistry and microsatellite analysis in the diagnosis of hereditary nonpolyposis colorectal cancer. *Int J Cancer* 2006;118:115-22.
31. Shia J, Tang LH, Vakiani E, Guillem JG, Stadler ZK, Soslow RA, et al. Immunohistochemistry as first-line screening for detecting colorectal cancer patients at risk for hereditary nonpolyposis colorectal cancer syndrome: a 2-antibody panel may be as predictive as a 4-antibody panel. *Am J Surg Pathol*. 2009;33:1639-45.
32. Pearlman R, Markow M, Knight D, Chen W, Arnold CA, Pritchard CC, et al. Two-stain immunohistochemical screening for Lynch syndrome in colorectal cancer may fail to detect mismatch repair deficiency. *Mod Pathol*. 2018 Jul 2. doi: 10.1038/s41379-018-0058-y. [Epub ahead of print]
33. Buhard O, Cattaneo F, Wong YF, Yim SF, Friedman E, Flejou J-F, et al. Multipopulation Analysis of Polymorphisms in Five Mononucleotide Repeats Used to Determine the Microsatellite Instability Status of Human Tumors. *J Clin Oncol* 2006;24:241-51.
34. Zhang L. Immunohistochemistry versus Microsatellite Instability Testing for Screening Colorectal Cancer Patients at Risk for Hereditary Nonpolyposis Colorectal Cancer Syndrome: Part II. The Utility of Microsatellite Instability Testing. *J Mol Diagn*. 2008;10(4):301-307.

35. Cohen R, Hain E, Buhard O, Guilloux A, Bardier A, Kaci R, et al. Association of Primary Resistance to Immune Checkpoint Inhibitors in Metastatic Colorectal Cancer With Misdiagnosis of Microsatellite Instability or Mismatch Repair Deficiency Status. *JAMA Oncol.* 2018 Nov 15. doi: 10.1001/jamaoncol.2018.4942. [Epub ahead of print]
36. Stadler ZK, Battaglin F, Middha S, Hechtman JF, Tran C, Cercek A, et al. Reliable Detection of Mismatch Repair Deficiency in Colorectal Cancers Using Mutational Load in Next-Generation Sequencing Panels. *J Clin Oncol.* 2016;34:2141-7.
37. Hampel H, Pearlman R, Beightol M, Zhao W, Jones D, Frankel WL, et al; Ohio Colorectal Cancer Prevention Initiative Study Group. Assessment of Tumor Sequencing as a Replacement for Lynch Syndrome Screening and Current Molecular Tests for Patients With Colorectal Cancer. *JAMA Oncol.* 2018;4:806-813.
38. Cohen JF, Korevaar DA, Altman DG, Bruns DE, Gatsonis CA, Hooft L, et al. STARD 2015 guidelines for reporting diagnostic accuracy studies: explanation and elaboration. *BMJ Open* 2016;6:e012799. doi:10.1136/bmjopen-2016-012799.
39. How-Kit A, Daunay A, Buhard O, Meiller C, Sahbatou M, Collura A, et al. Major improvement in the detection of microsatellite instability in colorectal cancer using HSP110 T17 E-ice-COLD-PCR. *Hum Mutat.* 2018;39:441-453.
40. Baudrin LG, Duval A, Daunay A, Buhard O, Bui H, Deleuze JF, How-Kit A. Improved Microsatellite Instability Detection and Identification by Nuclease-Assisted Microsatellite Instability Enrichment Using HSP110 T17. *Clin Chem.* 2018 Aug;64(8):1252-1253.
41. Parsons MT, Buchanan DD, Thompson B, Young JP, Spurdle AB. Correlation of tumour BRAF mutations and MLH1 methylation with germline mismatch repair (MMR) gene mutation status: a literature review assessing utility of tumour features for MMR variant classification. *J Med Genet.* 2012;49:151-7.
42. Hitchins MP. The role of epigenetics in Lynch syndrome. *Fam Cancer.* 2013;12:189-205.
43. Sourrouille I, Coulet F, Lefevre JH, Colas C, Eyries M, Svrcek M, Bardier-Dupas A, Parc Y, Soubrier F. Somatic mosaicism and double somatic hits can lead to MSI colorectal tumors. *Fam Cancer.* 2013 Mar;12(1):27-33.
44. Mensenkamp AR, Vogelaar IP, van Zelst-Stams WA, Goossens M, Ouchene H, Hendriks-Cornelissen SJ, et al. Somatic mutations in MLH1 and MSH2 are a frequent cause of mismatch-repair deficiency in Lynch syndrome-like tumors. *Gastroenterology.* 2014;146:643-646.e8.
45. Capel E, Fléjou JF, Hamelin R. Assessment of MLH1 promoter methylation in relation to gene expression requires specific analysis. *Oncogene.* 2007;26:7596-600.
46. Ligtenberg MJ, Kuiper RP, Chan TL, Goossens M, Hebeda KM, Voorendt M, et al. Heritable somatic methylation and inactivation of MSH2 in families with Lynch

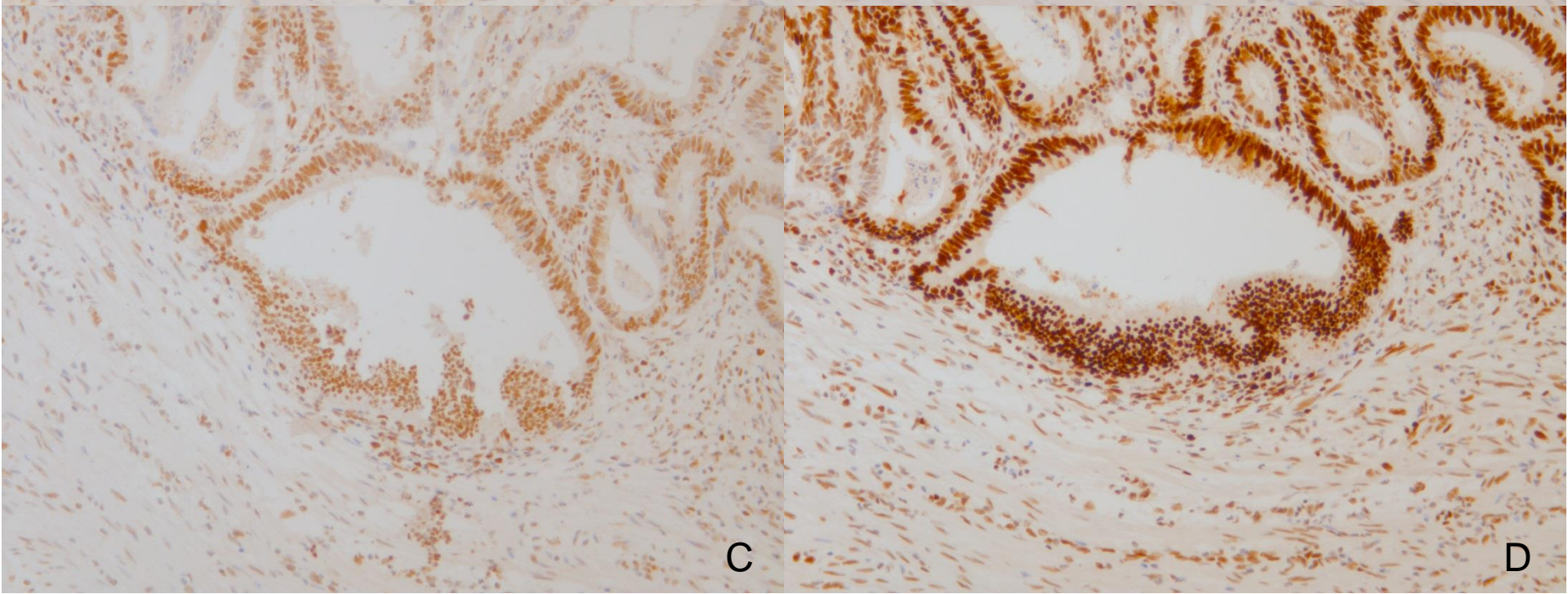
syndrome due to deletion of the 3' exons of TACSTD1. *Nat Genet.* 2009 Jan;41(1):112-7.

47. Boland CR, Goel A. Microsatellite instability in colorectal cancer. *Gastroenterology.* 2010 Jun;138(6):2073-2087.
48. Pai RK, Dudley B, Karloski E, Brand RE, O'Callaghan N, Rosty C, et al. DNA mismatch repair protein deficient non-neoplastic colonic crypts: a novel indicator of Lynch syndrome. *Mod Pathol.* 2018 Oct;31(10):1608-1618.
49. Vasen HF, Blanco I, Aktan-Collan K, Gopie JP, Alonso A, Aretz S, et al; Mallorca group. Revised guidelines for the clinical management of Lynch syndrome (HNPCC): recommendations by a group of European experts. *Gut.* 2013;62:812-23.
50. Dillon JL, Gonzalez JL, DeMars L, Bloch KJ, Tafe LJ. Universal screening for Lynch syndrome in endometrial cancers: frequency of germline mutations and identification of patients with Lynch-like syndrome. *Hum Pathol.* 2017 Dec;70:121-128.
51. Weissman SM, Burt R, Church J, Erdman S, Hampel H, Holter S, et al. Identification of individuals at risk for Lynch syndrome using targeted evaluations and genetic testing: National Society of Genetic Counselors and the Collaborative Group of the Americas on Inherited Colorectal Cancer joint practice guideline. *J Genet Couns.* 2012;21:484-93.
52. Smyth EC, Wotherspoon A, Peckitt C, Gonzalez D, Hulkki-Wilson S, Eltahir Z, et al. Mismatch Repair Deficiency, Microsatellite Instability, and Survival: An Exploratory Analysis of the Medical Research Council Adjuvant Gastric Infusional Chemotherapy (MAGIC) Trial. *JAMA Oncol.* 2017;3:1197-1203.
53. Bae YS, Kim H, Noh SH, Kim H. Usefulness of Immunohistochemistry for Microsatellite Instability Screening in Gastric Cancer. *Gut Liver.* 2015 Sep 23;9(5):629-35.
54. Humphris JL, Patch AM, Nones K, Bailey PJ, Johns AL, McKay S, et al. Hypermutation In Pancreatic Cancer. *Gastroenterology.* 2017 Jan;152(1):68-74.
55. Lavoine N, Colas C, Muleris M, Bodo S, Duval A, Entz-Werle N, et al. Constitutional mismatch repair deficiency syndrome: clinical description in a French cohort. *J Med Genet.* 2015 Nov;52:770-8.
56. Bodo S, Colas C, Buhard O, Collura A, Tinat J, Lavoine N, et al. Diagnosis of Constitutional Mismatch Repair-Deficiency Syndrome Based on Microsatellite Instability and Lymphocyte Tolerance to Methylating Agents. *Gastroenterology* 2015;149:1017-29.e3.



A

B



C

D

A

NR27

NR21

NR24

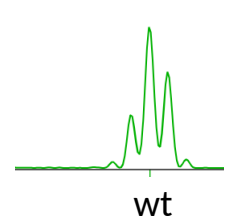
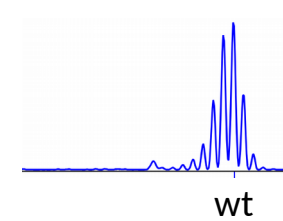
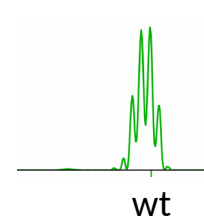
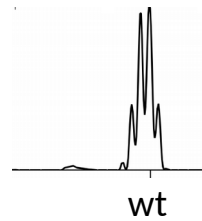
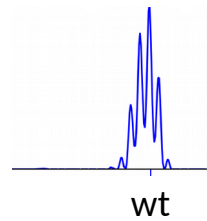
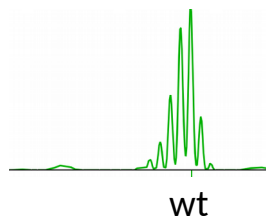
BAT25

BAT26

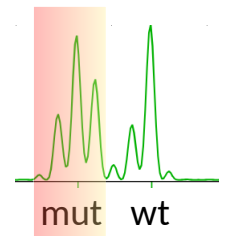
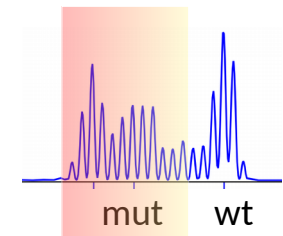
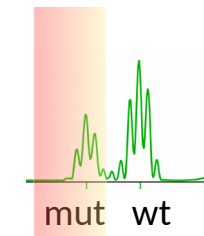
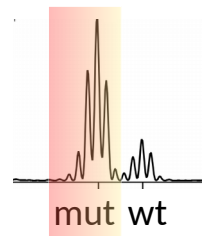
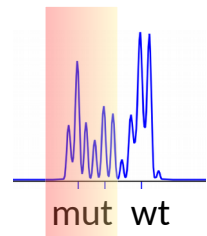
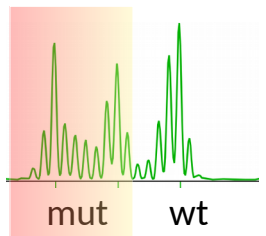
B

HT17

MSS



MSI



Determination of the MSI status. A) Standard method, referred to as pentaplex PCR, requires five monomorphic mononucleotide microsatellite loci. Amplified sequences profiles produce multi-peaked profiles by commonly used fragment analysis, that are restricted to a narrow area in microsatellite stable cases (MSS, upper profiles). MSI samples exhibit new peaks away from the stable area, corresponding generally to the appearance of deleted somatic variants (MSI, lower profiles with mut colored areas). B) HT17, a seventeen thymines tract in intron 8 of *HSPH1* gene is almost always mutated in MSI tumors, and may greatly improve the diagnosis, in particular due to its very low natural variation in size.