Localization, Morphologic Features, and Chemical Composition of Calciphylaxis-Related Skin Deposits in Patients With Calcific Uremic Arteriolopathy

Hester Colboc, Philippe Moguelet, Dominique Bazin, Priscille Carvalho, Anne-Sophie Dillies, Guillaume Chaby, Hervé Maillard, Diane Kottler, Elisa Goujon, Christine Jurus, et al.

Original Investigation

Localization, Morphology and Chemical Composition of Calciphylaxis-Related Skin Deposits

Running head: Characterization of calciphylaxis-related skin deposits

Manuscript word count: 2902/3000; Table count: 1; Figure count: 4

Online supplement: eTable 1

Hester Colboc, MD; Philippe Moguelet, MD;* Dominique Bazin, MD;* Priscille Carvalho, MD; Anne-Sophie Dillies, MD; Guillaume Chaby, MD; Hervé Maillard, MD; Diane Kottler, MD; Elisa Goujon, MD; Christine Jurus, MD; Marine Panaye, MD; Vincent Frochot, MD; Emmanuel Letavernier, MD, PhD; Michel Daudon, MD; Ivan Lucas, MD; Raphaël Weil, MD; Philippe Courville, MD; Jean-Benoit Monfort, MD; François Chasset, MD; Patricia Senet, MD; on behalf of the Groupe Angio-Dermatologie of the French Society of Dermatology

Author Affiliations: Sorbonne Université, Hôpital Rothschild, Service Plaies et Cicatrisation, Paris (Colboc); Sorbonne Université, Hôpital Tenon, Anatomie et Cytologie Pathologiques, Paris, (Moguelet); CNRS, Laboratoire de Chimie Physique, Ba340, Université Paris XI, 91405 Orsay (Bazin); Centre Hospitalier Universitaire de Rouen, Service de Dermatologie, Rouen (Carvalho); Centre Hospitalier Universitaire d'Amiens, Service de Dermatologie, Amiens (Dillies, Chaby); Centre Hospitalier du Mans, Service de Dermatologie, Le Mans (Maillard); Hôpital Bichat, Service de Dermatologie, Paris (Kottler); Centre Hospitalier de Chalon-sur-Saône, Service de Dermatologie, Chalon-sur-Saône (Goujon); Clinique du Tonkin, Service de Médecine Vasculaire, Villeurbanne (Jurus, Panaye); Sorbonne Université, Hôpital Tenon, Service des Explorations Fonctionnelles Multidisciplinaires, Paris (Frochot,

Letavernier, Daudon); Sorbonne Universités, UMR 8235, Paris (Lucas); CNRS, LPS, Ba510, Université Paris XI, 91405 Orsay (Weil); Centre Hospitalier Universitaire de Rouen, Anatomie et Cytologie Pathologiques, Rouen (Courville); Sorbonne Université, Hôpital Tenon, Service de Dermatologie, Paris (Monfort, Chasset, Senet)—all in France.

*These authors contributed equally to this work.

Corresponding Author: Dr Hester Colboc, APHP, Service Plaies et Cicatrisation, Hôpital Rothschild, 5, Rue Santerre, 75012 Paris, France. Phone: +33 (0)6 03 61 16 23; (hester.colboc@aphp.fr)

Funding sources: None

Conflicts of interest: None declared

Word count: 2902/3000

Key Points

Question What are the precise localization, morphology and chemical composition of calciphylaxis-related skin deposits?

Findings CUA calcifications are composed of pure calcium–phosphate apatite, always located circumferentially, mostly in the intima of otherwise normal-looking vessels, and often associated with interstitial deposits, unlike calcifications observed in cutaneous arteriolosclerotic vessels, which are associated with medial hypertrophy containing the calcifications and no interstitial deposits.

Meaning The differences observed between CUA and cutaneous arteriolosclerosis regarding calcification location and vessel morphology suggest different pathogenetic mechanisms and provide new insights into CUA pathogenesis that could explain the poor efficacy of vasodilators and the therapeutic effect of calcium-solubilizing drugs.

Abstract 311/350

IMPORTANCE Calcific uremic arteriolopathy (CUA), a rare disease with calcium deposits in skin, mostly affects dialyzed, end-stage renal disease patients. Chemical composition and structure of CUA calcifications have been poorly described.

OBJECTIVES To describe the localization and morphology, determine the precise chemical composition of CUA-related calcium deposits in skin, and identify any mortality-associated factors.

DESIGN A retrospective, multicenter ~~case–control~~ study was conducted between January 2006 and January 2017.

SETTING Seven French hospitals participated in the study.

PARTICIPANTS This study included consecutive adults diagnosed with CUA, confirmed according to Hayashi's clinical and histologic criteria. Patients with normal renal function were excluded. For comparison, 5 skin samples from patients with arteriolosclerosis and 5 others from the negative margins of skin-carcinoma resections were also analyzed.

MAIN OUTCOME(S) AND MEASURE(S) Localization and morphology of the CUA-related cutaneous calcium deposits were assessed with optical microscopy and field-emission–scanning electron microscopy (FE-SEM), and the chemical compositions of those deposits were evaluated with µFourier transform infra-red (FT-IR) spectroscopy, Raman spectroscopy and energy dispersive X-ray (EDX).

RESULTS Thirty-six patients (median age: 64 years) were included, and 29 cutaneous biopsies were analyzed. CUA and arteriolosclerosis skin calcifications were composed of pure calcium–phosphate apatite. CUA vascular calcifications were always circumferential, found in small-to-medium–sized vessels, with interstitial deposits in 76% of the samples. A thrombosis, most often in noncalcified capillary lumens in the superficial dermis, was seen in 5 CUA patients' samples. Except for calcium deposits, CUA patients' vessel structure

appeared normal, unlike thickened arteriolosclerotic vessel walls. Twelve (33%) patients died of CUA.

CONCLUSIONS AND RELEVANCE CUA-related skin calcifications were exclusively composed of pure calcium–phosphate apatite, localized circumferentially in small-to-medium–sized vessels and often associated with interstitial deposits, suggesting its pathogenesis differs from that of arteriolosclerosis. Although the chemical compositions of CUA and arteriolosclerosis calcifications were similar, the vessels' appearances and deposit localizations differed, suggesting different pathogenetic mechanisms.

Introduction

Uremic calciphylaxis, also called calcific uremic arteriolopathy (CUA), is a rare and severely morbid condition that predominantly affects dialyzed, end-stage renal disease (ESRD) patients. Its frequency among ESRD patients reaches 4% and its incidence increases for those on hemodialysis.[1] CUA's significant morbidity and mortality result from extensive skin necrosis and septic complications, with the latter being the leading cause of death. For ESRD patients, an increased risk of subsequent CUA development has been associated with female sex, diabetes mellitus, higher body mass index, elevated serum calcium, phosphorus and parathyroid hormone levels, nutritional status ~~cinacalcet~~ or vitamin K-antagonist treatments.[2]

Although noninvasive imaging tools (eg, plain X-rays) have been reported to help diagnose CUA,[3] none of those tools have been systematically evaluated.[4] Definitive CUA diagnosis requires a skin biopsy. However, because biopsying the skin is associated with the risk of new ulceration, bleeding and infection, actually obtaining one is ~~often discussed~~ sometimes debated.[5] When obtained, deep cutaneous biopsies of CUA lesions show small-sized calcifications, <500 µm, in hypodermal vessels and/or interstitial tissue, highly suggestive of CUA with good specificity.[6]

Despite well-characterized clinical and histologic descriptions of CUA, its precise pathogenetic mechanism remains unclear.[7] Arteriolar calcification is probably the first event, followed by thrombosis and skin ischemia. Chemical composition determination and description of the skin calcifications through physicochemical techniques could contribute to understanding CUA pathogenesis, leading to more appropriate and specific treatments.[8] Indeed, nanotechnologies are receiving increased attention to improve understanding of the effects of pathologic deposits on living tissues.[9,10]

The aims of this study were to determine precisely the localization, morphology and chemical composition of calcifications in the skin of CUA patients, and then examine whether

any association could be established between their microscopy findings and clinical characteristics.

Methods

This study was conducted in compliance with Good Clinical Practices and the Declaration of Helsinki, and in accordance with French law. Formal Ethics Committee approval of the study protocol was obtained (no. EudraCT 2017-000906-39).

Case Selection and Histopathologic Analyses

This retrospective ~~case-control~~ study included consecutive adults diagnosed with CUA, confirmed according to Hayashi's clinical and histologic criteria, and seen in 7 French hospitals between January 2006 and January 2017.[11] Patients with normal renal function were excluded. Patients' medical histories, treatments and laboratory findings were extracted from their medical charts. They were classified into 2 clinical subgroups, distal or proximal CUA, according to the skin-lesion localizations described by Brandenburg et al.[12]

Five skin samples from patients with arteriolosclerosis and 5 others from the negative margins of skin carcinoma resections on the leg were included and served as controls. All 10 controls had normal renal function; only the 5 with arteriolosclerosis from among a cohort of patients with necrotic angiodermatitis had leg-skin biopsies.

Skin-biopsy samples were sent to and centralized in Tenon Hospital, Department of Pathology. For each subject, 1.5-µm–thick sections of paraffin-embedded skin biopsies were deposited on glass slides, for hematoxylin–eosin–saffron (HES) and von Kossa staining, and low-e microscope slides (MirrIR, Kevley Technologies, Tienta Sciences, Indianapolis, IN, USA) for field-emission–scanning electron microscopy (FE-SEM), µFourier transform infra-red (FT-IR) spectroscopy and Raman spectroscopy.[13] Vascular and interstitial calcifications,

the calibers of calcified vessels and the topography of deposits in skin sections were analyzed and compared between CUA patients and controls.

FE-SEM

FE-SEM (Zeiss SUPRA55-VP, Oberkochen, Germany) was used to describe the ultrastructural characteristics of tissue sections. As previously described, high-resolution images were obtained with in-lens and Everhart-Thornley secondary electron detectors.[14] Measurements were taken at low voltage (1–2 kV), without the usual carbon-coating of the sample surface. For some samples, energy-dispersive X-ray (EDX) was also used to identify calcium in the abnormal deposits.

FT-IR and Raman Spectroscopies

Using the same sample as that for FE-SEM analyses, FT-IR and Raman spectroscopies identified the chemical compositions of the CUA calcifications. All the FT-IR hyperspectral images were recorded with a Spectrum Spotlight 400 FT-IR imaging system (Perkin–Elmer Life Sciences, Courtaboeuf, France), with 6.25-mm spatial resolution and 8-cm^{-1} spectral resolution.[16] Raman spectra were collected with a micro-Raman system (LabRam HR-800 Evolution, Horiba, Japan) using 785-nm laser excitation wavelength, 100× objective (Olympus, numerical aperture 0.9) and 300 grooves per mm grating. Spectra were corrected at baseline to suppress the strong luminescence background.[15]

Statistical Analyses

Data are expressed as median [range] or number (%). χ^2 or Fisher's exact tests were used to compare qualitative variables; Wilcoxon or Mann–Whitney tests were used to compare paired or nonpaired nonnormally distributed variables, respectively. Parameters with $P < .2$ in

univariate analysis were entered into a multivariate logistic-regression model, with *Y* as the dependent variable.

Results

Clinical and Histopathologic Findings

Among the 36 CUA patients included, 29 skin biopsies could be analyzed by optical microscopy, FE-SEM and spectroscopies. Clinical and histopathologic data are summarized in Table 1.

Optical microscopy analysis of HES- and von Kossa-stained CUA biopsies always found calcifications in small-and/or-medium–sized vessels (diameter: 10–300 μm), mostly in hypodermal arterioles and capillaries (Figure 1). These deposits were massive, occupying in the entire circumference of the vessel, and located in the intima and sometimes the media. They could be associated with intimal fibrous or myxoid changes.

Those CUA vascular calcifications were associated with interstitial deposits, mainly localized to the hypodermis, in 76% of the samples. Calcification size ranged from 1 to 500 μm, sometimes becoming confluent, with clusters reaching several millimeters in diameter. They were either isolated small clusters between adipocytes (Figure 2A and B) or aligned in a pearl collar along the cytoplasmic membranes of adipocytes (Figure 2D and E). Calcified elastic fibers and/or collagen fibers were also seen in hypodermic septa or deep dermis. Thromboses were seen in 5 samples, most often in noncalcified capillaries in the superficial dermis.

The 5 arteriolosclerosis-control biopsies showed classical intimal fibrous endarteritis and Monckeberg medial calcinosis associated with calcium deposits that were localized within the media along the internal elastic lamina. Those calcifications were never circumferential and no interstitial localization was observed. Negative margins of resected carcinomas contained

no vascular or interstitial calcium deposits.

Twelve (33%) patients died of CUA. Poorer CUA prognosis was only associated with male sex or nodular lesions (eTable 1 in the supplement).

FE-SEM and EDX Analyses

Subcellular calcification localization and morphology were assessed with FE-SEM. CUA vascular deposits were circumferential (Figures 1F and 2C); at least 1 thrombosis in 5/29 samples was located in the vessel lumen or intima, while the media usually appeared normal with rare calcifications. Interstitial deposits surrounded adipocytes, along the cell membranes. Morphologically, these calcifications appeared to be composed of aggregated micrometric plates (Figure 2F).

FE-SEM analyses of control skin biopsies showing arteriolosclerosis contained vascular calcifications in the media (Figure 1C), associated with medial hypertrophy and intimal fibrosis; no interstitial deposits were seen. FE-SEM analyses of negative resected carcinoma margins confirmed the absence of vascular and interstitial deposits.

EDX analyses of CUA samples verified the calcium and phosphate composition of vascular and interstitial deposits, with similar calcium/phosphate ratios in both sites. EDX analyses showed the composition of vascular deposits in control arteriolosclerosis biopsies to be similar to that found in CUA.

Spectroscopy Analyses

FT-IR analyses of CUA and arteriolosclerosis skin calcifications showed that all were composed of calcium–phosphate apatite (Figure 3). Careful examination of 3 CUA samples identified the presence of amorphous carbonated calcium–phosphate associated with calcium–phosphate apatite that was not seen in any arteriolosclerosis patients' samples.

Raman spectroscopy confirmed the similar calcium–phosphate-apatite compositions of vascular and interstitial calcifications (Figure 4).[16]

Discussion

These FE-SEM, EDX and spectroscopy analyses were able to finally specify the localization and the complete chemical composition of CUA patients' skin calcifications. Our spectroscopic analyses demonstrated that those circumferential calcifications, located in the intima and media of CUA patients' skin vessels, were composed exclusively of calcium–phosphate apatite. In 76% of the CUA patients' samples, calcium–phosphate apatite was also found in interstitial tissue of the deep dermis and hypodermis, along the cytoplasmic membranes of adipocytes, and elastic and collagen fibers.

The chemical composition and localization of cutaneous CUA calcifications have been investigated in only a few small series. Using EDX and FE-SEM, Kramann et al found calcium/phosphate accumulations, with a molar ratio matching that of hydroxyapatite, in the hypodermis of 7 CUA patients.[17] Two other studies used mass spectrometry and Raman spectroscopy to detect and characterize CUA skin calcifications. Using mass spectrometry, Amuluru et al showed that tissue samples from 12 CUA patients had high iron and aluminum contents, suggesting a role of metal deposition in CUA pathogenesis.[18] Using microcomputed-tomography and Raman spectroscopy, Lloyd et al confirmed the presence carbonated apatite in debrided CUA tissues from 6 patients.[19] However, those studies included only small numbers of samples and performed only chemical analyses. To the best of our knowledge, the precise localization and exact morphology of these abnormal deposits have not yet been reported.

Patients with proximal lesions, high body mass index, ulcerated lesions and female were reported to have poorer prognoses.[20] Our univariate and multivariate analyses did not identify

those factors as having a relationship with shorter survival, and retained only male sex and nodular lesions as being significantly associated with mortality. However, the relatively small number of patients included make those findings less relevant than risk factors identified in larger studies.

Skin deposits in CUA and arteriolosclerosis patients were always composed of calcium–phosphate apatite, but their different localizations in the vessel walls could indicate different pathogenetic mechanisms. Indeed, arteriolosclerotic vessel walls are thickened, with media hypertrophy, suggestive of slowly progressive thickening and degeneration of the arteriolar wall with secondary calcium–phosphate apatite accumulation. Circumferential CUA vascular deposits were located mostly in the intima of otherwise normal-looking vessels, suggesting a faster and global process, with primary calcium deposition.

Ellis et al recently showed that pathognomonic cutaneous calcifications associated with CUA could also occur in viable tissue from ESRD patients without CUA, ~~with ESDR~~ amputated because of peripheral arterial disease.[21,22] However, Ellis et al did not consider that some of their controls might have had undiagnosed acral calciphylaxis and undergone amputations for distal ischemia. Those possibilities might explain some of their histopathologic observations of calciphylaxis in their controls. ~~However,~~ Our histologic findings (circumferential calcifications of small-to-medium–sized vessels often associated with interstitial calcifications) and high-technology tools, such as FE-SEM, enabled us to demonstrate several differences between the vascular calcifications seen in CUA and arteriolosclerosis, thereby confirming our previous results and those of Chen et al.[6,23]

Patients with calciphylaxis probably develop skin calcifications subsequent to a dysequilibrium between calcification promoters and inhibitors. Calcium-inhibitor deficiency, like matrix Gla protein, impaired inhibition of calcium–phosphate precipitation, thereby leading to skin calcifications.[20]

Chronic inflammatory states, including ESRD, are associated with increased levels of reactive oxygen species that impair endothelial function.[24] ESRD-related endothelial dysfunction engenders vessel-wall abnormalities, including the presence of bone morphogenetic protein in medial and intimal layers.[25] Such vascular protein modification, associated with increased calcium × phosphate products, might explain the intimal and medial calcifications observed in CUA.

Interstitial calcifications were also seen in 76% of CUA samples. Voluminous calcifications of the subcutaneous tissue or dystrophic and metastatic calcinosis cutis are known to occur in a variety of disorders, including dermatomyositis, lupus or trauma. The ectopic calcified masses, composed of hydroxyapatite and amorphous calcium–phosphate apatite, were disseminated throughout the dermis and hypodermis that appeared petrified, involving interstitial tissue and vessels.[26] The pathophysiology is still unclear but it has been hypothesized that hypodermal inflammation might release the phosphate bound to denatured proteins and serve as a niche for ectopic calcifications.[26] However, despite clinical and pathologic differences, the physiology of these calcifying disorders might be similar, and calcium deposits obstructing some hypodermis vessels in CUA might lead to detrimental adipocyte, collagen and elastic fiber alterations, and the release of the phosphate bound to denatured proteins and ectopic interstitial calcifications. According to that hypothesis, interstitial calcifications might be a secondary phenomenon, thereby explaining the inconstant interstitial localization. The constant presence of vascular deposits could suggest a primary vascular trigger of CUA.

Our finding that CUA vascular calcifications were always circumferential, suggests that therapeutic strategies with vasodilators might be less relevant than those using calcium-solubilizing drugs. Therefore, drugs directly impacting calcium–phosphate precipitation, like sodium thiosulfate, bisphosphonates and vitamin K supplementation would seem to be more

appropriate and a rational approach for future therapeutic studies on CUA.[27,28] Along the same line, Dedinszki et al, who studied other calcifying disorders, including pseudoxanthoma elasticum and generalized arterial calcifications of infancy, reported that oral pyrophosphate inhibited tissue calcifications.[29]

Because our study was retrospective, some information, including vital status was missing for some patients. Our failure to identify factors associated with higher mortality in larger studies might be explained by the relatively small size of our series. It is worth highlighting that calcification morphology can be modified by the sectioning of paraffin-embedded skin biopsies and that the appearance of these deposits may differ between glass and low-e slides, making it more difficult to discern the relationship between optical microscopy and electronic microscopy.

Conclusions

In conclusion, our histologic, FE-SEM, EDX and spectroscopy results provide a better understanding of the morphologic, ultrastructural and chemical characteristics of CUA patients' skin calcium–phosphate-apatite deposits. Those deposits appear to be initially vascular and develop rapidly in normal vessel walls. Circumferential vascular and interstitial deposits, albeit inconstant, were specific to CUA. Although the chemical compositions of the calcifications were similar in CUA and arteriolosclerosis, the vessels' appearances and deposit localizations differed, suggesting different pathogenetic mechanisms.

Acknowledgments

Access to Data and Data Analysis

Hester Colboc had full access to all the data in the study and takes responsibility for the integrity of the data and the accuracy of the data analysis.

The authors declared no conflicts of interest involving this work, no relevant financial activities outside the submitted work (during the 3 years prior to submission) and no other relationships or activities that readers could perceive to have influenced, or that give the appearance of potentially influencing, what is written in the submitted work (based on all relationships that were present during the 3 years prior to submission).

Funding/Support: no funding.

Role of Funder/Sponsor Statement

No funding organization or sponsor we involved in the design and conduct of the study; collection, management, analysis, and interpretation of the data; preparation, review, or approval of the manuscript; and decision to submit the manuscript for publication.

The authors thank LabEx MICHEM (ANR-11-IDEX-0004-02) for allowing us to use their nano/micro-Raman facilities in UPMC. We thank Quentin Rezard from CNRS, LPC, Ba340, Université Paris XI, and Chantal Jouanneau from INSERM, Hôpital Tenon, for their help and support in this study

REFERENCES

1. Weenig RH, Sewell LD, Davis MD, McCarthy JT, Pittelkow MR. Calciphylaxis: natural history, risk factor analysis, and outcome. *J Am Acad Dermatol*. 2007;56(4):569-579.
2. Nigwekar SU, Zhao S, Wenger J, et al. A nationally representative study of calcific uremic arteriolopathy risk factors. *J Am Soc Nephrol*. 2016;27(11):3421-3429.

3. Shmidt E, Murthy NS, Knudsen JM, et al. Net-like pattern of calcification on plain soft-tissue radiographs in patients with calciphylaxis. *J Am Acad Dermatol*. 2012;67(6):1296-1301.

4. Halasz CL, Munger DP, Frimmer H, Dicorato M, Wainwright S. Calciphylaxis: comparison of radiologic imaging and histopathology. *J Am Acad Dermatol*. 2017;77(2):241-246.

5. Nigwekar SU, Kroshinksy D, Nazarian RM, et al. Calciphylaxis: risk factors, diagnosis, and treatment. *Am J Kidney Dis*. 2015;66(1):133-146.

6. Cassius C, Moguelet P, Monfort JB, et al. Calciphylaxis in haemodialysed patients: diagnostic value of calcifications in cutaneous biopsy. *Br J Dermatol*. 2018;178(1):292-293.

7. Jean G, Terrat JC, Vanel T, et al. Calciphylaxis in dialysis patients: to recognize and treat it as soon as possible. *Nephrol Ther*. 2010;6(6):499-504.

8. Bazin D, Daudon M, Combes C, Rey C. Characterization and some physicochemical aspects of pathological microcalcifications. *Chem Rev*. 2012;112(10):5092-5120.

9. Colboc H, Moguelet P, Bazin D, et al. Physicochemical characterization of inorganic deposits associated with granulomas in cutaneous sarcoidosis. *J Eur Acad Dermatol Venereol*. 2019;33(1):198-203.

10. Bazin D, Daudon M. Pathological calcifications and selected examples at the medicine–solid-state physics interface. *J Phys Appl Phys*. 2012;45(38):383001.

11. Hayashi M. Calciphylaxis: diagnosis and clinical features. *Clin Exp Nephrol*. 2013;17(4):498-503.

12. Brandenburg VM, Cozzolino M, Ketteler M. Calciphylaxis: a still unmet challenge. *J Nephrol*. 2011;24(2):142-148.

13. Dessombz A, Bazin D, Dumas P, Sandt C, Sule-Suso J, Daudon M. Shedding light on the

chemical diversity of ectopic calcifications in kidney tissues: diagnostic and research aspects. *PloS One.* 2011;6(11):e28007.

14. Brisset F. *Microscopie Électronique à Balayage et Microanalyses*. Paris, France: EDP Sciences; 2012.
15. Carden A, Morris MD. Application of vibrational spectroscopy to the study of mineralized tissues (review). *J Biomed Opt.* 2000;5(3):259-269.
16. Awonusi A, Morris MD, Tecklenburg MM. Carbonate assignment and calibration in the Raman spectrum of apatite. *Calcif Tissue Int.* 2007;81(1):46-52.
17. Kramann R, Brandenburg VM, Schurgers LJ, et al. Novel insights into osteogenesis and matrix remodelling associated with calcific uraemic arteriolopathy. *Nephrol Dial Transplant.* 2013;28(4):856-868.
18. Amuluru L, High W, Hiatt KM, et al. Metal deposition in calcific uremic arteriolopathy. *J Am Acad Dermatol.* 2009;61(1):73-79.
19. Lloyd WR, Agarwal S, Nigwekar SU, et al. Raman spectroscopy for label-free identification of calciphylaxis. *J Biomed Opt.* 2015;20(8):80501.
20. Nigwekar SU, Thadhani R, Brandenburg VM. Calciphylaxis. *N Engl J Med.* 2018;378(18):1704-1714.
21. Ellis CL, O'Neill WC. Questionable specificity of histologic findings in calcific uremic arteriolopathy. *Kidney Int.* 2018;94(2):390-395
22. Nigwekar SU, Nazarian RM. Cutaneous calcification in patients with kidney disease is not always calciphylaxis. *Kidney Int.* 2018;94(2):244-246.
23. Chen TY, Lehman JS, Gibson LE, Lohse CM, El-Azhary RA. Histopathology of calciphylaxis; cohort study with clinical correlations. *Am J Dermatopathol*. 2017;39(11):795-802.
24. Sowers KM, Hayden MR. Calcific uremic arteriolopathy: pathophysiology, reactive

oxygen species and therapeutic approaches. *Oxid Med Cell Longev*. 2010;3(2):109-121.

25. Nigwekar SU, Jiramongkolchai P, Wunderer F, et al. Increased bone morphogenetic protein signaling in the cutaneous vasculature of patients with calciphylaxis. *Am J Nephrol*. 2017;46(5):429-438.
26. Reiter N, El-Shabrawi L, Leinweber B, Berghold A, Aberer E. Calcinosis cutis: part I. Diagnostic pathway. *J Am Acad Dermatol*. 2011;65(1):1–12.
27. Zitt E, König M, Vychytil A, et al. Use of sodium thiosulphate in a multi-interventional setting for the treatment of calciphylaxis in dialysis patients. *Nephrol Dial Transplant*. 2013;28(5):1232-1240.
28. Nigwekar SU, Bloch DB, Nazarian RM, et al. Vitamin K-dependent carboxylation of matrix Gla protein influences the risk of calciphylaxis. *J Am Soc Nephrol*. 2017;28(6):1717-1722.
29. Dedinszki D, Szeri F, Kozák E, et al. Oral administration of pyrophosphate inhibits connective tissue calcification. *EMBO Mol Med*. 2017;9(11):1463-1470.

Figure legends

Fig 1. Skin biopsy sections. Arteriolosclerosis with asymmetrical fibrous intimal thickening ("fibrous endarteritis") and Monckeberg medial calcinosis, ie, calcification of the internal elastic lamina and media: A, hematoxylin–eosin–saffron (HES)-stained (×400); B, von Kossa-stained (×400); C, FE-SEM. Calcific uremic arteriolopathy (CUA) hypodermic arterioles with voluminous and circumferential parietal calcium deposits: D, HES-stained (×400), E, von Kossa-stained (×400); F, FE-SEM.

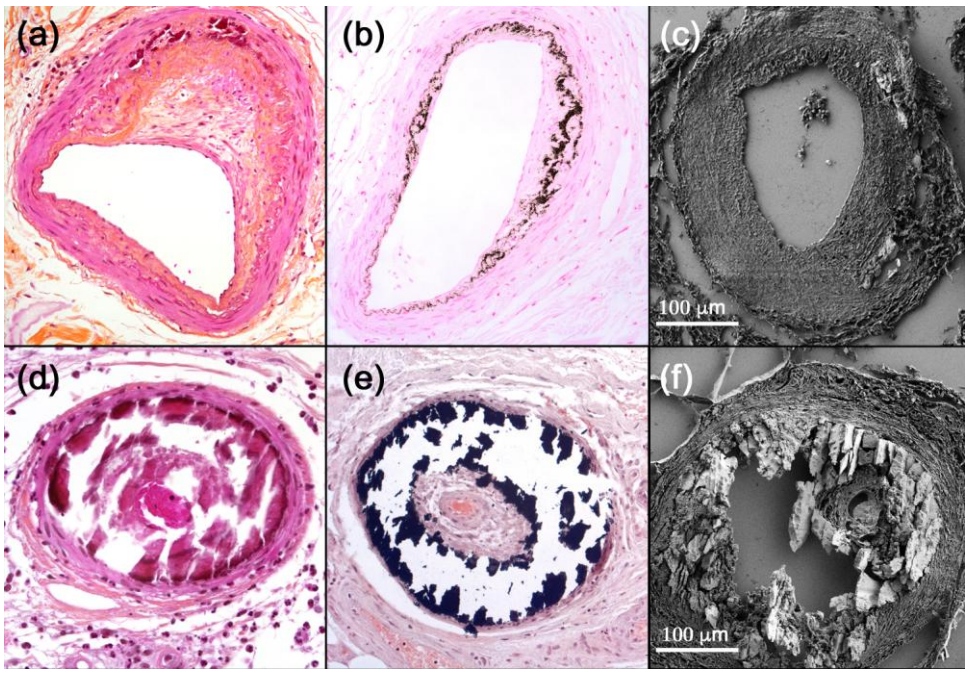

Fig 2. Skin biopsy sections. CUA hypodermic capillaries with voluminous and circumferential parietal calcium deposits: A, HES-stained (×400), B, von Kossa-stained (×400), C, FE-SEM. Interstitial CUA deposits, aligned along the cytoplasmic membranes of adipocytes: D, HES-stained (×400); E, von Kossa-stained (×400); F, FE-SEM.

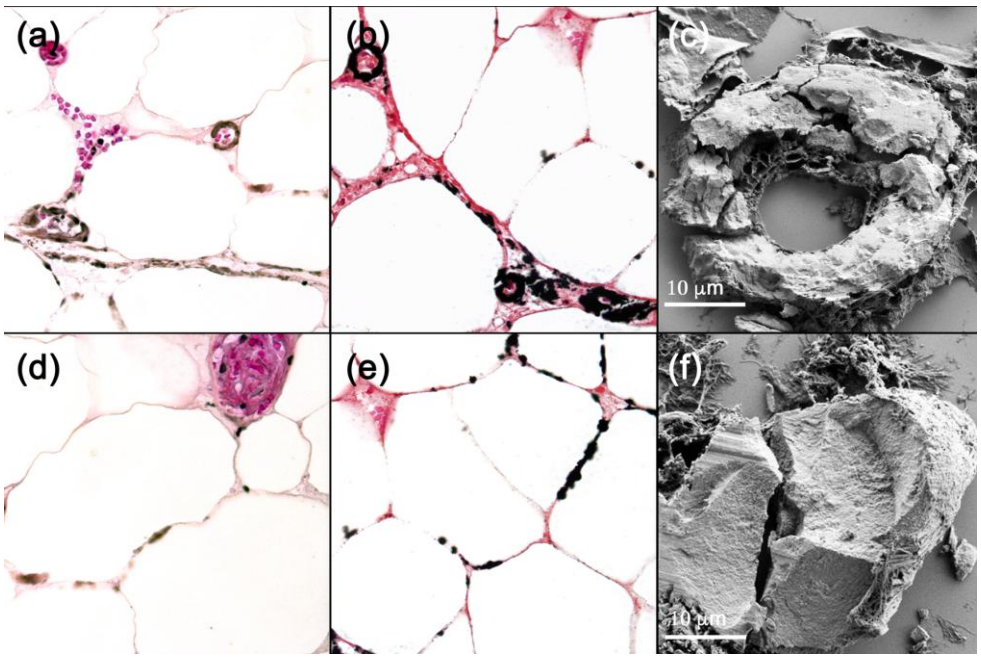

Fig 3. µFourier transform infra-red (FT-IR) spectroscopy of the interstitial CUA deposits: A, Skin biopsy of CUA; B, IR map of the red square area, showing an intense vascular deposit; C, IR spectrum of this vascular deposit: calcium–phosphate apatite spectrum with characteristic peaks (1015, 959 and 875 cm^{-1}) in a protein matrix (skin tissue). The same spectrum was obtained for CUA and arteriolosclerosis vascular calcifications.

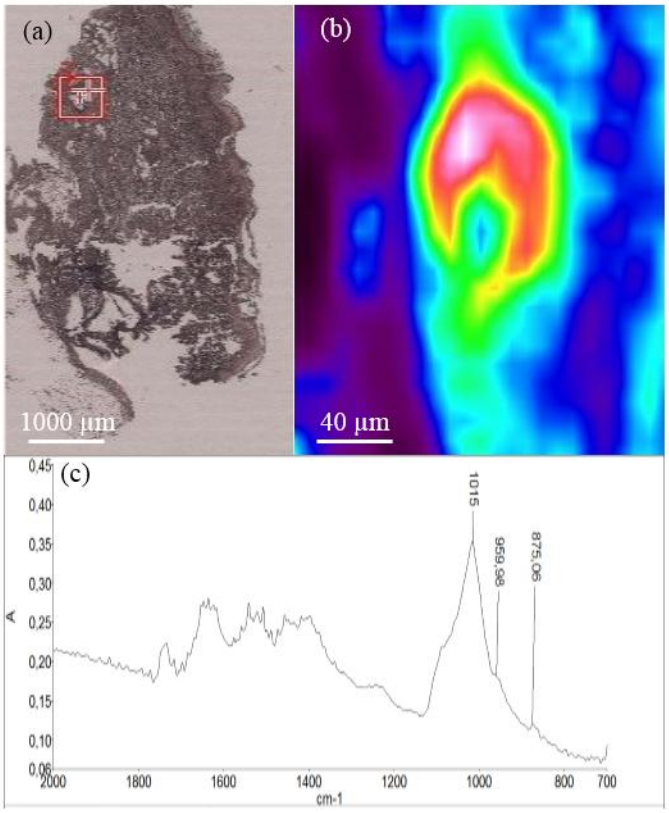

Fig 4. Micro-Raman signatures and optical micrographs (magnification 10× and 100×) of A, peri-adipocyte and B, vascular calcifications (excitation wavelength λ_{exc} = 785 nm, objective 100×, numerical aperture = 0.9). The Raman bands at 960, 1076 and 590 cm^{-1} correspond, respectively, to the ν_1, ν_3 and ν_4 phosphate vibrations of apatite. The low-intensity ν_4 carbonate vibrations around 680–715 cm^{-1}, expected for carbapatite, are not observed. The strong fluorescence background has been corrected on the presented spectra.

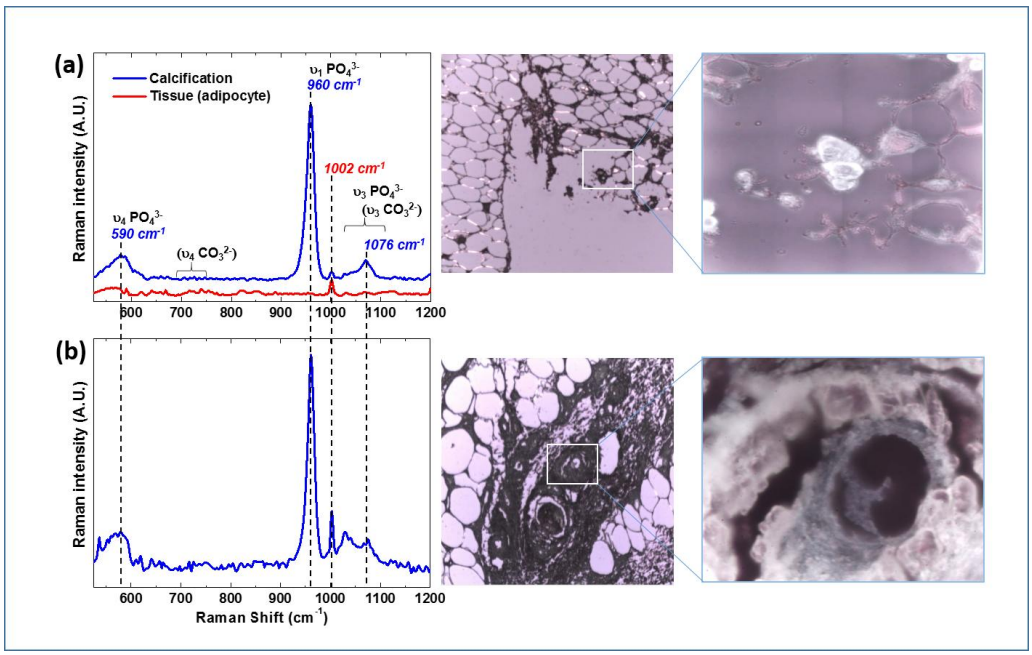

468

469

470 **Table 1** Baseline clinical, biologic and histologic characteristics of the 36 CUA patients

Characteristic	Value
Demographic	
Female/male ratio	2.6
Age at diagnosis, years	64 [33–89]
Comorbidity	
Dialysis	30 (83%)
Dialysis-to-CUA interval (months)	24 [1–156]
Diabetes	23 (64%)
Hypertension	33 (92%)
Body mass index >30 kg/m^2	14 (39%)
Vitamin K antagonists	16 (44%)
Clinical	
Proximal CUA	10 (28%)

Necrosis	26 (72%)
Ulceration	24 (67%)
Livedo reticularis	18 (50%)
Indurated plaques	15 (42%)
Nodular lesions	9 (25%)
Biologic	
Serum calcium, mmol/L	2.26 [1.89–2.84]
Serum phosphate, mmol/L	1.57 [0.93–3.68]
Calcium × phosphate product >4.5 $mmol^2/L^2$	12 (33%)
Serum parathormone >90 ng/L	24 (67%)
Serum albumin (median), g/L	28 [18–37]
Cutaneous histology	29
Vascular calcifications	29 (100%)
Interstitial calcifications	22 (76%)
Thrombosis	5 (14%)

Values are expressed as *n* (%) or median [range], unless stated otherwise. CUA, calcific uremic arteriolopathy