



HAL
open science

Are oxyphil cells responsible for the ineffectiveness of cinacalcet hydrochloride in haemodialysis patients?

Jacques Rottembourg, Fabrice Menegaux

► **To cite this version:**

Jacques Rottembourg, Fabrice Menegaux. Are oxyphil cells responsible for the ineffectiveness of cinacalcet hydrochloride in haemodialysis patients?. *Clinical Kidney Journal*, 2019, 12 (3), pp.433-436. <10.1093/ckj/sfy062>. <hal-02361944>

HAL Id: hal-02361944

<https://hal.sorbonne-universite.fr/hal-02361944v1>

Submitted on 13 Nov 2019

HAL is a multi-disciplinary open access archive for the deposit and dissemination of scientific research documents, whether they are published or not. The documents may come from teaching and research institutions in France or abroad, or from public or private research centers.

L'archive ouverte pluridisciplinaire **HAL**, est destinée au dépôt et à la diffusion de documents scientifiques de niveau recherche, publiés ou non, émanant des établissements d'enseignement et de recherche français ou étrangers, des laboratoires publics ou privés.



HAL Authorization



EXCEPTIONAL CASE

Are oxyphil cells responsible for the ineffectiveness of cinacalcet hydrochloride in haemodialysis patients?

Jacques Rottembourg¹ and Fabrice Menegaux²¹Department of Nephrology, Groupe Hospitalier Pitié-Salpêtrière, Paris, France and ²Department of Endocrine Surgery, Groupe Hospitalier Pitié-Salpêtrière, Paris, France

Correspondence and offprint requests to: Jacques Rottembourg; E-mail: jacques.rottembourg@wanadoo.fr

ABSTRACT

Parathyroid glands consist primarily of chief cells. In some cases, the proportion of parathyroid oxyphil cells increases in patients with chronic kidney disease. We describe a case of secondary hyperparathyroidism (SHPT) in a patient treated with haemodialysis who initially received large doses of vitamin D and calcium (Ca) supplements, as well as high doses of cinacalcet hydrochloride (C-HCl), but without any effect on parathyroid hormone levels. Following a successful parathyroidectomy, histopathological examination revealed that two of the parathyroid glands consisted of 40% of oxyphil cells. Oxyphil cells have significantly more Ca-sensing receptors (CaSRs) than chief cells, suggesting that CaSRs are involved in the transdifferentiation of chief cells to oxyphil cells. C-HCl treatment leads to a significant increase in parathyroid oxyphil cell content. This case suggests that C-HCl may induce specific phenotypic alterations in hyperplastic parathyroid glands in patients with severe SHPT.

Keywords: calcimimetic, calcium-sensing receptor, chronic kidney disease, haemodialysis, secondary hyperparathyroidism**INTRODUCTION**

Secondary hyperparathyroidism (SHPT) is one of the most important complications in chronic kidney disease-mineral and bone disorder (CKD-MBD). Patients are considered to have severe SHPT when serum phosphate (P), serum calcium (Ca) and intact parathyroid hormone (PTH) levels can no longer be adequately controlled by medical management and when clinical symptoms are associated with a significantly increased risk of cardiovascular morbidity and mortality [1–3]. Cinacalcet hydrochloride (C-HCl) is a calcimimetic agent for SHPT treatment that increases the sensitivity of Ca-sensing receptors (CaSRs) to activation by extracellular Ca and thus suppresses PTH release while simultaneously controlling other mineral biochemical parameters [4, 5]. C-HCl has the potential to control biochemical parameters, even in cases of severe SHPT refractory to conventional treatments with Ca supplements, P binders and active

vitamin D analogues. However, in some patients, C-HCl seems to be either only partially effective or ineffective [6, 7], and this case report discusses key points that could explain this, including the presence of severe SHPT and non-compliance to treatment.

CASE REPORT

A 12-year-old Moroccan female who presented a nephrotic syndrome was treated with corticosteroids, without any effect. A renal biopsy performed 8 years later showed typical focal glomerulosclerosis. Renal insufficiency developed rapidly, with the concomitant development of cardiac failure. Dialysis was required at the age of 22 years. Two years later the patient moved to France and was dialysed in our unit. Dialysis was carried out via an arteriovenous fistula and comprised 4-h sessions three

Received: 24.2.2018. Editorial decision: 15.5.2018

© The Author(s) 2018. Published by Oxford University Press on behalf of ERA-EDTA.

This is an Open Access article distributed under the terms of the Creative Commons Attribution Non-Commercial License (<http://creativecommons.org/licenses/by-nc/4.0/>), which permits non-commercial re-use, distribution, and reproduction in any medium, provided the original work is properly cited. For commercial re-use, please contact journals.permissions@oup.com

Table 1. Main biological parameters and medications prescribed to the patient after her arrival in the dialysis unit

Parameters	15 June 2005	7 December 2005	07 March 2006	10 June 2006	15 September 2006	6 December 2006	24 May 2007	Post-surgery	6 December 2007	March 2018
Body weight (kg)	48.5	43	42	43	42.5	42	42	42	44	56
Calcium level (mmol/L)	2.19	2.21	2.10	2.25	2.32	2.28	2.32	1.30	2.00	2.36
Phosphate level (mmol/L)	1.56	2.15	2.19	1.80	1.78	1.64	1.62	1.52	1.26	1.06
Alkaline phosphatase (IU/L)	62	89	79	110	120	130	165	110	57	46
PTH (pg/mL)	776	808	1065	1347	1207	1475	1869	8	15	36
Kt/V	1.78	1.88	1.69	1.73	1.79	1.67	1.72	–	1.76	–
Alfacalcidol (µg/day)	1	1	1	1	1	1	1	6	4	2
Calcium carbonate (g/day)	1.5	1.5	1.5	1.5	1.5	1.5	1.5	12 (IV)	4.5	2
Sevelamer (mg/day)	–	3200	4800	7200	7200	7200	7200	–	2400	–
Cinacalcet hydrochloride (mg/day)	–	–	30	60	90	120	150	–	–	–

IV, intravenous.

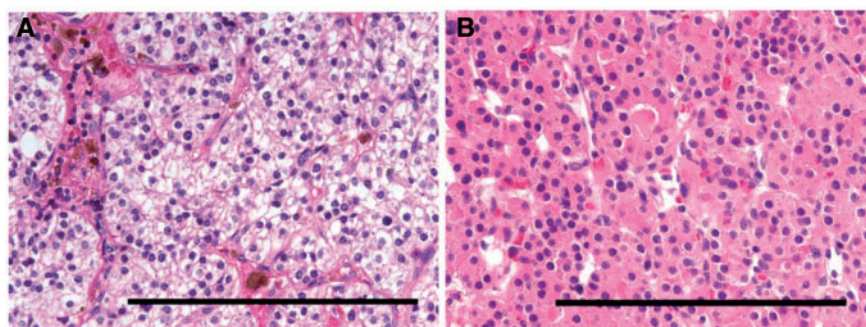


FIGURE 1: (A) The chief cells have an amphophilic, vacuolated cytoplasm. (B) The oxyphil cells are composed of large cells with a brightly stained eosinophilic granular cytoplasm. The bar at the bottom represents 1 mm (magnitude $\times 100$).

times a week, with a dialysate Ca level consistently maintained at 1.5 mmol/L. When the patient first presented in our unit, our main concern was severe cardiac failure due to uraemic cardiomyopathy, with a left ventricular ejection fraction (LVEF) of 28%. After a few months, following treatment adjustment using diuretics, β -blockers and angiotensin-converting enzyme (ACE) inhibitors, as well as a decrease in body weight, the LVEF improved to 54%. The next important problem was SHPT. The main biological parameters and medications prescribed to the patient are shown in Table 1. Despite an increase in the dosage of C-HCl, the level of PTH did not decrease but paradoxically increased. To ensure that the prescribed doses were effectively taken by the patient, the medication was given at the dialysis unit on the days of dialysis at the end of the dialysis session. However, the level of PTH consistently increased.

In May 2007, an ultrasound scan of the parathyroid glands revealed normal upper right and upper left parathyroids of ~3 mm in diameter and two enlarged parathyroids, with the right lower gland measuring $8 \times 6 \times 5.2$ mm and the left lower gland measuring $7 \times 6 \times 4.5$ mm. Consequently, a parathyroidectomy was performed in July 2007, at a preoperative PTH level of 2162 pg/mL. The two upper parathyroid glands were slightly hyperplastic but were left intact and controlled with a clip to ensure that they could be easily identified, if necessary. The two lower glands, each ~10 mm in diameter, were resected, with each gland weighing 5.3 and 5.2 g, respectively. The histopathological examination revealed the presence of a benign parathyroid adenoma consisting of chief cells in each resected gland; however, 30–40% of each gland contained oxyphil cells, which

was classified as an oxyphil adenoma (Figure 1), and a parathyroid carcinoma was excluded.

Two hours post-surgery, the serum Ca level dropped to 1.30 mmol/L and the PTH level to 8 pg/mL. The patient was prescribed 12 g/day of intravenous Ca and 6 µg/day of alfacalcidol. Four months later, with a treatment regimen of 4 g/day of Ca and 4 µg/day of alfacalcidol, the Ca level was 2.00 mmol/L, P level 1.20 mmol/L and PTH level 22 pg/mL. In the following year, the patient received a kidney transplant, was pregnant 3 years later and remained well 9 years later, with a creatinine level of 118 µmol/L, Ca level of 2.36 mmol/L and PTH level of 36 pg/mL on a treatment regimen of 2 g/day of Ca and 2 µg/day of alfacalcidol.

DISCUSSION

This case report raises many important points of discussion: the presence of SHPT, the patient's compliance with numerous medications, the presence of an oxyphil cell parathyroid adenoma and the role of C-HCl in the histologic type of parathyroid adenoma.

SHPT is a common, serious and progressive complication of CKD-MBD. It is mainly characterized by high serum PTH levels, parathyroid gland hyperplasia and disturbance in mineral metabolism characterized mainly by hypocalcaemia and hyperphosphataemia. Initial treatment of SHPT in haemodialysis (HD) patients usually includes Ca salts, intestinal P binders and vitamin D derivatives. The oral calcimimetic C-HCl is often used later in the course of the disease in patients who fail to respond

adequately to the initial treatments. C-HCl has been shown to be effective in reducing circulating PTH levels in HD patients with SHPT in several clinical trials [8–14]. Overall, treatment with C-HCl was associated with significant reductions in the total volume of parathyroid glands, with a corresponding decrease in PTH levels [6]. In another study, Meola *et al.* [15] found that C-HCl, in combination with conventional treatments, led to an improvement in biochemical and clinical parameters of SHPT and reduced glandular volume in patients with severe SHPT.

The median number of medications prescribed to HD patients is significant at ~19 pills/day [16]. Prescription of P binders makes up around half of the medications prescribed per day. However, the frequency distribution of adherence to P binders is ~40% [16]. Some patients appear to be insensitive to or exhibit hyporesponsiveness to C-HCl treatment. One explanation could be simply a lack of compliance with treatment and/or inadequate treatment education provided to these patients. In a recent European retrospective observational study [17], it was observed that 23% of the incident patients had their C-HCl treatment discontinued after 1 year. One of the causes of hyporesponsiveness could be the number, size and nodular hyperplastic characteristic of the parathyroid glands, which are known to predict the response to C-HCl. Another possibility of failed treatment with C-HCl could be the development of an oxyphil cell parathyroid adenoma.

Oxyphil cell parathyroid adenomas are rare. In 1967 it was postulated by Christie [18] that the development of oxyphil cells may be a defence mechanism in which oxyphil cells may produce a hormone necessary for maintaining 'a normal biochemical milieu in adverse circumstances in particular in CKD where gross electrolyte imbalance is likely to occur'. Oxyphil cell content is markedly increased in CKD; in general, the proportion of oxyphil cells increases in parallel with the total weight of the parathyroid glands in uraemic patients, suggesting that this cell type is sensitive to stimulation [19]. Recent studies have found an association between treatment of SHPT with calcitriol and/or C-HCl and an even higher oxyphil cell content of the parathyroid glands than in the absence of such treatment [20]. A recent study by Ritter *et al.* [21] shed new light on the role and function of oxyphil cells. The study analysed patients who underwent parathyroidectomy for SHPT after treatment with paricalcitol and/or C-HCl. The main findings were:

- The parathyroid tissue in uraemic patients had, on average, five times higher oxyphil cell content than normal parathyroid tissue.
- Conventional pharmacological treatment of SHPT could have affected the cell population of the parathyroid glands in uraemic patients.
- Among treated patients, the parathyroid tissue in the C-HCl group showed a significantly higher content of oxyphil cells ($26.7 \pm 14.2\%$) compared with the paricalcitol group ($6.9 \pm 5.1\%$); however, the cubic volume of the parathyroid glands in both groups was similar. In our case, the oxyphil cell content was ~40%.

These data indicate that the two conventional treatments for SHPT, i.e. C-HCl and paricalcitol, may have disparate effects on parathyroid tissue composition. However, one of the main questions is the function of parathyroid oxyphil cells in SHPT and the role of C-HCl in the development of these cells. It seems that the oxyphil cells express more CaSRs compared with chief cells, and Ritter *et al.* [19] postulated that CaSRs and calcimimetics may play a role in the transdifferentiation of chief cells to

oxyphil cells. In another paper, Ritter *et al.* [22] showed that oxyphil cells overexpress parathyroid tissue genes encoding, for example, PTH, calcium-sensing receptor, glial cells missing homolog 2 and parathyroid hormone-related protein.

Moreover, it was reported by the same group that human parathyroid oxyphil cells consistently expressed high levels of 1α -OHase protein compared with parathyroid chief cells [22]. C-HCl directly increased parathyroid 1α -OHase expression in cultured parathyroid cells. The importance of Ca in the regulation of 1α -OHase is also clinically important because calcimimetics are commonly used to treat patients with SHPT. The oxyphil:chief cell ratio was increased by C-HCl treatment [20]. The conversion of chief cells to oxyphil cells may be a compensatory mechanism by which increased local production of calcitriol could act to decrease PTH levels. Because C-HCl directly activates the response of CaSRs to extracellular Ca and calcitriol can activate CaSRs indirectly via its calcaemic effect, these actions may play a role in the transdifferentiation of chief cells to oxyphil cells. The complex balance between chief and oxyphil cells could, at least partly, be determined by an autocrine/paracrine regulation of the activity of chief cells by oxyphil cells [24]. C-HCl could also induce apoptosis and necrosis of parathyroid glands, as demonstrated by Sumida *et al.* [23], with a significant increase in oxyphil cell area and haemosiderosis score. These results suggest that C-HCl could induce specific qualitative alterations in hyperplastic parathyroid glands in patients with severe SHPT. Lomonte *et al.* [20] suggested that the change in the oxyphil:chief cell ratio was probably due to a significant decrease in the proportion of chief cells accelerated by C-HCl through an apoptotic mechanism in uraemic rats [24, 25]. It is possible that C-HCl has a qualitative influence on parathyroid cells and induces pathological changes.

Clearly further studies are required to determine the role of C-HCl in the chief-to-oxyphil cell transdifferentiation and the consequent influence on parathyroid gland function following treatment of SHPT in CKD patients as well as the possible role of oxyphil cells in attenuating or inactivating the role of C-HCl in the control of SHPT.

CONFLICT OF INTEREST STATEMENT

None declared.

REFERENCES

1. Chertow GM, Plone M, Dillon MA *et al.* Hyperparathyroidism and dialysis vintage. *Clin Nephrol* 2000; 54: 295–300
2. National Kidney Foundation. K/DOQI clinical practice guidelines for bone metabolism and disease in chronic kidney disease. *Am J Kidney Dis* 2003; 42(4 Suppl 3): S1–S201
3. Ketteler M, Block GA, Evenepoel P *et al.* Executive summary of the 2017 KDIGO chronic kidney disease-mineral and bone disorder (CKD-MBD) guideline update: what's changed and why it matters. *Kidney Int* 2017; 92: 26–36
4. Urena P, Frazao JM. Calcimimetic agents: review and perspectives. *Kidney Int* 2003; 63(Suppl 85): S91–S96
5. Urena P, Fouque D, Brunet P *et al.* Cinacalcet treatment for secondary hyperparathyroidism in dialysis patients in real-world clinical practice – the ECHO observational study: French experience. *Nephrol Ther* 2012; 8: 527–533
6. Komaba H, Nakanishi S, Fujimori A *et al.* Cinacalcet effectively reduces parathyroid hormone secretion and gland volume regardless of pretreatment gland size in patients with secondary hyperparathyroidism. *Clin J Am Soc Nephrol* 2010; 5: 2305–2314

7. Forni Ognà V, Pruijm M, Zwiackier C et al. Clinical benefits of an adherence monitoring program in the management of secondary hyperparathyroidism with cinacalcet: results of a prospective randomized controlled study. *Bio Med Res Int* 2013; 2013: 104892
8. Chertow GM, Block GA, Correa-Rotter R et al. Effect of cinacalcet on cardiovascular disease in patients undergoing dialysis. *N Engl J Med* 2012; 367: 2482–2494
9. Wetmore JB, Gurevich K, Sprague S et al. A randomized trial of cinacalcet versus vitamin D analogs as monotherapy in secondary hyperparathyroidism (PARADIGM). *Clin J Am Soc Nephrol* 2015; 10: 1031–1040
10. Fishbane S, Shapiro WB, Corry DB et al. Cinacalcet-HCl and concurrent low-dose vitamin D improves treatment of secondary hyperparathyroidism in dialysis patients compared with vitamin D alone: the ACHIEVE study results. *Clin J Am Soc Nephrol* 2008; 3: 1718–1725
11. Ketteler M, Martin KJ, Wolf M et al. Paracalcitol versus cinacalcet plus low-dose vitamin D therapy for the treatment of secondary hyperparathyroidism in patients receiving haemodialysis: results of the IMPACT SHPT study. *Nephrol Dial Transplant* 2012; 27: 3270–3278
12. Messa P, Macario F, Yaqoob M et al. The OPTIMA study: assessing a new cinacalcet (Sensipar/Mimpara) treatment algorithm for secondary hyperparathyroidism. *Clin J Am Soc Nephrol* 2008; 3: 36–45
13. Raggi P, Chertow GM, Torres PU et al. The ADVANCE study: a randomized study to evaluate the effects of cinacalcet plus low-dose vitamin D on vascular calcification in patients on hemodialysis. *Nephrol Dial Transplant* 2011; 26: 1327–1339
14. Urena-Torres P, Bridges I, Christiano C et al. Efficacy of cinacalcet with low-dose vitamin D in incident haemodialysis subjects with secondary hyperparathyroidism. *Nephrol Dial Transplant* 2013; 28: 1241–1254
15. Meola M, Petrucci I, Barsotti G. Long-term treatment with Cinacalcet and conventional therapy reduces parathyroid hyperplasia in severe secondary hyperparathyroidism. *Nephrol Dial Transplant* 2009; 24: 982–989
16. Chiu YW, Teitelbaum I, Misra M et al. Pill burden, adherence, hyperphosphatemia and quality of life in maintenance dialysis patients. *Clin J Am Soc Nephrol* 2009; 4: 1089–1096
17. de Francisco ALM, Gillespie IA, Gioni I et al. Anti-parathyroid treatment effectiveness and persistence in incident haemodialysis patients with secondary hyperparathyroidism. *Nefrologia* 2016; 36: 164–175
18. Christie AC. The parathyroid oxyphil cells. *J Clin Pathol* 1967; 20: 591–602
19. Ritter CS, Haughey BH, Miller B et al. Differential gene expression by oxyphil cells of human parathyroid glands. *J Clin Endocrinol Metab* 2012; 97: E1499–E1505
20. Lomonte C, Vernagione L, Chimienti D et al. Does vitamin D receptor and calcium receptor activation therapy play a role in the histopathologic alterations of the parathyroid glands in refractory uremic hyperparathyroidism. *Clin J Am Soc Nephrol* 2008; 3: 794–799
21. Ritter C, Miller B, Coyne DW et al. Paracalcitol and cinacalcet have disparate actions on parathyroid oxyphil cell content in patients with chronic kidney disease. *Kidney Int* 2017; 92: 1217–1222
22. Ritter CS, Haughey BH, Ambrecht HJ et al. Distribution and regulation of the 25-hydroxyvitamin D₃ 1 α -hydroxylase in human parathyroid glands. *J Steroid Biochem Mol Biol* 2012; 130: 73–80
23. Sumida K, Nakamura M, Ubara Y et al. Histopathological alterations of the parathyroid glands in haemodialysis patients with secondary hyperparathyroidism refractory to cinacalcet hydrochloride. *J Clin Pathol* 2011; 64: 756–760
24. Mizobuchi M, Ogata H, Hatamura I et al. Activation of calcium-sensing receptor accelerates apoptosis in hyperparathyroid cells. *Biochem Biophys Res Commun* 2007; 362: 11–16
25. Wada M, Nagano N. Control of parathyroid cell growth by calcimimetics. *Nephrol Dial Transplant* 2003; 18(Suppl 3): S13–S17