



HAL
open science

Screening for Cancer in Patients with Glomerular Diseases

Emmanuelle Plaisier, Pierre Ronco

► **To cite this version:**

Emmanuelle Plaisier, Pierre Ronco. Screening for Cancer in Patients with Glomerular Diseases. Clinical Journal of the American Society of Nephrology, 2020, pp.CJN.09000819. 10.2215/CJN.09000819 . hal-02491692

HAL Id: hal-02491692

<https://hal.sorbonne-universite.fr/hal-02491692>

Submitted on 26 Feb 2020

HAL is a multi-disciplinary open access archive for the deposit and dissemination of scientific research documents, whether they are published or not. The documents may come from teaching and research institutions in France or abroad, or from public or private research centers.

L'archive ouverte pluridisciplinaire **HAL**, est destinée au dépôt et à la diffusion de documents scientifiques de niveau recherche, publiés ou non, émanant des établissements d'enseignement et de recherche français ou étrangers, des laboratoires publics ou privés.

Screening for Cancer in Patients with Glomerular Diseases

Emmanuelle Plaisier^{1,2,3,4,5} and Pierre Ronco^{1,2,3,4,5}

CJASN 15: ●●●–●●●, 2020. doi: <https://doi.org/10.2215/CJN.09000819>

The diagnosis of malignancy in the setting of nephrotic syndrome is associated with a poor overall and kidney survival regardless of whether the glomerular disease represents a paraneoplastic manifestation or the cancer is a coincidental finding. The diagnosis of the neoplasia leads to consideration of antitumor therapy first, and may exclude the use of immunosuppressive agents. Although no cancer screening program has been established by nephrology societies because of the lack of evidence-based data, nephrologists usually question the cost-effectiveness of work-up for malignancy in newly diagnosed glomerulopathy. Furthermore, repeated screening during follow-up may be justified by treatment failure or early relapse despite suitable therapy, and by an excess risk of malignant diseases at months or years after the diagnosis of glomerulopathy, notably in membranous nephropathy (1).

Evaluation of the risk of cancer-associated glomerulopathies is primary on the basis of patient-related risk factors and the histopathological diagnosis. Screening for cancer should include a routine evaluation, completed by targeted tests driven by each patient's risk factors. In the case of membranous nephropathy where concerns of causative or associated malignancy are usually raised, it is important to consider whether the discovery of the new antigens M-type phospholipase A2 receptor (PLA2R) and thrombospondin type-1 domain-containing protein 7A (THSD7A) affect the decision to undergo, and the extent of, cancer screening.

Patient-Related Risk Factors for Cancer-Associated Glomerulopathy

Population-based studies and more focused case series have established age as a major risk factor for cancer-associated glomerulopathy, the highest prevalence being observed in patients aged >60 years in membranous nephropathy, IgA nephropathy, and IgA vasculitis (2). Heavy smoking (>20 pack-years) represented a strong predictor of cancer in a series of 240 membranous nephropathy that included 10% of malignancy-associated forms (3). Excess risks driven by familial predisposition or individual risks for neoplasia have not been evaluated in cancer-associated glomerulopathies, but they must be systematically recorded to target screening, notably in individuals aged <60 years.

Routine physical examination is informative if detecting lymphadenopathy; organomegaly; abdominal,

genital, or breast mass; skin lesion; or urological abnormality. Systemic symptoms (weight loss, fever, night sweats) are recorded in >70% of individuals with minimal change disease related to Hodgkin lymphoma. Necrotizing skin lesions are suggestive of paraneoplastic IgA vasculitis in patients aged >60 years. Standard laboratory testing may indicate secondary forms of glomerulopathy, including malignancy-related glomerulopathy, by detecting anemia, abnormal white blood count, elevated inflammatory markers, iron deficiency, abnormal liver tests, and chronic hepatitis B or C infection. Except for the fecal occult blood test, diagnostic accuracy of tumor biomarkers is low in asymptomatic patients; their relevance increases when combined with suggestive clinical symptoms and abnormal biologic or imaging findings.

Because thromboembolic disease occurs in 25% of patients with cancer-associated membranous nephropathy compared with 7% in primary forms, such complication raises suspicion of neoplasia in nephrotic syndrome, although global prevalence of cancer in patients with nephrotic syndrome who experience a thrombotic event is yet unknown.

Exposure to cyclophosphamide and azathioprine rarely accounts for late-onset bladder carcinoma, leukemia, and nonmelanoma skin cancer. Urine malignant cells must be searched in patients previously receiving cyclophosphamide (cumulative doses >36 g).

Besides cancer screening at diagnosis, subsequent evaluation for cancer is indicated if treatment failure or relapse despite suitable therapy.

Effect of Histopathological Diagnosis of Glomerular Disease on Decision to Screen for Malignancy

Kidney biopsy directs the screening toward the frequently observed solid tumors and hematologic malignancies according to the histopathological glomerular lesions (Figure 1). The prototype of glomerular disease associated with cancer is membranous nephropathy, although such association also occurs in minimal change disease, IgA nephropathy, IgA vasculitis, ANCA-positive and ANCA-negative crescentic GN, and membranoproliferative GN (Figure 1). The prevalence of neoplasia in membranous nephropathy cohorts is about 10%, with malignancy being

¹Department of Nephrology Day Hospital, Tenon Hospital Assistance Publique des Hôpitaux de Paris, Paris, France; ²Research Unit UMRS 1155, National Institute of Health and Medical Research-INSERM, Paris, France; ³Sorbonne Université, Paris 06, Paris, France; ⁴Reference Center of Rare disease-idiopathic Nephrotic Syndrome, Paris, France; and ⁵European Rare Kidney Disease Reference Network-ERKNet, Heidelberg, Germany

Correspondence: Prof. Pierre Ronco, Department of Nephrology, Tenon Hospital, 4 rue de la Chine, 75020 Paris, France. Email: pierre.ronco@yahoo.fr

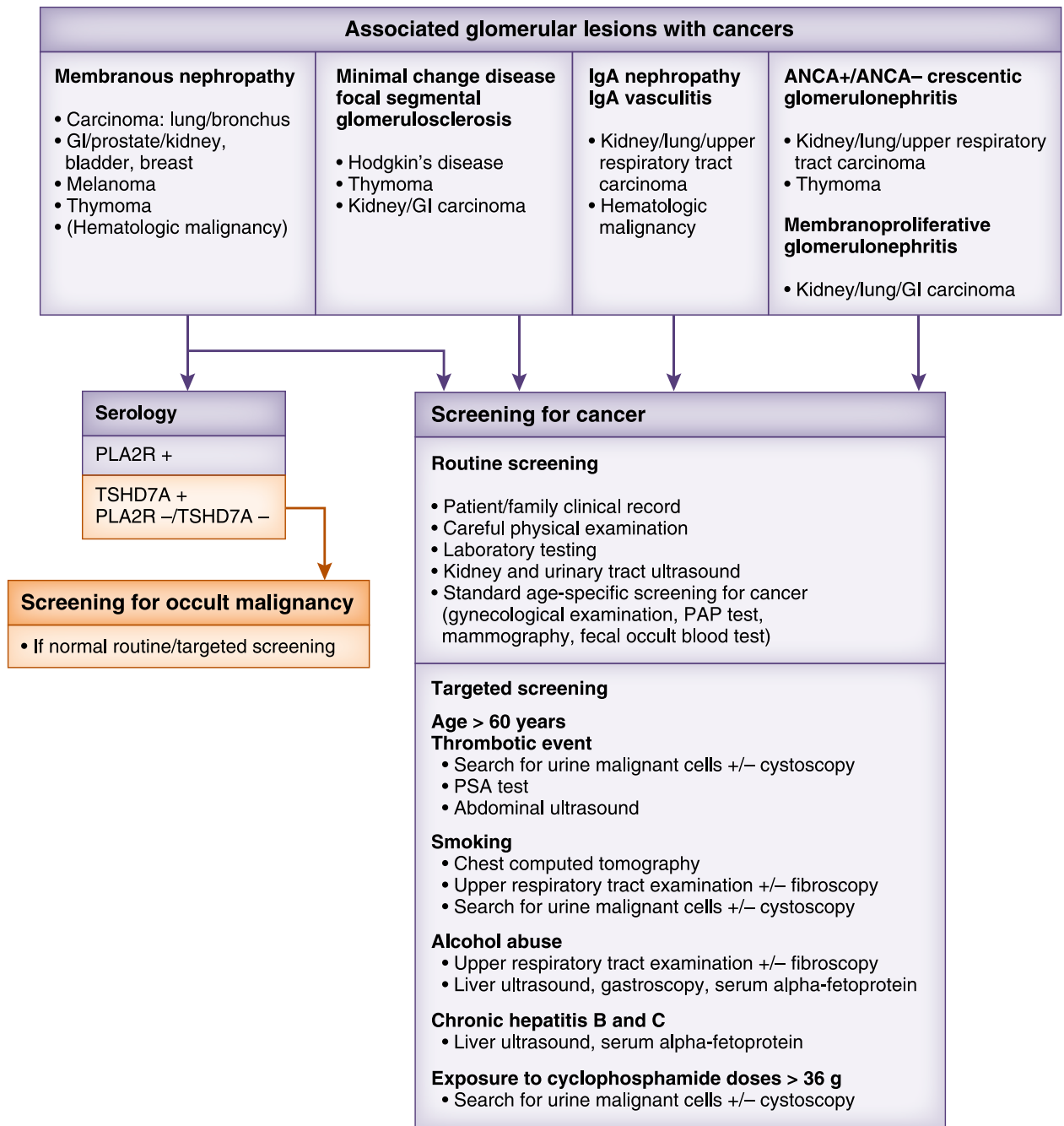


Figure 1. | Routine and targeted cancer screening in patients with glomerulopathy. The algorithm shows the main types of tumor associated with the various types of glomerulopathy and the two-step work-up including routine screening (all patients), followed by targeted screening (depending on the patient's cancer risk factors). In thrombospondin type-1 domain-containing protein 7A (THSD7A)-positive patients with membranous nephropathy and in those that are double negative, we suggest search for an occult malignancy if the routine and targeted screening is negative. GI, gastrointestinal; PAP test, Papanicolaou test; PLA2R, phospholipase A2 receptor; PSA, prostatic-specific antigen.

detected within the first 12 months of the diagnosis in 80% of patients, but an excess risk of cancer persists for at least 5 years (1). An excess of eight inflammatory cells per glomeruli was reported as a distinctive histologic lesion suggestive for malignancy-associated forms in a systematic review of 240 membranous nephropathy biopsy specimens (3), an observation not usually replicated in other series.

Malignancy-Associated Membranous Nephropathy

About 70%–80% of membranous nephropathy are classified as primary, with the remainder secondary forms developing in the course of autoimmune diseases, infections, drug exposure, or malignancy. Identification of the two target antigens PLA2R and THSD7A allowed the development of serologic tests for circulating anti-PLA2R or anti-THSD7A autoantibodies (4). In primary

membranous nephropathy, polytypic IgG4 subclass typically colocalizes with PLA2R or THSD7A in glomerular subepithelial deposits, and are usually found with circulating antibodies in 70%–80% and 1%–5% of adults, respectively. Secondary forms classically show predominant IgG1, IgG2, and IgG3 glomerular staining without PLA2R or THSD7A staining, and negative serologic test for anti-PLA2R and anti-THSD7A (4).

Recent cohort studies have indicated that malignancy-associated membranous nephropathy does not always share the classic secondary membranous nephropathy immunologic pattern; indeed, serum anti-PLA₂R antibody and IgG4-dominant deposits were reported in 20%–38% of malignancy-associated cases, which suggests coincidental association rather than causality. The link between cancer and THSD7A is also uncertain. In a series of 49 THSD7A-associated membranous nephropathies, eight (16%) patients developed cancer, but the chronology was suggestive of causality in only three patients (5). A single patient among 44 (2%) patients with cancer and membranous nephropathy developed anti-THSD7A antibodies, whereas 18 (41%) showed anti-PLA2R antibodies (6). Thus, the incidence of THSD7A antibodies seems to be low in patients with cancer-associated membranous nephropathy, whereas PLA2R antibodies are not uncommon in these patients. Actually, we lack robust epidemiologic data. There are informative case reports of membranous nephropathy where THSD7A is clearly linked to cancer because it is found in the tumor cells and the patient enters remission after efficacious anticancer therapy (7), but not all patients with a THSD7A-expressing tumor will develop membranous nephropathy. Although the discovery of PLA2R and THSD7A has provided tools to investigate pathophysiology and monitor patients, a number of questions remain. How the status for PLA2R and THSD7A affects the diagnostic work-up, the kidney outcome after tumor therapy or the pathogenic link between membranous nephropathy and cancer needs to be further evaluated.

Proposed Cancer Screening of Patients with Nephrotic Syndrome

A strategy for cancer screening in patients with glomerulopathy is proposed in Figure 1. Standard cancer screening is recommended in all patients with glomerular lesions that may be associated with malignancy. Targeted screening tests must be additionally performed according to each patient's specific risk factors for cancer. For the time being, occult malignancy should be considered in cases of negative routine and targeted screening in patients with PLA2R-negative membranous nephropathy, whether they are THSD7A-positive or double negative for PLA2R and THSD7A. Our recommendation mainly relies on the poorer cancer-free survival in PLA2R-negative patients (8) and the rare cases where a causality link with THSD7A is plausible (6).

Recent series have underlined the high diagnostic accuracy and moderate to high sensitivity and specificity of the ¹⁸F-fluorodeoxyglucose positron emission tomography/computed tomography (F-FDG-PET/CT) for cancer screening in patients suspected of having paraneoplastic manifestations (9). Interestingly, a preliminary retrospective analysis suggested that FDG-PET/CT was as efficient as targeted screening to early detect neoplasia in patients with

membranous nephropathy and normal routine evaluation (10). When available, FDG-PET/CT may then represent the investigation of choice at least to search for occult malignancy. Prospective, randomized studies are now required to compare these diagnostic approaches and their effect on the global and kidney outcome in membranous nephropathy. Novel pathophysiologic advances are warranted to identify more reliable noninvasive or histologic biomarkers to better stratify the risk of cancer-associated glomerulopathy at diagnosis and for long-term follow-up.

Acknowledgments

The content of this article does not reflect the views or opinions of the American Society of Nephrology (ASN) or CJASN. Responsibility for the information and views expressed therein lies entirely with the author(s).

Disclosures

Dr. Plaisier reports receiving personal fees from Amgen and Gilead Sciences outside the submitted work. Dr. Ronco reports receiving grant support from Alexion and Amgen; fees for advisory work from Amicus Therapeutics, Idorsia Pharmaceuticals, and MorphoSysAG; and travel support from Sanofi Genzyme, all outside the submitted work.

References

1. Bjørneklett R, Vikse BE, Svarstad E, Aasarød K, Bostad L, Langmark F, Iversen BM: Long-term risk of cancer in membranous nephropathy patients. *Am J Kidney Dis* 50: 396–403, 2007
2. Cambier JF, Ronco P: Onco-nephrology: Glomerular diseases with cancer. *Clin J Am Soc Nephrol* 7: 1701–1712, 2012
3. Lefaucheur C, Stengel B, Nochy D, Martel P, Hill GS, Jacquot C, Rossert J; GN-PROGRESS Study Group: Membranous nephropathy and cancer: Epidemiologic evidence and determinants of high-risk cancer association. *Kidney Int* 70: 1510–1517, 2006
4. De Vriese AS, Glassock RJ, Nath KA, Sethi S, Fervenza FC: A proposal for a serology-based approach to membranous nephropathy. *J Am Soc Nephrol* 28: 421–430, 2017
5. Zaghrini C, Seitz-Polski B, Justino J, Dolla G, Payré C, Jourde-Chiche N, Van de Logt AE, Booth C, Rigby E, Lonnbro-Widgren J, Nystrom J, Mariat C, Cui Z, Wetzels JFM, Ghiggeri G, Beck LH Jr., Ronco P, Debiec H, Lambeau G: Novel ELISA for thrombospondin type 1 domain-containing 7A autoantibodies in membranous nephropathy. *Kidney Int* 95: 666–679, 2019
6. Wang J, Cui Z, Lu J, Probst C, Zhang YM, Wang X, Qu Z, Wang F, Meng LQ, Cheng XY, Liu G, Debiec H, Ronco P, Zhao MH: Circulating antibodies against thrombospondin type-I domain-containing 7A in Chinese patients with idiopathic membranous nephropathy. *Clin J Am Soc Nephrol* 12: 1642–1651, 2017
7. Hoxha E, Wiech T, Stahl PR, Zahner G, Tomas NM, Meyer-Schwesinger C, Wenzel U, Janneck M, Steinmetz OM, Panzer U, Harendza S, Stahl RA: A mechanism for cancer-associated membranous nephropathy. *N Engl J Med* 374: 1995–1996, 2016
8. Timmermans SA, Ayalon R, van Paassen P, Beck LH Jr., van Rie H, Wirtz JJ, Verseput GH, Frenken LA, Salant DJ, Cohen Tervaert JW; Limburg Renal Registry: Anti-phospholipase A2 receptor antibodies and malignancy in membranous nephropathy. *Am J Kidney Dis* 62: 1223–1225, 2013
9. Feng Z, Wang S, Huang Y, Liang X, Shi W, Zhang B: A follow-up analysis of positron emission tomography/computed tomography in detecting hidden malignancies at the time of diagnosis of membranous nephropathy. *Oncotarget* 7: 9645–9651, 2016
10. Sheikhabaei S, Marcus CV, Fragomeni RS, Rowe SP, Javadi MS, Solnes LB: Whole-body ¹⁸F-FDG PET and ¹⁸F-FDG PET/CT in patients with suspected paraneoplastic syndrome: A systematic review and Meta-analysis of diagnostic accuracy. *J Nucl Med* 58: 1031–1036, 2017