



HAL
open science

Treatment of chronic hepatitis C-associated cryoglobulinemia vasculitis at the era of direct-acting antivirals

Cloé Comarmond, Patrice Cacoub, David Saadoun

► **To cite this version:**

Cloé Comarmond, Patrice Cacoub, David Saadoun. Treatment of chronic hepatitis C-associated cryoglobulinemia vasculitis at the era of direct-acting antivirals. *Therapeutic Advances in Gastroenterology*, 2020, 13, pp.175628482094261. 10.1177/1756284820942617 . hal-02934756

HAL Id: hal-02934756

<https://hal.sorbonne-universite.fr/hal-02934756v1>

Submitted on 9 Sep 2020

HAL is a multi-disciplinary open access archive for the deposit and dissemination of scientific research documents, whether they are published or not. The documents may come from teaching and research institutions in France or abroad, or from public or private research centers.

L'archive ouverte pluridisciplinaire **HAL**, est destinée au dépôt et à la diffusion de documents scientifiques de niveau recherche, publiés ou non, émanant des établissements d'enseignement et de recherche français ou étrangers, des laboratoires publics ou privés.

Treatment of chronic hepatitis C-associated cryoglobulinemia vasculitis at the era of direct-acting antivirals

Cloé Comarmond , Patrice Cacoub and David Saadoun

Abstract: Hepatitis C virus (HCV) infection is responsible for both hepatic and extrahepatic manifestations. Before the era of direct-acting antivirals (DAA), cryoglobulinemia was related to HCV infection in 70–90% of cases. Observed in 30% to 40% of patients with hepatitis C, mixed cryoglobulinemia is mainly asymptomatic. Conversely, symptomatic cryoglobulinemia vasculitis (CV) can occur in 5–10% of patients with HCV-associated cryoglobulinemia. CV is a small-vessel systemic vasculitis, and organ damage results from circulation and precipitation of cryoglobulins and complement activation. A wide range of clinical symptoms can be observed during CV, and manifestations are potentially life-threatening. The most frequent manifestations occurring in CV are cutaneous, with recurrent purpura, articular with joint pains, neurologic with peripheral neuropathy, and renal with membranoproliferative glomerulonephritis. DAA have drastically changed chronic HCV therapy. DAA induce sustained virological response (SVR) rates greater than 95%, and also improve extrahepatic manifestations such as CV. We review recent studies investigating the clinical and immune effects of DAA therapy on HCV-CV.

Keywords: cryoglobulinemia, direct-acting antivirals, HCV, treatment, vasculitis

Received: 15 April 2020; revised manuscript accepted: 12 June 2020.

Introduction

The advent of direct-acting antivirals (DAA) against hepatitis C virus (HCV) has dramatically changed the management and the prevalence of chronic HCV infection. DAA has improved treatment efficacy of HCV infection, resulting in sustained virological response (SVR) rates greater than 95% and a very good safety profile, including in patients previously considered difficult to treat (patients with cirrhosis, hepatocellular carcinoma (HCC), co-infected with HIV, or extra-hepatic manifestations such as cryoglobulinemia vasculitis).^{1–4} Circulating mixed cryoglobulins, composed of immune complexes of polyclonal IgG, monoclonal IgM with rheumatoid factor (RF) activity, are detected in 40–60% of patients with chronic HCV infection. Cryoglobulinemia vasculitis (CV) is observed in approximately 10% of patients with HCV-associated cryoglobulinemia. Before the era of DAA, HCV was identified as the main cause of

cryoglobulinemia. First-line treatment for HCV-associated CV (HCV-CV) is antiviral therapy because viral eradication is associated with clinical improvement in most patients with CV.^{5,6} However, despite SVR, CV may persist or reappear over variable lengths of time from the completion of therapy.^{5,7} Patients with HCV-associated cryoglobulinemia have an increased risk of developing B-cell non-Hodgkin's lymphoma.⁸

Despite successful treatment of HCV, circulating cryoglobulins, complement activation, RF activity and clonal B-cell proliferation may persist, and clinical relapse of CV is observed in patients with SVR.^{6,9} A large majority of HCV-infected patients achieve SVR following DAA treatment; however, clinical and immunological responses in HCV-CV are less consistent, showing varied results depending on organ involvement, reduction or disappearance of cryoglobulin,

Ther Adv Gastroenterol

2020, Vol. 13: 1–11

DOI: 10.1177/
1756284820942617

© The Author(s), 2020.
Article reuse guidelines:
sagepub.com/journals-
permissions

Correspondence to:

David Saadoun
Department of Internal
Medicine and Clinical
Immunology, Hôpital La
Pitié-Salpêtrière, 47–83,
boulevard de l'Hôpital,
75651 Cedex 13, Paris,
France

Sorbonne Université,
Département de Médecine
Interne et Immunologie
Clinique, Paris, France,
AP-HP, Groupe Hospitalier
Pitié-Salpêtrière, Centre
National de Référence
Maladies Auto-Immunes
Systémiques Rares,
Centre National de
Référence Maladies
Auto-Inflammatoires et
Amylose Inflammatoire
INSERM, UMR_S 959,
Paris, France; CNRS,
FRE3632, Paris, France;
AP-HP, Groupe Hospitalier
Pitié-Salpêtrière
david.saadoun@aphp.fr

Cloé Comarmond
Patrice Cacoub
Sorbonne Université,
Département de Médecine
Interne et Immunologie
Clinique, Paris, France,
AP-HP, Groupe Hospitalier
Pitié-Salpêtrière, Centre
National de Référence
Maladies Auto-Immunes
Systémiques Rares,
Centre National de
Référence Maladies
Auto-Inflammatoires et
Amylose Inflammatoire
INSERM, UMR_S 959,
Paris, France; CNRS,
FRE3632, Paris, France;
AP-HP, Groupe Hospitalier
Pitié-Salpêtrière

normalization of C4 level and/or disappearance of RF activity. Partial clinical and immune response after DAA treatment could be improved with earlier administration.^{6,10,11}

We review recent studies investigating the effect of DAA therapy on HCV-CV and exploring the restoration of HCV-specific immune responses following DAA therapy.

Safety and efficacy of DAA therapy in HCV-CV

Patients with HCV-CV have high rates of SVR (74–100%) and complete or partial clinical remission (61–100%) after treatment with DAA (Table 1). Similar to the rate of SVR in HCV-infected patients without extra-hepatic manifestation, patients with HCV-associated CV reach SVR in 90% of cases.^{12–14} Most studies have reported global clinical response in more than 80% of patients, with 20% partial clinical response and complete clinical response in 60%. The rate of complete clinical remission in HCV-CV after DAA therapy varied, especially according to organ involvement.^{2,4,6,12} A greater rate of response is observed in skin and skeletal manifestations such as myalgia, arthralgia, purpura, and skin ulcers (75–100%). The resolution of cutaneous manifestations is often described as rapid and complete. The rates of complete improvement of peripheral neuropathy and glomerulonephritis are lower, ranging from 30% to 70% (Table 2). Initial series of patients with HCV-CV treated with DAA reported a rate of viral suppression of 100% and a SVR12 rate of 83%.² This rate was similar to the SVR12 rate reported with same regimens in cohorts of non-cryoglobulinemic HCV patients. No difference in SVR12 was observed after DAA therapy between HCV patients with and without cryoglobulinemia.¹³ In a prospective study of patients with HCV-CV treated with Sofosbuvir (SOF) and Daclatasvir (DAC), our group reported SVR achievement in all patients ($n=41$). Complete clinical response was observed in 90% of patients and partial clinical response in 10% after 12 or 24 weeks of SOF and DAC therapy.¹² Gragnani *et al.* reported prospectively that 93% of HCV patients with CV ($n=41/44$) reached a complete response (CR) or partial response (PR), and 100% achieved SVR.⁴ Global clinical responses increased to 100% at SVR24, including 77% of complete clinical response.⁴ A recent Italian prospective study confirmed that

CV symptoms improved in 85% of cases, with CR or PR after virological response and persisted during follow up.¹⁴ The tolerance of DAA is excellent, and no difference was observed between the different DAA combinations (Table 1). Severe adverse events (SAE) of DAA regimens for HCV patients were rare [ribavirin (RBV)-related anemia requiring blood transfusion, hyperbilirubinemia]. SOF and dasabuvir have minimal drug–drug interactions and few adverse events (fatigue, symptomatic bradyarrhythmias). Adverse events most frequently reported with DAC, ledipasvir, ombitasvir, and elbasvir (NS5A inhibitors) were headache, fatigue, nausea, diarrhea, and insomnia. Across all studies using DAA, SAE or early discontinuation was less than 3%. Comparatively, SAEs, most frequently due to severe anemia requiring erythropoietin or red blood cell transfusion, were observed in more than 40% in HCV patients receiving first-generation protease inhibitors (telaprevir or boceprevir) associated with interferon (IFN) and RBV.¹

Outcome of cryoglobulinemia vasculitis after eradication of HCV

DAA regimens provide a safe and effective treatment for HCV eradication. However, the cost of DAA therapy remains more expensive than older treatment options. Thus, it is important to assess the long-term benefit on hepatic and extrahepatic outcomes of a DAA-induced SVR. Despite sustained clinical remission and virologic response after DAA therapy, cryoglobulinemia may persist or reappear. Symptoms of CV may reappear shortly after end of treatment by DAA therapy.^{5,7} Persistent HCV-CV following virus eradication after DAA therapy has also been described.¹⁸ Overall, 48% of HCV-CV patients had complete disappearance of cryoglobulinemia, and an additional 17% experienced a decrease in cryoglobulins. In a cohort of 18 HCV patients with symptomatic CV, clinical response was worse in HCV patients with severe vasculitis.¹⁶ Six among seven (85.7%) patients with mild–moderate CV, and one of seven (14.2%) patients with severe CV, reached complete clinical response. Despite HCV eradication in four patients with fulminant CV, none achieved a complete clinical response at the end of follow up. Bonacci *et al.* described five patients with relapse during follow up after HCV eradication.⁵ Patients with CV relapse had more frequently underlying cirrhosis (four of five relapses, 80%). Several months after the end of

Table 1. Studies with DAA therapy for patients with HCV-associated CV.

Author, Study design	n	DAA regimens	Immuno-suppressive therapy (n)	SVR (%)	CR (%)	PR (%)	Disappearance of cryoglobulins (%)	Adverse effects	Relapse
Sise <i>et al.</i> ² , Retrospective	12	SOF/SIM (n=8) SOF/RBV (n=4)	RTX (n=4)	83%	33%	33%	44%	17% of serious adverse events	2/12 (16.6%) after treatment discontinuation
Saadoun <i>et al.</i> ³ , Prospective	24	SOF/RBV X 24wk	RTX (n=4)	74%	87%	-	46%	The most common side effects were fatigue, insomnia and anaemia. Two serious adverse events were observed	4/24 (16.6%) Among patients with virological failure (n=2) or relapse (n=4), five had a liver cirrhosis
Bonacci <i>et al.</i> ⁶ , Prospective	35	3D (n=10) SOF/LDV (n=10) SOF/SIM (n=2) DAC/SIM (n=3) SOF/DAC (n=2) Peg-IFN/DAA (n=5) Others (n=3) Use of RBV (n=24)	-	94%	71%	14%	45%	50% Anemia most frequently (26%), followed by asthenia and headache	Three (8.5%) patients relapsed at follow up 12 and one patient presented a breakthrough at week 4 of treatment; cirrhosis was present in two of the four (50%) patients with treatment failure
Gragnani <i>et al.</i> ⁴ , Prospective	44	SOF/RBV (n=18) SOF/SIM/± RBV (n=12) SOF/LDV/± RBV (n=10) SOF/DAC/± RBV (n=4)	RTX (n=2)	100%	66%	27%	32%	59% (generally mild, with the exception of 1 patient with ribavirin-related anemia requiring blood transfusion)	
Emery <i>et al.</i> ¹⁶ , Retrospective	18	DAA ± IFN	RTX (n=3)	89%	39%	22%	29%	22.8% (n=19) RBV-induced anemia	One (5.5%) patient had clinical evidence of relapse and was diagnosed with a lymphoproliferative disorder after DAA completion
Saadoun <i>et al.</i> ¹² , Prospective	41	SOF/DAC (n=32) X 12wk SOF/DAC (n=9) X 24wk	RTX (n=2)	100%	90%	10%	50%	17% Fatigue (12.2%), nausea (7.3%), vertigo and insomnia (2.4%)	

(Continued)

Table 1. (Continued)

Author, Study design	n	DAA regimens	Immuno-suppressive therapy (n)	SVR (%)	CR (%)	PR (%)	Disappearance of cryoglobulins (%)	Adverse effects	Relapse
Bonacci et al. ⁵ , Prospective	46	SOF-based regimen (n=21) 3D (n=13) SIM + DAC (n=4) GZV + EBR (n=3) FDV + DLR (n=1) Use of RBV (n=26)	CS (n=19) RTX (n=3) PE (n=1)	96%	70%			45% (mostly mild to moderate) Anemia (16%) because of RBV No early discontinuation of DAA	11% (4/5 with cirrhosis) Purpura (n=4) Sd nephro (n=1) Mesenteric ischemia and death (n=1)
Passerini et al. ¹³ , Retrospective	35	SOF-based regimen (n=23) 3D (n=7) Harvoni-R (n=4) 2D-R (n=1)		100%	70%		68.5%	57% (n=20) Anemia (n=10), asthenia (n=10), gastrointestinal (n=9), itch (n=7), neurologic (n=3), rash (n=1) No discontinuation	No relapse No death No loss of follow up
Gragnani et al. ¹⁴ , Prospective	85	3D (n=16) 3D+RBV (n=4) SOF/DAC ± RBV (n=16) SOF/LDV ± RBV (n=19) SOF/SIM (n=7) SOF/RBV (n=23)	RTX (n=2)	90.6%	96.7%		46.2% (SVR12) 69.2% (SVR24)	2/85 (2.3%) One interruption for hyperbilirubinaemia at week 1, the patient was hospitalized for the appearance of jaundice during therapy. Another patient, with severe CV, voluntarily interrupted treatment reporting a subjective worsening of a previous sensorimotor neuropathy not supported by 2 different neurological check-ups	3/85 (3.5%), liver disease F3 or F4
Cacoub et al. ¹⁷ , Prospective	148	SOF/DAC (n=53) SOF/RBV (n=51) SOF/LDV (n=23) SOF/SIM (n=18)	RTX (n=3) PE (n=5)	97.2%	72.6%	22.6%	52.2%	Premature DAA withdrawal was reported for 4.1% of patients.	After a median follow-up time of 15.3 months, four patients (2.8%) died
Total	488	SOF-based regimen (n=393, 80.5%)	RTX (n=20, 4%)	SVR (90.8%)	CR or PR (82.4%)		Disappearance of cryoglobulins (48%)	Severe adverse effects or early discontinuation (n=13, 2.7%)	Relapse or death (n=11, 2.5%)

Table 2. Clinical response according to organ involvement in patients with HCV-associated CV after DAA therapy.

Author	n	Skin manifestation	Peripheral neuropathy	Renal involvement	Others
Sise <i>et al.</i> ²	12	Purpura: 5/6, 83% disappearance Ulcers (n=1): 100% disappearance	2/4, 50% disappearance	2/6, 33% disappearance	Arthralgia: 3/7, 43% disappearance
Saadoun <i>et al.</i> ³	24	Purpura (n=16): 100% disappearance Ulcers (n=3): 100% disappearance	15/16, 94% improvement Motor symptoms: 4/8, 50% improvement	4/5, 80% improvement	Arthralgia (n=14): 100% disappearance
Bonacci <i>et al.</i> ⁶	35	Purpura: 21/23, 91% disappearance	13/18, 72% disappearance	5/7, 71% disappearance	Arthralgia: 10/11, 91% disappearance Weakness: 24/25, 96% disappearance
Gragnani <i>et al.</i> ⁴	44	Purpura (n=32): 28/32, 87.5% disappearance 2/32, 6.25% improvement 2/32, 6.25% persistence Ulcers (n=6): 100% disappearance	14/28, 50% disappearance 10/28, 36% improvement 4/28, 14% persistence	3/4, 75% disappearance 1/4, 25% improvement	Arthralgias (n=26): 12/26, 46% disappearance 6/26, 23% improvement 8/26, 31% persistence Weakness (n=34): 19/34, 56% disappearance 10/34, 29% improvement 5/34, 15% persistence Sicca syndrome (n=18): 8/18, 44.5% disappearance 6/18, 33% improvement 4/18, 22% persistence Renaud's phenomenon (n=14): 11/14, 79% disappearance 1/14, 7% improvement 2/14, 14% persistence
Emery <i>et al.</i> ¹⁶	18	7/15, 47% disappearance	2/6, 33% disappearance	3/10, 30% disappearance	
Saadoun <i>et al.</i> ¹²	41	Purpura (n=31): 100% disappearance Ulcers (n=7): 100% disappearance	2/21, 9.5% disappearance 17/21, 80% improvement 2/21, 9.5% persistence	2/5, 40% disappearance 1/5, 20% improvement 2/5, 40% persistence	Arthralgias (n=26): 100% disappearance Myocarditis (n=1): 100% disappearance Gut (n=1): 100% disappearance
Bonacci <i>et al.</i> ⁶	46	Purpura (n=23): 2/23, 6% persistence	5/18, 14% persistence	2/7, 5% persistence	Arthralgias (n=11): 1/11, 3% persistence
Gragnani <i>et al.</i> ¹⁴	85	Purpura (n=58): 48/58, 83% disappearance 5/58, 9% improvement 5/58, 9% persistence Ulcer (n=7): 100% disappearance	18/37, 49% disappearance 6/37, 16% improvement 13/37, 35% persistence	Proteinuria (n=9): 3/9, 33% disappearance 6/9, 67% persistence	Arthralgias (n=41): 12/41, 29% disappearance 12/41, 29% improvement 17/41, 41% persistence
Cacoub <i>et al.</i> ¹⁷	148	Purpura: 97.2% disappearance	77.1% disappearance	91.5% disappearance	Arthralgia: 85.7% disappearance

CV, cryoglobulinemia vasculitis; DAA, direct-acting antiviral; DAC, daclatasvir; HCV, hepatitis C virus.

treatment, three patients presented episodes of purpura. Relapse occurred respectively at 22, 24, 6, 12 and 15 months after DAA. Nephrotic syndrome was observed in one patient. One death occurred due to acute mesenteric ischemia 1 year after virologic eradication. Notably, cryoglobulinemia became positive or serum level increased during relapse in four (80%) of five of the patients.⁵ Our group described the long-term tolerance and efficiency of different IFN-free DAA regimens in 148 patients with HCV-CV enrolled in a prospective international multicenter cohort study.¹⁷ CR was reported for 106 patients (72.6%), PR for 33 patients (22.6%), and no response for seven patients (4.8%). More than 95% of the patients had SVR. In addition, cryoglobulinemia disappeared in more than half of HCV-CV patients. DAA therapy was very well tolerated, and withdrawal was reported for only 4% of patients. The severity of CV and peripheral neuropathy were associated with no or PR to DAA therapy [odds ratio (OR), 0.33; 95% confidence interval (CI), 0.12–0.91; $p=0.03$; and OR=0.31; 95% CI, 0.11–0.84; $p=0.02$, respectively]. After a median follow up of 15.3 months, death occurred in four patients (2.8%). The clearance of CV manifestation was observed in 97% for purpura, 91% for renal involvement, 86% for arthralgia, and 77% for peripheral neuropathy. Cryoglobulinemia disappeared in 52% of cases. SVR after DAA therapy was associated with less severe complication of HCV infection, such as cirrhosis, HCC, and extrahepatic manifestations.¹⁹

Colussi *et al.* showed that patients who achieved SVR had a higher survival rate free from HCC than patients who did not reached SVR [hazard ratio (HR): 0.035, 95% CI: 0.015–0.084, $p<0.0001$].²⁰ Importantly, mixed cryoglobulinemia predicted the occurrence of HCC. The persistence of cryoglobulinemia independently of SVR was associated with a higher mortality from any cause (HR: 5.982, $p=0.028$ in patients with SVR and HR: 5.633, $p=0.047$ in patients without SVR).²⁰ Mortality could be reduced after SVR, even in patients without significant hepatic fibrosis. Predictive factors of new HCC occurrence or death from any cause during the follow up were high levels of HCV viremia (HR: 0.808, 95% CI: 0.666–0.980, $p=0.030$), platelet count (HR: 0.910, 95% CI: 0.831–0.996, $p=0.041$), presence of cryoglobulinemia (HR: 3.460, 95% CI: 1.035–11.56, $p=0.044$), and presence of SVR

(HR: 0.070, 95% CI: 0.025–0.194, $p<0.001$).²⁰ However, even after SVR and if the fibrosis score decreases during follow up, HCV patients with cirrhosis continue to have a higher risk of HCC (>2%/year) for many years. Thus, patients with cirrhosis should continue long-term surveillance.²¹

DAA therapy is also favorable for global survival of patients with HCV-related lymphoma.²² In a study of 46 patients with indolent B-cell non-Hodgkin lymphomas (NHL) or chronic lymphocytic leukemia (CLL) associated with HCV infection, Arcaini *et al.* reported that virological response after DAA therapy and lymphoproliferative disease response (LDR) are associated.²³ In this study, DAA therapy induced a high SVR rate (98%) and a high LDR rate in HCV-associated indolent lymphomas (67%). However, even after HCV eradication, the eventual appearance of B-NHL is also possible.⁸

The annual economic burden of extrahepatic manifestations seems to be significant and may be mitigated partly by treatment with DAA.²⁴ However, future studies are needed to evaluate the long-term durability of treatment response and for accounting amelioration of extrahepatic manifestations into the cost effectiveness of DAA regimens.

Immune restoration following DAA therapy

The mechanisms that lead to HCV-induced cryoglobulinemia, and the reasons why cryoglobulinemia can be symptomatic or asymptomatic, are not well understood. HCV envelope glycoproteins E1 and E2 help the virus enter into the hepatocytes and lymphocytes, possibly *via* the CD81 cell receptor.²⁵ HCV induced chronic stimulation of B cells by HCV, which generated clonal expansion of CD21⁺CD27⁺ memory B cells. These memory B cells release monoclonal or oligoclonal IgM cryoglobulins with RF activity. Immune complexes formed by immunoglobulins and HCV proteins precipitate in plasma below 37°C and activate complement, resulting in vascular damages and cryoglobulinemia vasculitis.^{26–29} Clonal expansion of CD27⁺IgM⁺CD21^{-low} memory B cells is highly prevalent in HCV-associated lymphoproliferation. These clonal cells are autoreactive as they produce RF autoantibodies. However, autoreactive CD27⁺IgM⁺CD21^{-low} memory B cells express reduced CD21, which mirrors an anergic state. Anergy is a well-known regulatory

mechanism for maintaining immune tolerance of autoreactive cells. To explain why only some HCV-infected individuals develop symptomatic cryoglobulinemia with severe vasculitis manifestations, whereas the majority remains asymptomatic, we hypothesize that anergic mechanisms fail to prevent autoimmune complication in some patients with HCV-related cryoglobulinemia. Our results suggest that TLR9 activation of CD27⁺IgM⁺CD21^{-low} memory B cells participate to break tolerance in patients with HCV-CV in driving HCV-CV autoimmunity through RF production and type 1 T cell responses(p9).³⁰

Some studies have reported immunologic response of HCV-CV to DAA therapy. Complete disappearance of cryoglobulinemia was reported in 48% of HCV-CV (Table 1). Normalization or significant decrease of RF levels were observed in 8 of 28 (28%) patients.^{2,4,6,12,31} Normalization or significant increase of C4 levels was reported in 20 of 41 patients (49%).^{2-4,6,12,31} Despite high rates of HCV elimination after DAA therapy (95%), only half of patients with HCV-CV presented normalization of cryoglobulinemia or complement level.

Bonacci *et al.* showed that immunologic response was associated with clinical improvement in 73% of patients.⁶ Conversely, clinical response was associated with normalization of immunologic parameters in only 37% of patients.⁶ Complete immunologic response was more frequently observed after 24 weeks of DAA therapy than after 12 weeks of DAA therapy (70% and 37%, respectively). At baseline, a low cryoglobulinemia was independently associated with a good immunological response.⁶

Resolution of CV seems to be inversely correlated with severity of lymphoproliferative disease and severity of organ damage. These data support that HCV elimination need to be achieved earlier as possible. Schiavinato *et al.* described HCV-infected patients with ($n=9$) or without ($n=20$) associated lymphoproliferative disease and the impact of interferon-free antiviral therapy on peripheral blood lymphocytes.¹⁰ SVR was reached in all patients. After HCV eradication, HCV-infected patients with lymphoproliferative disease presented a B-cell compartment reduced of 39%, and a less important reduction of 9% in HCV patients without lymphoproliferative disease. Among nine

patients with HCV-associated lymphoproliferative disease, six patients showed persistent clonal expansion of B cells even 1 year after end of treatment. Furthermore, three patients showed a reduction or normalization of the immunoglobulin light chain level. Thus, clonal expansion of memory B cells could reduce after HCV eradication by DAA treatment in the peripheral blood of patients with HCV-associated lymphoproliferative disorders. Conversely, persistence of monoclonal populations after virologic response have been reported.¹⁰ Persistence of clonal expanded B cell might underlie the risk of relapses of vasculitis, independently of viral infection. Depletion of B cell compartment with rituximab could be an additional therapeutic option to reduce the risk of vasculitis relapse, especially in patients with persistent cryoglobulinemia and detectable clonal memory B cells after the HCV eradication.

In our experience, amelioration of immune disorders of peripheral B- and T-cell populations in patients with HCV-associated cryoglobulinemia vasculitis is observed after HCV elimination induced by successful DAA therapy.¹¹ In HCV-associated cryoglobulinemia vasculitis, an increase rate of follicular helper T cells (TFH) has been positively correlated with T Helper 1 (Th1) and T Helper 17 Cells (Th17) polarization, clonal expansion of IgM⁺CD21^{-low} memory B cells. Expansion of TFH was also associated with lower rate of regulatory T cells (Tregs). B-cell disorders could be ameliorated after SVR following successful DAA therapy. Clonal anergic and autoreactive memory B cells and cryoglobulin levels decrease after HCV elimination. In addition, we demonstrated restoration of T-cell homeostasis by recovering Th1/Th17 balance and enhancing T lymphocyte activation pathway.

B-cell activating factor (BAFF) is a critical factor for B-cell maturation and survival.³² BAFF is also involved in the regulation of TFH, T-cell proliferation and cytokine production.³³ Rituximab treatment is marked by an increase in serum BAFF concentration and a decrease in B-lymphocyte stimulator receptor (BAFF-R).³⁴ After B-cell depletion by rituximab, the repopulation of the B-cell compartment in a BAFF-rich environment may favor long-lived autoreactive B cells,³⁵ which may be of special importance in HCV-induced B-cell proliferation. In contrast, BAFF-R expression on B-cells increase after DAA therapy.¹¹

Altogether, these data suggest that immune disorders observed in patients with HCV-associated CV may be partially resolved or improved after HCV eradication. It will be very interesting to analyse if the persistence of immune disturbances is associated with relapse of cryoglobulinemia vasculitis.

Management of patients with HCV-CV in the era of DAA

Nowadays, simplified anti-viral therapy with glecaprevir (300 mg)/pibrentasvir (120 mg) during 8 weeks, or SOF (400 mg)/velpatasvir (100 mg) during 12 weeks, is recommended in HCV patients without cirrhosis and who have not previously received HCV treatment.^{36,37} Simplified anti-viral therapy is not based on HCV genotype. Simplified anti-viral therapies are not recommended in patients with prior HCV treatment, cirrhosis, end-stage renal disease [estimated glomerular filtration rate (eGFR) < 30 ml/min/m²], co-infected with HIV or HBV, pregnant, hepatocellular carcinoma, or liver transplantation. In patients with renal disease, anti-viral therapy depends on the severity of renal damage.³⁸ DAA for the antiviral therapy of HCV in patients with mild or moderate renal impairment (chronic kidney disease (CKD) stage 1, 2, or 3), have been approved without dose adjustment. However, other drugs may interact with DAA, requiring dose adjustment. Two regimens based on DAAs have been approved recently for the antiviral therapy of HCV in patients with severe renal impairment (CKD stage 4/5, eGFR less than 30 ml/min/1.73 m² or end-stage renal disease requiring hemodialysis): elbasvir/grazoprevir and glecaprevir/pibrentasvir.³⁹ SOF has predominant renal excretion. Safety and efficacy of SOF have not been established in patients with severe renal impairment.

Across all studies, long-term follow up after DAA therapy show high level of clinical response (85%), either partial (20%) or complete disappearance of vasculitis symptoms (65%) (Table 1). SVR achievement is correlated to clinical response. However, clinical remission of vasculitis is also observed in patients with virological relapse.^{2,4,12,16} Overall, more than 50% of HCV-CV patients who achieve SVR after DAA therapy, had a complete clinical remission. Complete clinical response is defined as amelioration or disappearance of all the baseline vasculitis symptoms and

absence of clinical relapse. Some symptoms of CV seem to be more prone to resolve after SVR. Cutaneous manifestation such as purpura and skin ulcers, articular manifestations, and myalgia were most frequently reported to respond with rapid improvement and complete resolution (ranging from 75% to 100%) (Table 2). Peripheral neuropathy and renal disorders had less frequent CR compared with cutaneous and articular manifestations (30–70% versus 75–100%, respectively).^{2–4,6,12,13,16,17}

Mixed cryoglobulinemia is detected in 40–60% of HCV-infected patients. In most HCV patients, the presence of cryoglobulinemia is asymptomatic. Manifestations of cryoglobulinemia vasculitis, ranging from mild symptoms to fulminant life-threatening complications, are observed in approximately 15% of patients. Although cryoglobulinemia without symptoms is possible in HCV patients, viral clearance is strongly associated with clinical response of CV. Consistent with international guidelines on HCV treatment, anti-viral therapy should be started without delay for HCV patients with extrahepatic manifestations such as vasculitis manifestations.^{40,41} Most HCV-associated CV manifestations have been shown to disappear after HCV clearance after antiviral therapy with DAA. To treat HCV-CV, it is always recommended to eliminate HCV infection using DAA therapy.⁴⁰ Management of patients with HCV-CV by combining antiviral treatment with plasmapheresis and/or deletion of B-cell clonal expansions using rituximab should be tailored according to the severity of CV disease. Patients with symptomatic disease that persists after antiviral therapy remain candidates for immunotherapy. Patients with mild-to-moderate CV should be treated with an optimized DAA therapy. Severe CV manifestations, such as renal involvement (membranoproliferative glomerulonephritis), skin necrosis, peripheral neuropathy, gastrointestinal vasculitis (intestinal ischemia), lung involvement, heart and/or CNS vasculitis, may require additional immunosuppressive drugs to DAA therapy (Figure 1).⁴² Rituximab is discussed for HCV-CV patients with severe systemic manifestations, including renal involvement, large necrotizing ulcers, and polyneuropathy.^{40,43} Rituximab is administered intravenously at a dose of 375 mg/m² on days 1, 8, 15, and 22.⁴⁴ In severe cases, rituximab 375 mg/m² every week for 4 weeks should be administered, with plasmapheresis if necessary, associated with DAA

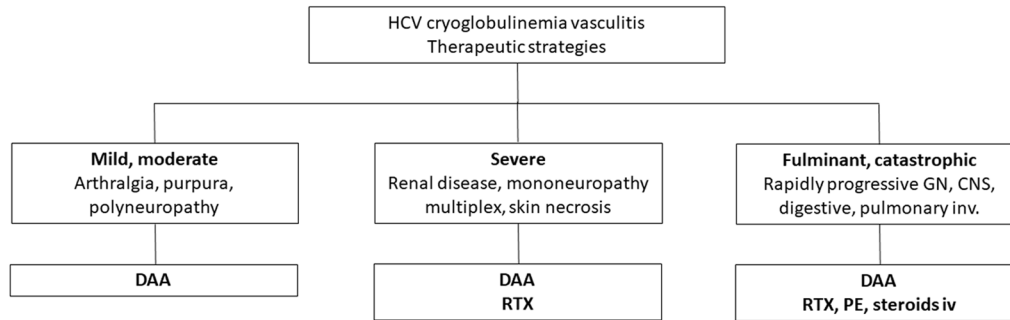


Figure 1. Summary of additional treatments suggested according to the severity of HCV-related CV (adapted from Cacoub *et al.*²⁶)

CV, cryoglobulinemia vasculitis; DAA, direct-acting antivirals; GN, glomerulonephritis; HCV, hepatitis C virus; inv., involvement; iv, intravenous; PE, plasma exchange; RTX, rituximab.

therapy.⁴⁵ During plasmapheresis, the exchange solution should be warmed to body temperature to avoid cryoglobulin precipitation. In case of acute cryoglobulinemic symptoms, 3–8 procedures should be considered, every 1–3 days: 1–1.5 total plasma volume.^{5,46} In fulminant cases such as diffuse alveolar hemorrhage and/or rapidly progressive glomerulonephritis (pulmonary-renal syndrome), or if there is hyperviscosity syndrome, plasmapheresis is usually performed. Removal of circulating cryoglobulins by therapeutic plasmapheresis is accepted as an adjunctive therapy for fulminant cases or severe exacerbation of vasculitis, especially with rapidly progressive glomerulonephritis, central nervous system involvement, cardiac manifestations, ulcers or cutaneous necrotizing vasculitis.^{47,48} Complementary and alternative therapies after treatments previously mentioned, are limited. Low-dose corticosteroids may help to control inflammatory symptoms such as articular manifestations but do not succeed in case of major organ involvement. Other immunosuppressants should be given only in case of severe and refractory forms of CV, frequently associated with B-cells lymphoproliferative disease.⁴⁹ After HCV clearance following DAA therapy, patients with partial clinical response, persistence of cryoglobulinemia, or relapse of vasculitis symptoms will need to be monitored and alternative therapies assessed.

Safety and efficiency of DAA regimens are excellent in patients with HCV-associated CV. A large majority of patients with HCV-CV (>95%) achieve CR or clinical PR after DAA therapy. Less than 5% of patients discontinue DAA treatment. Mortality was fewer than 3%. The achievement of SVR is necessary, but not sufficient, to

achieve a complete immunological and clinical response. SVR with DAA is associated with a rapid control of most vasculitis manifestations. However, cryoglobulins remain positive in about 50% of patients and a small proportion of HCV-associated cryoglobulinemia vasculitis patients remain at risk of clinical relapse and of B-NHL. In cirrhotic patients, the risk of hepatocellular carcinoma should be monitored. Severe forms of CV and peripheral neuropathy seem associated with a lack of response of HCV-CV to DAA therapy.

Conflict of interest statement

The authors declare that there is no conflict of interest.

Funding

The authors received no financial support for the research, authorship, and/or publication of this article.

ORCID iD

Cloé Comarmond  <https://orcid.org/0000-0002-0990-8213>

References

1. Hilgenfeldt EG, Schlachterman A and Firpi RJ. Hepatitis C: treatment of difficult to treat patients. *World J Hepatol* 2015; 7: 1953–1963.
2. Sise ME, Bloom AK, Wisocky J, *et al.* Treatment of hepatitis C virus-associated mixed cryoglobulinemia with direct-acting antiviral agents. *Hepatol Baltim Md* 2016; 63: 408–417.
3. Saadoun D, Thibault V, Si Ahmed SN, *et al.* Sofosbuvir plus ribavirin for hepatitis C virus-associated cryoglobulinaemia vasculitis:

- VASCUVALDIC study. *Ann Rheum Dis* 2016; 75: 1777–1782.
4. Gragnani L, Visentini M, Fognani E, *et al.* Prospective study of guideline-tailored therapy with direct-acting antivirals for hepatitis C virus-associated mixed cryoglobulinemia. *Hepatology* 2016; 64: 1473–1482.
 5. Bonacci M, Lens S, Mariño Z, *et al.* Long-term outcomes of patients with HCV-associated cryoglobulinemic vasculitis after virologic cure. *Gastroenterology* 2018; 155: 311–315.e6.
 6. Bonacci M, Lens S, Londoño MC, *et al.* Virologic, clinical, and immune response outcomes of patients with hepatitis C virus-associated cryoglobulinemia treated with direct-acting antivirals. *Clin Gastroenterol Hepatol* 2017; 15: 575–583.e1.
 7. Barbieri D, García-Prieto A, Torres E, *et al.* Mixed cryoglobulinaemia vasculitis after sustained hepatitis C virological response with direct-acting antivirals. *Clin Kidney J* 2019; 12: 362–364.
 8. Rodríguez de Santiago E, Velázquez Kennedy K, García González M, *et al.* HCV-positive lymphoma after sustained virological response with direct-acting antiviral agents: the game is not over after HCV eradication. *J Viral Hepat* 2018; 25: 614–615.
 9. Santoriello D, Pullela NK, Uday KA, *et al.* Persistent hepatitis C virus-associated cryoglobulinemic glomerulonephritis in patients successfully treated with direct-acting antiviral therapy. *Kidney Int Rep* 2018; 3: 985–990.
 10. Schiavinato A, Zanetto A, Pantano G, *et al.* Polyclonal and monoclonal B lymphocytes response in HCV-infected patients treated with direct-acting antiviral agents. *J Viral Hepat* 2017; 24: 1168–1176.
 11. Comarmond C, Garrido M, Pol S, *et al.* Direct-acting antiviral therapy restores immune tolerance to patients with hepatitis C virus-induced cryoglobulinemia vasculitis. *Gastroenterology* 2017; 152: 2052–2062.e2.
 12. Saadoun D, Pol S, Ferfar Y, *et al.* Efficacy and safety of sofosbuvir plus daclatasvir for treatment of HCV-associated cryoglobulinemia vasculitis. *Gastroenterology* 2017; 153: 49–52.e5.
 13. Passerini M, Schiavini M, Magni CF, *et al.* Are direct-acting antivirals safe and effective in hepatitis C virus-cryoglobulinemia? Virological, immunological, and clinical data from a real-life experience. *Eur J Gastroenterol Hepatol* 2018; 30: 1208–1215.
 14. Gragnani L, Cerretelli G, Lorini S, *et al.* Interferon-free therapy in hepatitis C virus mixed cryoglobulinaemia: a prospective, controlled, clinical and quality of life analysis. *Aliment Pharmacol Ther* 2018; 48: 440–450.
 15. Saadoun D, Resche Rigon M, Pol S, *et al.* Peg-IFN α /Ribavirin/Protease inhibitor combination in severe hepatitis C virus associated mixed cryoglobulinemia vasculitis. *J Hepatol*. Epub ahead of print 15 August 2014. DOI: 10.1016/j.jhep.2014.08.015.
 16. Emery JS, Kuczynski M, La D, *et al.* Efficacy and safety of direct acting antivirals for the treatment of mixed cryoglobulinemia. *Am J Gastroenterol* 2017; 112: 1298–1308.
 17. Cacoub P, Si Ahmed SN, Ferfar Y, *et al.* Long-term efficacy of interferon-free antiviral treatment regimens in patients with hepatitis C virus-associated cryoglobulinemia vasculitis. *Clin Gastroenterol Hepatol* 2019; 17: 518–526.
 18. Artemova M, Abdurakhmanov D, Ignatova T, *et al.* Persistent hepatitis C virus-associated cryoglobulinemic vasculitis following virus eradication after direct-acting antiviral therapy. *Hepatology* 2017; 65: 1770–1771.
 19. Kanwal F, Kramer J, Asch SM, *et al.* Risk of hepatocellular cancer in HCV patients treated with direct-acting antiviral agents. *Gastroenterology* 2017; 153: 996–1005.e1.
 20. Colussi G, Donnini D, Brizzi RF, *et al.* Sustained virologic response to direct-acting antiviral agents predicts better outcomes in hepatitis C virus-infected patients: a retrospective study. *World J Gastroenterol* 2019; 25: 6094–6106.
 21. Ioannou GN, Beste LA, Green PK, *et al.* Increased risk for hepatocellular carcinoma persists up to 10 years after HCV eradication in patients with baseline cirrhosis or high FIB-4 scores. *Gastroenterology* 2019; 157: 1264–1278.e4.
 22. Ferri C, Feld JJ, Bondin M, *et al.* Expert opinion on managing chronic HCV in patients with non-Hodgkin lymphoma and other extrahepatic malignancies. *Antivir Ther* 2018; 23: 23–33.
 23. Arcaini L, Besson C, Frigeni M, *et al.* Interferon-free antiviral treatment in B-cell lymphoproliferative disorders associated with hepatitis C virus infection. *Blood* 2016; 128: 2527–2532.
 24. Cacoub P, Buggisch P, Carrión JA, *et al.* Direct medical costs associated with the extrahepatic manifestations of hepatitis C infection in Europe. *J Viral Hepat*. Epub ahead of print 30 March 2018. DOI: 10.1111/jvh.12881.

25. Pileri P, Uematsu Y, Campagnoli S, *et al.* Binding of hepatitis C virus to CD81. *Science* 1998; 282: 938–941.
26. Cacoub P, Comarmond C, Domont F, *et al.* Extrahepatic manifestations of chronic hepatitis C virus infection. *Ther Adv Infect Dis* 2016; 3: 3–14.
27. Charles ED, Green RM, Marukian S, *et al.* Clonal expansion of immunoglobulin M+CD27+ B cells in HCV-associated mixed cryoglobulinemia. *Blood* 2008; 111: 1344–1356.
28. Charles ED, Orloff MIM, Nishiuchi E, *et al.* Somatic hypermutations confer rheumatoid factor activity in hepatitis C virus-associated mixed cryoglobulinemia. *Arthritis Rheum* 2013; 65: 2430–2440.
29. Dammacco F, Lauletta G, Russi S, *et al.* Clinical practice: hepatitis C virus infection, cryoglobulinemia and cryoglobulinemic vasculitis. *Clin Exp Med* 2019; 19: 1–21.
30. Comarmond C, Lorin V, Marques C, *et al.* TLR9 signalling in HCV-associated atypical memory B cells triggers Th1 and rheumatoid factor autoantibody responses. *J Hepatol* 2019; 71: 908–919.
31. Mazzaro C, Dal Maso L, Quartuccio L, *et al.* Long-term effects of the new direct antiviral agents (DAAs) therapy for HCV-related mixed cryoglobulinaemia without renal involvement: a multicentre open-label study. *Clin Exp Rheumatol* 2018; 36(Suppl. 111): 107–114.
32. Sasaki Y, Casola S, Kutok JL, *et al.* TNF family member B cell-activating factor (BAFF) receptor-dependent and -independent roles for BAFF in B cell physiology. *J Immunol Baltim Md* 1950 2004; 173: 2245–2252.
33. Ng LG, Sutherland APR, Newton R, *et al.* B cell-activating factor belonging to the TNF family (BAFF)-R is the principal BAFF receptor facilitating BAFF costimulation of circulating T and B cells. *J Immunol Baltim Md* 1950 2004; 173: 807–817.
34. Landau DA, Rosenzweig M, Saadoun D, *et al.* The B lymphocyte stimulator receptor-ligand system in hepatitis C virus-induced B cell clonal disorders. *Ann Rheum Dis* 2009; 68: 337–344.
35. Mahévas M, Michel M, Weill JC, *et al.* Long-lived plasma cells in autoimmunity: lessons from B-cell depleting therapy. *Front Immunol* 2013; 4: 494.
36. Lawitz E, Mangia A, Wyles D, *et al.* Sofosbuvir for previously untreated chronic hepatitis C infection. *N Engl J Med* 2013; 368: 1878–1887.
37. Zeuzem S, Foster GR, Wang S, *et al.* Glecaprevir-Pibrentasvir for 8 or 12 weeks in HCV genotype 1 or 3 infection. *N Engl J Med* 2018; 378: 354–369.
38. Maruyama A, Partovi N, Yoshida EM, *et al.* A review of direct-acting antivirals for the treatment of hepatitis C in patients with advanced chronic kidney disease. *Nephrol Dial Transplant* 2017; 32: 35–41.
39. Bruchfeld A and Lindahl K. Direct acting anti-viral medications for hepatitis C: clinical trials in patients with advanced chronic kidney disease. *Semin Dial* 2019; 32: 135–140.
40. Ramos-Casals M, Zignego AL, Ferri C, *et al.* Evidence-based recommendations on the management of extrahepatic manifestations of chronic hepatitis C virus infection. *J Hepatol* 2017; 66: 1282–1299.
41. European Association for the Study of the Liver. EASL recommendations on treatment of hepatitis C 2018. *J Hepatol* 2018; 69: 461–511.
42. Galli M, Monti G, Marson P, *et al.* Recommendations for managing the manifestations of severe and life-threatening mixed cryoglobulinemia syndrome. *Autoimmun Rev* 2019; 18: 778–785.
43. Ferri C, Cacoub P, Mazzaro C, *et al.* Treatment with rituximab in patients with mixed cryoglobulinemia syndrome: results of multicenter cohort study and review of the literature. *Autoimmun Rev* 2011; 11: 48–55.
44. Roccatello D, Baldovino S, Rossi D, *et al.* Rituximab as a therapeutic tool in severe mixed cryoglobulinemia. *Clin Rev Allergy Immunol* 2008; 34: 111–117.
45. Zignego AL, Gagnani L, Visentini M, *et al.* Reply. *Hepatol Baltim Md* 2017; 65: 1771–1772.
46. Rockx MA and Clark WF. Plasma exchange for treating cryoglobulinemia: a descriptive analysis. *Transfus Apher Sci* 2010; 42: 247–251.
47. Desbois AC, Comarmond C, Saadoun D, *et al.* Cryoglobulinemia vasculitis: how to handle. *Curr Opin Rheumatol* 2017; 29: 343–347.
48. Zignego AL, Pawlotsky JM, Bondin M, *et al.* Expert opinion on managing chronic HCV in patients with mixed cryoglobulinaemia vasculitis. *Antivir Ther* 2018; 23: 1–9.
49. Saadoun D, Pineton de Chambrun M, Hermine O, *et al.* Using rituximab plus fludarabine and cyclophosphamide as a treatment for refractory mixed cryoglobulinemia associated with lymphoma. *Arthritis Care Res* 2013; 65: 643–647.