



**HAL**  
open science

# Acute Coronary Syndrome With Immune Checkpoint Inhibitors: A Proof-of-Concept Case and Pharmacovigilance Analysis of a Life-Threatening Adverse Event

Jennifer Cautela, Franck Rouby, Joe-Elie Salem, Joachim Alexandre, Ugo Scemama, Charles Dolladille, Ariel Cohen, Franck Paganelli, Stéphane Ederhy, Franck Thuny

## ► To cite this version:

Jennifer Cautela, Franck Rouby, Joe-Elie Salem, Joachim Alexandre, Ugo Scemama, et al.. Acute Coronary Syndrome With Immune Checkpoint Inhibitors: A Proof-of-Concept Case and Pharmacovigilance Analysis of a Life-Threatening Adverse Event. *Canadian Journal of Cardiology*, 2020, 36 (4), pp.476-481. 10.1016/j.cjca.2019.11.035 . hal-02948357

HAL Id: hal-02948357

<https://hal.sorbonne-universite.fr/hal-02948357>

Submitted on 20 May 2022

**HAL** is a multi-disciplinary open access archive for the deposit and dissemination of scientific research documents, whether they are published or not. The documents may come from teaching and research institutions in France or abroad, or from public or private research centers.

L'archive ouverte pluridisciplinaire **HAL**, est destinée au dépôt et à la diffusion de documents scientifiques de niveau recherche, publiés ou non, émanant des établissements d'enseignement et de recherche français ou étrangers, des laboratoires publics ou privés.



Distributed under a Creative Commons Attribution - NonCommercial 4.0 International License

# **Acute Coronary Syndrome with Immune Checkpoint Inhibitors: A Proof-of-Concept Case and Pharmacovigilance Analysis of a Life- Threatening Adverse Event**

Jennifer Cautela, MD,<sup>1,2,3</sup> Franck Rouby, MD,<sup>4</sup> Joe-Elie Salem, MD, PhD,<sup>5</sup> Joachim Alexandre, MD, PhD,<sup>6,7,8</sup> Ugo Scemama, MD,<sup>9</sup> Charles Dolladille, MD,<sup>6,7,8</sup> Ariel Cohen, MD, PhD,<sup>10</sup> Franck Paganelli, MD, PhD,<sup>1,3</sup> Stéphane Ederhy, MD,<sup>10</sup> Franck Thuny, MD, PhD<sup>1,2,3</sup>

**Short title:** *Acute Coronary Syndrome with Checkpoint Inhibitors*

<sup>1</sup> Aix-Marseille Univ, Assistance Publique – Hôpitaux de Marseille, Mediterranean university Cardio-Oncology center (MEDI-CO center), Unit of Heart Failure and Valvular Heart Diseases, Department of Cardiology, Hôpital Nord, Marseille, France.

<sup>2</sup> Groupe Méditerranéen de Cardio-Oncologie (gMEDICO), France.

<sup>3</sup> Aix-Marseille Univ, Center for CardioVascular and Nutrition research (C2VN), Inserm 1263, Inra 1260, Marseille France.

<sup>4</sup>, Department of clinical pharmacology and pharmacovigilance, regional pharmacovigilance centre of Marseille Provence Corse, Marseille, France

<sup>5</sup> Sorbonne Université, Inserm, CIC Paris-Est, AP-HP, UNICO-GRECO Cardio-Oncology Program, Pitié-Salpêtrière Hospital, Department of Pharmacology, Paris, France.

<sup>6</sup>CHU de Caen, PICARO Cardio-oncology Program, Department of Pharmacology, Caen, F-14000, France.

<sup>7</sup>CHU de Caen, Department of Cardiology, Caen, F-14000, France.

<sup>8</sup> Université de Caen Normandie, Medical School, EA 4650, Signalisation, électrophysiologie et imagerie des lésions d'ischémie-reperfusion myocardique, Caen, F-14000, France.

<sup>9</sup> Aix-Marseille Univ, Assistance Publique – Hôpitaux de Marseille, Department of Imaging, Hôpital Nord, Marseille, France.

<sup>10</sup> Sorbonne Université, Hôpitaux Universitaires Est Parisien, Hôpital Saint Antoine, Hôpital Tenon. Assistance Publique-Hôpitaux de Paris, Inserm 856, Paris, France.

**Total word count:** 2870

## **Corresponding Author**

Prof. Franck Thuny

Mediterranean University Cardio-Oncology center, Unit of Heart Failure and Valvular Heart Diseases, Hôpital NORD, Chemin des Bourrely, 13015, Marseille, France

Tel: +33 (0) 491 968 683; Fax: +33 (0) 0491 968 979

E-mail: [franck.thuny@gmail.com](mailto:franck.thuny@gmail.com)

## **BRIEF SUMMARY**

Immune checkpoint inhibitors (ICIs) represent a major breakthrough therapy for cancers. Isolated clinical cases of acute coronary syndromes (ACSs) associated with ICI have been described without the establishment of a formal cause-and-effect relationship between treatment and adverse event. Report of a proof-of concept case and pharmacovigilance analysis provided new data suggesting that ACS may be another life-threatening cardiac adverse event occurring with ICIs exposure.

## **ABSTRACT**

Isolated cases of acute coronary syndromes (ACSs) associated with immune checkpoint inhibitors (ICIs) have been described without the establishment of a formal cause-and-effect relationship between treatment and adverse event.

First, we reported a case of ACS after the first administration of an ICI and with a fatal recurrence in another coronary area immediately after readministration. According to the guidelines, causality was considered as *certain*. Subsequently, the French pharmacovigilance database was queried and found four cases of ACS with coronary artery thrombosis. Causality was *probable* in these patients.

These data suggest that ACS may be another life-threatening cardiac adverse event occurring with ICIs exposure.

**Clinical Trial Registration:** NCT03492242

## **INTRODUCTION**

Immune checkpoint inhibitors (ICIs) represent a major breakthrough therapy in various cancers. They include programmed death-1 checkpoint inhibitor (PD-1<sub>i</sub>), programmed death ligand-1 checkpoint inhibitor (PD-L1<sub>i</sub>), and cytotoxic T-lymphocyte-associated protein-4 inhibitors (CTLA-4<sub>i</sub>). These cancer therapies are associated with frequent immune-related adverse events (irAEs) that can have an impact on patients' overall prognosis.<sup>1</sup> ICI-induced myocarditis is the most severe cardiac complication of this treatment and is associated with a fatality rate of approximately 50%.<sup>1,2,3</sup> Pericarditis and vasculitis are two other cardiovascular irAEs.<sup>2,3,4,5,6</sup> Recently, isolated clinical cases of acute coronary syndromes (ACSs) associated with ICI have been described without the establishment of a formal cause-and-effect relationship between treatment and adverse events.<sup>7,8</sup> We aimed to describe new data showing that ACS may be associated with ICI.

## **METHODS**

First, we reported a case of a 52-year-old woman, who was suspected of ACS after the first administration of a PD-L1<sub>i</sub> and a fatal recurrence in another coronary area immediately after readministration. Subsequently, the French pharmacovigilance database was queried for all ICI-induced adverse drug reactions reported until March 30, 2019 (NCT03492242). Immune checkpoint inhibitor drugs studied were nivolumab, pembrolizumab, ipilimumab, atezolizumab, and avelumab. We selected all cases with at least one adverse effect listed in the MedDRA Standard Medical Query "ischemic heart disease". Finally, all the "ischemic heart diseases" cases were analyzed to identify those related to ACS with an evidence of coronary artery thrombosis on angiogram. Drug exposition was defined by the presence in the case safety reports of an ICI drug coded as "suspect". Causality assessment has been assessed

according to the adverse drug reactions (ADR) guidelines<sup>9</sup> (**Supplementary Table S1**) and the Naranjo scale<sup>10</sup> (**Supplementary Table S2**).

## RESULTS

### Proof-of-Concept Case (Figure 1)

A 52-year-old woman with metastatic lung cancer was admitted to the coronary care unit for recurrent acute chest pain five days after the first administration of a PD-L1<sub>i</sub> and a mitogen-activated protein kinase inhibitor (MEK<sub>i</sub>) during an ongoing open label phase Ib/II clinical trial. An active smoking habit was her only cardiovascular risk factor and pre-therapeutic ECG, troponin T serum level (<14ng/L) and echocardiography were normal. She had received a first-line treatment combining docetaxel with carboplatin and a second line with only nivolumab (4 injections). The combination of PD-L1<sub>i</sub> plus MEK<sub>i</sub> was started 44 days after the last injection of nivolumab because of disease progression. Four hours after the last chest pain episode, ECG showed a Q-wave in the inferior leads (**Figure 2A**), and troponin T and NT-proBNP levels were 2076ng/L and 7871ng/L respectively. Echocardiography showed left ventricle (LV) inferior wall akinesia, with a 45% LV ejection fraction (LVEF) (**Video 1**). Coronary angiogram showed nonsignificant atherosclerotic plaques in the middle right coronary artery (**Figure 2B**) and the proximal left anterior descending artery (**Figure 2C**) (**Video 2, Video 3**). No endocoronary imaging was performed. Cardiac magnetic resonance showed a late gadolinium enhancement (**Figure 2D**) in the inferior LV wall. Thus, we suspected the diagnosis of myocardial infarction with nonobstructive coronary arteries. There were no other events. At this stage, the medical team was not sure of the relationship between the drugs administration and the occurrence of ACS, as well as a possible association with myocarditis. Therefore, the two drugs were stopped and a high dose of corticosteroids (methylprednisolone, 1g/day for 3 days and then prednisolone, 2mg/Kg/day and tapering over 6 weeks) in combination with dual antiplatelet therapy (aspirin plus clopidogrel) and statins was introduced. Angiotensin-converting enzyme inhibitors and beta-blockers could not be administered due to low blood pressure. Two weeks after this episode, troponin and NT-

proBNP levels decreased, and LVEF was 55%. A new injection of PD-L1<sub>i</sub> associated with prednisolone but without MEK<sub>i</sub> administration was decided after multidisciplinary discussion between cardiologists and oncologists and allowed by the trial sponsor. Twelve days later, the patient was readmitted suffering from dyspnea and fever attributed to left infectious pneumonia. Empiric antibiotic therapy was introduced despite a negative infection rate. During her stay, she was referred to the coronary care unit for a recurrence of chest pain associated with cardiogenic shock. The ECG showed new Q-waves and ST-segment elevation in the anterior leads (**Figure 2E**). The levels of troponin T and NT-proBNP were 1063ng/L and 22646ng/L, respectively. Echocardiography then showed severe LV dysfunction with 10% LVEF (**Video 4**). Coronary angiogram showed a thrombotic occlusion at the level where a nonsignificant lesion had been previously identified in the left anterior descending artery (**Figure 2F** and **Figure 2G**) (**Video 5**). It was treated by angioplasty and drug-eluting stent implantation. The patient died 16 days later from refractory shock, without ACS recurrence, despite inotropic pharmacological support, high doses of corticosteroids and antithymocyte globulin. Endomyocardial biopsy and autopsy could not be performed.

According to the ADR guidelines and the Naranjo scale, causality was considered as *certain* and *probable* (score=5) respectively. Recurrence after readministration represented a strong causality criterion.

### **Pharmacovigilance Database Analysis**

We identified 3 733 adverse events reported in patients who received ICIs and 820 571 adverse events reported in patients treated with any drugs (full database). Ten cases of coronary events associated with ICI were found. Among them, four had a coronary artery thrombosis on angiogram (**Figure 3A**). These cases were associated with nivolumab, a PD-1<sub>i</sub>. **Figure 3B**. Two patients died of this ACS. According to the ADR guidelines, causality of the



incriminated treatment was *probable* in the four patients. According to the Naranjo scale, the causality was *possible* (score=4) in three patients and *probable* (score=5) in one. Only one case of ACS was reported one month after initiation of the same MEK<sub>i</sub> in association with vemurafenib, a BRAF inhibitor with *unlikely-doubtful* causality according to the ADR guidelines and the Naranjo scale.

## DISCUSSION

We report for the first time a case of recurrent ACS following ICI administration, leading to a fatal outcome and *certain* ADR causality. This presentation strongly suggests an ICI-related coronary toxicity by destabilization of previous nonsignificant atherosclerotic lesions after analysis of coronary angiograms before and after ICI administration. Four other cases of ACS associated with ICI were found in the French pharmacovigilance database, further supporting this concept.

In the case we reported, after the first ACS episode we could not conclude that the ICI was the cause of the event because it was associated with a MEK<sub>i</sub> and the patient had risk factors. On the other hand, ACS recurrence after readministration of the ICI and discontinuation of the MEK<sub>i</sub> strongly suggested the involvement of the former. In our pharmacovigilance analysis, we found 10 other cases of suspected acute coronary events. In order to avoid including some cases of ICI-related myocarditis or pericarditis, we have only selected patients with an acute coronary artery thrombosis on angiogram.

The development of ACS from ICI has biological plausibility and was suggested by experts.<sup>6</sup> Immune checkpoint proteins play a pivotal role in atherosclerosis by regulating various immune cells and cytokines.<sup>11,12</sup> Nihms et al. showed that PD-1 inhibits the activation of proatherogenic T cells.<sup>13</sup> In experimental atherosclerosis of dyslipidemic mice (Ldlr<sup>-/-</sup>), complete genetic loss of the PD-1 receptor drives larger atherosclerotic lesions with more

abundant inflammatory cells, such as CD4+ and CD8+ T cells and macrophages, with more CD8+ cytotoxicity. Administering a PD-1-blocking antibody in Ldlr-/- mice significantly increases atherosclerotic lesion content of CD4+ and CD8+ T cells.<sup>13</sup> Moreover, activation of immune cells in atherosclerotic plaques induces IFN- $\gamma$  and TNF- $\alpha$  release that contributes to the destabilization of the lesions, potentially resulting in rupture of the lesion and causing ACS.<sup>11</sup> This possibility is also supported by the fact that the PD-1 and PD-L1 complex is expressed at lower levels on T cells in patients with coronary artery disease.<sup>14</sup> Another hypothetical mechanism is coronary vasculitis<sup>2,6</sup> but we do not have histologic evidence. Therefore, we hypothesize that in our case, inhibition of PD-1/PD-L1 pathway resulted in upregulation of proatherogenic T cell responses, leading to the rupture of a pre-existing coronary lesion. The four previously reported cases of ACS were with nivolumab. At this stage of knowledge, we cannot explain why no ACS cases were reported with pembrolizumab, another PD-1i. Moreover, no previous cases of ACS were reported with PD-L1i. This might be related to the recent use of this drugs and the relative fewer number of treated patients.

Our study had some limitations. First, data on coronary angiogram preceding ICI administration were lacking for other cases found in the analysis of the pharmacovigilance database. Nevertheless, the case described in this study is the only one for which we had previous angiogram, allowing us to strengthen our hypothesis. Moreover, the causality assessment according to the ADR guidelines was *certain*. Second, we cannot exclude the role of MEK inhibition in the coronary toxicity of the case we reported. However, only one ACS has been found in pharmacovigilance database with this drug and it had been stopped after the first ACS episode in our patient. Moreover, a recent meta-analysis showed that treatment with BRAF and MEK inhibitors was not associated with an increased risk of myocardial infarction.<sup>15</sup> Third, to support our hypothesis we analyzed only reported French cases.

However, the French Pharmacovigilance database is large and provides more details regarding the reported cases compared to the WHO's global database. This allowed selecting validated cases of ACS. Finally, in our case an immunosuppressive strategy was not effective and we cannot make specific recommendations for the treatment of ICI-related ACS.

**In conclusion,** this study suggests that ACS may be another life-threatening cardiac irAE occurring with ICIs exposure. In addition to myocarditis, this irAE should be suspected in case of cardiac symptoms/signs occurring during ICI therapy. A careful cardiac monitoring of ICI-treated patients with a high risk of ischemic heart disease might be useful.

## **ACKNOWLEDGMENTS**

None

## **FUNDING SOURCES**

This study received support from the Fédération Française de Cardiologie and Assistance Publique Hôpitaux de Marseille. The funding organizations had no role in the design and conduct of the study; collection, management, analysis, and interpretation of the data; preparation, review, or approval of the manuscript; and decision to submit the manuscript for publication.

## **DISCLOSURES**

Dr Cautela received modest consultant and lecture fees from Merck Sharp and Dohme, Novartis, Astra-Zeneca. Dr Thuny received modest personal fees for lectures and speakers bureaus from Novartis, Merck Sharp and Dohme, Bristol-Myers Squibb, Roche, Astra-Zeneca. Dr Barlesi received modest consultant fees from Bristol-Myers Squibb, Roche, Astra-Zeneca, Merck Sharp and Dohme. Dr Ederhy received modest consultant and lecture fees from Bristol-Myers Squibb, Novartis.

## REFERENCES

1. Wang DY, Salem JE, Cohen JV, et al. Fatal toxic effects associated with immune checkpoint inhibitors: a systematic review and meta-analysis. *JAMA Oncol* 2018;4:1721-28.
2. Salem JE, Manouchehri A, Moey M, et al. Cardiovascular toxicities associated with immune checkpoint inhibitors: an observational, retrospective, pharmacovigilance study. *Lancet Oncol* 2018;19:1579-89.
3. Mir H, Alhussein M, Alrashidi S, et al. Cardiac complications associated with checkpoint inhibition: a systematic review of the literature in an important emerging area. *Can J Cardiol* 2018;34:1059-68.
4. Escudier M, Cautela J, Malissen N, et al. Clinical features, management, and outcomes of immune checkpoint inhibitor-related cardiotoxicity. *Circulation*.2017;136:2085-87.
5. Johnson DB, Balko JM, Compton ML, et al. Fulminant myocarditis with combination immune checkpoint blockade. *N Engl J Med* 2016;375:1749-55.
6. Lyon AR, Yousaf N, Battisti NML, Moslehi J, Larkin J. Immune checkpoint inhibitors and cardiovascular toxicity. *Lancet Oncol* 2018;19:e447-e458.
7. Ferreira M, Pichon E, Carmier D, et al. Coronary toxicities of anti-PD-1 and anti-PD-L1 immunotherapies: a case report and review of the literature and international registries. *Target Oncol* 2018;13:509-515.
8. Tomita Y, Sueta D, Kakiuchi Y et al. Acute coronary syndrome as a possible immune-related adverse event in a lung cancer patient achieving a complete response to anti-PD-1 immune checkpoint antibody. *Ann Oncol* 2017;28:2893-95.
9. Edwards IR, Aronson JK. Adverse drug reactions: definitions, diagnosis, and management. *Lancet* 2000;356:1255-9.
10. Naranjo CA, Busto U, Sellers EM, et al. A method for estimating the probability of adverse drug reactions. *Clin Pharmacol Ther* 1981;30:239-45.

11. Foks AC, Kuiper J. Immune checkpoint proteins: exploring their therapeutic potential to regulate atherosclerosis. *Br J Pharmacol* 2017;174:3940-55.
12. Zhao TX, Mallat Z. Targeting the immune system in atherosclerosis: JACC state-of-the-art review. *J Am Coll Cardiol* 2019;73:1691-1706.
13. Bu DX, Tarrío M, Maganto-García E, et al. Impairment of the programmed cell death-1 pathway increases atherosclerotic lesion development and inflammation. *Arterioscler Thromb Vasc Biol* 2011;31:1100-7.
14. Lee J, Zhuang Y, Wei X, et al. Contributions of PD-1/PD-L1 pathway to interactions of myeloid DCs with T cells in atherosclerosis. *J Mol Cell Cardiol* 2009;46:169-76.
15. Mincu RI, Mahabadi AA, Michel L, et al. Cardiovascular adverse events associated with BRAF and MEK inhibitors: a systematic review and meta-analysis. *JAMA Netw Open* 2019;2:e198890.

## FIGURE LEGENDS

### **Figure 1. Sequence and events with the main imaging findings and therapeutics in a cancer patient treated with ICI**

ACS: acute coronary syndrome; D: day; inj.: injection; LVEF: left ventricular ejection fraction; MRI: magnetic resonance imaging; Mo: months

### **Figure 2. Recurrent acute coronary syndrome after a PD-L1 checkpoint inhibitor administration in a 52-year-old woman with lung cancer.**

Five days after the first administration, she presented recurrent acute chest pain. A. ECG: Q-wave in the inferior leads. B. Coronary angiography: nonsignificant atherosclerotic plaques in the right coronary artery (arrow). C. Coronary angiography: nonsignificant atherosclerotic plaques in the left anterior descending artery (arrow). D. Cardiac magnetic resonance with PSIR-FLASH sequence: late gadolinium enhancement in the mid inferoseptal and inferior left ventricle wall (arrow). After readministration, she was referred for a recurrent ACS and a cardiogenic shock. E. ECG: ST-segment elevation and new Q-waves in the anteroseptal leads. F. Coronary angiography: unchanged nonsignificant atherosclerotic plaques in the right coronary artery. G. Coronary angiography: thrombotic occlusion at the level where a nonsignificant lesion had been previously identified in the left anterior descending artery (arrow).

### **Figure 3. Pharmacovigilance Analysis Flow Chart (A) and Characteristics of Patients with Suspected ICI- Related Acute Coronary Syndrome with Evidence of Coronary Artery Thrombosis from the French Pharmacovigilance Database (B).**

ADR: adverse drug reactions; M: male; ACS: acute coronary syndrome; F: female; ICI: immune checkpoint inhibitor; STEMI: ST elevation myocardial infarction

## **ONLINE-ONLY SUPPLEMENTS AND MULTIMEDIA**

**Supplementary Table S1. Causality assessment of suspected adverse drug reactions according to Edwards IA, et al.<sup>9</sup>**

**Supplementary Table S2. Naranjo adverse drug reaction probability scale: Items and score are adapted from Naranjo CA, et al.<sup>10</sup>**

**Video 1. Echocardiography performed during the first ACS episode showing left ventricle inferior wall akinesia, with a 45% LV ejection fraction.**

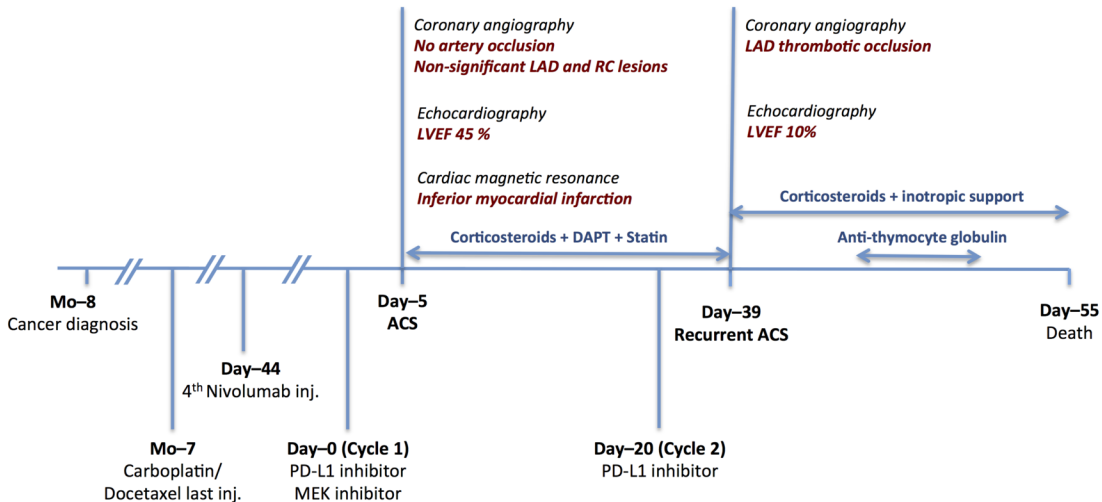
**Video 2. Coronary angiogram showed nonsignificant atherosclerotic plaques in the middle right coronary artery.**

**Video 3. Coronary angiogram during the first ACS episode showing nonsignificant atherosclerotic plaques in the proximal left anterior descending artery.**

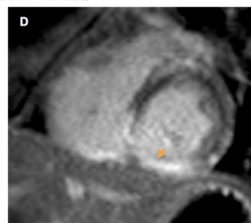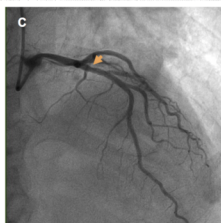
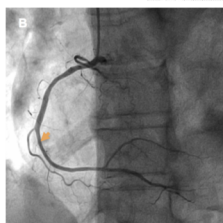
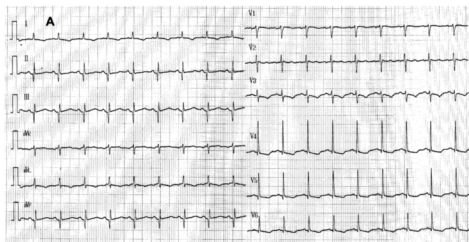
**Video 4. Echocardiography performed during the second ACS episode showing severe left ventricular dysfunction.**

**Video 5. Coronary angiogram during the second ACS episode showing a thrombotic occlusion at the level where a nonsignificant lesion had been previously identified in the left anterior descending artery.**

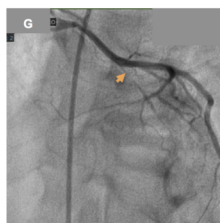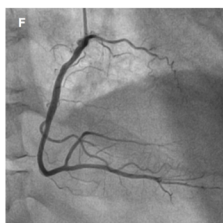
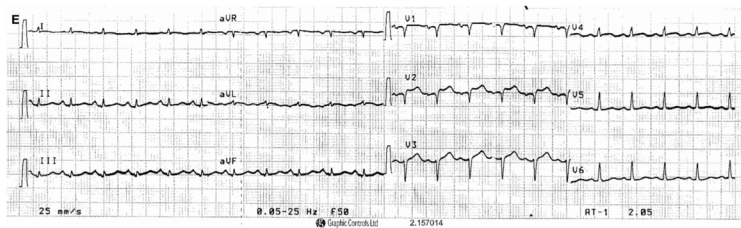





# ACS after first administration of PD-L1 inhibitor



# Recurrent ACS after readministration



**A**



**B**

Patient	Age (y)	Sex	Cardiovascular Risk Factors and Diseases	Cancer	ICI	Toxicity	Number of Injections before Toxicity	Clinical Signs Symptoms	Other Associated Cancer Drugs	Coronary Angiogram	ICI Management	ADR Guidelines Classification	Naranjo Scale
1	74	M	Hypertension, diabetes	Lung cancer	Nivolumab	STEMI	2	Asystole	None	Significant thrombotic lesion on circumflex artery	- (death)	Probable	5 (Probable)
2	75	M	Stroke	Hodgkin lymphoma	Nivolumab	STEMI	9	Chest pain	None	Thrombotic occlusion of proximal right artery	Pursuit No recurrence	Probable	4 (Possible)
3	80	M	Hypertension, active smoker, ischemic heart disease	Lung cancer	Nivolumab	STEMI	16	Chest pain	None	Thrombotic occlusion of proximal circumflex artery	Interruption	Probable	4 (Possible)
4	68	F	Diabetes, ischemic heart disease	Metastatic melanoma	Nivolumab	STEMI	2	Chest pain	Ipilimumab	Thrombotic occlusion of left descending and circumflex arteries	- (death)	Probable	4 (Possible)