



HAL
open science

Clinical Communications Symmetrical drug-related intertriginous and flexural exanthema: A little-known drug allergy

Tullia De Risi-Pugliese, Héloïse Barailler, Aurore Hamelin, Emmanuelle Amsler, Hafida Gaouar, Flore Kurihara, Marie Laure Jullie, Eric Dean Merrill, Annick Barbaud, Philippe Moguelet, et al.

► To cite this version:

Tullia De Risi-Pugliese, Héloïse Barailler, Aurore Hamelin, Emmanuelle Amsler, Hafida Gaouar, et al.. Clinical Communications Symmetrical drug-related intertriginous and flexural exanthema: A little-known drug allergy. *Journal of Allergy and Clinical Immunology: In Practice*, 2020, 8 (9), pp.3185-3189.e4. 10.1016/j.jaip.2020.04.052 . hal-02995700

HAL Id: hal-02995700

<https://hal.sorbonne-universite.fr/hal-02995700v1>

Submitted on 9 Nov 2020

HAL is a multi-disciplinary open access archive for the deposit and dissemination of scientific research documents, whether they are published or not. The documents may come from teaching and research institutions in France or abroad, or from public or private research centers.

L'archive ouverte pluridisciplinaire **HAL**, est destinée au dépôt et à la diffusion de documents scientifiques de niveau recherche, publiés ou non, émanant des établissements d'enseignement et de recherche français ou étrangers, des laboratoires publics ou privés.

Symmetrical drug-related intertriginous and flexural exanthema: A little-known drug allergy



Tullia de Risi-Pugliese, MD^{a,b}, Héloïse Barailler, MD^c,
Aurore Hamelin, MD^a, Emmanuelle Amsler, MD^{a,b},
Hafida Gaouar, MD^a, Flore Kurihara, MD^{a,b},
Marie Laure Jullie, MD^d, Eric Dean Merrill, MD^e,
Annick Barbaud, MD, PhD^{a,b}, Philippe Moguelet, MD^f,
Brigitte Milpied-Homsi, MD^b, and
Angèle Soria, MD, PhD^{a,b,g}

Clinical Implications

- Symmetrical drug-related intertriginous and flexural exanthema is a flexural eruption that occurs within a few days of drug exposure. Antibiotics and iodinated contrast agents are the most frequent triggers. Skin testing has low sensitivity. Rechallenge identifies the culprit drug without serious manifestations.

The symmetrical drug-related intertriginous and flexural exanthema (SDRIFE) is a delayed flexural exanthema induced by a systemic drug without previous cutaneous sensitization, typically presenting as “a sharply defined symmetrical erythema of the gluteal area and in the flexural or intertriginous folds without systemic symptoms and signs.”¹ SDRIFE clinically resembles Baboon syndrome (BS); however, in BS, patients develop the exanthem after systemic exposure to an allergen to which they have been previously topically sensitized.²

We retrospectively reviewed records from 2 French dermatology departments between 2006 and 2018 for adults with SDRIFE as defined by Häusermann et al¹: (1) exposure to systemically administered drug either following the first or subsequent dose, (2) sharply demarcated erythema of the gluteal and/or inguinal area, (3) involvement of at least 1 other flexural localization, (4) symmetry of affected area, and (5) absence of systemic symptoms and signs. Twelve patients were excluded because of previous topical sensitization to the allergen (BS, n = 2), diffuse maculopapular rash (MPR) with flexural reinforcement (n = 7), other causes of flexural rash, for example, acute generalized exanthematous pustulosis (AGEP), toxic erythema due to chemotherapy (TEC) based on clinical and histological findings (n = 2), and flexural erythema thought to be drug-induced but without relapse after reexposure (n = 1). Patch tests (PTs) (IQ ultrachambers, Chemotechnique Diagnostics, Vellinge, Sweden), skin prick tests (SPTs), and intradermal tests (IDTs) with delayed readings were performed following European guidelines³ (Table 1). We further reviewed all published cases of SDRIFE since Häusermann et al's publication (2004-2018).

Eighteen patients were included, 10 females and 8 males, with mean and median ages of 57 years (range, 33-83 years). Erythematous patches or plaques affecting a mean of 5 (range,

2-7) large or small skin folds (especially inguinal, gluteal, axillary, and mammary) (Figure 1, Table 1) were observed. Four patients had localized skin vesicles or bullae and 1 (no. 16) had mucosal involvement. The eruption occurred shortly after drug exposure (median, 22 hours; mean, 34; range, 0.5-120). The causative drug was discontinued immediately in all patients, 10 were treated with topical steroids, and resolution of lesions was observed within a median of 4 days (mean, 6.2; range, 1-18). Lymphopenia was found in 6 of 12 patients (50%; range, 350-1400/mm³), not explained by a distinct underlying condition.

The most frequent histological pattern, found in 5 of 11 patients who had a skin biopsy, was subepidermal edema with a polymorphous perivascular and interstitial infiltrate of neutrophils, eosinophils, and lymphocytes in the upper dermis. Four patients had a spongiotic and/or lichenoid pattern on skin biopsy and 2 had a nonspecific scant lymphocytic superficial perivascular infiltrate. There was no obvious relationship between histology and the clinical presentation and severity of the rash or timing of skin biopsy.

The suspected drug was an antibiotic in 10 of 18 cases (56%), including amoxicillin ± clavulanate in 4 (22%), a iodinated contrast agent (ICA) in 5 of 18 (28%), an analgesic in 2 of 18, and fluconazole in 1 of 18 (Table 1). Fourteen patients had PT, 12 had SPT, and 11 IDT with delayed readings. Testing was performed within 1 month to 9 years of the original reaction, and most patients (13 of 16) were tested within 1 year of the reaction. Positive skin test results were obtained only in 5 patients, all with antibiotics: PT in 3 of 14 cases (21%); 1 with amoxicillin-clavulanate and 2 with pristinamycin; IDT in 2 of 11 cases (18%) with amoxicillin ± clavulanate. Skin test results remained negative in patient number 2 who also had a SDRIFE due to amoxicillin confirmed by rechallenge test (RT). Results of all skin tests performed with ICAs (PT n = 3, SPT and IDT n = 5) were negative. The result of RT with the suspected causative drug, performed in 9 patients with negative skin test results, was always positive, without severe cutaneous or systemic manifestations. There was no obvious relationship between clinical presentation and positivity of skin test results. The median time for SDRIFE recurrence after reexposure to the drug (induced by RT [n = 9] or skin tests [n = 1]) was 12 hours (mean, 15 hours; range 2.5-30), shorter than during the first episode.

SDRIFE is thought to involve a type IV delayed-hypersensitivity immune response, because it occurs within a few hours to a few days after drug exposure, and there is evidence for a T-cell-mediated reaction,^{1,4} though the precise pathophysiology is not known. Antibiotics are common triggering agents in the literature (60% in Häusermann et al's¹ review, 33% in our literature review [2004-2018], n = 51 [see Tables E1 and E2 in this article's Online Repository at www.jaci-inpractice.org]), especially beta-lactams (55% in Häusermann et al's review and 23% in our review), but only 5 cases of SDRIFE due to ICAs were reported.⁵ In previously published cases, skin test results were positive more frequently than in our study, 40% of PTs, 11% of SPTs, and 70% of IDTs, for various drugs (antibiotics and others), possibly due to a publication bias. Different methods for identifying the culprit drug might be necessary in SDRIFE. Skin testing on affected sites is one option; however,

TABLE I. Clinical, biological, and allergological findings

No.	Sex, age (y)	No. of occurrences	Delay between first drug intake and eruption (h)	Eruption aspects				Biological investigations
				Lesions type	No. of affected skin folds	Affected skin folds	Other affected site(s)	
1	F, 70	1	20	Erythema	2	Inguinal, gluteal	Back (mild erythema)	NA
2	M, 38	2	8	Erythema	3	Inguinal, axillary, neck	Back	CBC: ND, electrolytes, creatininemia, liver enzymes, CRP: N
3	M, 83	≥2	48	Maculopapular erythema	2	Inguinal, gluteal	0	CBC: lymphopenia 1,110/mm ³ (N > 1,500), electrolytes: N, creatininemia: 642 μmol/L [†] , liver enzymes: N, CRP: 65 mg/L [†]
4	F, 49	2	24	Maculopapular erythemaedema ++vesicles after second RT	6	Inguinal, gluteal, axillary, neck, mammary, abdominal	0	CBC: mild neutropenia 1,390/mm ³ , electrolytes, creatininemia, CRP: N, liver enzymes: GGT 248, ALT 52 (N < 32), GGT 52 (N < 32), ALP N, HSV, CMV, EBV PCR: –
5	F, 50	2	30	Maculopapular erythema	4	Inguinal, popliteal, mammary, interdigital	0	CBC: aggravation of former lymphopenia 600/mm ³ , electrolytes: N, creatininemia, liver enzymes: N, CRP: 37 mg/L, HSV1+2, EBV, CMV, HHV6 PCR: –
6	M, 81	2	20	Maculopapular erythema	4	Inguinal, axillary, antecubital fossae, interdigital	0	CBC: lymphopenia 1,020/mm ³ , electrolytes, creatininemia: N, liver enzymes: GGT 248, AST 39, ALT 50, ALP 112 (N < 35) [†] , CRP: N, HSV1+2, EBV, CMV, HHV6 PCR: –
7	M, 68	3	96	Erosive maculopapular erythema	4	Inguinal, gluteal, axillary, mammary	Outer arms, upper chest	CBC, electrolytes, creatininemia, liver enzymes: N, HSV 1+2, CMV, HHV6 A+B PCR: –, EBV PCR: 3.96 log, 9,038 U/mL
8	F, 33	2	10	Erythema	5	Inguinal, gluteal, axillary, mammary, antecubital fossae	Lumbar region	CBC: lymphopenia 1,210/mm ³ , electrolytes, creatininemia, liver enzymes, CRP: N
9	M, 77	2	12	Erythema	7	Inguinal, gluteal, popliteal, antecubital fossae, neck, mammary, abdominal	0	CBC: lymphopenia 720/mm ³ , electrolytes, creatininemia, liver enzymes, CRP: N, HSV1+2, CMV, EBV PCR: –
10	M, 36	1	6	Macular erythema, vesicles	5	Inguinal, axillary, antecubital fossae, interdigital, wrists	Dorsum of feet	CBC: lymphopenia 1,120/mm ³ , electrolytes, creatininemia, liver enzymes: N, CRP 35 mg/L [†]
11	M, 65	2	0.5	Macular erythema	4	Inguinal, axillary, abdominal, interdigital	0	CBC: lymphopenia 1,430/mm ³ [†] , electrolytes, creatininemia N, liver enzymes: ALT 127 (N < 43 U/L), ALP 74 (N < 35 U/L) [†] , CRP: N
12	F, 59	1	24	Maculopapular erythema (+2 bullae left hand)	6	Inguinal, gluteal, axillary, popliteal, neck, wrists	Dorsum of hands	NA
13	F, 38	≥2	12	Erythema	6	Inguinal, gluteal, axillary, neck, mammary, abdominal	0	NA
14	F, 55	1	96	Erythema	7	Inguinal, gluteal, axillary, popliteal, antecubital fossae, neck, abdominal	Anterior thighs and legs	NA
15	F, 72	1	48	Erythema with purpuric lesions	6	Inguinal, gluteal, axillary, antecubital fossae, mammary, abdominal	Inner arms, sides	CBC: elevated PMN 15,830/mm ³ (N < 8,000) [†] , lymphopenia 350/mm ³ [†] , electrolytes, creatininemia, liver enzymes: N, CRP: 74.2 [†] mg/L
16	F, 43	1	24	Macular erythema, vesicles	7	Inguinal, gluteal, axillary, mammary, abdominal, interdigital, nasolabial	Vesicles of the soft palate	CBC: hyperleucocytosis 13,000/mm ³ [†] , electrolytes, creatininemia: N, liver enzymes: ALT 50 U/L, AST 29 U/L, ALP 67 U/L [†] , CRP: 100 mg/L [†]
17	M, 69	1	12	Erythema, secondarily bleeding erosions and scaling	5	Inguinal, gluteal, axillary, neck, interdigital	Feet	CBC: elevated PMN 11,670/mm ³ [†] , electrolytes, creatininemia, liver enzymes: N, CRP: 156 mg/L [†]
18	F, 41	1	120	Erythema	5	Inguinal, gluteal, axillary, mammary	0	NA

ALP, Alkaline phosphatase; ALT, aspartate aminotransferase; AMOX, amoxicillin; AMOX-CLAV, amoxicillin-clavulanate; AST, alanine aminotransferase; CBC, complete blood cell count; Chem, Chemotechnique; CLINDA, clindamycin; CMV, cytomegalovirus; CRP, C-reactive protein; CS, corticosteroid; EBV, Epstein-Barr virus; F, female; GGT, gamma-glutamyl transferase; HI, antihistaminic H1; HHV6, human herpesvirus 6; HSV, herpes simplex virus; M, male; N, normal; NA, data not available; ND, not done; PB19, parvovirus B19; PCR, polymerase chain reaction; PMN, polymorphonuclear neutrophil; PRIST, pristinamycin; +, positive; –, negative; RT+, recurrence of SDRIFE; RT–, no recurrence of SDRIFE; SULFTX, sulfamethoxazole; TS, topical steroid.

Note: For patient numbers 9 and 13: RTs were performed with alternative β-lactams (ceftriaxone, cefpodoxime) after confirmed hypersensitivity to amoxicillin ± clavulanate, and results were negative.

*Most drug PTs were performed using commercialized preparations (Chemotechnique Diagnostic, Vellinge, Sweden). If not available, the hospital pharmacy freshly prepared the drug PT at nonirritant concentrations as previously recommended in the literature.

[†]Abnormally former to the SDRIFE, explained by underlying condition (eg, infection).

[‡]Abnormally possibly explained by underlying condition, or by the SDRIFE (unknown).

TABLE I. Continued

Treatment	Time to healing (d)	Suspected drugs	Skin tests				RT result and delay for SDRIFE recurrence (h)	Drug confirmed by tests or rechallenge
			PTs*	Prick tests	IDTs			
TS	NA	PRIST	PRIST (Chem) –	PRIST –	ND	PRIST (1 g) +, <24, with erythematous reaction on site of previous SPT	PRIST	
TS	NA	AMOX	AMOX (Chem): –	AMOX, cefpodoxim, ceftriaxone (undiluted): –	AMOX, ceftriaxone (diluted to 10 ⁻¹): –	AMOX (1 g) +, 12	AMOX	
TS	15	Oxycodone, oxycodone chloryhydrate	ND	ND	ND	ND	–	
TS	NA	Iodixanol	Iodixanol, iomeprol, iohexol, ioxitalamate (undiluted): –	Iodixanol, iomeprol, iohexol, ioxitalamate (undiluted): –	Iodixanol, iomeprol, iohexol, ioxitalamate (diluted to 10 ⁻¹): –	Iodixanol (50 mL) +, 2.5 Iomeprol (50 mL): +, 2.5 (cross-reactivity)	Iodixanol	
TS	4	Ioversol (3 episodes with Ioversol)	Ioversol, iohexol, iomeprol, iodixanol ioxitalamate, iobitridol (undiluted): –	Ioversol, iohexol, iomeprol, iodixanol ioxitalamate, iobitridol (undiluted): –	Ioversol, iohexol, iomeprol, iodixanol ioxitalamate, iobitridol (diluted to 10 ⁻¹): –	Iomeprol (50 mL) +, 24 (cross-reactivity) Iodixanol (50 mL) +, 24 (cross-reactivity) Iobitridol (50 mL): –	ICAs (group A)	
TS	2	Iomeprol	ND	Iomeprol, iobitridol, iodixanol (undiluted): –	Iomeprol, iobitridol, Iodixanol (diluted to 10 ⁻¹): –	Iomeprol (50 mL) +, 12 Iobitridol (50 mL) –	Iomeprol	
TS	NA	Iomeprol (for both episodes) + ibuprofene, lamaline (first episode), terbinafine (second episode)	ND	Iomeprol, iodixanol, iohexol, iompromide (undiluted): –	Iomeprol, iodixanol, iohexol, iompromide (diluted to 10 ⁻¹): –	Iomeprol (50 mL) +, 24	Iomeprol	
NA	3	CLINDA, nefopam, oxytocin, esomeprazole, ketoprofen, levobupicaine, sufentanil, tranexamic acid	CLINDA (Chem): – nefopam, oxytocin, esomeprazol, eketoprofen, levobupicain, esufentanil, tranexamic acid (30% in water): –	CLINDA (Chem), nefopam, oxytocin, esomeprazole, ketoprofen, levobupicaine, sufentanil, tranexamic acid (undiluted): –	CLINDA, nefopam, oxytocin, esomeprazole, ketoprofen, levobupicaine, sufentanil, tranexamic acid (diluted to 10 ⁻¹): –	CLINDA (300 mg) +, 3	CLINDA	
NA	10	AMOX	AMOX (Chem): –	AMOX, ceftriaxone, cefpodoxime (undiluted): –	AMOX (diluted to 10 ⁻¹): + with SDRIFE recurrence 30 h after IDT; ceftriaxone (diluted to 10 ⁻¹): –	Ceftriaxone (1 g), – Cefpodoxime (100 mg): –	AMOX	
TS	4	Paracetamol, tramadol	ND	ND	ND	ND	–	
TS, HI	1	Ioxaglate	Ioxaglate, iodixanol, iomeprol, iopamidol, iopromide (undiluted): –	Ioxaglate, iodixanol, iomeprol, iopamidol, iopromide (undiluted): –	Ioxaglate iodixanol, iomeprol, iopamidol, iopromide (diluted to 10 ⁻¹): –	Ioxaglate 50 mL +, 6 Iodixanol –	Ioxaglate	
TS	5	SULFTX	SULFTX (Chem): –	SULFTX (undiluted): –	SULFTX (diluted to 10 ⁻¹): –/–	ND	–	
HI	2	AMOX-CLAV	AMOX (Chem): –	AMOX-CLAV, ceftriaxone, cefpodoxime (undiluted): –	AMOX-CLAV (diluted to 10 ⁻¹): – and + when retested after positive RT result Ceftriaxone (diluted to 10 ⁻¹): –	AMOX-CLAV (1 g): +, 12 Ceftriaxone (1 g): – Cefpodoxime (100 mg): –	AMOX-CLAV	
NA	NA	AMOX-CLAV, ofloxacin, tramadol	AMOX-CLAV (30% pet.): +, ofloxacin: –	ND	ND	ND	AMOX-CLAV	
HI	18	PRIST	PRIST (10% pet.): + Pristinamycin (30% water): –	ND	ND	ND	PRIST	
TS	28	Vancomycin	Vancomycin (30% pet., 30% water): –	Vancomycin (undiluted): –	Vancomycin (diluted to 10 ⁻³): irritative at 20 min, – at D2	ND	–	
	35	PRIST, ofloxacin	PRIST (10% pet.): +, PRIST (30% water): +, erythromycin, spiramycin, clarithromycin, norfloxacin, ciprofloxacin, acetaminophen (10% pet.): –	ND	ND	ND	PRIST	
NA	42	Fluconazole	Fluconazole (30% pet.), econazole cream (undiluted): –	ND	ND	ND	–	

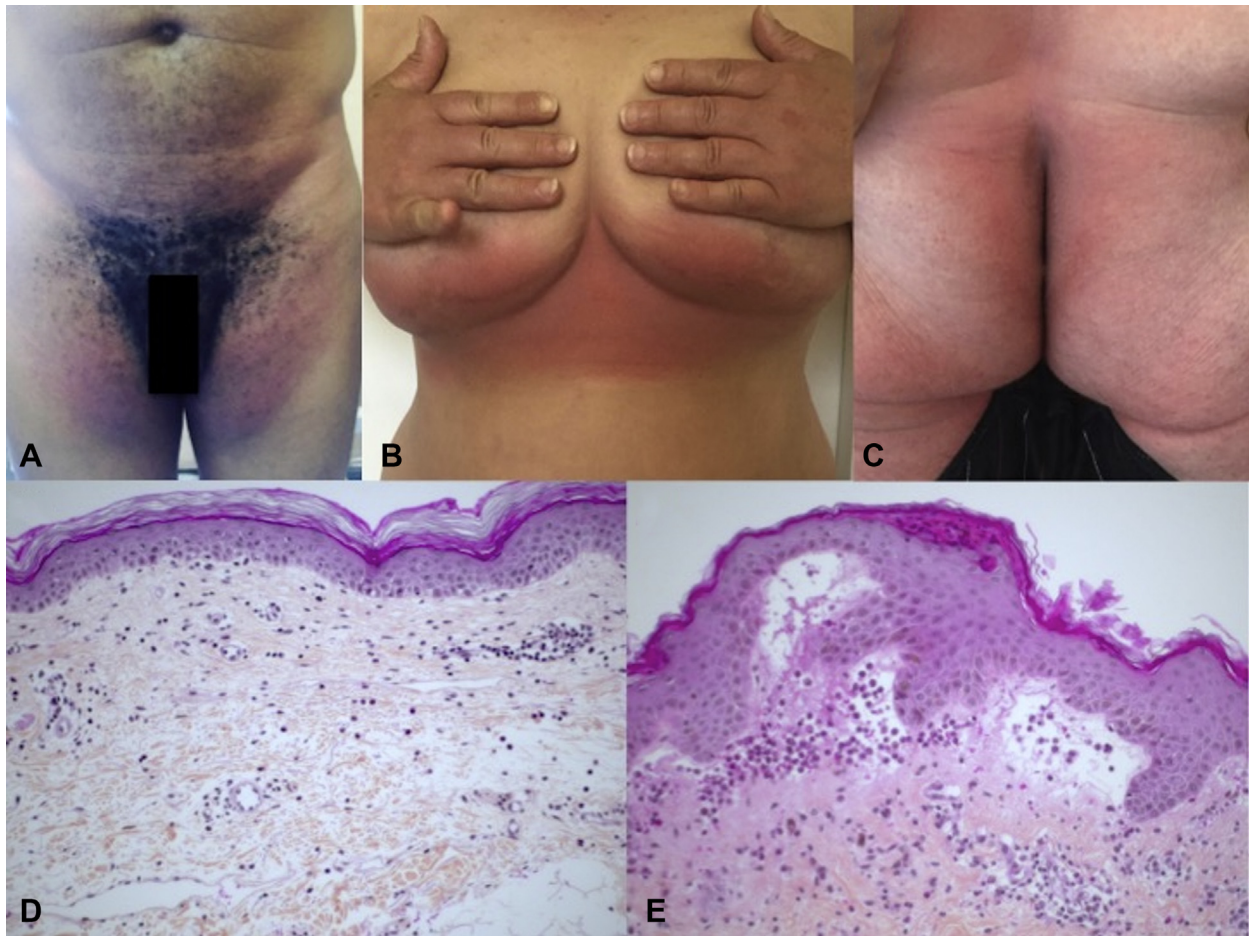


FIGURE 1. SDRIFE. (A-C) Clinical aspects. Maculopapular, sharply demarcated erythema of the (A) inguinal (patient no. 10), (B) mammary (patient no. 5), and (C) gluteal folds (patient no. 9). (D and E) Histology on skin biopsy (most frequently found pattern). Subepidermal edema, perivascular and interstitial infiltrate of neutrophils, eosinophils, and lymphocytes in the upper dermis with minimal leucocytoclasia (patient nos. 4 and 10).

site-specific skin testing with PT and/or IDT has been negative in 3 cases to date.^{4,6,7} Thus, RT, result for which was positive in 9 of 9 cases in our study and 13 of 13 in our literature review (2004-2018), appears to be the most reliable way to identify the culprit drug, without serious manifestations during recurrence.

SDRIFE is a syndrome characterized by a drug-induced flexural eruption, but it cannot be clearly defined on the basis of histology and skin testing. We observed that using Häusermann et al's 5 diagnostic criteria may have led to misdiagnosis: we excluded 2 patients who fulfilled these criteria but where alternate diagnoses of TEC in one case and TEC with features of AGEP in the other were better fits. Typical SDRIFE occurring within a few days after drug exposure can be clinically diagnosed. However, in patients with pustules, bullae, erosions, and atypical chronology, or in patients receiving chemotherapy, a skin biopsy should be performed to rule out another diagnosis. Moreover, the well-demarcated erythema of the folds is an important clinical aspect for diagnosis, to distinguish an MPR that can have flexural reinforcement. Taken together, we suggest the addition of a sixth criterion: (6) exclusion of another cause of flexural eruption (including AGEP, TEC, psoriasis,

fixed drug eruption, MPR with flexural reinforcement, systemic contact dermatitis), with skin biopsy in cases with an atypical clinical presentation.

^aAP-HP, Service de Dermatologie et Allergologie, Hôpital Tenon, Paris, France

^bSorbonne Université, UPMC University, Paris, France

^cService de Dermatologie, Hôpital Saint André, Bordeaux, France

^dService d'Anatomopathologie, Hôpital Haut Lévêque, Bordeaux, France

^eDepartment of Dermatology, University of California San Francisco, San Francisco, Calif

^fAP-HP, Service d'Anatomopathologie, Hôpital Tenon, Paris, France

^gInserm 1135, Centre d'Immunologie et des Maladies Infectieuses (Cimi-Paris), Paris, France

Conflicts of interest: The authors declare that they have no relevant conflicts of interest.

Received for publication August 23, 2019; revised April 8, 2020; accepted for publication April 21, 2020.

Available online May 4, 2020.

Corresponding author: Tullia de Risi-Pugliese, MD, Service de Dermatologie et Allergologie, Hôpital Tenon, 4 rue de la Chine, 75020 Paris, France. E-mail: tullia.derisi@gmail.com.

2213-2198

© 2020 American Academy of Allergy, Asthma & Immunology

<https://doi.org/10.1016/j.jaip.2020.04.052>

REFERENCES

1. Häusermann P, Harr T, Bircher AJ. Baboon syndrome resulting from systemic drugs: is there strife between SDRIFE and allergic contact dermatitis syndrome? *Contact Dermatitis* 2004;51:297-310.
2. Miyahara A, Kawashima H, Okubo Y, Hoshika A. A new proposal for a clinical-oriented subclassification of baboon syndrome and a review of baboon syndrome. *Asian Pac J Allergy Immunol* 2011;29:150-60.
3. Barbaud A, Gonçalo M, Bruynzeel D, Bircher A, European Society of Contact Dermatitis. Guidelines for performing skin tests with drugs in the investigation of cutaneous adverse drug reactions. *Contact Dermatitis* 2001; 45:321-8.
4. Barbaud A, Tréchet P, Granel F, Lonchamp P, Faure G, Schmutz JL, et al. A baboon syndrome induced by intravenous human immunoglobulins: report of a case and immunological analysis. *Dermatol Basel Switz* 1999;199:258-60.
5. Tasker F, Fleming H, McNeill G, Creamer D, Walsh S. Contrast media and cutaneous reactions, part 2: delayed hypersensitivity reactions to iodinated contrast media. *Clin Exp Dermatol* 2019;44:844-60.
6. Ozkaya E, Babuna G. A challenging case: symmetrical drug related intertriginous and flexural exanthem, fixed drug eruption, or both? *Pediatr Dermatol* 2011;28:711-4.
7. Ferreira O, Mota A, Morais P, Cunha AP, Azevedo F. Symmetrical drug-related intertriginous and flexural exanthema (SDRIFE) induced by telmisartan-hydrochlorothiazide. *Cutan Ocul Toxicol* 2010;29:293-5.

ONLINE REPOSITORY

TABLE E1. Comparison between present study, literature review, and the Häusermann et al^{E1} review (2004)

	n	Age (y), mean (median)	Sex: M/F, n	Delay between first drug intake and eruption (h), median (mean)	Culprit drug, n (%)						Allergological workup, n (%)			
					ATB, n (%)	β-Lactam	Amoxicillin	Iodinated contrast media	Chemotherapy or immunotherapy	Others	Positive PT/PT performed	Positive SPT/SPT performed	Positive IDT/IDT performed	Positive RT/RT performed
Häusermann et al, ^{E1} 2004 (review + original cases)	40+2	48 (55)	30/12	48 (72)	25 (60)	22 (52)	14 (33)	0 (0)	3 (12)	14 (64)	12 of 24 (50)	2 of 10 (20)	3 of 5 (60)	4 of 4 (100)
Literature review (2004-2018)	51	46 (53)	27/24	48 (285)	17 (33)	10 (20)	5 (10)	5 (10)	2 (4)	27 (53)*	7 of 24 (29)†	0 of 8 (0)	4 of 5 (80)‡	13 of 13 (100)
Present study	18	57 (57)	10/8	22 (34)	10 (56)	4 (22)	4 (22)	5 (28)	0 (0)	2 (11)	3 of 14 (21)	0 of 12 (0)	2 of 11 (18)	9 of 9 (100)

F, Female; M, male.

*Other drugs included itraconazole, thiamine disulphide, golimumab, terbinafine, zoledronic acid, etoricoxib, everolimus, codeine, infliximab, paracetamol, ranitidine, coix lacryma jobi, celecoxib, hydroxyzine, omeprazole, etonorgestrel, clozapine, rivastigmine, telmisartan-hydrochlorothiazide, risperidone, valacyclovir, palifermin (keratinocyte growth factor), prednisolone, and methylprednisolone.

†Positive PT result obtained with clarithromycin, etoricoxib, clindamycin, hydroxyzine, etonorgestrel, and Iomeprol prednisolone.

‡Positive IDT result obtained with bortezomib, clindamycin, iomeprol, and methylprednisolone.

TABLE E2. Published cases of SDRIFE (literature review 2004-2018): Culprit drug and results of allergological workup

Reference (first author, year)	No. of cases	Culprit drug	Allergological workup
Fischbach, ^{E2} 2018	1	Ceftriaxone/daptomycine/clindamycin	—
Karagöl, ^{E3} 2018	1	Ampicillin-sulbactam IV	—
Li, ^{E4} 2017	1	Doxycycline	—
Mohapatra, ^{E5} 2017	1	Itraconazole	PT: Negative
Moreira, ^{E6} 2017	1	Clarithromycin	PT: Positive
Magnolo, ^{E7} 2017	1	Cefuroxime	—
Hattori, ^{E8} 2017	1	Thiamine disulfide	PT: Negative SPT: Negative RT: Positive
Yang, ^{E9} 2017	1	Golimumab	—
Janjua, ^{E10} 2017	1	Terbinafine	PT: Negative
Cohen, ^{E11} 2016	1	Zoledronic acid	—
Lora, ^{E12} 2016	1	Ceftazidime	—
Caralli, ^{E13} 2016	1	Etoricoxib	PT: Positive RT: Positive
Malissen, ^{E14} 2016	1	Bortezomib	IDT: Positive
Kurtman, ^{E15} 2016	1	Everolimus	—
Karadag, ^{E16} 2016	1	Amoxicilline	PT: Negative
Huynh, ^{E17} 2015	3	ICA	—
		ICA	—
		ICA	—
Morales-Cabeza, ^{E18} 2015	1	Clindamycin	PT: Positive IDT: Positive
Erfan, ^{E19} 2015	1	Codeine	PT: Negative SPT: Negative RT: Positive
Bulur, ^{E20} 2015	1	Infliximab	RT: Positive
Obara, ^{E21} 2014	1	Paracetamol = acetaminophen	PT: Negative RT: Positive
Binitha, ^{E22} 2014	1	Ranitidine	PT: Negative
Sikar Akturk, ^{E23} 2014	1	Metronidazole	—
Choi, ^{E24} 2014	1	Coix lacryma jobi	—
Can, ^{E25} 2014	1	Cefixime and clarithromycin	PT: Negative
Kim, ^{E26} 2014	1	Celecoxib	PT: Negative RT: Positive
Blackmur, ^{E27} 2013	1	Benzyl penicillin	—
Akkari, ^{E28} 2013	1	Hydroxyzine	PT: Positive RT: Positive
Lee, ^{E29} 2013	1	Piperacillin/tazobactam/phenytoin	—
Culav, ^{E30} 2013	1	Sulfamethoxazole-trimethoprim	PT: Negative SPT: Negative
Lugovic-Mihic, ^{E31} 2013	1	Paracetamol	—
Dogru, ^{E32} 2012	1	Amoxicillin-clavulanate	PT: Negative SPT: Negative
Kardaun, ^{E33} 2012	2	Omeprazole	PT: Negative
		Omeprazole	—
Peeters, ^{E34} 2012	1	Nuvaring: etonorgestrel	PT: Positive
Rao, ^{E35} 2012	2	Clozapine	—
		Clozapine	—
Ozkaya, ^{E36} 2011	1	Amoxicillin	PT: Negative RT: Positive
Allain-Veyrac, ^{E37} 2011	1	Rivastigmine	—
Chong, ^{E38} 2010	1	Cloxacillin	—
Ferreira, ^{E39} 2010	1	Telmisartan-hydrochlorothiazide	PT: Negative
Elmariah, ^{E40} 2009	1	CR011-vcMMAE experimental mAb-Auristatin E conjugate	RT: Positive

(continued)

TABLE E2. (Continued)

Reference (first author, year)	No. of cases	Culprit drug	Allergological workup
Akay, ^{E41} 2009	1	Risperidone	PT: Negative RT: Positive
Thierman, ^{E42} 2009	1	ICA	—
Daito, ^{E43} 2009	1	Valacyclovir	PT: Negative RT: Positive
Handisurya, ^{E44} 2009	1	Amoxicillin/sulbactam	PT: Negative SPT: Negative IDT: Negative RT: Positive
Diaz Ley, ^{E45} 2008	1	Palifermin (keratinocyte growth factor)	—
Dhingra, ^{E46} 2007	1	Cefadroxil/paracétamol/cough-mixture for acute respiratory infection	—
Arnold, ^{E47} 2007	1	Iomeprol	PT: Positive SPT: Negative IDT: Positive RT: Positive
Treudler, ^{E48} 2006	1	Prednisolone	PT: Positive SPT: Negative

REFERENCES

- E1. Häusermann P, Harr T, Bircher AJ. Baboon syndrome resulting from systemic drugs: is there strife between SDRIFE and allergic contact dermatitis syndrome? *Contact Dermatitis* 2004;51:297-310.
- E2. Fischbach S, Hall N, Bains S, Selvaraj V. An unusual case of worsening cellulitis: baboon syndrome or SDRIFE. *BMJ Case Rep* 2018;2018:bcr2018224503.
- E3. Karagöl C, Ceran A, Güngör A, Akman AÖ, Misirlioğlu ED. Baboon syndrome associated with ampicillin sulbactam. *J Allergy Clin Immunol Pract* 2018;6:2106-7.
- E4. Li DG, Thomas C, Weintraub GS, Mostaghimi A. Symmetrical drug-related intertriginous and flexural exanthema induced by doxycycline. *Cureus* 2017;9:e1836.
- E5. Mohapatra M, Panda M, Kar BR, Raj C. Symmetric drug-related intertriginous and flexural exanthema due to itraconazole: an uncommon side effect of a commonly used drug. *Indian Dermatol Online J* 2017;8:501-3.
- E6. Moreira C, Cruz MJ, Cunha AP, Azevedo F. Symmetrical drug-related intertriginous and flexural exanthema induced by clarithromycin. *An Bras Dermatol* 2017;92:587-8.
- E7. Magnolo N, Metzke D, Ständer S. Pustulobullöse Variante eines SDRIFE (symmetrical drug-related intertriginous and flexural exanthema). *J Dtsch Dermatol Ges J Ger Soc Dermatol JDDG* 2017;15:657-9.
- E8. Hattori Y, Matsuyama K, Shu E, Kanoh H, Seishima M. Symmetrical drug-related intertriginous and flexural exanthema possibly due to thiamine disulfide. *J Dermatol* 2017;44:e115-6.
- E9. Yang S-Y, Lan C-C, Hu SC-S. Symmetrical drug-related intertriginous and flexural exanthema (SDRIFE) induced by golimumab. *Int J Dermatol* 2017;56:571-2.
- E10. Janjua SA, Pastar Z, Iftikhar N, Ammad S. Intertriginous eruption induced by terbinafine: a review of baboon syndrome. *Int J Dermatol* 2017;56:100-3.
- E11. Cohen PR. Zoledronic acid-associated symmetrical drug-related intertriginous and flexural exanthema (SDRIFE): report of baboon syndrome in a woman with recurrent metastatic breast cancer after receiving zoledronic acid. *Dermatol Online* 2015;21:13030.
- E12. Lora V, Capitanio B, Cota C. A symmetrical flexural rash. *Pediatr Dermatol* 2016;33:345-6.
- E13. Caralli ME, Seoane Rodríguez M, Rojas Pérez-Ezquerria P, Pelta Fernández R, De Barrio Fernández M. Symmetrical drug-related intertriginous and flexural exanthema (SDRIFE) caused by etoricoxib. *J Investig Allergol Clin Immunol* 2016;26:128-9.
- E14. Malissen N, Bourrain J-L, Chiriac A, Vincent L, Dereure O, Du-Thanh A, et al. Symmetrical intertriginous and flexural exanthema due to bortezomib (a proteasome inhibitor) given for myeloma. *Acta Derm Venereol* 2016;96:995-6.
- E15. Kurtzman DJB, Oulton J, Erickson C, Curriel-Lewandrowski C. Everolimus-induced symmetrical drug-related intertriginous and flexural exanthema (SDRIFE). *Dermat Contact Atopic Occup Drug* 2016;27:76-7.
- E16. Karadag AS, Ozlu E, Akdeniz N, Uzuncakmak TK, Turkoglu Z, Ozkanli S, et al. Oral mucosal involvement and petechial lesions: a SDRIFE case with unusual findings. *Cutan Ocul Toxicol* 2016;35:157-9.
- E17. Huynh T, Hughey LC, McKay K, Carney C, Sami N. Systemic drug-related intertriginous and flexural exanthema from radio contrast media: A series of 3 cases. *JAAD Case Rep* 2015;1:147-9.
- E18. Morales-Cabeza C, Caralli Bonetti ME, Micozzi S, Seoane Rodríguez M, Rojas-Pérez-Ezquerria P, de Barrio Fernández M. SDRIFE-like reaction induced by an intradermal skin test with clindamycin: A case report. *J Allergy Clin Immunol Pract* 2015;3:976-7.
- E19. Erfan G, Yanik ME, Kaya S, Oznur M, Kulac M. Symmetrical drug-related intertriginous and flexural exanthema due to codeine. *Indian J Dermatol Venereol Leprol* 2015;81:405-6.
- E20. Bulur I, Keseroglu HO, Saracoglu ZN, Gönül M. Symmetrical drug-related intertriginous and flexural exanthema (baboon syndrome) associated with infliximab. *J Dermatol Case Rep* 2015;9:12-4.
- E21. Obara K, Maejima H, Katayama C, Takasu H, Amoh Y. A case of symmetrical drug related intertriginous and flexural exanthema induced by acetaminophen. *J Dermatol* 2014;41:1132-3.
- E22. Biniha MP, Sasidharanpillai S, John R, Sherjeena PVB. Symmetrical drug-related intertriginous and flexural exanthema due to ranitidine. *Indian J Pharmacol* 2014;46:551-2.
- E23. Şikar Aktürk A, Bayramgürler D, Salman S, Yıldız KD, Odyakmaz Demirsoy E. Symmetrical drug-related intertriginous and flexural exanthema (SDRIFE) induced by oral metronidazole. *Cutan Ocul Toxicol* 2014;33:337-8.
- E24. Choi MJ, Oh SH, Cho SB. Coix lacryma-jobi associated symmetrical drug-related intertriginous and flexural exanthema. *Int J Dermatol* 2014;53:e301-3.
- E25. Can C, Yazicioglu M, Ozdemir PG, Kilavuz S4, Tastekin E. Symmetrical drug-related intertriginous and flexural exanthema induced by two different antibiotics. *Allergol Immunopathol (Madr)* 2014;42:173-5.
- E26. Kim BJ, Kim HS, Lee JY, Kim HO, Park YM, La HO. Symmetrical drug-related intertriginous and flexural exanthema caused by celecoxib. *Int J Dermatol* 2014;53:e1-3.
- E27. Blackmur JP, Lammy S, Baring DEC. Baboon syndrome: an unusual complication arising from antibiotic treatment of tonsillitis and review of the literature. *BMJ Case Rep* 2013;2013:bcr2013201977.
- E28. Akkari H, Belhadjali H, Youssef M, Mokni S, Zili J. Baboon syndrome induced by hydroxyzine. *Indian J Dermatol* 2013;58:244.
- E29. Lee HY, Philippidou M, Schey S, Selway R, Walsh S, Creamer D. Flexural eruption in two hospitalized patients. *Clin Exp Dermatol* 2013;38:943-5.
- E30. Culav I, Ljubojevic S, Buzina DS. Baboon syndrome/SDRIFE due to sulfamethoxazole-trimethoprim. *Int J Dermatol* 2013;52:1159-60.
- E31. Lugović-Mihic L, Duvančić T, Vučić M, Situm M, Kolić M, Mihic J. SDRIFE (baboon syndrome) due to paracetamol: case report. *Acta Dermatovenerol Croat ADC* 2013;21:113-7.
- E32. Dogru M, Ozmen S, Ginis T, Duman H, Bostanci I. Symmetrical drug-related intertriginous and flexural exanthema (baboon syndrome) induced by amoxicillin-clavulanate. *Pediatr Dermatol* 2012;29:770-1.
- E33. Kardaun SH, Tupker RA. Symmetrical drug-related intertriginous and flexural exanthema (baboon syndrome) induced by omeprazole. *Int J Dermatol* 2012;51:1134-7.
- E34. Peeters D, Baeck M, Dewulf V, Tennstedt D, Dachelet C. A case of SDRIFE induced by Nuvaring®. *Contact Dermatitis* 2012;66:110-1.
- E35. Rao A, Francis N, Morar N. Clozapine-induced symmetrical drug-related intertriginous and flexural exanthema: first reported cases. *Br J Dermatol* 2012;166:1142-3.
- E36. Ozkaya E, Babuna G. A challenging case: symmetrical drug related intertriginous and flexural exanthema, fixed drug eruption, or both? *Pediatr Dermatol* 2011;28:711-4.
- E37. Allain-Veyrac G, Lebreton A, Collonnier C, Jolliet P. First case of symmetric drug-related intertriginous and flexural exanthema (sdrife) due to rivastigmine? *Am J Clin Dermatol* 2011;12:210-3.
- E38. Chong W-S, Lim H-LJ. Symmetrical drug-related intertriginous and flexural exanthema (baboon syndrome) with fever induced by oral cloxacillin: does fever confound the diagnosis? *J Dermatol* 2010;37:830-2.
- E39. Ferreira O, Mota A, Moraes P, Cunha AP, Azevedo F. Symmetrical drug-related intertriginous and flexural exanthema (SDRIFE) induced by telmisartan-hydrochlorothiazide. *Cutan Ocul Toxicol* 2010;29:293-5.
- E40. Elmariah SB, Cheung W, Wang N, Kamino H, Pomeranz MK. Systemic drug-related intertriginous and flexural exanthema (SDRIFE). *Dermatol Online J* 2009;15:3.
- E41. Akay BN, Sanli H. Symmetrical drug-related intertriginous and flexural exanthema due to oral risperidone. *Pediatr Dermatol* 2009;26:214-6.
- E42. Thierman S, Chinthraja RS. Symmetrical drug-related intertriginous and flexural exanthema after coronary artery angiography. *J Hosp Med* 2009;4:203.
- E43. Daito J, Hanada K, Katoh N, Katoh S, Sakamoto K, Asai J, et al. Symmetrical drug-related intertriginous and flexural exanthema caused by valacyclovir. *Dermatol Basel Switz* 2009;218:60-2.
- E44. Handisurya A, Stingl G, Wöhrl S. SDRIFE (baboon syndrome) induced by penicillin. *Clin Exp Dermatol* 2009;34:355-7.
- E45. Diaz Ley B, Guhl G, Eguren Michelen C, Fernandez Herrera J, Fraga J, Garcia Diez A. Flexural cutaneous eruption due to palifermin. *Br J Haematol* 2008;140:464-5.
- E46. Dhingra B, Grover C. Baboon syndrome. *Indian Pediatr* 2007;44:937.
- E47. Arnold AW, Hausermann P, Bach S, Bircher AJ. Recurrent flexural exanthema (SDRIFE or baboon syndrome) after administration of two different iodinated radio contrast media. *Dermatol Basel Switz* 2007;214:89-93.
- E48. Treudler R, Simon JC. Symmetric, drug-related, intertriginous, and flexural exanthema in a patient with polyvalent intolerance to corticosteroids. *J Allergy Clin Immunol* 2006;118:965-7.