

Case report of nutritional rickets in an infant following a vegan diet

Nutritional rickets and a vegan diet

A. Lemoine, E. Giabicani, V. Lockhart, E. Grimprel, P. Tounian

Authors names and affiliations:

A. LEMOINE ^a, MD

E. GIABICANI ^b, MD, PhD

V. LOCKHART ^b, MD

E. GRIMPREL ^c, MD, PhD

P. TOUNIAN ^a, MD, PhD

^a Paediatric Nutrition and Gastroenterology Department, Trousseau Hospital-APHP, Sorbonne Université, Paris, France

^b Sorbonne Université, INSERM, Centre de Recherche Saint Antoine, APHP, Hôpital Armand Trousseau, Explorations Fonctionnelles Endocriniennes, F-75012, Paris, France.

^c Department of Paediatrics, Trousseau Hospital-APHP; Sorbonne Université, Paris, France

Full Address: 26 avenue du Dr Arnold Netter, 75012 Paris, France

Author emails:

anais.lemoine@aphp.fr

egiabicani@protonmail.com

veronique.lockhart@ap-hm.fr

emmanuel.grimprel@aphp.fr

p.tounian@aphp.fr

Corresponding author: anais.lemoine@aphp.fr

Declaration of interest: No conflicts of interest related to this work

Authorship:

A. Lemoine analysed and interpreted the data and drafted the article.

E. Giabicani, V. Lockhart, E. Grimprel and P. Tounian revised the article and gave the final approval of the version to be submitted.

Abstract:

We report the case of a 13-month-old infant, who was referred to paediatric emergencies because of psychomotor regression with four bone fractures due to nutritional rickets. The reason was prolonged breastfeeding from a vegetarian mother followed by a vegan diet after weaning.

Rickets is one of the many nutritional deficiencies which could affect infants fed vegan or vegetarian diets.

These diets are a public health concern requiring adapted information that suggests alternative formulas made from rice or soy proteins and adapted supplementation after weaning.

Key words:

vegan; vegetarian; rickets; nutritional deficiency; fracture

Introduction

Nutritional rickets due to low calcium intake and/or vitamin D deficiency was a common disease in Europe until the mid-20th century [1]. Vitamin D enrichment of infant formulas and systematic supplementation during pregnancy and infancy significantly decrease the occurrence of this disease. Currently, affected children are more likely to be dark-skinned, receive limited exposure to sunshine on their skin, lack recommended daily supplementation, and/or be exclusively breastfed for a long period by mothers who have had low calcium intake and/or poor vitamin D status during pregnancy (not receiving the recommended supplementation during the third trimester of gestation [1,2]).

Vegetarian diets exclude all types of meats, fish, shellfish and crustaceans, but in lacto-ovo vegetarian diets, dairy products, eggs and honey are tolerated. Vegan diets avoid all animal products such as meat, fish, shellfish, insects, dairy, eggs and honey. A macrobiotic diet is a vegan diet where only cereals, pulses, vegetables, seaweed, soy, and occasionally fish are consumed. Meats, dairy products, eggs and some vegetables are usually avoided. The number of infants following these alternative dietary patterns has dramatically increased during the last decades [3,4]. This is becoming a real public health concern since vegetarian and vegan diets can induce many nutritional deficiencies in infants including iron, calcium, vitamins D and B12, docosahexaenoic acid (DHA), zinc and proteins [3,4]. Nutritional deficiencies are more frequent and severe in young infants fed a non-dairy drink made with almonds, chestnuts, rice or soya [4].

In this article, we describe a 13-month-old infant following a vegan diet who developed rickets and bone fractures.

Case report

A 13-month-old Eurasian infant was referred to paediatric emergencies for a 1-month psychomotor regression and apathy.

He had no significant neonatal antecedent with a term eutrophic birth at home. He was seen by a paediatrician on day 12, and then missed all check-ups, including vaccinations, until the age of 12 months when his parents became worried about a decrease in appetite and weight loss that had begun at 10 months of age. These symptoms were associated with psychomotor regression since he crawled at 8 months, took a few steps at 10 months, and struggled to hold the position and did not get up anymore at 11 months.

His weight was at -2.7 SD (standard deviation), his height at -1.4 SD, the Waterlow index was 78% and the cranial circumference at -1.0 SD. The study of growth velocity was not possible because of the lack of check-ups in his health record. His adipose panniculus was thin, and he was apathetic, but there was no abdominal bloating. A widening of the wrists was clearly visible, as well as a bilateral costal rosary. There was no pain when limbs were palpated, and limbs were not deformed or unequal in length. Sitting was difficult without support and hypotonia was observed. There was a delayed eruption of teeth: at 13 months of age, the child only had the primary teeth 71 and 81. The rest of the clinical examination, including exploration of cardio-respiratory and ganglionic areas, revealed no additional anomalies.

He was exclusively breastfed up to the age of 7 or 8 months, when complementary feeding was introduced consisting of a vegan diet that included rice flour, fruits, vegetables, legumes, oatmeal, algae powders, black sesame and almonds on the advice of the Asian-born maternal family with the addition of a spoonful of olive, peanut and fish oils twice a day, but without

any pharmaceutical vitamin D supplementation. Before hospitalization, the retrospective estimation of energy intake was about 950 kcal/d. The mother was following a vegetarian diet herself, without meat or fish, but with a few dairy products and eggs. The parents had many beliefs and misconceptions about food and thought that they should limit the amount of animal products (meat, fish, eggs and dairy products) in their child's diet.

An initial blood test revealed a normal calcium level (2.21 mmol/L; N: 2.1-2.6) and hypophosphatemia (0.64 mmol/L; N: 1.3-1.8) with elevated alkaline phosphatase (ALP) (1066 IU/L; N<35). There was a vitamin D deficiency (25-hydroxy-cholecalciferol: 22.6 nmol/L; normal values (N): 75-250), and a secondary hyperparathyroidism (21.2 pmol/l; N: 0.8-5.2). A urinary analysis performed before vitamin D supplementation but after calcium enriched diet showed a urinary calcium/creatinine ratio of 0.62 mmol/mmol. At that time, phosphate reabsorption rate was lowered at 44% and C terminal Fibroblast Growth Factor 23 (FGF-23) was normal (165 RU/ml). The rest of the nutritional assessment showed deficiencies in vitamins A, B6 and C, but normal levels of vitamins B1, B9, B12 and E. Anaemia, probably due to Glucose 6 Phosphate Dehydrogenase deficiency, existed since ferritinemia was normal. Albumin was normal, with decreased prealbumin (0.110 g/L). Celiac serology was negative and thyroid function was normal.

Bone X-rays revealed diffuse osteopenia with bone hypertransparency and fine cortical, consolidated left ulnar and bilateral peroneal diaphyseal fractures, enlargement, cupping, splaying, fraying and a coarse trabecular pattern in the metaphysis, with widening of the growth plate (Figures 1, 2), and an enlargement of the anterior costochondral joints (Figure 3).

The case pointed to calcium and vitamin D deficiency rickets, with no basis for hereditary rickets or other risk factors to develop rickets apart from his diet.

This infant was supplemented with vitamin D (100,000 IU per month for 3 months) and calcium (500 mg/day for 15 days). Because of severe rickets with fractures, malnutrition and absence of medical check-ups, this child had been initially separated from his parents and placed in a tertiary care unit. After discussion with the parents, a diversified diet was started with the introduction of infant formula containing cow's milk proteins, and animal proteins with close medical check-ups.

Subsequently, the child's general condition quickly improved, with a gradual recovery of sitting and standing within 1 month, then walking abilities within 3 months. Phosphoremia corrected, then vitamin D levels, and finally ALP. A recovery in weight began gradually over time (Figures 4), in parallel with a spontaneous increase in energy intake up to 1100 kcal/day. Moreover, regarding vaccination, parents agreed to participate in the catch-up vaccination program and to provide him with an omnivore diet. A few months later, the child was able to rejoin his family at home and is now developing well. His growth has caught up to normal rates and he is regularly taken to medical check-ups.

Discussion

This case report describes deficient rickets due to parental ignorance of their child's dietary needs, associated with psychomotor regression and four peripheral fractures. Unfortunately, this infant was not reached by existing prevention measures because of a home birth, refusal of a neonatal screening on blotting paper, and lack of medical check-ups.

Rickets in children is prevented by a vitamin D load in the pregnant woman in the seventh month of pregnancy, and by a systematic supplementation from birth to the age of 12-18 months [5]. All countries in Europe have established this policy for supplementation in infancy and childhood, but in 5 out of 29 countries, this supplementation only involves breastfed infants [5]. In the majority of European countries (24/28), the information given concerning the value of vitamin D supplementation is provided in maternity wards [5]. In our case, because of the home birth and lack of check-ups, such information could not be given. In case of nutritional rickets, consensus recommends a minimum dose of 2000 IU/day of vitamin D2 or D3 or a single large dose of vitamin D3, preferably by oral route rather than intramuscular, for a minimum of 3 months in conjunction with oral calcium, 500 mg/day, either through dietary intake or supplement [6].

In addition to the vitamin D deficiency, the quantity and quality of calcium consumption are important. Despite the fact that nuts such as almonds, leafy vegetables and pulses are high in calcium, the bioavailability of this source of calcium is negatively correlated to the amounts of oxalate and phytate [7]. That is why one must consume tofu or mineral water fortified with calcium in the absence of dairy products [8]. The milk of breastfeeding women who are vegetarian or follow a macrobiotic diet is usually rich enough in calcium due to maternal bone demineralization and higher PTH, driving to an increase of 1,25-dihydroxy vitamin D conversion enhancing calcium absorption [7,8].

Rickets affects up to 55% of infants following a macrobiotic diet [9] but it is not the only disease that could affect vegetarian or vegan children due to lack of nutrients [8]. When the child is exclusively or partially breastfed, nutritional deficiencies could occur too, depending on the quality of the vegetarian or vegan mother's supplementation. Several European

societies of nutrition and/or paediatrics do not recommend a vegan diet in children or say it is possible only when dietary and medical treatments are provided [7,10]. It is therefore necessary to provide advice to parents who want a vegan diet for their children, offering them alternatives in order to avoid potentially irreversible consequences. Nowadays, it is obvious that non-dairy drinks are inappropriate for infants [4]. Hydrolysed rice protein-based formulas are the best alternative to respect family choice of vegetarian or vegan diet. Soy formulas can also be suggested but they have now been supplanted in many countries by rice formulas.

Concerning growth, the birthweight of babies born to women on a macrobiotic diet are lower than expected, unlike to those of vegan or vegetarian women [7]. During breastfeeding, the milk of vegetarian mothers is usually nutritionally adapted, and the growth of infants is normal during the first 6 months of life. This is not the case for mothers on a macrobiotic diet because of a significantly lower protein content than omnivore mothers [7]. When breastfeeding occurs for longer than 6 months for infants of vegetarian mothers, the growth rate reaches the lower end of normal [7].

Vitamin B12 deficiency in breastfed children is more frequent when mothers are on a lacto-ovo vegetarian diet than on omnivore diet [7]. There is a good correlation between vitamin B12 levels in breast milk and serum concentrations in infants [8]. In most cases, the discovery of a vitamin B12 deficiency in a breastfed infant is due to a vegetarian diet in the mothers [7]. Vitamin B12 deficiency results in anaemia and neuro-developmental delay in the first year of life [8]. In non-breastfed vegetarian children, rice or soy-based infant formula contains enough vitamin B12 to prevent the deficiency [8]. In our case, the infant did not have a vitamin B12-deficiency because his mother ate some eggs and fish during pregnancy and breastfeeding.

Iron levels in the milk of lacto-ovo vegetarian and vegan women are identical to non-vegetarian women and therefore, there is no difference in the incidence of iron deficiency anaemia during weaning [7]. During infancy, macrobiotic children are often affected by iron deficiency [7].

Because the main sources of eicosapentaenoic acid (EPA) and docosahexaenoic acid (DHA) are seafood products, breast milk from vegetarian women is poorer in DHA than omnivorous women [7,8]. To prevent these deficiencies, recommendations are to consume DHA-enriched rice-based infant formula, add omega-3 rich vegetable oils (colza, walnut, soy) to savoury meals, and/or to eat algae [8].

From a practical point of view, in front of vegan parents who want a vegan diet for their child, you should encourage them to breastfeed or give them a rice-based formula and/or a soy-based formula after the age of 6 months, and ideally up to at least 6 years of age. After diversification onset, supplementation in calcium could be needed, according to the consumption of infant formula and other calcium intakes (mineral water, calcium-rich vegetables). Vitamin D supplementation is the same for vegan infant as for other children up to 18 months of age, and should be continued after the age of 18 months. For iron, a supplementation could be required if the systematic serum ferritin dosage is low, when the consumption of plant-based formula decreases. And when the child is no longer consuming rice or soy-based formulas, vitamin B12 supplementation must be systematic. A supplementation in DHA is recommended from the age of one with omega-3-rich vegetable oils (rapeseed, walnut, soybean) and/or with algae-based supplements [8]. In any cases, a close follow-up with a paediatrician trained in nutrition is recommended.

Conclusion

Vegetarian and vegan diets in infants and children have become a public health concern in many European countries [3]. They lead to severe nutritional deficiencies which could irreversibly damage neurologic development or bone mineralization, especially in young infants. Paediatricians must campaign for information to be provided about health risks associated with these alternative diets.

References

- [1] Uday S, Högler W. Nutritional Rickets and Osteomalacia in the Twenty-first Century: Revised Concepts, Public Health, and Prevention Strategies. *Curr Osteoporos Rep* 2017;15:293–302.
- [2] Prentice A. Nutritional rickets around the world. *J Steroid Biochem Mol Biol* 2013;136:201–6.
- [3] Ferrara P, Corsello G, Quattrocchi E, Dell’aquila L, Ehrich J, Giardino I, et al. Caring for Infants and Children Following Alternative Dietary Patterns. *J Pediatr* 2017;8:339–40.
- [4] Lemale J, Salaun J, Assathiany R, Garcette K, Peretti N, Tounian P. Replacing breastmilk or infant formula with a nondairy drink in infants exposes them to severe nutritional complications. *Acta Paediatr* 2018;107:1828–9.
- [5] Uday S, Kongjonaj A, Aguiar M, Tulchinsky T, Högler W. Variations in infant and childhood vitamin D supplementation programmes across Europe and factors influencing adherence. *Endocr Connect* 2017;6:667–75.
- [6] Munns CF, Shaw N, Kiely M, Specker BL, Thacher TD, Ozono K, et al. Global Consensus Recommendations on Prevention and Management of Nutritional Rickets. *J Clin Endocrinol Metab* 2016;101:394–415.
- [7] Agnoli C, Baroni L, Bertini I, Ciappellano S, Fabbri A, Papa M, et al. Position paper on vegetarian diets from the working group of the Italian Society of Human Nutrition. *Nutr Metab Cardiovasc Dis* 2017;27:1037–52.
- [8] Lemale J, Mas E, Jung C, Bellaiche M, Tounian P. Vegan diet in children and adolescents. Recommendations from the French-speaking Pediatric Hepatology, Gastroenterology and Nutrition Group (GFHGNP). *Arch Pediatr* 2019;26:442–50.
- [9] Dagnelie PC, Vergote FJ, van Staveren WA, van den Berg H, Dingjan PG, Hautvast JG. High prevalence of rickets in infants on macrobiotic diets. *Am J Clin Nutr* 1990;51:202–8.
- [10] Fewtrell M, Bronsky J, Campoy C, Domellöf M, Embleton N, Mis NF, et al.

Complementary feeding: A position paper by the European Society for Paediatric Gastroenterology, Hepatology, and Nutrition (ESPGHAN) committee on nutrition. *J Pediatr Gastroenterol Nutr* 2017;64:119–32.

Legends

Figure 1: right arm X-ray

enlargement of the wrist, cupping, splaying and fraying of humerus and ulna-radius metaphysis, widened growth plates (a)

consolidated diaphyseal ulna fracture (b)

diffuse osteopenia

Figure 2: right leg X-ray

cupping, splaying and fraying of metaphysis, widened growth plates (a)

diaphyseal peroneal fracture with continuous periosteal appositions and rough of bony callus (b)

diffuse osteopenia

Figure 3: chest and abdomen X-ray

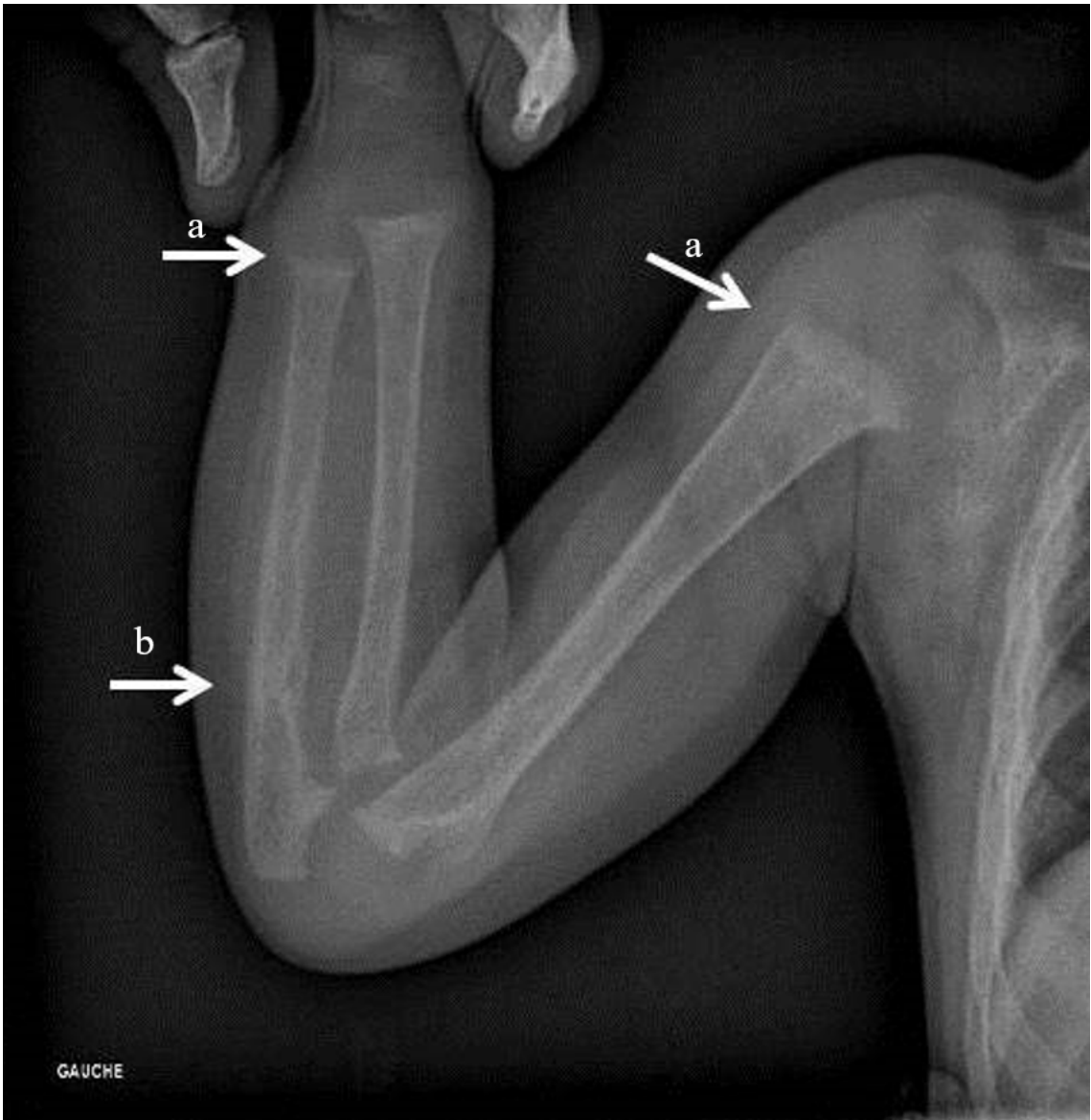enlargement of anterior costochondral junctions (c)

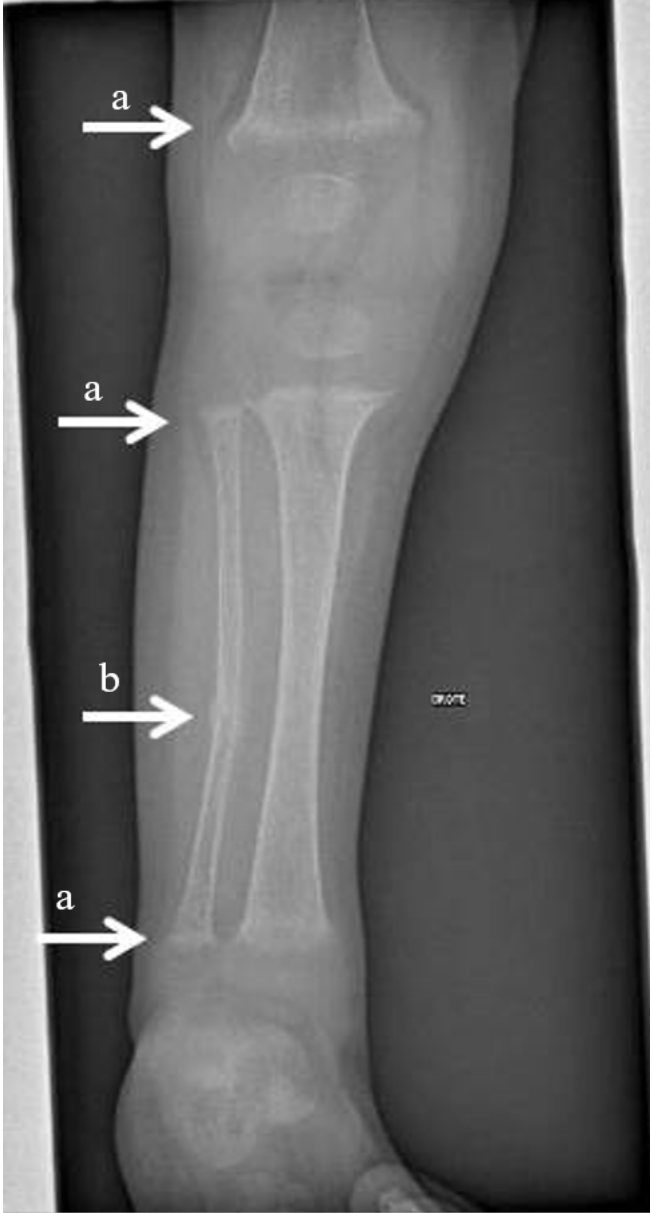scapula hypertransparency

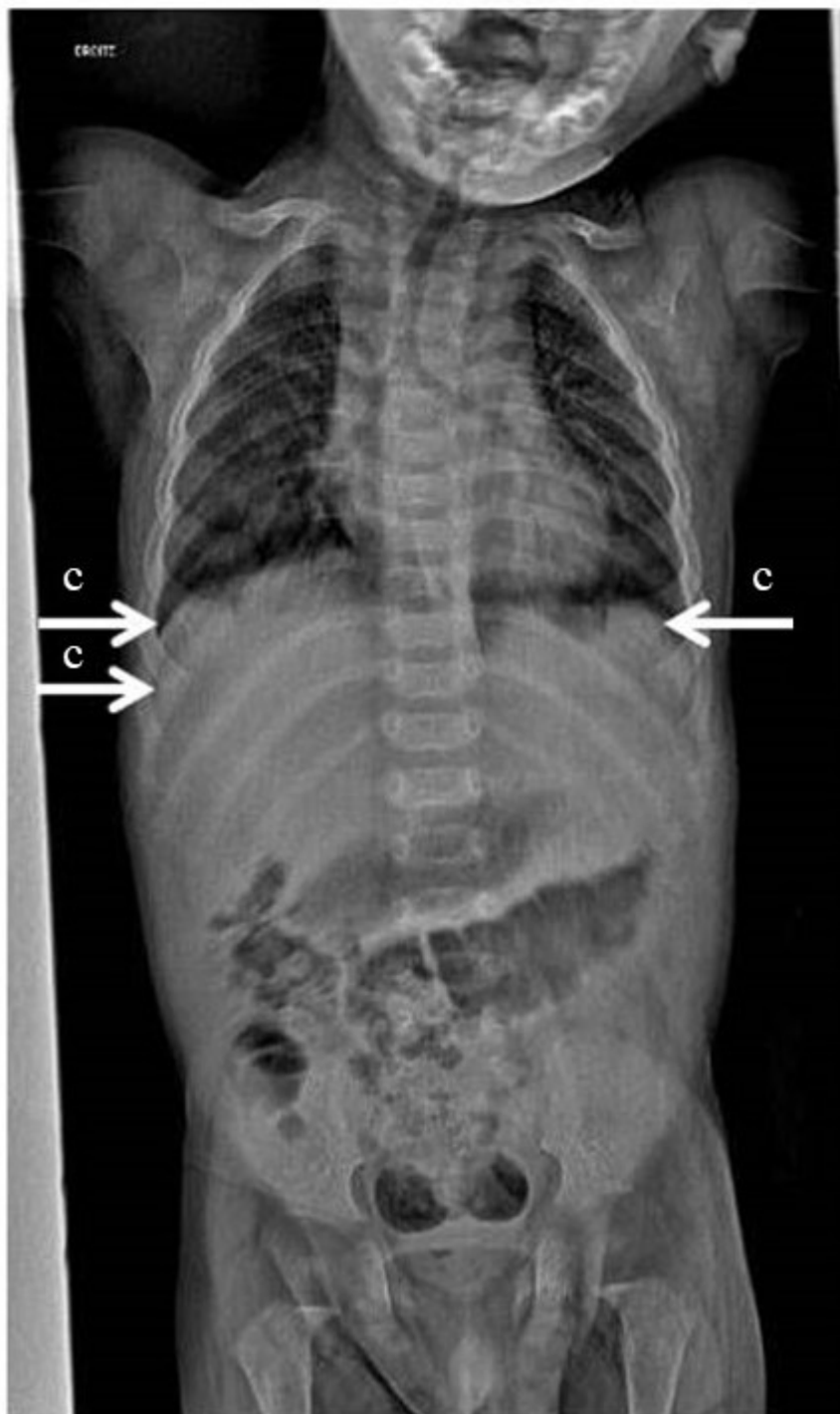Figure 4a and 4b: Weight, length and head circumference charts.

No data from 12 days to 13 months. Omnivore diet was started right after the first consultation.

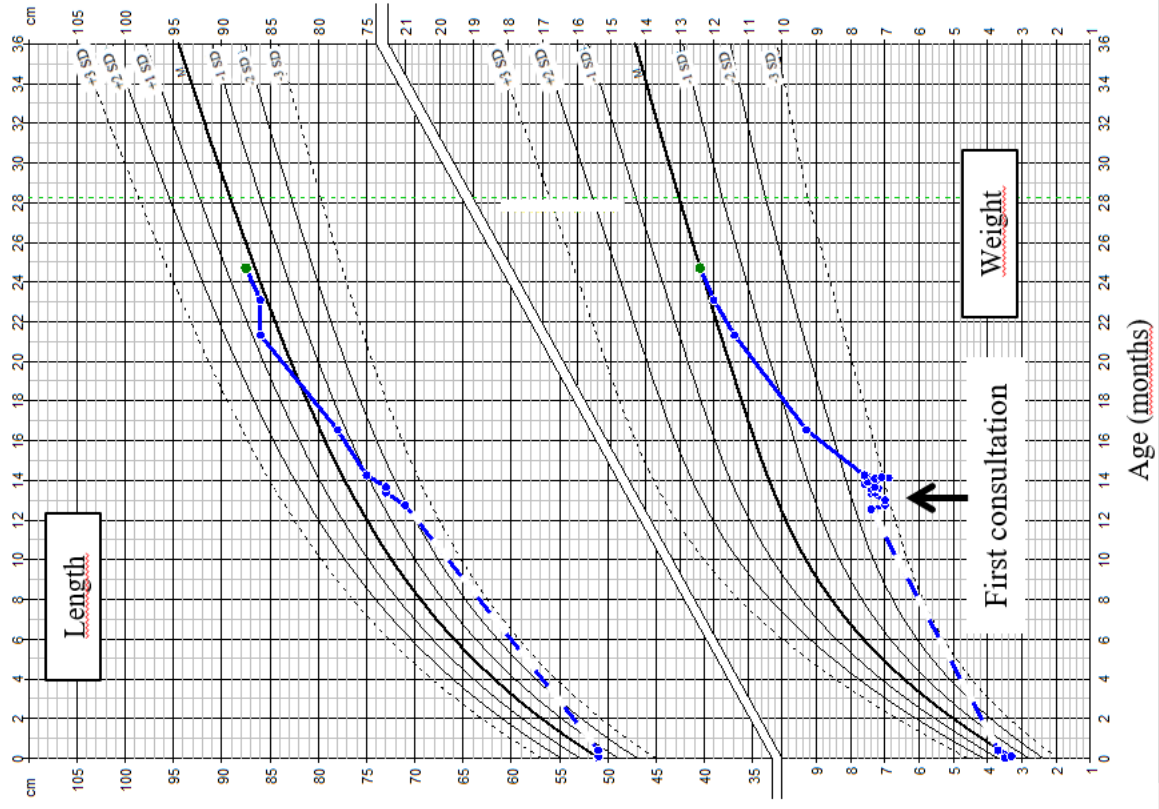
SD: standard deviation







4a. Weight and Length



4b. Head circumference

