



HAL
open science

Muscle entrapment in Orbito-zygomatoco-maxillary complex fracture Author names and affiliations

Jebrane Bouaoud, Matthieu Olivetto, Jérémie Bettoni, Bernard Devauchelle

► To cite this version:

Jebrane Bouaoud, Matthieu Olivetto, Jérémie Bettoni, Bernard Devauchelle. Muscle entrapment in Orbito-zygomatoco-maxillary complex fracture Author names and affiliations. *Journal of Stomatology, Oral and Maxillofacial Surgery*, 2019, 120 (6), pp.605-607. 10.1016/j.jormas.2019.02.018 . hal-03048170

HAL Id: hal-03048170

<https://hal.sorbonne-universite.fr/hal-03048170v1>

Submitted on 9 Dec 2020

HAL is a multi-disciplinary open access archive for the deposit and dissemination of scientific research documents, whether they are published or not. The documents may come from teaching and research institutions in France or abroad, or from public or private research centers.

L'archive ouverte pluridisciplinaire **HAL**, est destinée au dépôt et à la diffusion de documents scientifiques de niveau recherche, publiés ou non, émanant des établissements d'enseignement et de recherche français ou étrangers, des laboratoires publics ou privés.

TITLE PAGE

Muscle entrapment in Orbito-zygomatico-maxillary complex fracture

Author names and affiliations:

Jebrane Bouaoud ^{a,b}, Matthieu Olivetto ^a, Jeremie Bettoni ^a, Bernard Devauchelle ^a

a. Department of Maxillofacial Surgery, University Hospital of Amiens, Avenue Laennec 80000, Amiens Cedex 1, France.

b. Department of Maxillo-facial Surgery and Stomatology, Pitié-Salpêtrière Hospital, Pierre et Marie Curie University Paris 6, Sorbonne Paris Cite University, AP-HP, Paris, 75013, France

Corresponding author:

Jebrane Bouaoud, M.D

Department of Maxillo-facial Surgery and Stomatology, Pitié-Salpêtrière Hospital, Pierre et Marie Curie University Paris 6, Sorbonne Paris Cite University, AP-HP, Paris, 75013, France

E-mail jebrane.bouaoud@gmail.com

Phone# +33142161049

Keywords: Orbito-zygomatic fracture; Ophthalmologic injury; Muscle entrapment;

1. Case report

1
2 A 48-year-old man without relevant personal medical history, was addressed to the emergency
3
4 department for medical care following a maxillofacial trauma after receiving a stone on the left
5
6 cheekbone. The general examination revealed an alcohol-related trauma without loss of
7
8 consciousness. The patient was alert, Glasgow 14 and presented a spontaneously resolved epistaxis.
9

10
11 At the maxillofacial examination, we have found a middle face trauma with a deformation of the left
12
13 hemiface due to bones displacement, a left peri orbital hematoma, photophobia, a very painful
14
15 limitation of all ocular movement of the left eye (Figure 1, supplementary video) and diplopia. There
16
17 was no loss of vision. The mouth opening was painfully limited to 1.5 centimeters. The rest of the
18
19 maxillofacial examination was unremarkable. The patient was not comforted by opioid analgesics. A
20
21 computerized tomography (CT scan) was realized (Figure 2).
22
23
24

What is your diagnosis?

2. Answer

25
26
27
28
29 Left orbito-zygomatico-maxillary complex (OZMC) fracture with lateral wall displacement and
30
31 entrapment of the lateral and inferior rectus muscles, without intracranial lesion but with an
32
33 undisplaced and asymptomatic fracture of the left mandibular coronoid process.
34
35
36

37
38 Immediate surgery under general anesthesia was performed. An ophthalmic exam was realized at
39
40 the beginning of the procedure. No corneal or intra-orbital lesions were found. Then, we have
41
42 realized a forced duction test which has confirmed the limitation of the extra ocular motility for
43
44 elevation and adduction of the left globe. All the fracture sites were controlled by three surgical
45
46 approaches (oral, sub ciliary and sub brow). After liberation of oculomotor muscles, we have realized
47
48 an open reduction and osteosynthesis by mini-plates (Modus® 1.5) of the different fracture sites
49
50 (Figure 3). At the end of the surgery, the forced duction test showed no entrapment. The
51
52 postoperative period was uneventful, and an ophthalmologic control confirmed the absence of
53
54
55
56
57 trouble.
58
59
60
61
62
63
64
65

1
2
3
4
5
6
7
8
9
10
11
12
13
14
15
16
17
18
19
20
21
22
23
24
25
26
27
28
29
30
31
32
33
34
35
36
37
38
39
40
41
42
43
44
45
46
47
48
49
50
51
52
53
54
55
56
57
58
59
60
61
62
63
64
65

3. Discussion

Lateral orbital wall fractures are rarely isolated but most commonly seen with orbito-zygomatico-maxillary complex (OZMC) fractures. These fractures account for around 27% of all facial fractures¹. Alcohol-related assault for males are the most common presentation of this type of injury. Restriction of the extraocular muscles is among the most frequent ophthalmic injuries associated with fractures of the OZMC, reaching up to 15% of cases². There is a real benefit of early preoperative detection of ophthalmological injuries to manage it as soon as possible. The delay between the trauma and the treatment is a prognostic factor for ophthalmologic outcomes. Furthermore, it is important from a medicolegal position². Thus, entrapped muscle with limitation of motility is an indication of immediate surgical management³. The maxillofacial surgeons should have a thorough knowledge of the various ophthalmologic injuries that could occur secondary to facial trauma⁴.

Computed tomography (CT) is the gold standard for the diagnosis, the evaluation of the complexity of the OZMC fracture and allow to research complications such as globe, optic nerve and muscle injuries. In addition, the CT provides information on neurologic status to rule out any neurological cause of confusion in an alcoholic patient (skull fracture, extra-sub dural hematoma or intracranial bleeding). The evaluation of the sphenozygomatic suture provides a good estimation of the degree of displacement of the lateral wall. Significant displaced bones in OZMC fractures should be reduced and fixed to preserve the anatomical shape of the orbit and to preserve their function of globe protectors⁵.

In all cases, the CT should not delay the treatment. The diagnosis of muscle entrapment is first of all clinic with typically a painful limitation of the extraocular muscles in a context of facial trauma. The

1
2 clinical examination should be systematized to ensure to not omit brain or eyeball lesions. The
3 alcohol and the post traumatic confusion should not be underestimated.
4
5
6

7 **Figure 1: Patient pre-operative ophthalmologic examination. Here, we can see a painful limitation**
8 **of adduction of the left eye. This eye was limited in all directions of the visual field.**
9

10
11 **Figure 2: Pre-operative X-Ray computed tomography, 3D reconstruction and 2D axial and coronal**
12 **view of interest.**
13
14

15
16 **Figure 3: Post-operative X-Ray computed tomography, 3D reconstruction and 2D axial and coronal**
17 **view of interest.**
18
19
20
21
22

23 **References**

- 24
25
26 1. Johnson NR, Singh NR, Oztel M, Vangaveti VN, Rahmel BB, Ramalingam L. Ophthalmological
27 injuries associated with fractures of the orbitozygomaticomaxillary complex. *Br J Oral Maxillofac*
28 *Surg.* 2018;56(3):221-226. doi:10.1016/j.bjoms.2018.02.009
29
- 30 2. Jamal BT, Pfahler SM, Lane KA, et al. Ophthalmic injuries in patients with zygomaticomaxillary
31 complex fractures requiring surgical repair. *J Oral Maxillofac Surg Off J Am Assoc Oral Maxillofac*
32 *Surg.* 2009;67(5):986-989. doi:10.1016/j.joms.2008.12.035
33
34
- 35 3. Dubois L, Steenen SA, Gooris PJJ, Mourits MP, Becking AG. Controversies in orbital
36 reconstruction—II. Timing of post-traumatic orbital reconstruction: A systematic review. *Int J*
37 *Oral Maxillofac Surg.* 2015;44(4):433-440. doi:10.1016/j.ijom.2014.12.003
38
39
- 40 4. Patil SG, Kotwal IA, Joshi U, Allurkar S, Thakur N, Aftab A. Ophthalmological Evaluation by a
41 Maxillofacial Surgeon and an Ophthalmologist in Assessing the Damage to the Orbital Contents
42 in Midfacial Fractures: A Prospective Study. *J Maxillofac Oral Surg.* 2016;15(3):328-335.
43 doi:10.1007/s12663-015-0844-8
44
- 45 5. Alsuhaibani AH. Orbital Fracture: Significance of lateral wall. *Saudi J Ophthalmol.* 2010;24(2):49-
46 55. doi:10.1016/j.sjopt.2009.12.003
47
48
49
50
51
52
53
54
55
56
57
58
59
60
61
62
63
64
65

TITLE PAGE

Muscle entrapment in Orbito-zygomatico-maxillary complex fracture

Author names and affiliations:

Jebrane Bouaoud ^{a,b}, Matthieu Olivetto ^a, Jeremie Bettoni ^a, Bernard Devauchelle ^a

a. Department of Maxillofacial Surgery, University Hospital of Amiens, Avenue Laennec 80000, Amiens Cedex 1, France.

b. Department of Maxillo-facial Surgery and Stomatology, Pitié-Salpêtrière Hospital, Pierre et Marie Curie University Paris 6, Sorbonne Paris Cite University, AP-HP, Paris, 75013, France

Corresponding author:

Jebrane Bouaoud, M.D

Department of Maxillo-facial Surgery and Stomatology, Pitié-Salpêtrière Hospital, Pierre et Marie Curie University Paris 6, Sorbonne Paris Cite University, AP-HP, Paris, 75013, France

E-mail jebrane.bouaoud@gmail.com

Phone# +33142161049

Keywords: Orbito-zygomatic fracture; Ophthalmologic injury; Muscle entrapment;

1. Case report

A 48-year-old man without relevant personal medical history, was addressed to the emergency department for medical care following a maxillofacial trauma after receiving a stone on the left cheekbone. The general examination revealed an alcohol-related trauma without loss of consciousness. The patient was alert, Glasgow 14 and presented a spontaneously resolved epistaxis.

At the maxillofacial examination, we have found a middle face trauma with a deformation of the left hemiface due to bones displacement, a left peri orbital hematoma, photophobia, a very painful limitation of all ocular movement tricity of the left eye (Figure 1, supplementary video) and diplopia. There was no loss of vision. The mouth opening was painfully limited to 1.5 centimeters. The rest of the maxillofacial examination was unremarkable. The patient was not comforted by opioid analgesics. A computerized tomography (CT scan) was realized (Figure 2).

What is your diagnosis?

2. Answer

Left oOrbito-zygomatico-maxillary complex (OZMC) fracture with lateral wall displacement and entrapment of the lateral and inferior rectus muscles, without intracranial lesion but with an undisplaced and asymptomatic fracture of the left mandibular coronoid process.

Immediate surgery under general anesthesia was performed. An ophthalmic exam was realized at the beginning of the procedure. No corneal or intra-orbital lesions were found. Then, we have realized a forced duction test which has confirmed the limitation of the extra ocular motility for elevation an adduction of the left globe. The ~~all~~ All the fracture sites were controlled by three surgical approaches (oral, sub ciliary and sub brow). After liberation of oculomotor muscles, we have realized an open reduction and osteosynthesis by mini-plates (Modus® 1.5) of the different fracture sites (Figure 3). At the end of the surgery, the forced duction test showed no entrapment. The postoperative period was uneventful, and an ophthalmologic control confirmed the absence of trouble.

3. Discussion

~~Immediate surgery under general anesthesia was performed. An ophthalmic exam was realized at the beginning of the procedure. No corneal or intra-orbital lesions were found. Then, we have realized a forced duction test which has confirmed the limitation of the extra-ocular motility for elevation and adduction of the left globe. The all fracture sites were controlled by three surgical approaches (oral, sub-ciliary and sub-brow). After liberation of oculomotor muscles, we have realized an open reduction and osteosynthesis by mini-plates (Modus® 1.5) of the different fracture sites (Figure 3). At the end of the surgery, the forced duction test showed no entrapment. The postoperative period was uneventful, and an ophthalmologic control confirmed the absence of trouble.~~

Lateral orbital wall fractures are rarely isolated but most commonly seen with orbito-zygomaticomaxillary complex (OZMC) fractures. These fractures account for around 27% of all facial fractures¹. Alcohol-related assault for males are the most common presentation of this type of injury. Restriction of the extraocular muscles is among the most frequent ophthalmic injuries associated with fractures of the OZMC, reaching up to 15% of cases². There is a real benefit of early preoperative detection of ophthalmological injuries to manage it as soon as possible. The delay between the trauma and the treatment is a prognostic factor for ophthalmologic outcomes. Furthermore, it is important from a medicolegal position². Thus, entrapped muscle with limitation of motility is an indication of immediate surgical management³. The maxillofacial surgeons should have a thorough knowledge of the various ophthalmologic injuries that could occur secondary to facial trauma⁴.

Computed tomography (CT) is the gold standard for the diagnosis, the evaluation of the complexity of the OZMC fracture and allow to research complications such as globe, optic nerve and muscle

1 injuries. In addition, the CT provides information on neurologic status to rule out any neurological
2 cause of confusion in an alcoholic patient (skull fracture, extra-sub dural hematoma or intracranial
3 bleeding). The evaluation of the sphenozygomatic suture provides a good estimation of the degree of
4 displacement of the lateral wall. Significant displaced bones in OZMC fractures should be reduced
5 and fixed to preserve the anatomical shape of the orbit and to preserve their function of globe
6 protectors⁵.
7
8
9
10
11
12
13
14
15

16 In all cases, the CT should not delay the treatment. The diagnosis of muscle entrapment is first of all
17 clinic with typically a painful limitation of the extraocular muscles in a context of facial trauma. The
18 clinical examination should be systematized to ensure to not omit brain or eyeball lesions. The
19 alcohol and the post traumatic confusion should not be underestimated.
20
21
22
23
24
25
26
27

28 **Figure 1: Patient pre-operative ophthalmologic examination. Here, we can see a painful limitation**
29 **of adduction of the left eye. This eye was limited in all directions of the visual field.**
30
31
32

33 **Figure 2: Pre-operative X-Ray computed tomography, 3D reconstruction and 2D axial and coronal**
34 **view of interest.**
35
36
37

38 **Figure 3: Post-operative X-Ray computed tomography, 3D reconstruction and 2D axial and coronal**
39 **view of interest.**
40
41
42
43
44

45 **References**

- 46
47 1. Johnson NR, Singh NR, Oztel M, Vangaveti VN, Rahmel BB, Ramalingam L. Ophthalmological
48 injuries associated with fractures of the orbitozygomaticomaxillary complex. *Br J Oral Maxillofac*
49 *Surg.* 2018;56(3):221-226. doi:10.1016/j.bjoms.2018.02.009
50
51
- 52 2. Jamal BT, Pfahler SM, Lane KA, et al. Ophthalmic injuries in patients with zygomaticomaxillary
53 complex fractures requiring surgical repair. *J Oral Maxillofac Surg Off J Am Assoc Oral Maxillofac*
54 *Surg.* 2009;67(5):986-989. doi:10.1016/j.joms.2008.12.035
55
- 56 3. Dubois L, Steenen SA, Gooris PJJ, Mourits MP, Becking AG. Controversies in orbital
57 reconstruction—II. Timing of post-traumatic orbital reconstruction: A systematic review. *Int J*
58 *Oral Maxillofac Surg.* 2015;44(4):433-440. doi:10.1016/j.ijom.2014.12.003
59
60
61
62
63
64
65

4. Patil SG, Kotwal IA, Joshi U, Allurkar S, Thakur N, Aftab A. Ophthalmological Evaluation by a Maxillofacial Surgeon and an Ophthalmologist in Assessing the Damage to the Orbital Contents in Midfacial Fractures: A Prospective Study. *J Maxillofac Oral Surg.* 2016;15(3):328-335. doi:10.1007/s12663-015-0844-8
5. Alsuhaibani AH. Orbital Fracture: Significance of lateral wall. *Saudi J Ophthalmol.* 2010;24(2):49-55. doi:10.1016/j.sjopt.2009.12.003

1
2
3
4
5
6
7
8
9
10
11
12
13
14
15
16
17
18
19
20
21
22
23
24
25
26
27
28
29
30
31
32
33
34
35
36
37
38
39
40
41
42
43
44
45
46
47
48
49
50
51
52
53
54
55
56
57
58
59
60
61
62
63
64
65

Figure 1
[Click here to download high resolution image](#)

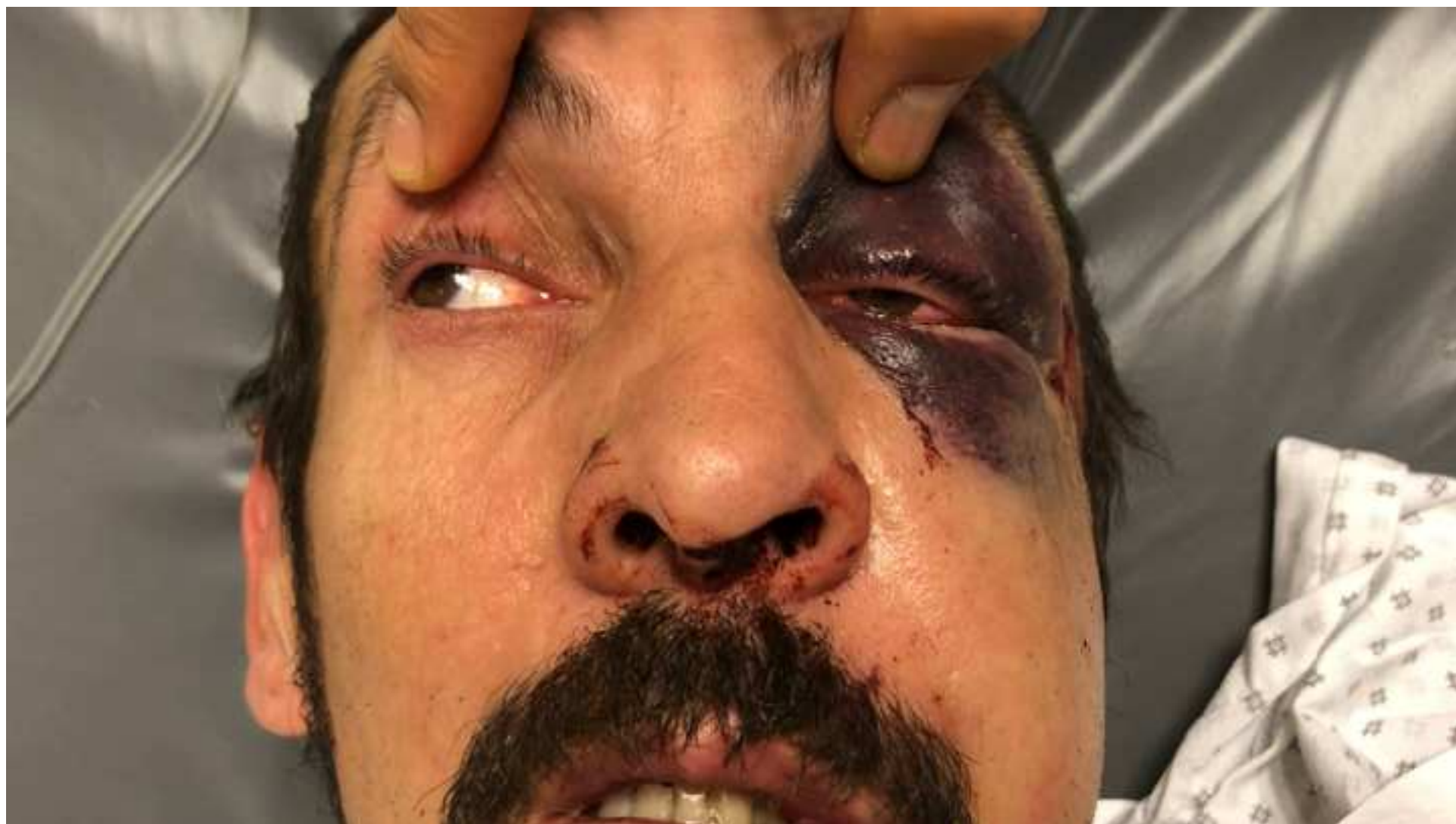

Figure 2
[Click here to download high resolution image](#)

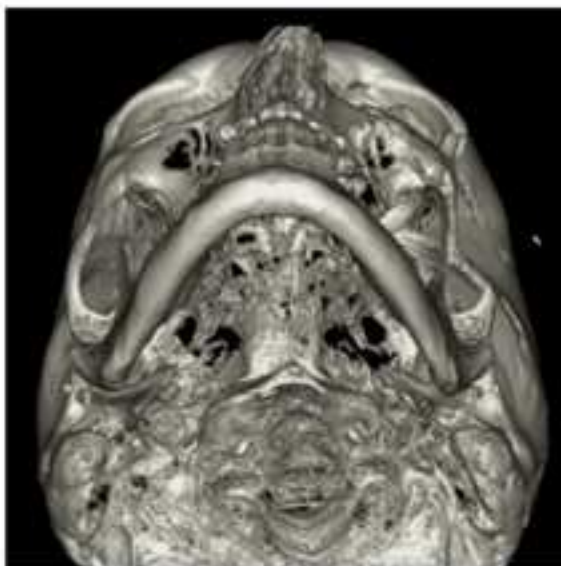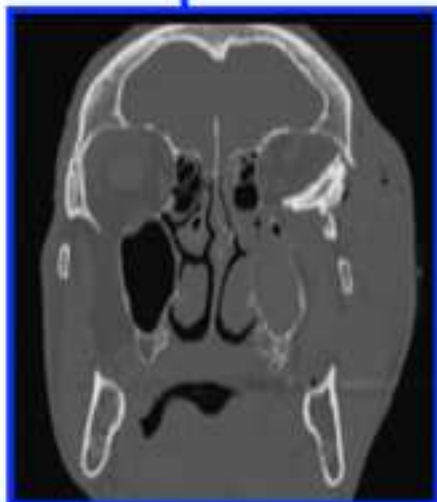
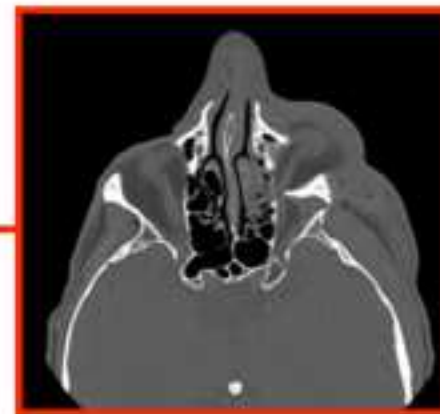
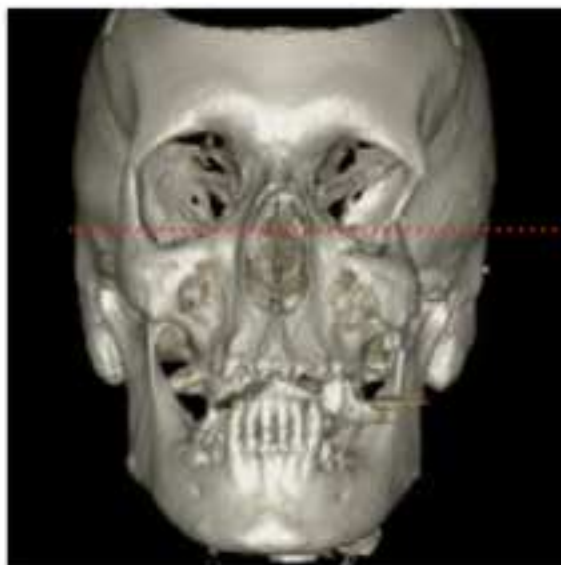
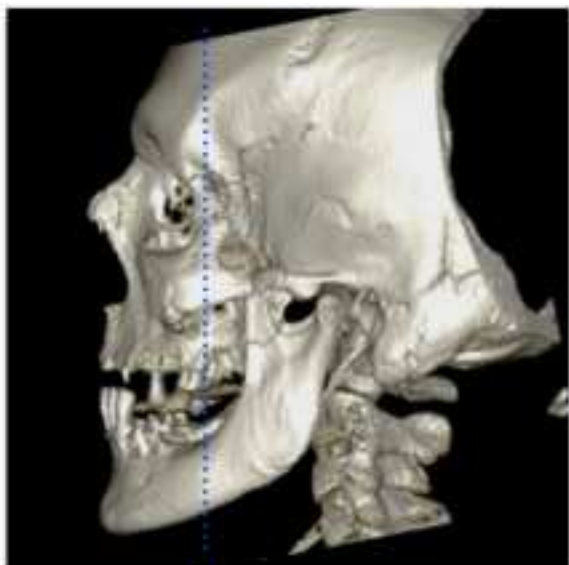


Figure 3
[Click here to download high resolution image](#)

