



HAL
open science

Adrenal gland as a sanctuary site for immunotherapy in patients with microsatellite instability-high metastatic colorectal cancer

Romain Cohen, Vincent Jonchère, Christelle de La Fouchardière, Toky Ratovomanana, Quentin Letourneur, Mira Ayadi, Lucile Armenoult, Adrien Buisson, Matthieu Sarabi, Anna Pellat, et al.

► To cite this version:

Romain Cohen, Vincent Jonchère, Christelle de La Fouchardière, Toky Ratovomanana, Quentin Letourneur, et al.. Adrenal gland as a sanctuary site for immunotherapy in patients with microsatellite instability-high metastatic colorectal cancer. *Journal for Immunotherapy of Cancer*, 2021, 9 (2), pp.e001903. 10.1136/jitc-2020-001903. hal-03141378

HAL Id: hal-03141378




<https://hal.sorbonne-universite.fr/hal-03141378>

Submitted on 15 Feb 2021

HAL is a multi-disciplinary open access archive for the deposit and dissemination of scientific research documents, whether they are published or not. The documents may come from teaching and research institutions in France or abroad, or from public or private research centers.

L'archive ouverte pluridisciplinaire **HAL**, est destinée au dépôt et à la diffusion de documents scientifiques de niveau recherche, publiés ou non, émanant des établissements d'enseignement et de recherche français ou étrangers, des laboratoires publics ou privés.

Adrenal gland as a sanctuary site for immunotherapy in patients with microsatellite instability-high metastatic colorectal cancer

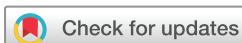Romain Cohen ^{1,2}, Vincent Jonchère ², Christelle De La Fouchardière,³ Toky Ratovomanana,² Quentin Letourneur,² Mira Ayadi,⁴ Lucile Armenoult,⁴ Adrien Buisson,⁵ Matthieu Sarabi,³ Anna Pellat,¹ Raphael Colle,¹ Francois Paye,⁶ Pierre Meeus,⁷ Magali Svrcek,^{2,8} Alex Duval,² Thierry Andre ^{1,2}

To cite: Cohen R, Jonchère V, De La Fouchardière C, *et al*. Adrenal gland as a sanctuary site for immunotherapy in patients with microsatellite instability-high metastatic colorectal cancer. *Journal for ImmunoTherapy of Cancer* 2021;**9**:e001903. doi:10.1136/jitc-2020-001903

► Prepublication history and additional material is published online only. To view please visit the journal online (<http://dx.doi.org/10.1136/jitc-2020-001903>).

RC and VJ contributed equally.

Accepted 10 January 2021



© Author(s) (or their employer(s)) 2021. Re-use permitted under CC BY-NC. No commercial re-use. See rights and permissions. Published by BMJ.

For numbered affiliations see end of article.

Correspondence to

Dr Romain Cohen;
romain.cohen@aphp.fr

ABSTRACT

Metastatic colorectal cancers (mCRC) harboring microsatellite instability (MSI) are sensitive to immune checkpoint inhibitors (ICIs), but the mechanisms of resistance to ICIs remain unclear. Dissociated responses in patients with ICI-treated cancer suggest that certain organs may serve as sanctuary sites due to the tumor microenvironment. This case series describes five patients with ICI-treated MSI mCRC with disease progression limited to the adrenal glands. At ICI initiation, three patients were free of metastasis in the adrenal glands. Four patients experienced objective response per RECIST (Response Evaluation Criteria in Solid Tumors) while treated with ICI. ICI treatment was discontinued due to progressive disease limited to the adrenal glands (n=3) or toxicity (n=2). The time between ICI initiation and progression in the adrenal glands ranged from 11 to 39 months. Adrenalectomy (n=3) and stereotactic body radiation therapy (n=2) were performed. At the last follow-up, all patients were alive and progression free. Molecular analyses were performed in one patient. A significant impairment of the antigen presentation pathway was observed in the ICI-resistant lesion of the adrenal gland, which could be explained by the presence of glucocorticoids in the adrenal gland microenvironment. We also detected an overexpression of *TSC22D3*, a glucocorticoid-target gene that functions as a mediator of anti-inflammation and immunosuppression. This case series suggests that the adrenal glands may be the sanctuary sites for ICI-treated MSI mCRC through the glucocorticoid-induced impairment of the antigen presentation machinery.

INTRODUCTION

Microsatellite instability (MSI) is a tumor phenotype resulting from a deficient mismatch repair system (dMMR). It is observed in approximately 5% of patients with metastatic colorectal cancers (mCRC). Immune checkpoint inhibitors (ICIs) have changed the treatment of patients with MSI/dMMR mCRC, with an objective response

(OR) rate ranging from 30% to 60% and a 1-year overall survival rate ranging from 72% to 85% in heavily pretreated patients.¹ Recently, first-line pembrolizumab has been associated with clinically meaningful and statistically significant improvement of progression-free survival compared with standard of care chemotherapy with or without bevacizumab or cetuximab.² However, up to 50% of patients with MSI/dMMR mCRC exhibit primary resistance to ICIs. Besides, 5%–25% of responders might develop acquired resistance to these treatments, knowing this estimation might increase with longer follow-up.¹ Mechanisms underlying *de novo* and acquired resistance to ICIs in MSI/dMMR cancer are barely known. Besides, dissociated responses have been reported in approximately 8% of patients with metastatic solid tumors treated with ICIs, suggesting potential site-specific patterns of response.^{3,4} MSI/dMMR mCRC are associated with a specific metastatic pattern, reflected in high rates of peritoneal carcinomatosis and distant lymph node metastasis. Contrarily, adrenal glands metastases are rarely found in mCRC.

Here we report a case series of five patients with MSI/dMMR mCRC treated with ICI who experienced progression of adrenal gland metastases despite OR or disease stability of other metastatic sites, suggesting potential site-specific resistance to ICI. Translational analyses were performed for one patient, seeking for potential site-specific mechanisms of resistance.

RESULTS

The five patients of this case series represent 2.5% of the entire population of patients with ICI-treated MSI/dMMR in our institutions. Table 1 summarizes the disease history of these five ICI-treated mCRC cases. The age of patients ranged from 44 to 77 years. Three patients had germline MMR gene mutation. Two patients had an adrenal gland metastasis at the ICI initiation. Other metastatic sites were distant lymph nodes (4/5), liver (3/5), peritoneum and lung (1/5). Four patients were treated with a combination of an anti-PD1 monoclonal antibody and an anti-CTLA4 antibody, one received an anti-PD1 alone. Four patients experienced OR, with three partial responses and one complete response. Reasons of treatment discontinuation were progression limited to the adrenal glands (n=3) and toxicity (n=2). All five patients experienced a significant disease progression limited to the adrenal gland, with three of them being newly defined target lesions (online supplemental figure S1). The time from ICI initiation to the date of disease progression in the adrenal gland ranged from 11 to 39 months. The progressive adrenal metastases were treated with adrenalectomy (n=3) or stereotactic body radiation therapy (n=2). No other systemic anticancer treatments was initiated. At the last follow-up visit (the time from local treatment date to the last patient visit: 3–47 months), all patients were alive and free of progression.

Tumor tissue samples from patient #1 were investigated to identify the potential resistance mechanisms. Paired tumor-normal tissue samples from the progressive adrenal gland, the primary tumor, and liver metastasis resected before ICI initiation were analyzed using whole-exome sequencing and RNA sequencing (Supplementary methods). All three metastatic disease sites displayed the hypermutator phenotype (online supplemental figure S2A and S3) in repetitive (43.9, 43.9, 51.7 mutations/Mb) and non-repetitive DNA sequences (29.1, 27.5, 32.0 mutations/M for the colon, liver, and adrenal tumors, respectively). All sites exhibited an MSI phenotype (online supplemental figure S2B; 34.5, 32.4, 37.0) MSI sensor score for the colon, liver and adrenal tumors, respectively).

We hypothesized that adrenal tumors could decrease their antigen presentation, leading to immune escape. For the majority of the antigen presenting genes (*HLA-B*, *HLA-C*, *HLA-E*, *HLA-F*, *HLA-DRA*, *HLA-DRB1*, *TAP1*, *TAP2*, *TAPBP*) a decrease expression in the adrenal tumor was observed (figure 1A). This loss of expression might be related to the presence of glucocorticoids, which inhibit *NF-κB* gene, controlling the HLA-class I expression (online supplemental figure S4). This might be also explained by adrenal-specific mutation(s) in antigen presentation pathway. In line, we identified two candidate's mutations, namely *TAPBP* and *CIITA* (figure 1B), which are essential for the signaling pathway (online supplemental figure S4). We also detected an overexpression of *TSC22D3* (figure 1C), a glucocorticoid-target gene, which functions

Table 1 Patient clinical characteristics

Patient	Age (year), gender	Germline status	Tumor profile	Number of prior lines of chemotherapy	Metastatic sites at ICI initiation	ICI	First and last infusion of ICI	Reason of ICI discontinuation	Overall best response	Best response of adrenal gland metastasis	PD of adrenal gland metastasis (date)	Treatment of adrenal gland progression (date)	PD on other metastatic sites (date)	The last follow-up visit (status)
#1	61, F	Sporadic case	MSI, MLH1-neg, BRAFmt	1	Liver, lymph nodes	Anti-PD1 +anti-CTLA4	06/2015 to 07/2015	Necrotizing myositis	PR	NA (not present at baseline)	03/2016	Adrenalectomy (08/2016)	No	07/2020 (free of progression)
#2	44, M	Lynch syndrome	MSI, MSH2-neg, RAS/RAF-wt	2	Adrenal gland, liver, lymph nodes,	Anti-PD1 +anti-CTLA4	05/2016 to 03/2018	PD (adrenal gland)	PR	SD	03/2018	SBRT (06/2018)	No	06/2020 (free of progression)
#3	45, M	Lynch syndrome	MSI, MSH2-neg, KRAS-mt	3	Adrenal gland, liver, lymph nodes	Anti-PD1 +anti-CTLA4	09/2016 to 11/2019	PD (adrenal gland)	PR	SD	12/2019	SBRT (03/2020)	No	06/2020 (free of progression)
#4	52, M	Lynch syndrome	MSI, MSH6-neg, MSH6-neg	0	Peritoneum	Anti-PD1	07/2017 To 02/2019	Grade 3 colitis	CR	NA (not present at baseline)	12/2019	Adrenalectomy (03/2020)	No	06/2020 (free of progression)
#5	77, F	Unknown	MLH1-neg, PMS2-neg, βcatenine-mt	3	Lung, lymph nodes	Anti-PD1 +anti-CTLA4	01/2019 To 01/2020	PD (adrenal gland)	SD	NA (not present at baseline)	12/2019	Adrenalectomy (03/2020)	No	06/2020 (free of progression)

CR, complete response; ICI, immune checkpoint inhibitor; MSI, microsatellite instability; mt, mutated; neg, negative; PD, progressive disease; PR, partial response; SBRT, stereotactic body radiation therapy; SD, stable disease; wt, wild type.

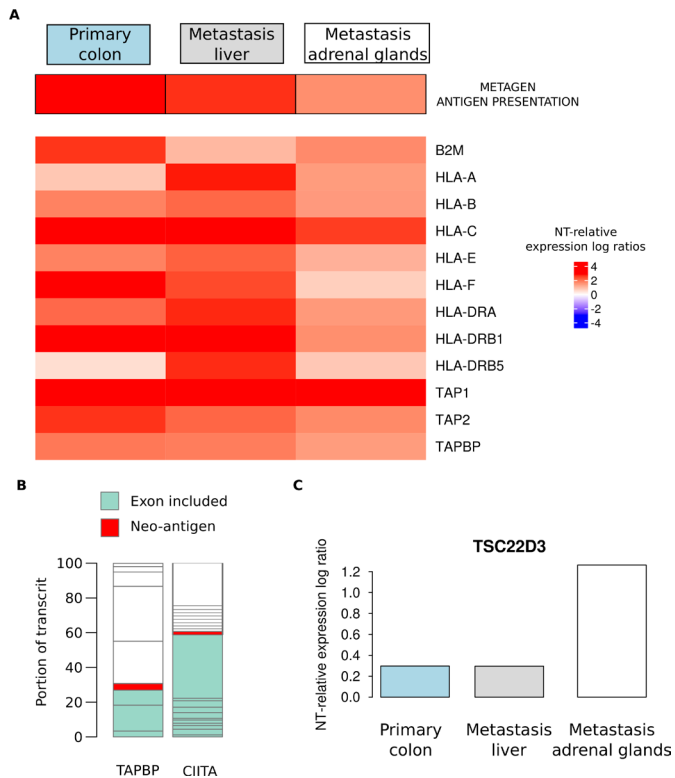


Figure 1 Potential resistance mechanism. The heatmap shows the percentage of nucleotide (NT) relative expression ratios at three tumor sites for key genes from the antigen presentation pathway. (A) Biological consequence of two microsatellite mutations on two key genes of the antigen presentation pathway. (B) Box plot represents NT relative expression ratio across tumor sites for *TSC22D3* gene (C).

as a mediator of anti-inflammation and immunosuppression and has been shown to abolish the therapeutic benefit of PD-1 blockade in mouse models of cancers.⁵ Our analysis of the tumor microenvironment using Microenvironment Cell Populations-counter (MCP-counter) did not show significant differences in cell populations according to the tumor site. There were no significant differences for expressions of gene (*PDCD1*, *PDCD1LG2*, *CTLA4*, and *HAVCR2*) encoding for checkpoint proteins (PD1, PDL2, CTLA4, and TIM3, respectively; data not shown).

DISCUSSION

We report here a case series of five patients with MSI/dMMR mCRC who experienced disease progression limited to the adrenal gland while on ICIs. To our knowledge, this is the first report suggesting the site-specific resistance to ICIs of MSI/dMMR tumors. Molecular analysis of one patient showed a significant decrease of expression of the antigen presentation pathway genes in the ICI-resistant adrenal gland.

The concept of the sanctuary sites, such as the brain, ovary, or testis is well known in the context of cytotoxic chemotherapy. In the era of immunotherapy it is supported by the existence of dissociated tumor responses.⁴ Besides, retrospective studies suggest that the

sensitivity to ICIs may depend on the metastatic site, with lung lesions being more likely to achieve OR than other sites such as liver metastases.⁶ The differential responses to treatment observed according to the site of metastasis suggest that the tumor microenvironment is involved in the intrapatient heterogeneity of tumor response.

Few clinical case reports of ICI-treated solid tumors and surgical series of patients with melanoma suggest that adrenal glands might be a sanctuary for tumor cells.⁷ No warning signal has been reported for patients with lung cancer, though.³ Our case series with five tumor progressions limited to the adrenal glands in patients with MSI/dMMR mCRC is striking since CRC involving adrenal glands is uncommon. The fact that these cases had no PD in other metastatic sites after local treatment (surgery or stereotactic body radiation therapy) supports the use of local therapies in case of progression limited to the adrenal glands. One unresolved question is whether ICI should be maintained beyond progression limited to a sanctuary site.

The systemic administration of synthetic glucocorticoids such as dexamethasone and prednisolone has been associated with poorer outcomes in patients with ICI-treated cancer.⁸ It has been shown that both synthetic and endogenous glucocorticoids can inhibit anticancer immune response through an impairment of the antigen presentation by dendritic cells or the activation of T-cells.⁹ Given that endogenous glucocorticoids is produced by the adrenal glands, one might hypothesize the adrenal gland microenvironment might be immunosuppressive and acts as a sanctuary site for ICI-treated neoplasms tumor cells.

From the molecular data of one analyzed patient, we conclude that the mechanism underlying the acquired resistance of the tumor to ICI was not related to a loss of the MSI phenotype. All tumor samples of this single patient (the primary colon tumor, liver metastasis, and refractory adrenal gland lesion) presented an MSI phenotype associated with high mutation burden. A defect in the antigen presentation processing was likely to be involved and we hypothesize therefore that this may act synergistically with local immunosuppression for the adrenal gland metastasis resistance in this patient. This hypothesis is strengthened by the work of Yang *et al*⁵ who showed in mouse models that *TSC22D3* abolishes the therapeutic effect of PD-1 blockade. Since an antigen presentation is known as a mechanism of acquired resistance to ICIs,¹⁰ we hypothesize that the adrenal gland might be a sanctuary of ICI-treated cancer through the glucocorticoid-induced impairment of the antigen presentation machinery.

We acknowledge some limitations of our work. Only one patient has his tumor samples analyzed with the adrenal gland sample collected at the time of disease progression when on ICI and the primary tumor and the liver metastasis samples before the ICI initiation. Another limitation was the lack a control group to evaluate the relationship between dissociated tumor responses and the adrenal gland involvement. Therefore, the interpretation of our

results, which deserve confirmation in larger studies, should be interpreted with caution. Molecular investigations of ICI-resistant MSI/dMMR mCRC metastases (from adrenal glands and other sites) are urgently needed to decipher microenvironment-related mechanisms of resistance to ICI and, eventually, identify other sanctuary sites.

In conclusion, our case series highlights the importance of giving attention to the adrenal glands in patients treated with ICIs for MSI/dMMR mCRC.

Author affiliations

¹Sorbonne Université; Department of Medical Oncology, Hôpital Saint-Antoine, AP-HP, Paris, France

²Sorbonne Université, INSERM UMRS 938, Équipe Instabilité des Microsatellites et Cancer, Équipe Labellisée par la Ligue Nationale Contre le Cancer et SIRIC CURAMUS, Centre de recherche Saint Antoine, Paris, France

³Medical Oncology Department, Centre Leon Berard, Lyon I University, Lyon, France

⁴Programme Cartes d'Identité des Tumeurs, Ligue Nationale Contre Le Cancer, Paris, France

⁵Centre Léon Berard, Department of Biopathology, Lyon, Paris

⁶Sorbonne Université; Department of Digestive Surgery, Hôpital Saint-Antoine, AP-HP, Paris, France

⁷Centre Leon Berard, Department of Surgery, Lyon, France

⁸Sorbonne Université; Department of Pathology, Hôpital Saint-Antoine, AP-HP, Paris, France

Acknowledgements The authors thank Magdalena Benetkiewicz, Sc.D, for editorial assistance.

Contributors Data collection: RC, CDLF, MS, TA. Translational analysis: VJ, TR, QL, MA, LA, AD. Data interpretation: RC, VJ, CDLF, TR, QL, MA, LA, AB, MS, AP, RC, FP, PM, MS, AD, TA. Manuscript drafting: RC, VJ, AD, TA. Manuscript reviewing: RC, VJ, CDLF, TR, QL, MA, LA, AB, MS, AP, RC, FP, PM, MS, AD, TA.

Funding The authors have not declared a specific grant for this research from any funding agency in the public, commercial or not-for-profit sectors.

Competing interests Dr André reports consulting/advisory role and or received honoraria from Amgen, Bristol-Myers Squibb, Chugai, Clovis, GlaxoSmithKline, Gristone oncology, HaliuDx, MSD Oncology, Pierre Fabre, Roche/Ventana, Sanofi, Servier and Tesaro and has received travel, accommodations, and expenses from Roche/Genentech, MSD Oncology, and Bristol-Myers Squibb. Dr Cohen reports honoraria from MSD Oncology, and research grant from Servier Institute. Dr Pellat reports honoraria from Servier and travel fees from Ipsen. Dr Svrcek reports consulting/advisory role and or received honoraria from Bristol-Myers Squibb, Astellas, MSD Oncology, Sanofi, and has received travel, accommodations, and expenses from Bristol-Myers Squibb and Ventana/Roche. The other authors did not report any conflict of interest.

Patient consent for publication Obtained.

Provenance and peer review Not commissioned; externally peer reviewed.

Supplemental material This content has been supplied by the author(s). It has not been vetted by BMJ Publishing Group Limited (BMJ) and may not have been

peer-reviewed. Any opinions or recommendations discussed are solely those of the author(s) and are not endorsed by BMJ. BMJ disclaims all liability and responsibility arising from any reliance placed on the content. Where the content includes any translated material, BMJ does not warrant the accuracy and reliability of the translations (including but not limited to local regulations, clinical guidelines, terminology, drug names and drug dosages), and is not responsible for any error and/or omissions arising from translation and adaptation or otherwise.

Open access This is an open access article distributed in accordance with the Creative Commons Attribution Non Commercial (CC BY-NC 4.0) license, which permits others to distribute, remix, adapt, build upon this work non-commercially, and license their derivative works on different terms, provided the original work is properly cited, appropriate credit is given, any changes made indicated, and the use is non-commercial. See <http://creativecommons.org/licenses/by-nc/4.0/>.

ORCID iDs

Romain Cohen <http://orcid.org/0000-0001-9602-5162>

Vincent Jonchère <http://orcid.org/0000-0002-1925-6650>

Thierry Andre <http://orcid.org/0000-0002-5103-7095>

REFERENCES

- Overman MJ, Lonardi S, Wong KYM, *et al*. Durable clinical benefit with nivolumab plus ipilimumab in DNA mismatch Repair-Deficient/Microsatellite Instability-High metastatic colorectal cancer. *J Clin Oncol* 2018;36:773–9.
- Andre T, Shiu K-K, Kim TW, *et al*. Pembrolizumab versus chemotherapy for microsatellite instability-high/mismatch repair deficient metastatic colorectal cancer: the phase 3 KEYNOTE-177 study. *JCO* 2020;38:LBA4.
- Tazdait M, Mezquita L, Lahmar J, *et al*. Patterns of responses in metastatic NSCLC during PD-1 or PDL-1 inhibitor therapy: comparison of RECIST 1.1, irRECIST and iRECIST criteria. *Eur J Cancer* 2018;88:38–47.
- Vaflard P, Paoletti X, Servois V, *et al*. Dissociated responses in patients with metastatic solid tumours treated with immunotherapy. *Annals of Oncology* 2019;30:v521.
- Yang H, Xia L, Chen J, *et al*. Stress-glucocorticoid-TSC2D3 axis compromises therapy-induced antitumor immunity. *Nat Med* 2019;25:1428–41.
- Pires da Silva I, Lo S, Quek C, *et al*. Site-Specific response patterns, pseudoprogression, and acquired resistance in patients with melanoma treated with ipilimumab combined with anti-PD-1 therapy. *Cancer* 2020;126:86–97.
- Nguyen MC, Shah MH, Liebner DA, *et al*. The adrenal gland as a sanctuary site of metastases after pembrolizumab treatment: a case series. *J Natl Compr Canc Netw* 2018;16:1279–83.
- Petrelli F, Signorelli D, Ghidini M, *et al*. Association of steroids use with survival in patients treated with immune checkpoint inhibitors: a systematic review and meta-analysis. *Cancers* 2020;12. doi:10.3390/cancers12030546. [Epub ahead of print: 27 Feb 2020].
- Falcón-Beas C, Tittarelli A, Mora-Bau G, *et al*. Dexamethasone turns tumor antigen-presenting cells into tolerogenic dendritic cells with T cell inhibitory functions. *Immunobiology* 2019;224:697–705.
- Sade-Feldman M, Jiao YJ, Chen JH, *et al*. Resistance to checkpoint blockade therapy through inactivation of antigen presentation. *Nat Commun* 2017;8:1136.