



**HAL**  
open science

## Chronic persistent HHV-6B infection after sulfasalazine-induced DRESS with demonstration of HHV-6 encoded small noncoding RNAs (sncRNAs) in Crohn's-like colitis: Case report

Vincent Descamps, Agnès Gautheret-Dejean, Anne-Laure Pelletier, Pascale Bonnafous, Lydia Deschamps, Bhupesh Prusty

### ► To cite this version:

Vincent Descamps, Agnès Gautheret-Dejean, Anne-Laure Pelletier, Pascale Bonnafous, Lydia Deschamps, et al.. Chronic persistent HHV-6B infection after sulfasalazine-induced DRESS with demonstration of HHV-6 encoded small noncoding RNAs (sncRNAs) in Crohn's-like colitis: Case report. *Clinical Case Reports*, 2021, 9 (2), pp.841-844. 10.1002/ccr3.3680 . hal-03147075

**HAL Id: hal-03147075**

**<https://hal.sorbonne-universite.fr/hal-03147075v1>**

Submitted on 19 Feb 2021

**HAL** is a multi-disciplinary open access archive for the deposit and dissemination of scientific research documents, whether they are published or not. The documents may come from teaching and research institutions in France or abroad, or from public or private research centers.

L'archive ouverte pluridisciplinaire **HAL**, est destinée au dépôt et à la diffusion de documents scientifiques de niveau recherche, publiés ou non, émanant des établissements d'enseignement et de recherche français ou étrangers, des laboratoires publics ou privés.

# Chronic persistent HHV-6B infection after sulfasalazine-induced DRESS with demonstration of HHV-6 encoded small noncoding RNAs (sncRNAs) in Crohn's-like colitis: Case report

Vincent Descamps<sup>1</sup>  | Agnès Gautheret-Dejean<sup>2</sup> | Anne-Laure Pelletier<sup>3</sup> |  
Pascale Bonnafous<sup>4</sup> | Lydia Deschamps<sup>5</sup> | Bhupesh K. Prusty<sup>6</sup>

<sup>1</sup>Department of Dermatology, Bichat Hospital, APHP Paris, Paris 7 University, Paris, France

<sup>2</sup>Department of Virology, Pitié-Salpêtrière Hospital, APHP, Paris, France

<sup>3</sup>Department of Gastroenterology, Bichat Hospital, APHP Paris, Paris 7 University, Paris, France

<sup>4</sup>INSERM, IPLESP, THERAVIR team, Sorbonne Université, Paris, France

<sup>5</sup>Department of Pathology, Bichat Hospital, APHP Paris, Paris 7 University, Paris, France

<sup>6</sup>Institute for Virology and Immunobiology, University of Wuerzburg, Wuerzburg, Germany

## Correspondence

Vincent Descamps, Department of Dermatology, Bichat Hospital, APHP Paris, Paris 7 University, 46 rue Henri Huchard, 75018 Paris, France.  
Email: vincent.descamps@aphp.fr

## Abstract

A sulfasalazine-induced DRESS (Drug Reactivation with Eosinophilia and Systemic Symptoms) was complicated by a Crohn's-like colitis. We demonstrated HHV-6 reactivation with presence of HHV-6 DNA and small noncoding RNA in colonic lesions. This observation confirms the major role of HHV-6 reactivation in DRESS manifestations and the importance of looking for HHV-6 reactivation in DRESS.

## KEYWORDS

Crohn's disease, drug reaction with eosinophilia and systemic symptoms, drug-induced hypersensitivity syndrome, human herpesvirus 6B

## 1 | INTRODUCTION

Drug reaction with eosinophilia and systemic symptoms (DRESS), also referred to as drug-induced hypersensitivity syndrome (DIHS), is a severe hypersensitivity drug reaction associating skin eruption and organ involvement. We report a 32-year-old man with sulfasalazine-induced DRESS with reactivation of human herpesvirus 6B (HHV-6B). His case is remarkable because he had chronic persistent HHV-6 infection with colonic infection and development of Crohn's disease.

Drug reaction with eosinophilia and systemic symptoms (DRESS) is a severe drug hypersensitivity syndrome.<sup>1,2</sup> The pathophysiology of this syndrome is not fully understood, but human herpesvirus 6 (HHV-6) reactivation plays a major role in its development.<sup>1-4</sup> In most cases, duration of HHV-6 reactivation is limited.

We report a typical case of sulfasalazine-induced DRESS with reactivation of HHV-6B in a patient with spondyloarthritis who developed a Crohn's-like colitis after DRESS. We demonstrated a chronic persistent HHV-6 infection with the

This is an open access article under the terms of the Creative Commons Attribution-NonCommercial-NoDerivs License, which permits use and distribution in any medium, provided the original work is properly cited, the use is non-commercial and no modifications or adaptations are made.

© 2020 The Authors. *Clinical Case Reports* published by John Wiley & Sons Ltd.

presence of HHV-6 DNA and encoded small noncoding RNA (sncRNA) in colonic lesions.

## 2 | CASE REPORT

A 32-year-old man was treated for axial and peripheral spondyloarthritis by sulfasalazine without any symptom suggestive of Crohn's disease. He presented 3 weeks after the beginning of sulfasalazine on August 2009 with exanthema, facial edema, high fever, and diffuse lymphadenopathy. The first blood tests confirmed an eosinophilia (3200 cells/ $\mu$ L), a mononucleosis syndrome with atypical lymphocytes and an hepatitis with a drop of prothrombin ratio to 65%. He subsequently developed pneumonitis and colitis. A diagnosis of sulfasalazine-induced DRESS was made, and sulfasalazine was discontinued. The patient was treated by intravenous methylprednisolone and intravenous immunoglobulins. Intravenous corticosteroids were changed for oral prednisone (1 mg/kg/d). Visceral manifestations progressively improved. HHV-6B viral load in whole blood was at a high level (23 495 gec/M cells).<sup>5-7</sup> Epstein-Barr virus and cytomegalovirus viral loads measured by PCR remained negative.

Corticosteroids were progressively tapered within 6-month period, and HHV-6 viral load was monitored. The patient developed diarrhea with bloody bowel movement. On February 2010, HHV-6 viral load was high at 32 737 gec/M cells (genomic DNA per million cells). Endoscopy examination and colonic biopsy demonstrated clinical and microscopic features of Crohn's disease (Figure 1). HHV-6B DNA PCR was positive in colonic biopsy (1808 gec/M cells) with high levels of virus encoded sncRNAs (Figure 2). Antivirals were started with a monitoring of HHV-6 viremia. The patient was treated by 14 days of ganciclovir. The whole blood viral load decreased from 7051 to 3675 gec/M cells. HHV-6 DNA test was negative in hair follicles. The colitis manifestations

resolved. Cidofovir treatment was proposed for the treatment of this persistent HHV-6 infection. He received six infusions of 400 mg each without significant effect on HHV-6 viral load (3934 gec/M cells). Six months later, on February 2011, it remained 8061 gec/M cells. Colitis manifestations resumed, and a new endoscopy confirmed luminal stenosis of the transverse colon. At that time, a treatment with TNF alpha blocker (adalimumab) was started. After 8-year treatment with adalimumab, HHV-6 viral load in whole blood remained stable at 905-1084 gec/M cells. The patient did not develop any flare of DRESS. The Crohn's-like colitis was under control.

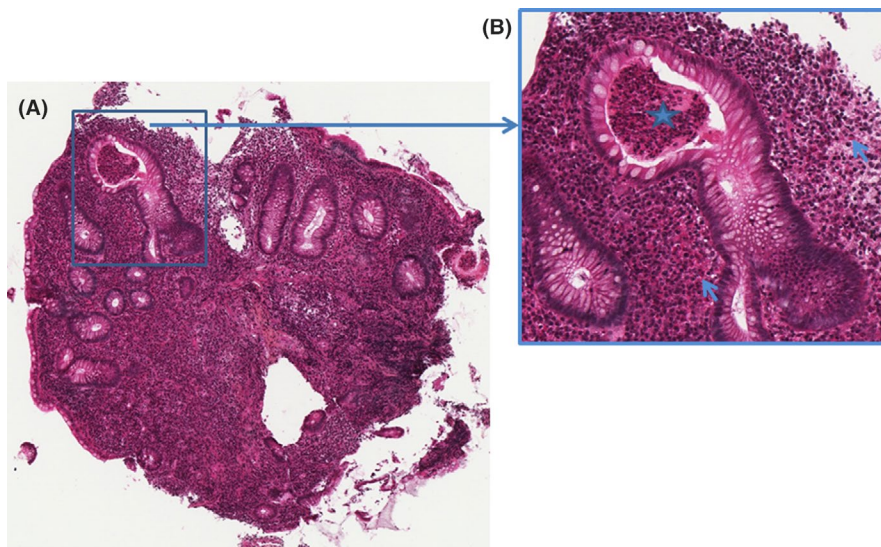
Subsequently, the cellular localization of HHV-6 genome in leukocyte subpopulations was studied by flow cytometry and PCR because the patient had an unusual persistent HHV-6 infection after DRESS. HHV-6 DNA was present only in T lymphocytes fraction with 1212 gec/M cells and was absent from all other fractions (B lymphocytes, monocytes, NK cells, polymorphonuclear cells). Apart from this high HHV-6 load, the patient had no clinical manifestation and all biological tests were normal.

## 3 | DISCUSSION

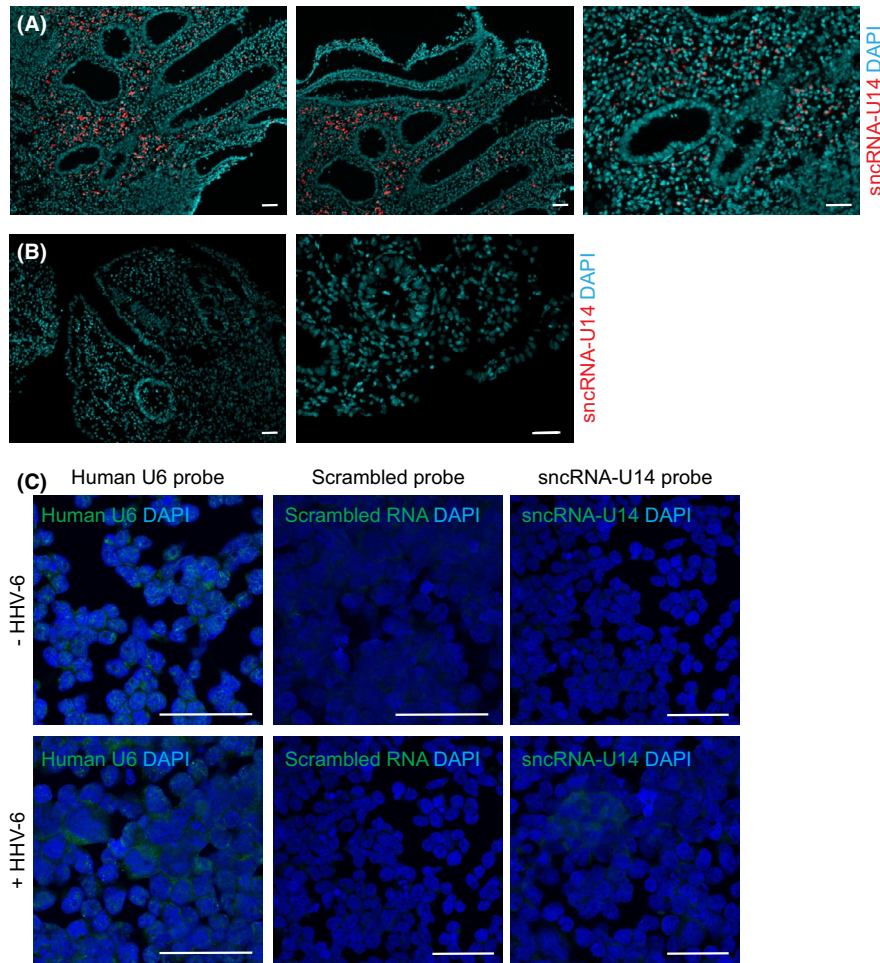
This case illustrates a severe case of sulfasalazine-induced DRESS with Regiscar criteria score of 7 having reactivation of HHV-6B.<sup>9</sup>

HHV-6 is a lymphotropic virus that predominantly infects T-cell lymphocyte. It possesses telomere-like repeats at the terminal regions of its genome that facilitate latency by a unique mechanism of viral latency, integration into the host telomeres, rather than by episome formation. HHV-6 reactivation plays a major role in DRESS syndrome.

This observation is of great interest because the patient had a persistent HHV-6 infection after DRESS and developed a



**FIGURE 1** Histological examination of a biopsy of large intestine. A, Hematein eosin saffron: original magnification x 5: The mucosa contains a dense inflammatory infiltrate with focal crypt architectural distortion. B, Hematein eosin saffron: original magnification x 200: A focal active colitis with crypt abscess formation (star) and numerous lymphocytes and eosinophils (arrow)



**FIGURE 2** Demonstration of transcription of HHV-6 encoded sncRNA-U14 in colon (the study was done on 2019 on stored biopsy samples from 2010). A, Detection of HHV-6 encoded sncRNA-U14 in the colonic biopsy of the DRESS patient. FFPE colonic tissue biopsies were used for the analysis. Three different representative images from different regions of the tissue have been shown. Imaging was done using an epifluorescence microscope. The scale bars represent 100  $\mu$ m. B, Detection of HHV-6 encoded sncRNA-U14 in HHV-6 negative colonic biopsy. Two representative images are shown from different regions of a single biopsy. C, Detection of sncRNA-U14 by FISH in various in vivo cell types. HHV-6A infected HSB-2 cells were used as positive control for sncRNA-U14 FISH analysis. Uninfected HSB-2 cells were used as negative control. Human small RNA U6 was used as a FISH positive control. At the same time, a scrambled small RNA probe was used as a FISH negative control. Imaging was done on a SP5 confocal microscope. The scale bars represent 100  $\mu$ m

Crohn's-like colitis. Relapsing course of DRESS is usual, and flares are frequently associated with short duration HHV-6 reactivations.<sup>1,4</sup> In this case, HHV-6 was regularly detected even a long time after DRESS. Persistent HHV-6 infection was confirmed by a high level of viral DNA in whole blood but HHV-6B being present only in T lymphocytes. The viral loads below 6 log gc/M cells and negative in hair follicles excluded the presence of inherited chromosomally integrated HHV-6. Miyagawa et al recently reported 3 cases of DRESS in which HHV-6 DNA was detected mainly in peripheral T lymphocytes long after resolution of DRESS (until 700 days with HHV-6 viral DNA up to 3 log copies/million cells).<sup>10</sup>

The major point in our case was the demonstration of HHV-6-induced colitis. High HHV-6 DNA load and more interestingly a very high level of viral sncRNA confirmed HHV-6 reactivation in colon (Figure 1,2). Antiviral drugs

induced a control of colitis symptoms but did not significantly decrease HHV-6 viral load in whole blood. It may be possible that the antiviral treatment controlled HHV-6 DNA replication that marks classical active viral infection. However, transient viral reactivation characterized by transcription of HHV-6 sncRNA-U14, in the absence of viral DNA replication, cannot be controlled by current antiherpesvirus drugs that target only the viral DNA replication.<sup>8</sup> The residual HHV-6 viral load possibly represents a latent HHV-6 infection that can persist as episomal or integrated form in T lymphocytes and other cells.

Crohn's disease and more globally inflammatory bowel diseases may be associated with spondylarthritis and stay silent for a long time. Crohn's disease has not been reported as a consequence of DRESS. Patient with Crohn's disease is at risk for the development of DRESS because they are

frequently treated by sulfasalazine or azathioprine which are well known inducers of DRESS. A previous control study did not find evidence of HHV-6 infection in patients with Crohn's disease as compared to the controls.<sup>11</sup> In another study HHV-6B antigen positivity and intensity of immunohistochemistry correlated with endoscopy severity of Crohn's disease.<sup>12</sup> We postulate that HHV-6 could trigger a previous asymptomatic Crohn's disease. In our patient, the Crohn's disease remained and was subsequently treated by TNF alpha blocker without any relapse of DRESS.

## 4 | CONCLUSION

Through this case report, we would like to emphasize on the advantage of new tools (demonstration of HHV6 sncRNA in tissue sample) for the diagnosis of HHV-6 reactivation.

### ACKNOWLEDGMENTS

Informed consent was obtained for this case.

### CONFLICT OF INTEREST

The authors have no conflicts of interest to declare.

### AUTHOR CONTRIBUTIONS

DV: involved in the diagnosis and care of the patient and wrote the manuscript. GDA: involved in the virological tests and their interpretation. PAL: involved in the diagnosis and care of the patient. BP: involved in the virological tests and their interpretation. DL: performed the pathological analysis. PBK: performed the HHV-6 snc-RNA study and its interpretation. All authors: involved in the critical revision and final approval of the manuscript.

### ETHICAL APPROVAL

The article describes a case report. Therefore, no additional permission from our Ethics Committee was required.

### DATA AVAILABILITY STATEMENT

All data that support the findings of this study are included in this case report. Details are available on request from the corresponding author.

### ORCID

Vincent Descamps  <https://orcid.org/0000-0001-6043-6242>

### REFERENCES

- Descamps V, Ranger-Rogez S. DRESS syndrome. *Joint Bone Spine*. 2014;81(1):15-21.
- Shiohara T, Iijima M, Ikezawa Z, Hashimoto K. The diagnosis of a DRESS syndrome has been sufficiently established on the basis of typical clinical features and viral reactivations. *Br J Dermatol*. 2007;156:1083-1084.
- Picard D, Janela B, Descamps V, et al. Drug reaction with eosinophilia and systemic symptoms (DRESS): a multiorgan antiviral T cell response. *Sci Transl Med*. 2010;2:46ra62.
- Tohyama M, Hashimoto K, Yasukawa M, et al. Association of human herpesvirus 6 reactivation with the flaring and severity of drug-induced hypersensitivity syndrome. *Br J Dermatol*. 2007;157:934-940.
- Gautheret-Dejean A, Manichanh C, Thien-Ah-Koon F, et al. Development of a real-time polymerase chain reaction assay for the diagnosis of human herpesvirus-6 infection in bone marrow transplant patients. *J Virol Methods*. 2002;100:27-35.
- Laurendeau I, Bahuau M, Vodovar N, et al. TaqMan PCR-based gene dosage assay for predictive testing in individuals from a cancer family with INK4 locus haploinsufficiency. *Clin Chem*. 1999;45:982-986.
- Boutolleau D, Duros C, Bonnafous P, et al. Identification of human herpesvirus 6 variants A and B by primer-specific real-time PCR may help to revisit their respective role in pathology. *J Clin Virol*. 2006;35:257-263.
- Prusty BK, Gulve N, Chowdhury SR, et al. HHV-6 encoded small non-coding RNAs define an intermediate and early stage in viral reactivation. *NPJ Genom Med*. 2018;3:25.
- Kardaun SH, Sekula P, Valeyrie-Allanore L, et al. Drug reaction with eosinophilia and systemic symptoms (DRESS): an original multisystem adverse drug reaction. Results from the prospective RegiSCAR study. *Br J Dermatol*. 2013;169:1071-1080.
- Miyagawa F, Nakamura Y, Ommori R, et al. Predominant contribution of CD4 T cells to human herpesvirus 6 (HHV-6) load in the peripheral blood of patients with drug-induced hypersensitivity syndrome and persistent HHV-6 infection. *Acta Derm Venereol*. 2018;98:146-148.
- Sura R, Gavrilov B, Flamand L, et al. Human herpesvirus-6 in patients with Crohn's disease. *APMIS*. 2010;118:394-400.
- Sipponen T, Turunen U, Lautenschlager I, Nieminen U, Arola J, Halme L. Human herpesvirus 6 and cytomegalovirus in ileocolonic mucosa in inflammatory bowel disease. *Scand J Gastroenterol*. 2011;46:1324-1333.

**How to cite this article:** Descamps V, Gautheret-Dejean A, Pelletier A-L, Bonnafous P, Descamps L, Prusty BK. Chronic persistent HHV-6B infection after sulfasalazine-induced DRESS with demonstration of HHV-6 encoded small noncoding RNAs (sncRNAs) in Crohn's-like colitis: Case report. *Clin Case Rep*. 2021;9:841–844. <https://doi.org/10.1002/ccr3.3680>