



Management of Immune Checkpoint Inhibitor-Induced Myocarditis The French Working Group's Plea for a Pragmatic Approach

Franck Thuny, Joachim Alexandre, Joe-Elie Salem, Mariana Mirabel, Charles Dolladille, Alain Cohen-Solal, Ariel Cohen, Stéphane Ederhy, Jennifer Cautela

► To cite this version:

Franck Thuny, Joachim Alexandre, Joe-Elie Salem, Mariana Mirabel, Charles Dolladille, et al.. Management of Immune Checkpoint Inhibitor-Induced Myocarditis The French Working Group's Plea for a Pragmatic Approach. JACC: CardioOncology, 2021, 3 (1), pp.157-161. 10.1016/j.jacc.2020.12.001 . hal-03155782

HAL Id: hal-03155782

<https://hal.sorbonne-universite.fr/hal-03155782>

Submitted on 2 Mar 2021

HAL is a multi-disciplinary open access archive for the deposit and dissemination of scientific research documents, whether they are published or not. The documents may come from teaching and research institutions in France or abroad, or from public or private research centers.

L'archive ouverte pluridisciplinaire **HAL**, est destinée au dépôt et à la diffusion de documents scientifiques de niveau recherche, publiés ou non, émanant des établissements d'enseignement et de recherche français ou étrangers, des laboratoires publics ou privés.

VIEWPOINT

Management of Immune Checkpoint Inhibitor–Induced Myocarditis

The French Working Group's Plea for a Pragmatic Approach

Franck Thuny, MD, PhD,^{a,b} Joachim Alexandre, MD, PhD,^c Joe-Elie Salem, MD, PhD,^d Mariana Mirabel, MD, PhD,^e Charles Dolladille, MD,^c Alain Cohen-Solal, MD, PhD,^f Ariel Cohen, MD, PhD,^g Stéphane Ederhy, MD,^g Jennifer Cautela, MD,^{a,b} on behalf of the French Working Group of Cardio-Oncology

Immune checkpoint inhibitor (ICI)-induced myocarditis is one of the most serious complications of cancer treatment. Although the incidence is uncommon, physicians should be aware of this potentially life-threatening immune-related adverse event (irAE) because of a potential case-fatality rate that can, in the most severe cases, approach 50% (1). The prevalence of disease may also increase as a result of the exponential rise in the indication and prescription of ICIs.

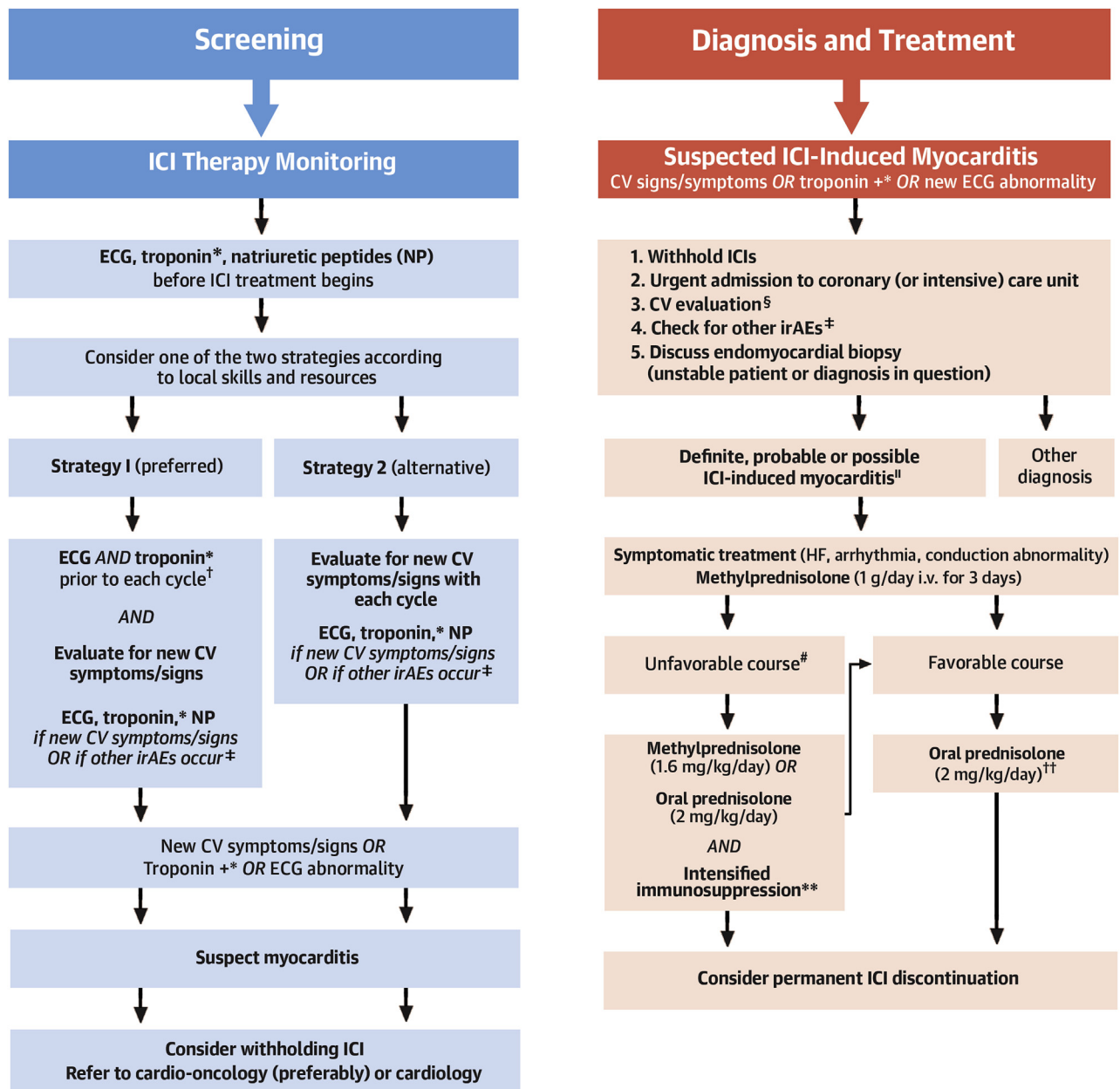
ICI-induced myocarditis is an autoimmune process targeting the myocardium, similar to cellular rejection in heart transplant recipients. It is caused by

restoration of the immune response and up-regulation of CD4+ and CD8+ T cells, which together with macrophages infiltrate and attack myocytes and cardiac conduction tissue (2). Whereas the reported incidence of cardiovascular irAEs was very low in the first trials to study the efficacy of ICIs in melanoma and lung cancers, myocarditis has subsequently emerged as a life-threatening condition, described first in case reports and then in larger case series (1–3). In the Bristol-Myers Squibb safety databases, the initial incidence estimates of ICI-induced myocarditis ranged from 0.06% for monotherapy to 0.27% for combination therapy (2). This incidence was most likely underestimated, considering the lack of a systematic screening policy or well-defined diagnostic criteria for myocarditis when these first therapeutic trials were conducted; it is plausible that several cases of myocarditis were undiagnosed. Subsequent cohorts of patients treated with ICIs have suggested an incidence of myocarditis ranging from 1% to 2%, often occurring early after treatment initiation, following the first few cycles (1).

Patients with ICI-induced myocarditis may not have any prior cardiovascular symptoms or signs, and the first manifestation can be a serious cardiac complication; they are at high risk of ventricular arrhythmias and atrioventricular block despite an often preserved left ventricular ejection fraction (1–3). Moreover, severity of illness and clinical course may exceed imaging findings, leading to underdiagnosis (3). A high index of suspicion and low threshold of investigation are therefore essential in all patients treated with ICIs, especially those on combination therapy. In our view, any cardiovascular symptoms, new appearance of electrocardiographic abnormality,

From the ^aFrench Institute of Health and Medical Research 1263, National Institute of Agricultural Research, Centre for CardioVascular and Nutrition Research, Unit of Heart Failure and Valvular Heart Diseases, Department of Cardiology, University Mediterranean Centre of Cardio-Oncology, Nord Hospital, Assistance Publique-Hôpitaux de Marseille, Aix-Marseille University, Marseille, France; ^bMediterranean Group of Cardio-Oncology, Marseille, France; ^cPICARO Cardio-oncology Program, Department of Pharmacology, Department of Cardiology, Caen Hospital, Medical School, University of Caen Normandy, Caen, France; ^dUNICO-GRECO Cardio-Oncology Program, Centre d'Investigation Clinique Paris-Est, Department of Pharmacology, Pitié-Salpêtrière Hospital, Assistance Publique-Hôpitaux de Paris, Sorbonne University, Paris, France; ^eUnit of Cardio-Oncology and Prevention, European Georges Pompidou Hospital, Assistance Publique-Hôpitaux de Paris, Paris University, Paris, France; ^fUMR-S 942, Department of Cardiology, Lariboisière Hospital, Assistance Publique-Hôpitaux de Paris, Paris University, Paris, France; and the ^gFrench Institute of Health and Medical Research 856, UNICO-GRECO Cardio-Oncology Program, Department of Cardiology, Saint-Antoine Hospital and Tenon Hospital, Assistance Publique-Hôpitaux de Paris, Sorbonne University, Paris, France.

The authors attest they are in compliance with human studies commitments and animal welfare regulations of the authors' institutions and Food and Drug Administration guidelines, including patient consent where appropriate. For more information, visit the [Author Center](#).

FIGURE 1 The French Working Group's Pragmatic Approach for ICI CV Monitoring and Management of ICI-Induced Myocarditis

Continued on the next page

or rise in troponin level should trigger a cardio-oncology consult. Treatment consists of the discontinuation of ICIs, administration of high doses of corticosteroids as first-line therapy, and intensified immunosuppressive therapy initiated as soon as there is indication of an unfavorable clinical course.

U.S. and European guidelines on the diagnosis and management of ICI-associated irAEs have been published recently (4-6). However, the relatively low level of evidence supporting these recommendations has led to numerous discrepancies, leaving clinicians without a consensus strategy to follow.

Regarding the screening strategy for ICI-induced myocarditis, the guidelines recommend that baseline electrocardiography, troponin, and natriuretic peptides testing should be evaluated before starting ICI therapy (especially in patients treated with combination ICIs) (5,6). Whereas some guidelines recommend repeating this evaluation before each infusion in patients treated with combination ICI (6), others recommend that this should be based on the occurrence of cardiovascular symptoms or signs or if non-cardiovascular irAEs occur (5).

On suspicion of ICI-induced myocarditis, the guidelines emphasize that work-up should include troponin and natriuretic peptides testing, a transthoracic echocardiogram, cardiovascular magnetic resonance imaging, and endomyocardial biopsy when possible (4-6). Nevertheless, the diagnosis of ICI-induced myocarditis may not be easy to establish given the frequently normal results in the early phase of the disease. One report suggested normal cardiovascular magnetic resonance findings in up to 70% of patients when performed within 4 days of admission (7). Furthermore, endomyocardial biopsy is not available in all centers. Case reports have suggested a potential role of other imaging modalities such as positron emission tomography. Recently, diagnostic criteria have been published, leading to the classification of ICI-induced myocarditis as definite, probable, or possible based on the results of clinical,

biological, and imaging investigations (8). This classification has yet to be validated in a clinical study.

Regarding the management of patients with a clinical suspicion of ICI-induced myocarditis, guidelines recommend immediate withholding of ICI treatment, urgent admission into a coronary (or intensive) care unit, and prompt investigations to confirm or rule out the diagnosis of myocarditis without delaying the introduction of high-dose corticosteroid treatment. Although early initiation of corticosteroids is associated with improved cardiac outcomes, it remains unclear which treatment should be used when the patient's clinical condition deteriorates despite corticosteroid therapy. According to the disease pathophysiology, it is currently recommended to use therapies similar to those prescribed for acute cellular rejection in transplanted hearts. Nevertheless, this strategy is empiric, and recent case series have suggested the efficacy of drugs such as tocilizumab, abatacept, alemtuzumab, or tofacitinib. Furthermore, the clinical criteria that should lead to the intensification of the immunosuppressive therapy have yet to be precisely defined by further studies.

Regarding the decision on whether to rechallenge ICI therapy, only the American Society of Clinical Oncology guidelines have addressed this issue, and recommend to permanently discontinue ICI treatment regardless of the severity of myocarditis (grades 1 to 4) (6). This recommendation is based on expert

FIGURE 1 Continued

*For monitoring, troponin testing should be carried out by the same laboratory (same assay and method of measurement). Troponin testing is considered positive if troponin I or T is >99th percentile of the upper reference limit. Concomitant myositis may result in significant elevations of creatine kinase (CK), CK isoforms, and even troponin T. Thus, troponin I would be the most specific option for myocardial injury. CK-myocardial band should be used if troponin I measurement is not available. In patients with pre-therapeutic troponin elevation, a 50% increase of the level may be used as a cutoff, but no evidence currently supports this recommendation. †We feel that electrocardiography (ECG) and troponin testing should be performed for at least 6 weeks after initiation of immune checkpoint inhibitor (ICI) therapy because most ICI-induced myocarditis episodes occur after the first cycles. This is a specific strategy suggested by the French Working Group of Cardio-Oncology. We acknowledge that there is a need for greater evidence, and thus far, the data to date do not strongly support this strategy. Moreover, we propose that ECG and troponin are performed within 48 h prior to each cycle. ‡Especially pericarditis, vasculitis, myositis, and myasthenia gravis. Immune toxicities can also affect the skin (maculopapular rash, vitiligo, psoriasis, Lyell syndrome, drug reaction with eosinophilia, and systemic symptoms), the gastrointestinal tract (enterocolitis, gastritis, pancreatitis, celiac disease), the endocrine glands (abnormal thyroid function, hypophysitis, adrenal insufficiency, diabetes), the lungs (pneumonitis, pleural effusion, sarcoidosis), the nervous system (peripheral neuropathy, aseptic meningitis, Guillain-Barre syndrome, encephalopathy, myelitis, meningoradiculoneuritis, myasthenia gravis), the liver (hepatitis), the kidney (granulomatous interstitial nephritis, lupus-like glomerulonephritis), hematological cells (hemolytic anemia, thrombocytopenia, neutropenia, pancytopenia), the musculoarticular system (arthritis, myopathies), the pericardium (pericarditis), the vessels (vasculitis), and the eyes (uveitis, conjunctivitis, blepharitis, retinitis, choroiditis, orbital myositis). §Including ECG, transthoracic echocardiogram, troponin, natriuretic peptides [NPs], CK, CK-myocardial band, and cardiovascular (CV) magnetic resonance imaging. Rule out acute coronary syndrome using coronary angiography or computed tomography according to the clinical context. Consider excluding acute pulmonary embolism. ||According to Bonaca diagnostic criteria (8) and clinical judgment. #Unfavorable course defined as hemodynamic instability OR electrical instability OR increasing troponin OR decreasing left ventricular ejection fraction. **There is a lack of data to recommend a standardized strategy for the intensification of immunosuppressive therapy. For now, case series and case reports have shown the potential efficacy of antithymocyte globulin, intravenous immunoglobulin, plasma exchange, mycophenolate mofetil, tacrolimus, tocilizumab, abatacept, alemtuzumab, and tofacitinib. The decision regarding optimal therapy must be multidisciplinary, involving specialists in immunology and organ rejection. Infliximab was also proposed but was not incorporated into the algorithm because of its contraindication in acute heart failure. ††2 mg/kg/day for 14 days, then 1 mg/kg/day for 14 days and then tapered over 4 to 6 weeks. Consider troponin monitoring at each dose change. i.v. = intravenous; irAE = immune-related adverse event.

consensus and the perceived concern that recurrence would be fatal. On the one hand, clinical trials have demonstrated that patients with noncardiovascular irAEs may have favorable clinical outcomes even after ICI discontinuation (9). Thus, many patients with ongoing stable or responding disease may not need an ICI rechallenge as maintenance therapy. On the other hand, case reports have suggested that a rechallenge might be tolerated in cases of mild irAEs, including low-grade myocarditis.

The low level of evidence supporting the management of ICI-induced myocarditis has not resulted in clear decisional algorithms in the recent guidelines; in our view, clinicians would benefit from pragmatic recommendations to help guide them in their daily practice.

In the face of an uncommon, fatal, but curable disease, should we wait for more evidence before proposing a rapid and standardized management strategy? This question is certainly relevant to ICI-induced myocarditis. We urgently need management protocols—ones that should be updated as knowledge evolves and that should be tailored to specific situations. For now, pending the availability of a higher level of evidence from randomized trials, we have to rely on observational studies and the experience from high-volume centers. A number of screening protocols, based on local expertise, have been suggested.

In an effort to comprehensively harmonize the current guidelines, the French Working Group of Cardio-Oncology recently proposed a different approach (10). This expert panel consisted of cardiologists, oncologists, hematologists, and pharmacologists, who lead regional cardio-oncology programs involved in the daily management of patients with cancer therapy-induced cardiovascular toxicity. The panel analyzed and compared the key components of the pathways recommended in the most recent guidelines from the U.S. and European societies of both oncology and cardiology, then harmonized these consensus statements into practical roadmaps that we feel can be adapted by clinicians for use in daily practice (Figure 1). We fully acknowledge that this is

not based on stronger evidence than that used to establish the guidelines, and it will have to be updated regularly in response to emerging evidence from future studies.

The increasing prescription of ICIs makes it imperative to provide new data to address the following issues related to ICI-induced myocarditis. 1) What are the clinical, biological, and imaging predictors of this complication? 2) Are there predisposing genetic factors? 3) Is it possible to establish a preventive strategy? 4) What are the predictors of poor prognosis? 5) What is the best immunosuppressive therapeutic strategy? 6) Is it possible to rechallenge ICIs in some patients after an episode of myocarditis?

Knowledge of the cardiovascular toxicity associated with cancer immune therapies is increasing, but many uncertainties remain. Cardiologists and oncologists urgently need practical management protocols, which will need to be updated regularly as research and our understanding evolves.

AUTHOR DISCLOSURES

Dr. Thuny has received modest fees for lectures outside the submitted work from Merck Sharp and Dohme, Bristol-Myers Squibb, and Roche. Dr. Alexandre has received modest lecture fees outside the submitted work from Bristol-Myers Squibb. Dr. Salem has received modest fees for serving on advisory boards from Bristol-Myers Squibb; and shares a patent related to the use of CTLA4 agonists for the treatment of severe immune-related adverse reactions. Dr. Cohen-Solal has received fees for lectures or board participation, outside the submitted work, from Merck Sharp and Dohme. Dr. Cohen has received modest consultant and lecture fees outside the submitted work from Bristol-Myers Squibb. Dr. Ederhy has received modest lecture fees outside the submitted work from Bristol-Myers Squibb. Dr. Cautela has received modest lecture fees outside the submitted work from Merck Sharp and Dohme. All other authors have reported that they have no relationships relevant to the contents of this paper to disclose.

ADDRESS FOR CORRESPONDENCE: Dr. Franck Thuny, University Mediterranean Center of Cardio-Oncology, Unit of Heart Failure and Valvular Heart Diseases, North Hospital, Aix-Marseille University, Chemin des Bourrely, 13015 Marseille, France. E-mail: franck.thuny@gmail.com. Twitter: @franckthuny.

REFERENCES

- Mahmood SS, Fradley MG, Cohen JV, et al. Myocarditis in patients treated with immune checkpoint inhibitors. *J Am Coll Cardiol* 2018;71:1755-64.
- Johnson DB, Balko JM, Compton ML, et al. Fulminant myocarditis with combination immune checkpoint blockade. *N Engl J Med* 2016;375:1749-55.
- Escudier M, Cautela J, Malissen N, et al. Clinical features, management, and outcomes of immune checkpoint inhibitor-related cardiotoxicity. *Circulation* 2017;136:2085-7.
- Haanen JBAG, Carbone F, Robert C, et al. Management of toxicities from immunotherapy: ESMO Clinical Practice Guidelines for diagnosis, treatment and follow-up. *Ann Oncol* 2017;28:iv119-42.
- Brahmer JR, Lacchetti C, Schneider BJ, et al. Management of immune-related adverse events in

patients treated with immune checkpoint inhibitor therapy: American Society of Clinical Oncology Clinical Practice Guideline. *J Clin Oncol* 2018;36:1714–68.

6. Pudil R, Mueller C, Čelutkienė J, et al. Role of serum biomarkers in cancer patients receiving cardiotoxic cancer therapies: a position statement from the Cardio-Oncology Study Group of the Heart Failure Association and the Cardio-Oncology Council of the European Society of Cardiology. *Eur J Heart Fail* 2020;22:1966–83.

7. Zhang L, Awadalla M, Mahmood SS, et al. Cardiovascular magnetic resonance in immune checkpoint inhibitor-associated myocarditis. *Eur Heart J* 2020;41:1733–43.

8. Bonaca MP, Olenchock BA, Salem J-E, et al. Myocarditis in the setting of cancer therapeutics: proposed case definitions for emerging clinical syndromes in cardio-oncology. *Circulation* 2019;140:80–91.

9. Postow MA, Chesney J, Pavlick AC, et al. Nivolumab and ipilimumab versus ipilimumab in

untreated melanoma. *N Engl J Med* 2015;372:2006–17.

10. Alexandre J, Cautela J, Ederhy S, et al. Cardiovascular toxicity related to cancer treatment: a pragmatic approach to the American and European Cardio-Oncology Guidelines. *J Am Heart Assoc* 2020;9:e018403.

KEY WORDS cancer, immune checkpoint inhibitors, myocarditis