



**HAL**  
open science

## Hemispheric asymmetries in visual mental imagery

Jianghao Liu, Alfredo Spagna, Paolo Bartolomeo

► **To cite this version:**

Jianghao Liu, Alfredo Spagna, Paolo Bartolomeo. Hemispheric asymmetries in visual mental imagery. *Brain Structure and Function*, 2021, 10.1007/s00429-021-02277-w . hal-03207921

**HAL Id: hal-03207921**

**<https://hal.sorbonne-universite.fr/hal-03207921>**

Submitted on 26 Apr 2021

**HAL** is a multi-disciplinary open access archive for the deposit and dissemination of scientific research documents, whether they are published or not. The documents may come from teaching and research institutions in France or abroad, or from public or private research centers.

L'archive ouverte pluridisciplinaire **HAL**, est destinée au dépôt et à la diffusion de documents scientifiques de niveau recherche, publiés ou non, émanant des établissements d'enseignement et de recherche français ou étrangers, des laboratoires publics ou privés.

## Hemispheric asymmetries in visual mental imagery

Jianghao Liu<sup>1,2</sup>, Alfredo Spagna<sup>3</sup>, and Paolo Bartolomeo<sup>1</sup>

<sup>1</sup> Sorbonne Université, Inserm U 1127, CNRS UMR 7225, Paris Brain Institute, ICM, Hôpital de la Pitié-Salpêtrière, 75013 Paris, France

<sup>2</sup> Dassault Systèmes, Vélizy-Villacoublay, France

<sup>3</sup> Department of Psychology, Columbia University in the City of New York, NY, USA, 10027

Correspondence to:

Paolo Bartolomeo

INSTITUT DU CERVEAU

HOPITAL PITIE-SALPETRIERE

47 BOULEVARD DE L'HOPITAL

CS 21414

75646 PARIS CEDEX 13

paolo.bartolomeo@icm-institute.org

ACKNOWLEDGMENTS. Supported by an ICM post-doctoral fellowship to A.S., and by funding from Dassault Systèmes. P.B. is supported by the *Agence Nationale de la Recherche* through ANR-16-CE37– 0005 and ANR-10-IAIHU-06, and by the *Fondation pour la Recherche sur les AVC* through FR-AVC-017. The authors declare no conflict of interest or competing interests.

## Abstract

Visual mental imagery is the faculty whereby we can “visualize” objects that are not in our line of sight. Longstanding evidence dating back over thirty years has shown that unilateral brain lesions, especially in the left temporal lobe, can impair aspects of this ability. Yet, there is currently no attempt to identify analogies between these neuropsychological findings of hemispheric asymmetry and those from other neuroscientific approaches. Here, we present a critical review of the available literature on the hemispheric laterality of visual mental imagery, by looking at cross-method patterns of evidence in the domains of lesion neuropsychology, neuroimaging, and direct cortical stimulation. Results can be summarized under three main axes. First, frontoparietal networks in both hemispheres appear to be associated with visual mental imagery. Second, lateralization patterns emerge in the temporal lobes, with the left inferior temporal lobe being the most common finding in the literature for endogenously generated images, especially, but not exclusively, when orthographic material is used to ignite imagery. Third, an opposite pattern of hemispheric laterality emerges when visual mental images are induced by exogenous stimulation; direct cortical electrical stimulation tends to produce visual imagery experiences predominantly when applied to the right temporal lobe. These patterns of hemispheric asymmetry are difficult to reconcile with the dominant model of visual mental imagery, which emphasizes the implication of early sensory cortices. They suggest instead that visual mental imagery relies on large-scale brain networks, with a crucial participation of high-level visual regions in the temporal lobes.

In the *new age* (mis)reading of Roger Sperry's work (reviewed by Bartolomeo 2020), the left hemisphere is considered to be the seat of logical, analytic thinking, whereas the right hemisphere would be visual, free, and creative. Such way of thinking naturally suggested a privileged role for the right hemisphere in visual mental imagery. Defined as the capacity to "visualize" things that are not in our direct line of sight, by using our "mind's eye", visual mental imagery can indeed be considered as the most creative among the visual abilities.

Here, we performed a critical review of the available literature on the hemispheric laterality of visual mental imagery, and examined patterns of results in the domains of lesion neuropsychology, neuroimaging, and direct cortical stimulation, by selecting the relevant published literature in English, to the best of our knowledge.

#### Evidence from patients with acquired brain damage

The detailed study of patients with unilateral brain lesions has traditionally provided crucial causal evidence for neural models of cognitive functions (Bartolomeo 2011, Bartolomeo et al 2020, Bartolomeo et al 2017, Broca 1865, Caramazza & McCloskey 1988, Shallice 1988).

Consistent with the *new age* idea of hemispheric specialization, some patients with right hemisphere damage were indeed found to show signs of impaired visual imagery for the left portions of visual mental images (representational or imaginal neglect) (Bartolomeo et al 2005, Bartolomeo et al 1994, Bisiach & Luzzatti 1978, Boursillon et al 2008, Guariglia et al 1993, Rode et al 2010). Reported cases of imaginal neglect typically have right hemisphere lesions.

Despite this evidence, however, there was little empirical support for a general superiority of the right hemisphere in visual mental imagery (Ehrlichman & Barrett 1983).

Indeed, the “new age” view of right hemisphere superiority for visual mental imagery was challenged by subsequent evidence, and a careful consideration of lesion location in patients who developed deficits of visual mental imagery after unilateral strokes led to the discovery of two important patterns. First, contrary to the then prevalent view and to the evidence relative to imaginal neglect, left hemisphere lesions were found to be more likely than right hemisphere damage to impair the generation of visual mental images (Farah 1984). Farah reported about 12 brain-damaged patients with relatively selective visual mental imagery impairment and reasonably preserved visual perception; their lesions predominantly affected the posterior regions of the left hemisphere. Farah subsequently described consistent evidence in normal participants, by demonstrating a lateral asymmetry of the facilitating effect of mental imagery on visual discrimination; facilitation was especially evident for tachistoscopic stimulus presentation in the right visual field (left hemisphere) (Farah 1986). Although less directly relevant for hemispheric asymmetries, the description of two patients with bilateral posterior cerebral lesions (Levine et al 1985) demonstrated dissociated patterns of performance reminiscent of the dorsal/ventral dichotomy in vision (Kravitz et al 2013): a patient with a right temporal / inferior frontal lesion and a smaller left temporo-occipital lesion showed defective description of objects from memory (faces, animals, and colors of objects); another patient, with bilateral parieto-occipital lesions, larger on the left, was impaired in describing spatial relations from memory. The study of two further patients, with surgical resection of the corpus callosum (Kosslyn et al 1985), demonstrated that the left hemisphere in both subjects could inspect imaged patterns and could generate single and multipart images. In contrast, although the right hemisphere could inspect imagined patterns and could generate images of overall shape, it had difficulty in generating multipart images.

The second major contribution from the study of brain-damaged patients confirmed and specified Farah's (1986) discovery of an asymmetry favoring the left hemisphere in image generation, by revealing that visual mental imagery deficits were typically consequent upon extensive damage of the left temporal lobe (review in Bartolomeo 2002). Left temporal lesion location was especially frequent for impaired imagination of object form, size and color, as well as of orthographic material (Bartolomeo et al 2002, Moro et al 2008).

A recent case report of a brain-damaged patient (Thorudottir et al 2020) provided more specific evidence on crucial structures for visual mental imagery in the left temporal lobe. After a bilateral stroke in the territory of the posterior cerebral artery, an architect, who before the stroke could easily imagine objects and buildings, spontaneously reported to have become virtually unable to visualize items. He had now to rely on computer-aided design for his work, because he needed to see items that he could previously imagine. The stroke had provoked extensive damage to the right hemisphere, including the occipital pole, the lingual gyrus, the fusiform gyrus and the parahippocampal region. In the left hemisphere, the lesion was smaller and affected only the medial fusiform gyrus and lingual gyrus. The authors compared the location of his lesions with those of other patients with strokes in the same arterial territory, who experienced normal visual mental imagery. The comparison showed that the architect with impaired imagery had selective damage in the right lingual gyrus and in the left posterior medial fusiform gyrus. The left fusiform lesion is highly consistent with the evidence reviewed above, and further specifies the crucial lesion location within the extensive left temporal damage occurring in most patients with visual mental imagery deficits (Bartolomeo 2002, 2008). Starting from the seminal case of visual agnosia described by Lissauer (see Bartolomeo 2021), patients with more posterior lesions in

the left occipital lobe can instead exhibit well preserved abilities of visual mental imagery (Bartolomeo 2002).

Possible exceptions to the left temporal locus of lesion are the already mentioned condition of imaginal neglect, and visual mental imagery for faces. Imaginal neglect is likely to result from inadequate exploration of the mental scene as a consequence of right hemisphere damage (Bartolomeo et al 2005, Bartolomeo & Chokron 2002, Bartolomeo et al 1994, Boursillon et al 2011, Boursillon et al 2008, Rode et al 2010), and not, as proposed by Bisiach and Luzzatti in their seminal study (Bisiach & Luzzatti 1978), by impaired generation of the left portion of the mental scene (Bartolomeo et al 2005). That the right hemisphere could inspect visual mental images had already been suggested by the previously mentioned evidence on split-brain patients (Kosslyn et al 1985).

Concerning face imagery, the anatomical evidence is unfortunately scanty. Lesion location in these cases might affect both temporal lobes, with a possible preference for the right temporal cortex (Etcoff et al 1991). Interestingly, a patient who experienced an isolated, vivid face hallucination followed by intense headache was later shown to have developed a hemorrhage in the rostral two-thirds of the right temporal lobe (Cohen et al 1992). In healthy participants, VanRullen and Reddy (2019) were able to decode the identity of imagined faces from the BOLD response of temporal voxels, but not from occipital or frontoparietal voxels. Unfortunately, hemispheric laterality was not assessed in this study.

Thus, the bulk of evidence from brain-damaged patients indicates that left temporal damage is usually present in patients with defective visual mental imagery for object form or color, and for orthographic material.

## Evidence from neuroimaging

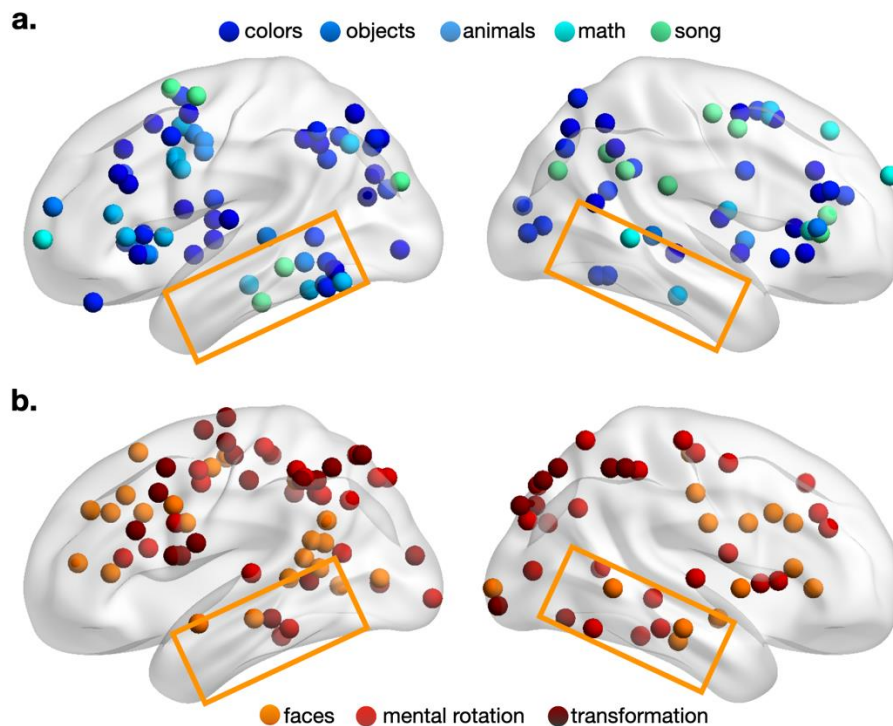
Results from the past twenty years of functional magnetic resonance imaging (fMRI) studies on endogenous visual mental imagery in healthy individuals have been recently summarized in a meta-analysis (Spagna et al 2021). A re-examination of the patterns of hemispheric laterality observed in the fMRI literature combined with positron emission tomography studies shows evidence that is consistent with the neuropsychological evidence described above. These findings can be summarized around three main lines. First, consistent activation occurs in *left*-hemisphere areas, mostly including the temporal lobe, in tasks requiring subjects to endogenously build mental images of the following items: inanimate things (e.g., object, tools)(Belardinelli et al 2009, Handy et al 2004, Lambert et al 2002, Mazard et al 2005), animate items (e.g., animals) (Thompson-Schill et al 1999), concrete objects (D'Esposito et al 1997, Mazard et al 2005, Yomogida et al 2004), single letters (Gulyás 2001, Stokes et al 2009), mathematical operations (Pyke et al 2017), the content of a sentence (Belardinelli et al 2009), a song (Boly et al 2007), or a familiar melody (Zvyagintsev et al 2013), or the ordinal time of historical events (Gauthier et al 2020). Exceptions to this general left-hemisphere pattern are a right inferior temporal lobe activation found for familiar objects (Boccia et al 2015, Mellet et al 2000), and right parietal activation associated with the presentation of a written word (Daselaar et al 2010).

Second, activation of the *right* inferior temporal lobe was described in tasks requiring to imagine or describe a face, with emotional facial expression (Kim et al 2007), or without it (e.g., Boly et al 2007, Zeman et al 2010), or to imagine the color and size of objects (Kellenbach et al 2001). Also, tasks tapping on the visuospatial component (e.g., the mental rotation required by Shepard and Metzler (1971), or the Mental Clock task) rely on the activation of the right medial temporal lobe (including the fusiform gyrus)(Barnes et al 2000, Creem-Regehr



et al 2007, Dhindsa et al 2014, Jordan et al 2001). Yet, Lamp et al (2016) showed *left* fusiform gyrus activation associated with imagined motion, while Goebel et al (1998) found bilateral frontal and parietal activation associated with motion imagery. Frontal (Boccia et al 2015, Trojano et al 2000), and parietal (Bien & Sack 2014) activation lateralized to the right hemisphere was also observed in studies using a modified version of the mental clock task (but see (Sasaoka et al 2014) for left-parietal activation associated with mental transformation). The right hippocampus participates to the imagination of the spatial aspects of a city (Gauthier et al 2020).

Third, irrespectively of the content of imagination, or of the modality used to instruct participants, the generation and maintenance of visual mental images is associated with a large-scale, mostly *bilateral* frontoparietal network, including frontal eye field, inferior and superior parietal lobules, anterior cingulate/supplementary motor area and anterior insula (Boccia et al 2015, Boly et al 2007, Daselaar et al 2010, Formisano et al 2002, Ganis et al 2004, Gardini et al 2005, Goebel et al 1998, Guillot et al 2009, Kilintari et al 2016, Kukolja et al 2006, Logie et al 2011, Newman et al 2005, Whittingstall et al 2014, Zvyagintsev et al 2013). **Figure 1** depicts the coordinates obtained by studies that observed left-lateralized (a) or right-lateralized (b) activation associated with endogenous visual mental imagery, with a color-coding scheme representing which category of stimuli was used in the study.



**Figure 1.** a) Activation foci reported in the functional neuroimaging studies reviewed here, which showed either a left-lateralized pattern of activity in the inferior temporal lobe (a), or a right-lateralized one (b).

The existence of domain-preferring regions in the ventral temporal cortex, as discussed for example by Mahon and Caramazza (2011), and supporting the organization of object knowledge in the ventral visual cortical stream (Kravitz et al 2013), seems to be preserved in mental imagery, as already suggested by the above-mentioned case studies by Levine et al (1985). However, neuroimaging data on this regard is still insufficient to draw a clear-cut organizing equivalence between the two processes. For example, Ishai et al (2000) showed that the perception of visual stimuli such as houses and faces activated clusters located in the right ventrotemporal cortex, but imagery of the same type of stimuli was observed in the contralateral homologous areas. Similar effects were found by O'Craven and Kanwisher (2000), with mid-fusiform activation occurring bilaterally in face perception, but being restricted to the right hemisphere during face imagery. Further, Ganis and Schendan

(2008) showed the existence of a right-lateralized pattern of activation associated with both perception and imagery of faces, but perception and imagery were associated with opposite patterns of event-related potentials (N170) recorded from an occipitotemporal site: N170 decreased with face perception, but increased with face imagery.

Concerning the mental imagery of color, Howard and colleagues showed activation in right rostral fusiform gyrus, right hippocampus, parahippocampal gyrus and left insula (Howard et al 1998), whereas color perception was associated with activity in the bilateral caudal fusiform gyrus and V1. The decoding accuracy between perception and imagery of letters was significantly above chance level for the anterior-lateral occipital complex, a region partially overlapping with the Fusiform Imagery Node (FIN) identified in the left fusiform gyrus by our recent meta-analysis (Spagna et al 2021, see also Stokes et al 2009). The activation of the left fusiform gyrus was also observed in the study of imagery of objects such as a candle by Belardinelli et al (2009), while perception of the candle produced bilateral occipitotemporal activation. Adjacent cortical areas in the temporal lobe activated differently in visual imagery and in perception, in the left hemisphere for letters (Hamamé et al 2012), or bilaterally for scenes (Steel et al 2020). In line with this evidence, while temporal neurons selectively altered their firing rates for specific domains like faces, scenes, both on perception and imagery, there were also neurons selectively activated by either vision or imagery (Kreiman et al 2000).

Overall, the most consistent results in the literature seem to indicate an involvement of the left fusiform gyrus in visual mental imagery. Left fusiform activation occurs especially, but not exclusively, when orthographic material is used to instruct on which item to imagine. Further regions consistently activated in endogenous visual mental imagery are bilateral frontoparietal networks, as also shown by the various meta-analyses conducted over the years

(Hawes et al 2019, McNorgan 2012, Spagna et al 2021, Winlove et al 2018). The literature indicating a right hemisphere lateralization for the spatial components of imagery, or for the imagery of faces, seems to be less conspicuous, and constitutes a line of inquiry that deserves further effort.

#### Evidence from direct cortical stimulation

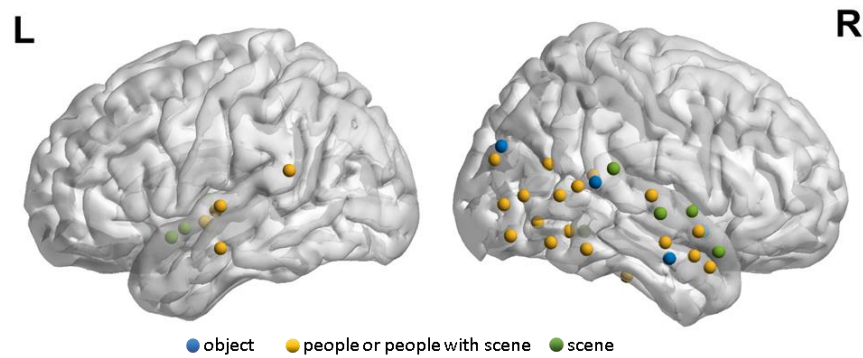
The observation of epileptic patients during crises, or when undergoing direct electrical stimulation over the exposed cerebral cortex, revealed an additional layer of information about the potential involvement of cortical regions in visual mental imagery.

About a century ago, the British neurologist John Hughlings Jackson observed that seizures arising in the temporal lobe may result in a 'dreamy state' (Hughlings Jackson 1931). This phenomenon consisted of both vivid hallucinations of scenes and a feeling of 'reminiscence' that current experience was a repetition of something already lived (*déjà vu*) (Hughlings Jackson 1888). Jackson described the occurrence of dreamy states in a patient with probable right temporal abscess or tumor, and proposed that dreamy states arise from abnormal discharges in the hippocampal uncus (Hughlings Jackson & Stewart 1899).

Later, the seminal work of Wilder Penfield demonstrated that dreamy states could be evoked by direct electrical stimulation of the lateral temporal neocortex in the absence of any task requirement. A first case of stimulation in an epileptic patient during neurosurgery induced what Penfield labeled as *experiential responses*, consisting in hallucinations of things previously seen, heard or experienced, which had occurred regularly as part of the patient's seizure pattern (Penfield 1938). During the following years, Penfield and colleagues performed similar operations on 1,132 patients, most of whom suffered from seizures. Experiential responses occurred in 40 of these patients (Penfield & Perot 1963). Penfield and his co-workers classified the experiential responses into four groups of 'interpretive

illusions': *déjà vu*, auditory, visual, and emotional illusions (Mullan & Penfield 1959).

Importantly, direct cortical stimulation produced experiential responses exclusively when applied to the temporal neocortex, with a greater number of responses arising from stimulation of the *right* temporal lobe. In visual experiential responses, patients reported seeing a recognizable object, a scene, a person or group of people upon stimulation (**Figure 2**). The responsive points were scattered throughout the temporal lobe of the right hemisphere, especially in its caudal portion, whereas on the left side there were only a few responses on the lateral temporal surface. In the right hemisphere, there was a remarkable collection of points in the caudal temporal areas, with some of them laying quite close to the border between the temporal and occipital lobes. A striking delimitation pattern involving a sharp transition in patients' responses was observed when stimulating the visual sensory areas (Brodmann areas 17, 18, 19) vs more rostral regions: responsive sites on the occipital cortex produced colored flashes of light or stars; however, by moving the electrode only a few millimeters rostrally in the temporal lobe, the visual flashes of colored lights gave way to a scene, or the sudden appearance of a familiar person. More recently, Schulz and colleagues (Schulz et al 2007) observed a similar effect in the left hemisphere: stimulating a site of the lateral middle occipital gyrus at the junction with the temporal and parietal lobes evoked a vivid and moving cartoon figure, whereas the stimulation of close, more caudal electrodes produced only typical elementary illusions. The wealth of detail and the sense of immediacy, or vividness, which goes with these hallucinatory experiences, set them apart from the ordinary process of recall that rarely display such qualities. Nevertheless, none of Penfield's patients has ever confused the hallucination with reality, except for brief moments. Further, some patients reported that visual hallucinations were subjectively different from dreams (Bancaud et al 1994).



**Figure 2.** Sites of visual experiential responses produced by electrical stimulation in the studies by Penfield and colleagues [redrawn from (Penfield & Perot 1963)].

In line with the discovery from Penfield and colleagues, many subsequent studies confirmed that complex visual hallucinations mostly involved inferior/middle temporal, temporo-occipital and temporo-parietal structures, predominantly in the right hemisphere, whereby patients reported visual experience like seeing faces, geometric shapes, colors or scenes (Jonas et al 2014, Selimbeyoglu & Parvizi 2010). For example, stimulating a site of the right rostral fusiform gyrus induced the perception of a face (Penfield & Perot 1963), consistent with the above-mentioned evidence from brain damage (Cohen et al 1992) and fMRI decoding (VanRullen & Reddy 2019). Allison et al (1994) identified face-preferring regions in the bilateral fusiform and inferior temporal gyri during face perception tasks; stimulation of these sites produced facial hallucinations (Puce et al 1999), with patients reporting detailed imagery of single or multiple faces or face parts. In line with this evidence, electrical stimulation of a face-preferring area in the right rostral fusiform gyrus could also evoke a transient inability to name familiar faces (Jonas et al 2015). Further, Jonas and colleagues found that complex meaningful shapes were almost exclusively evoked by stimulation in the right hemisphere; this hemispheric asymmetry for evoking a visual

phenomenon increased along the caudo-rostral axis in the occipito-temporal ventral cortex (Jonas et al 2014). Subjective perception of color was elicited by stimulating a right fusiform region (as early as area V4), consistent with the results of a fMRI color task (Murphey et al 2009). The right parahippocampal gyrus was engaged in seeing scenes, as indicated by consistent results from fMRI, intracranial EEG and electrical stimulation (Mégevand et al 2014). A patient with left parietotemporal lesion had epilepsy-related visual hallucinations of written words (Rousseaux et al 1994), with abnormal electrical activity over left posterior temporal and anterior parietal areas. After epileptic seizures, the patient described the perception of isolated words written in black letters and referring to animals or objects.

The role of medial temporal lobe (MTL) in generating dreamy states is still debated. Penfield rejected Hughlings Jackson's localization of dreamy state to the medial temporal lobe, because his colleagues failed to evoke them by stimulating the uncus (Jasper & Rasmussen 1958). However, subsequent studies confirmed that stimulation on the rostral medial temporal structures, bilaterally, elicited complex feelings as familiarity, illusion of dream-like state, recall of past experiences and complex visual hallucinations (Gloor et al 1982, Vignal et al 2007). Importantly, Gloor and colleagues found that activation of limbic structures (recorded by intracerebral EEG) was necessary to produce experiential phenomena either in the course of a spontaneous seizure or through stimulation (Gloor et al 1982). Complex visual hallucinations were elicited by stimulating limbic structures, but not neocortical regions. Further, Bancaud and colleagues proposed that both lateral temporal neocortex and MTL were involved in evoking dreamy states (Bancaud et al 1994). Consistent with the Gloor et al's results, the authors found that it was more efficient to elicit visual experiential responses by stimulating the MTL (i.e., anterior hippocampus or amygdala), compared with temporal neocortical sites. The stimulation-evoked discharge tended to

spread from MTL to temporal neocortex, rather than in the opposite direction. No dreamy state was evoked from stimulation of the left lateral cortex in this study. However, in a single patient, stimulating the left lateral temporal cortex after ipsilateral medial temporal lobe resection (including complete left hippocampectomy), still evoked complex auditory hallucination (Moriarty et al 2001). A possibility proposed by the authors is that memory might have undergone some plasticity or restructuring of its neural substrates, by moving away from the medial temporal lobe due to sclerosis; alternatively, the stimulation retrieved some residual memory from the right hippocampus. More generally, however, it must be noted that phenomena of hemispheric asymmetry are typically evident at the population level (Bartolomeo & Seidel Malkinson 2019), and that single case reports are to be considered with caution in this domain (Bartolomeo et al 2017).

Thus, stimulation outside the temporal lobe rarely elicits complex visual hallucinations, with some exceptions to this rule occurring with stimulation of the prefrontal cortex (Andelman-Gur et al 2019, Andelman-Gur et al 2020, Blanke et al 2000, Vignal et al 2000). Blanke et al (2000) reported that two patients showed visual dream-like feeling after stimulation of the left frontal cortex. The induced phenomena showed different spatial organization based on the localization of the stimulation; stimulation of the inferior frontal gyrus led to hallucinations in the whole visual field, whereas complex visual responses elicited by stimulation on the middle frontal gyrus were restricted to the right visual field. Vignal et al (2000) described face-related hallucinations, subjectively reported as a rapid succession of portrait-like faces, upon stimulation of the right anterior-inferior frontal gyrus / anterior-inferior temporal sulcus. In the same patient, subsequent cortectomy of the right ventral prefrontal regions resulted in a severe deficit in the recognition of emotional facial expression (Marinkovic et al 2000). Anderman-Gur and colleagues found responsive sites that were



widely dispersed in the right hemisphere, from frontal areas to temporo-occipital regions, whereas in the left hemisphere they were more tightly clustered (Andelman-Gur et al 2019). The authors also described a single patient whose responsive sites were located in distant anatomical regions of the right hemisphere (the frontal lobe and inferior occipital gyrus), suggesting a potential involvement of white matter tracts in provoking hallucinatory responses. Recently, the same research group elicited complex visual hallucinations in a group of nineteen epilepsy patients by stimulating the inferior fronto-occipital fasciculus. Stimulation of the bilateral orbito-frontal white matter tracts in two patients induced complex visual hallucinations of scenes, people and faces (Andelman-Gur et al 2020).

In contrast, stimulation of the bilateral posterior occipital lobe usually elicits simple visual sensations such as seeing simple patterns, white or black spots or phosphenes (Dobelle & Mladejovsky 1974), geometric shapes or colors (Selimbeyoglu & Parvizi 2010), with no complex visual hallucinations; stimulation of peristriate cortex or of the parieto-occipital junction produced a visual sensation of geometric shapes like triangles, diamonds, or stars (Lee et al 2000, Murphey et al 2009). Visual sensation of color was generated primarily by stimulating the posterior striate cortex and inferior occipital lobe (Farrell et al 2007, Lee et al 2000), while stimulation of cuneate gyrus evoked lights without colors (Allison et al 1993).

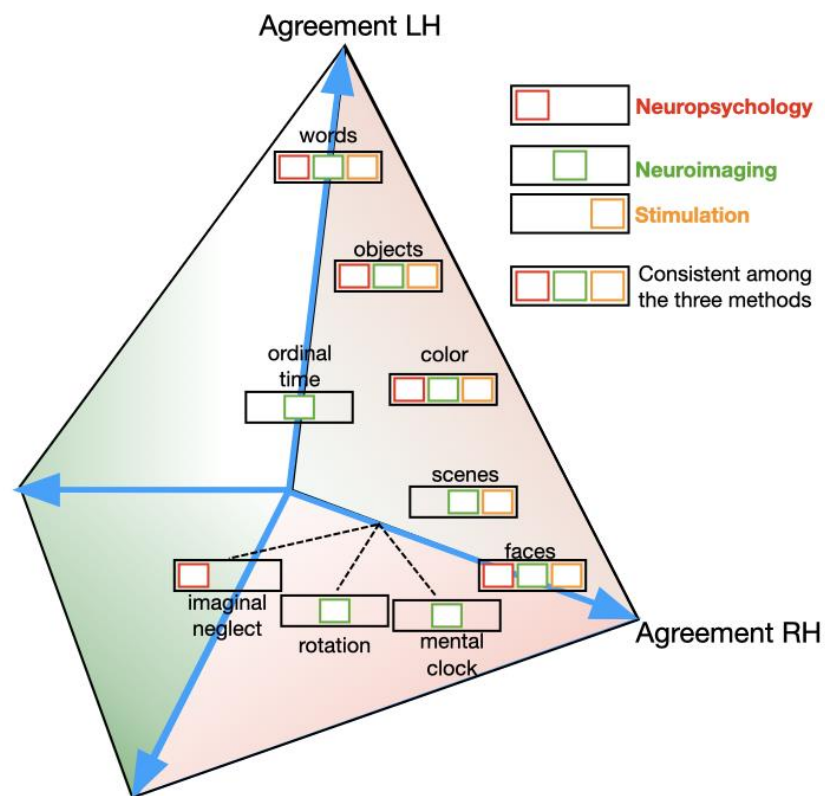
To summarize, evidence from direct cortical stimulation suggests the existence of large-scale brain networks including prefrontal, lateral temporal neocortex, and medial temporal structures, as the substrate of vivid complex visual hallucination, with an asymmetry favoring the right over the left hemisphere for such exogenously provoked mental images. Similar experiences could be evoked by stimulating different nodes within this distributed and interconnected functional network (Fish et al 1993, Selimbeyoglu & Parvizi 2010). Medial temporal activation, involving the bilateral rostral hippocampi and the amygdalae, may add

an affective dimension to the sensory content processed by the temporal neocortex, or endow them with experiential immediacy (Gloor et al 1982). The sharp transition of visual experience, from simple to complex objects, which occurs across the temporo-occipital junction, in both hemispheres (Penfield & Perot 1963, Schulz et al 2007), is consistent with the well-known cortical hierarchy from elementary to increasing levels of complexity in the processing of visual information. Importantly, however, subjective experiences in hallucination induced by stimulation were clearly distinguished from real visual input and from dreams, which might suggest separate functional mechanisms for these different visual experiences.

## Discussion

In the present study, we reviewed evidence regarding hemispherical asymmetries in visual mental imagery, drawing from the neuropsychological, neuroimaging, and stimulation literature. We highlight patterns of hemispheric asymmetry that hardly reconcile with the dominant model of visual mental imagery, which stresses the implication of early visual cortex. Rather, visual mental imagery seemed to rely on large-scale brain networks, with a striking pattern of lateralization in endogenous visual mental imagery, especially regarding the involvement of the left inferior temporal lobe (as shown in **Figure 3** and **Table 1**). Altogether, lesion and neuroimaging studies indicate a striking pattern of lateralization in endogenous visual mental imagery, with the left inferior temporal lobe being one of the regions more consistently observed. More specifically, a candidate area might be the FIN (Bartolomeo et al 2020, Spagna et al 2021). When imagery was prompted by word-like stimuli (words, letters, songs, and national anthems among many others) the role of the left fusiform gyrus held in the great majority of the studies. On the other hand, the right inferior temporal lobe seems to be important the visuospatial aspects of mental imagery, whether mental rotation or navigation, or with face perception, as shown by both

neuroimaging and stimulation literature. Yet, the literature on the necessity of right inferior temporal lobe in visuospatial imagery and imagery of faces is less conspicuous, and therefore conclusions need to be drawn with caution. Also, a right hemisphere advantage emerged when visual mental images were exogenously induced by electrical stimulation. Interestingly, the occipital lobes did not seem to have a cardinal role in any of the three realms investigated. Therefore, the evidence reviewed here seems to be incompatible with the classical model of visual mental imagery (Kosslyn et al 2006, Pearson 2019), because (i) bilateral damage or resection of the occipital lobe does not typically produce a deficit in mental imagery (Bartolomeo 2002); (ii) Bayesian analysis of meta-analytic evidence indicated that visual mental imagery does not require the activation of the occipital lobe (Spagna et al 2021); and (iii) stimulating the temporal cortex results in a subjective experience of a complex visual scene or objects, while stimulation of the occipital cortex produces more elementary visual experiences such as phosphenes (Dobelle & Mladejovsky 1974).



**Figure 3.** Dimensional spatial embedding of the agreement of laterality patterns of visual mental imagery towards the left hemisphere (LH) or the right hemisphere (RH), across the three research approaches: neuropsychology (13 studies, red), neuroimaging (33 studies, green), stimulation (26 studies, orange). Distance along the axes indicates the degree of agreement and was obtained by summing votes from each approach as (left, right) coordinates. A research approach showing clear signs of hemispheric asymmetry (see Table 1) yielded one vote. A half vote (0.5) corresponded to evidence of bilateral hemispheric implication; unclear/unknown evidence was given a 0 vote. The closer an item is to the axis, the more hemispheric asymmetry was found (e.g., words for LH). Items showing equal distance from LH and RH axes feature low agreement for lateralization (e.g., color).

**Table 1.** Summary of hemispheric preference in temporal lobe

	Approach		
	Neuropsychology	Neuroimaging	Stimulation
<b>objects</b>	left IT	left IT	right LT/IT
<b>colors</b>	left IT	bilateral IT	right LT/IT
<b>faces/people</b>	right IT	right IT, bilateral MT	right LT/IT, bilateral MT
<b>words/letters</b>	left IT	left IT	left LT
<b>imaginal neglect</b>	right LT	/	/
<b>scenes</b>	/	bilateral MT	right LT, right MT
<b>rotation</b>	/	right IT	/
<b>mental clock</b>	/	right IT/MT	/
<b>ordinal time</b>	/	left MT	/

Note: IT = inferior temporal; LT = lateral temporal; MT = medial temporal. "/" = Unknown

Evidence from direct cortical electrical stimulation did not show any hemispheric asymmetry in low-level visual areas or in the medial temporal lobe. However, there was substantial evidence for right hemispheric lateralization in the lateral temporal neocortex in the emergence of stimulation-evoked complex visual hallucinations (Jonas et al 2014, Penfield & Perot 1963). In contrast, neuroimaging evidence and cases of brain-damaged patients are sharply in favor of the role of the left temporal lobe in building endogenous visual mental images (Bartolomeo 2002, Spagna et al 2020a). This dramatic difference might be consistent with a basic pattern of asymmetry highly conserved during evolution, which assigns to the left hemisphere well-established behavioral patterns in familiar, routine situations, whereas the right hemisphere takes control of responses to novel, unpredicted and potentially dangerous changes in the environment (Bartolomeo & Seidel Malkinson 2019, Vallortigara & Versace 2017). In this view, which remains speculative, electrical stimulation might be akin to encountering an unexpected external event, and thus primarily recruit right hemisphere networks. A role of right hemisphere networks in rapidly dealing

with urgent, unanticipated situations might be sustained by the generally richer white matter connections in comparison with the left hemisphere (Iturria-Medina et al 2011). These abundant white matter tracts might facilitate fast parallel visuospatial information processing when facing exogenous stimulation.

Another possible reason for the observed left-right asymmetries in visual mental imagery might reside in hemispheric differences in processing semantic knowledge during the endogenous recall of past experience, where the left hemisphere more efficiently performs highly discriminating ‘fine’ encoding (Reilly et al 2015), and gains access to contextual, associative information in semantic processing (Deacon et al 2004, Grose-Fifer & Deacon 2004). A recent, revised model of visual mental imagery (Spagna et al 2021) proposed the existence of a core imagery network built upon the left FIN node. During imagery, this node would get semantic information from rostral regions of the left temporal lobe (Lambon Ralph et al 2017). Dysfunctional connectivity of the visual mental imagery network with domain-preferring regions in the ventral temporal cortex might result in selective forms of visual mental imagery impairment, for example for orthographic material (Bartolomeo et al 2002). Dysfunctional connectivity of this core left hemisphere network with frontoparietal networks in the right hemisphere might instead provoke imaginal neglect (Rode et al 2010).

In this review, we examined three different sources of evidence: patients with brain damage, neuroimaging in neurotypical individuals, and neurostimulation in epileptic patients. Findings from patients with brain damage provide irreplaceable causal evidence on the relevant functions (Bartolomeo et al 2020), which helps to disentangle correlative versus causal signals (Bassett et al 2020). Concerning visual mental imagery, with its important inter-individual differences, it has been argued that evidence from brain-damaged patients would not be causal, because patients cannot be tested before the lesion occurs (Pearson

2020). If a patient had poor visual mental imagery before the stroke, then one might mistakenly attribute the impaired mental imagery to the brain lesion. Contrary to this hypothesis, however, patients with acquired aphantasia after left temporal damage often spontaneously complain to have lost their previous abilities (see, e.g., Thorudottir et al 2020). On the other hand, it is difficult to see how the premorbid state of visual mental imagery could influence the performance of patients with damage restricted to the occipital cortex and *preserved* visual mental imagery (Bartolomeo et al 1998). Another potential confound could result from reorganization of function in patients with brain damage. Several control steps can be taken to deal with this complex issue, such as replication in other similar patients, or estimation of how the patient's premorbid neurocognitive profile (excluding visual mental imagery) is representative of the general population (Bartolomeo et al 2017). Importantly, moreover, evidence from neurotypical individuals, such as the neuroimaging evidence reviewed here, is reassuring in showing a converging pattern of results implicating the left temporal cortex and not the occipital cortex. This neuroimaging evidence is correlative in nature but does not suffer from the potential confounds mentioned above. Finally, neurostimulation in patients with drug-resistant epilepsy is yet another source of causal evidence, with greater spatiotemporal resolution than the other approaches. While also in these patients there could be some reorganization of function, this is unlikely to have influenced the extremely robust pattern of results reviewed here, again indicating the implication of temporal cortex in visual mental imagery.

In conclusion, evidence from different research approaches, such as lesion neuropsychology, neuroimaging, and direct cortical stimulation, converges in stressing an important role of bilateral frontoparietal networks in initiating and maintaining visual mental imagery. Activity in frontoparietal systems seems to be independent of the imagery domain,

in line with recent evidence showing the role of this bilateral network in implementing supra-modal and supra-domain attention and working memory mechanisms (Spagna et al 2015, Spagna et al 2020b, Wu et al 2020). The evidence we reviewed also highlights the role of domain-preferring regions in the ventral temporal cortex, which may act as an interface with stored information in long-term memory. These temporal regions show varying patterns of hemispheric asymmetry depending both on the nature of the imagined items (e.g., words vs. faces), and on the type of visual mental imagery (endogenous vs. exogenous).



## References

- Allison T, Begleiter A, McCarthy G, Roessler E, Nobre AC, Spencer DD. 1993. Electrophysiological studies of color processing in human visual cortex. *Electroencephalography and Clinical Neurophysiology/Evoked Potentials Section* 88: 343-55
- Allison T, Ginter H, McCarthy G, Nobre AC, Puce A, et al. 1994. Face recognition in human extrastriate cortex. *Journal of neurophysiology* 71: 821-5
- Andelman-Gur MM, Gazit T, Andelman F, Kipervasser S, Kramer U, et al. 2019. Spatial distribution and hemispheric asymmetry of electrically evoked experiential phenomena in the human brain. *J Neurosurg*: 1-9
- Andelman-Gur MM, Gazit T, Strauss I, Fried I, Fahoum F. 2020. Stimulating the inferior fronto-occipital fasciculus elicits complex visual hallucinations. *Brain Stimulation: Basic, Translational, and Clinical Research in Neuromodulation* 13: 1577-9
- Bancaud J, Brunet-Bourgin F, Chauvel P, Halgren E. 1994. Anatomical origin of déjà vu and vivid 'memories' in human temporal lobe epilepsy. *Brain* 117 ( Pt 1): 71-90
- Barnes J, Howard RJ, Senior C, Brammer M, Bullmore ET, et al. 2000. Cortical activity during rotational and linear transformations. *Neuropsychologia* 38: 1148-56
- Bartolomeo P. 2002. The relationship between visual perception and visual mental imagery: a reappraisal of the neuropsychological evidence. *Cortex* 38: 357-78
- Bartolomeo P. 2008. The neural correlates of visual mental imagery: an ongoing debate. *Cortex* 44: 107-8
- Bartolomeo P. 2011. The quest for the 'critical lesion site' in cognitive deficits: problems and perspectives. *Cortex* 47: 1010-2
- Bartolomeo P. 2020. *Penser droit*. Paris: Flammarion
- Bartolomeo P. 2021. Visual agnosia and imagery after Lissauer. *Brain* in press
- Bartolomeo P, Bachoud-Lévi A-C, Azouvi P, Chokron S. 2005. Time to imagine space: a chronometric exploration of representational neglect. *Neuropsychologia* 43: 1249-57
- Bartolomeo P, Bachoud-Lévi AC, Chokron S, Degos JD. 2002. Visually- and motor-based knowledge of letters: evidence from a pure alexic patient. *Neuropsychologia* 40: 1363-71
- Bartolomeo P, Bachoud-Lévi AC, de Gelder B, Denes G, Dalla Barba G, et al. 1998. Multiple-domain dissociation between impaired visual perception and preserved mental imagery in a patient with bilateral extrastriate lesions. *Neuropsychologia* 36: 239-49
- Bartolomeo P, Chokron S. 2002. Can we change our vantage point to explore imaginal neglect? (Commentary on Pylyshyn: Mental imagery: In search of a theory). *Behavioral and Brain Sciences* 25: 184-5
- Bartolomeo P, D'Erme P, Gainotti G. 1994. The relationship between visuospatial and representational neglect. *Neurology* 44: 1710-4
- Bartolomeo P, Hajhajate D, Liu J, Spagna A. 2020. Assessing the causal role of early visual areas in visual mental imagery. *Nat Rev Neurosci* 21: 517
- Bartolomeo P, Seidel Malkinson T. 2019. Hemispheric lateralization of attention processes in the human brain. *Current Opinion in Psychology* 29C: 90-6
- Bartolomeo P, Seidel Malkinson T, de Vito S. 2017. Botallo's error, or the quandaries of the universality assumption. *Cortex* 86: 176-85
- Bassett DS, Cullen KE, Eickhoff SB, Farah MJ, Goda Y, et al. 2020. Reflections on the past two decades of neuroscience. *Nature Reviews Neuroscience*: 1-11

- Belardinelli MO, Palmiero M, Sestieri C, Nardo D, Di Matteo R, et al. 2009. An fMRI investigation on image generation in different sensory modalities: the influence of vividness. *Acta psychologica* 132: 190-200
- Bien N, Sack AT. 2014. Dissecting hemisphere-specific contributions to visual spatial imagery using parametric brain mapping. *NeuroImage* 94: 231-8
- Bisiach E, Luzzatti C. 1978. Unilateral neglect of representational space. *Cortex* 14: 129-33
- Blanke O, Landis T, Seeck M. 2000. Electrical cortical stimulation of the human prefrontal cortex evokes complex visual hallucinations. *Epilepsy & Behavior* 1: 356-61
- Boccia M, Piccardi L, Palermo L, Nemmi F, Sulpizio V, et al. 2015. A penny for your thoughts! Patterns of fMRI activity reveal the content and the spatial topography of visual mental images. *Human Brain Mapping* 36: 945-58
- Boly M, Coleman MR, Davis M, Hampshire A, Bor D, et al. 2007. When thoughts become action: an fMRI paradigm to study volitional brain activity in non-communicative brain injured patients. *Neuroimage* 36: 979-92
- Bourlon C, Duret C, Pradat-Diehl P, Azouvi P, Loeper-Jeny C, et al. 2011. Vocal response times to real and imagined stimuli in spatial neglect: A group study and single-case report. *Cortex* 47: 536-46
- Bourlon C, Pradat-Diehl P, Duret C, Azouvi P, Bartolomeo P. 2008. Seeing and imagining the "same" objects in unilateral neglect. *Neuropsychologia* 46: 2602-6
- Broca P. 1865. Sur le siège de la faculté du langage articulé. *Bulletins de la Société d'Anthropologie de Paris* 6: 377-93
- Caramazza A, McCloskey M. 1988. The case for single-patient studies. *Cognitive Neuropsychology* 5: 517-27
- Cohen L, Verstichel P, Pierrot-Deseilligny C. 1992. Hallucinatory vision of a familiar face following right temporal hemorrhage. *Neurology* 42: 2052
- Creem-Regehr SH, Neil JA, Yeh HJ. 2007. Neural correlates of two imagined egocentric transformations. *Neuroimage* 35: 916-27
- D'Esposito M, Detre JA, Aguirre GK, Stallcup M, Alsop DC, et al. 1997. A functional MRI study of mental image generation. *Neuropsychologia* 35: 725-30
- Daselaar SM, Porat Y, Huijbers W, Pennartz CM. 2010. Modality-specific and modality-independent components of the human imagery system. *Neuroimage* 52: 677-85
- Deacon D, Grose-Fifer J, Yang CM, Stanick V, Hewitt S, Dynowska A. 2004. Evidence for a new conceptualization of semantic representation in the left and right cerebral hemispheres. *Cortex* 40: 467-78
- Dhindsa K, Drobinin V, King J, Hall GB, Burgess N, Becker S. 2014. Examining the role of the temporo-parietal network in memory, imagery, and viewpoint transformations. *Frontiers in human neuroscience* 8: 709
- Dobelle W, Mladejovsky M. 1974. Phosphenes produced by electrical stimulation of human occipital cortex, and their application to the development of a prosthesis for the blind. *The Journal of physiology* 243: 553-76
- Ehrlichman H, Barrett J. 1983. Right hemispheric specialization for mental imagery: A review of the evidence. *Brain and Cognition* 2: 55-76
- Etcoff NL, Freeman R, Cave KL. 1991. Can we lose memories of faces? Content specificity and awareness in a prosopagnosic. *Journal of Cognitive Neuroscience* 3: 25-41
- Farah MJ. 1984. The neurological basis of mental imagery: A componential analysis. *Cognition* 18: 245-72

- Farah MJ. 1986. The laterality of mental image generation: a test with normal subjects. *Neuropsychologia* 24: 541-51
- Farrell DF, Leeman S, Ojemann GA. 2007. Study of the human visual cortex: direct cortical evoked potentials and stimulation. *Journal of Clinical Neurophysiology* 24: 1-10
- Fish DR, Gloor P, Quesney FL, Olivier A. 1993. Clinical responses to electrical brain stimulation of the temporal and frontal lobes in patients with epilepsy. Pathophysiological implications. *Brain* 116 ( Pt 2): 397-414
- Formisano E, Linden DE, Di Salle F, Trojano L, Esposito F, et al. 2002. Tracking the mind's image in the brain I: time-resolved fMRI during visuospatial mental imagery. *Neuron* 35: 185-94
- Ganis G, Schendan HE. 2008. Visual mental imagery and perception produce opposite adaptation effects on early brain potentials. *Neuroimage* 42: 1714-27
- Ganis G, Thompson WL, Kosslyn SM. 2004. Brain areas underlying visual mental imagery and visual perception: an fMRI study. *Brain Res Cogn Brain Res* 20: 226-41
- Gardini S, De Beni R, Cornoldi C, Bromiley A, Venneri A. 2005. Different neuronal pathways support the generation of general and specific mental images. *Neuroimage* 27: 544-52
- Gauthier B, Prabhu P, Kotegar KA, van Wassenhove V. 2020. Hippocampal Contribution to Ordinal Psychological Time in the Human Brain. *J Cogn Neurosci* 32: 2071-86
- Gloor P, Olivier A, Quesney LF, Andermann F, Horowitz S. 1982. The role of the limbic system in experiential phenomena of temporal lobe epilepsy. *Ann Neurol* 12: 129-44
- Goebel R, Khorram-Sefat D, Muckli L, Hacker H, Singer W. 1998. The constructive nature of vision: direct evidence from functional magnetic resonance imaging studies of apparent motion and motion imagery. *Eur J Neurosci* 10: 1563-73
- Grose-Fifer J, Deacon D. 2004. Priming by natural category membership in the left and right cerebral hemispheres. *Neuropsychologia* 42: 1948-60
- Guariglia C, Padovani A, Pantano P, Pizzamiglio L. 1993. Unilateral neglect restricted to visual imagery. *Nature* 364: 235-7
- Guillot A, Collet C, Nguyen VA, Malouin F, Richards C, Doyon J. 2009. Brain activity during visual versus kinesthetic imagery: an fMRI study. *Hum Brain Mapp* 30: 2157-72
- Gulyás B. 2001. Neural networks for internal reading and visual imagery of reading: A PET study. *Brain Research Bulletin* 54: 319-28
- Hamamé CM, Vidal JR, Ossandón T, Jerbi K, Dalal SS, et al. 2012. Reading the mind's eye: online detection of visuo-spatial working memory and visual imagery in the inferior temporal lobe. *Neuroimage* 59: 872-9
- Handy T, Miller M, Schott B, Shroff N, Janata P, et al. 2004. Visual imagery and memory: Do retrieval strategies affect what the mind's eye sees? *European Journal of Cognitive Psychology* 16: 631-52
- Hawes Z, Sokolowski HM, Ononye CB, Ansari D. 2019. Neural underpinnings of numerical and spatial cognition: An fMRI meta-analysis of brain regions associated with symbolic number, arithmetic, and mental rotation. *Neurosci Biobehav Rev* 103: 316-36
- Howard RJ, Barnes J, McKeefry D, Ha Y, Woodruff PW, et al. 1998. The functional anatomy of imagining and perceiving colour. *Neuroreport* 9: 1019-23
- Hughlings Jackson J. 1888. On a Particular Variety of Epilepsy ("Intellectual Aura"), One Case with Symptoms of Organic Brain Disease. *Brain* 11: 179-207
- Hughlings Jackson J. 1931. Selected writings. On epilepsy and epileptiform convulsions.

- Hughlings Jackson J, Stewart P. 1899. Epileptic Attacks with a Warning of a Crude Sensation of Smell and with the Intellectual Aura (Dreamy State) in a Patient Who Had Symptoms Pointing to Gross Organic Disease of the Right Temporo-Sphenoidal Lobe. *Brain* 22: 534-49
- Ishai A, Ungerleider LG, Haxby JV. 2000. Distributed neural systems for the generation of visual images. *Neuron* 28: 979-90
- Iturria-Medina Y, Pérez Fernández A, Morris DM, Canales-Rodríguez EJ, Haroon HA, et al. 2011. Brain hemispheric structural efficiency and interconnectivity rightward asymmetry in human and nonhuman primates. *Cereb Cortex* 21: 56-67
- Jasper HH, Rasmussen T. 1958. Studies of clinical and electrical responses to deep temporal stimulation in man with some considerations of functional anatomy. *Research Publications of the Association for Research in Nervous & Mental Disease* 36: 316-34
- Jonas J, Frismand S, Vignal JP, Colnat - Coulbois S, Koessler L, et al. 2014. Right hemispheric dominance of visual phenomena evoked by intracerebral stimulation of the human visual cortex. *Human brain mapping* 35: 3360-71
- Jonas J, Rössion B, Brissart H, Frismand S, Jacques C, et al. 2015. Beyond the core face-processing network: Intracerebral stimulation of a face-selective area in the right anterior fusiform gyrus elicits transient prosopagnosia. *Cortex* 72: 140-55
- Jordan K, Heinze HJ, Lutz K, Kanowski M, Jäncke L. 2001. Cortical activations during the mental rotation of different visual objects. *Neuroimage* 13: 143-52
- Kellenbach ML, Brett M, Patterson K. 2001. Large, colorful, or noisy? Attribute- and modality-specific activations during retrieval of perceptual attribute knowledge. *Cognitive, Affective, & Behavioral Neuroscience* 1: 207-21
- Kilintari M, Narayana S, Babajani-Feremi A, Rezaie R, Papanicolaou AC. 2016. Brain activation profiles during kinesthetic and visual imagery: An fMRI study. *Brain Res* 1646: 249-61
- Kim S-E, Kim J-W, Kim J-J, Jeong BS, Choi EA, et al. 2007. The neural mechanism of imagining facial affective expression. *Brain Research* 1145: 128-37
- Kosslyn SM, Holtzman JD, Farah MJ, Gazzaniga MS. 1985. A computational analysis of mental image generation: evidence from functional dissociations in split-brain patients. *Journal of Experimental Psychology: General* 114: 311-41
- Kosslyn SM, Thompson WL, Ganis G. 2006. *The case for mental imagery*. New York, NY, US: Oxford University Press. vi, 248-vi, pp.
- Kravitz DJ, Saleem KS, Baker CI, Ungerleider LG, Mishkin M. 2013. The ventral visual pathway: an expanded neural framework for the processing of object quality. *Trends Cogn Sci* 17: 26-49
- Kreiman G, Koch C, Fried I. 2000. Imagery neurons in the human brain. *Nature* 408: 357-61
- Kukolja J, Marshall JC, Fink GR. 2006. Neural mechanisms underlying spatial judgements on seen and imagined visual stimuli in the left and right hemifields in men. *Neuropsychologia* 44: 2846-60
- Lambert S, Sampaio E, Scheiber C, Mauss Y. 2002. Neural substrates of animal mental imagery: calcarine sulcus and dorsal pathway involvement—an fMRI study. *Brain research* 924: 176-83
- Lambon Ralph MA, Jefferies E, Patterson K, Rogers TT. 2017. The neural and computational bases of semantic cognition. *Nature Reviews Neuroscience* 18: 42
- Lamp G, Alexander B, Laycock R, Crewther DP, Crewther SG. 2016. Mapping of the Underlying Neural Mechanisms of Maintenance and Manipulation in Visuo-Spatial

- Working Memory Using An n-back Mental Rotation Task: A Functional Magnetic Resonance Imaging Study. *Frontiers in Behavioral Neuroscience* 10
- Lee HW, Hong SB, Seo DW, Tae WS, Hong SC. 2000. Mapping of functional organization in human visual cortex: electrical cortical stimulation. *Neurology* 54: 849-54
- Levine DN, Warach J, Farah M. 1985. Two visual systems in mental imagery: Dissociation of "what" and "where" in imagery disorders due to bilateral posterior cerebral lesions. *Neurology* 35: 1010-8
- Logie RH, Pernet CR, Buonocore A, Della Sala S. 2011. Low and high imagers activate networks differentially in mental rotation. *Neuropsychologia* 49: 3071-7
- Mahon BZ, Caramazza A. 2011. What drives the organization of object knowledge in the brain? *Trends Cogn Sci* 15: 97-103
- Marinkovic K, Trebon P, Chauvel P, Halgren E. 2000. Localised face processing by the human prefrontal cortex: Face-selective intracerebral potentials and post-lesion deficits. *Cognitive neuropsychology* 17: 187-99
- Mazard A, Laou L, Joliot M, Mellet E. 2005. Neural impact of the semantic content of visual mental images and visual percepts. *Cognitive Brain Research* 24: 423-35
- McNorgan C. 2012. A meta-analytic review of multisensory imagery identifies the neural correlates of modality-specific and modality-general imagery. *Front Hum Neurosci* 6: 285
- Mégevand P, Groppe DM, Goldfinger MS, Hwang ST, Kingsley PB, et al. 2014. Seeing Scenes: Topographic Visual Hallucinations Evoked by Direct Electrical Stimulation of the Parahippocampal Place Area. *The Journal of Neuroscience* 34: 5399-405
- Mellet E, Bricogne S, Tzourio-Mazoyer N, Ghaem O, Petit L, et al. 2000. Neural correlates of topographic mental exploration: the impact of route versus survey perspective learning. *Neuroimage* 12: 588-600
- Moriarty JL, Boatman D, Krauss GL, Storm PB, Lenz FA. 2001. Human "memories" can be evoked by stimulation of the lateral temporal cortex after ipsilateral medial temporal lobe resection. *Journal of neurology, neurosurgery, and psychiatry* 71: 549-51
- Moro V, Berlucchi G, Lerch J, Tomaiuolo F, Aglioti SM. 2008. Selective deficit of mental visual imagery with intact primary visual cortex and visual perception. *Cortex* 44: 109-18
- Mullan S, Penfield W. 1959. Illusions of comparative interpretation and emotion; production by epileptic discharge and by electrical stimulation in the temporal cortex. *AMA Arch Neurol Psychiatry* 81: 269-84
- Murphey DK, Maunsell JHR, Beauchamp MS, Yoshor D. 2009. Perceiving electrical stimulation of identified human visual areas. *Proceedings of the National Academy of Sciences* 106: 5389-93
- Newman SD, Klatzky RL, Lederman SJ, Just MA. 2005. Imagining material versus geometric properties of objects: an fMRI study. *Brain Res Cogn Brain Res* 23: 235-46
- O'Craven KM, Kanwisher N. 2000. Mental imagery of faces and places activates corresponding stimulus-specific brain regions. *J Cogn Neurosci* 12: 1013-23
- Pearson J. 2019. The human imagination: the cognitive neuroscience of visual mental imagery. *Nat Rev Neurosci* 20: 624-34
- Pearson J. 2020. Reply to: Assessing the causal role of early visual areas in visual mental imagery. *Nat Rev Neurosci* 21: 517-8
- Penfield W. 1938. The cerebral cortex in man: I. The cerebral cortex and consciousness. *Archives of Neurology & Psychiatry* 40: 417-42

- Penfield W, Perot P. 1963. The Brain's Record of Auditory and Visual Experience. A Final Summary and Discussion. *Brain* 86: 595-696
- Puce A, Allison T, McCarthy G. 1999. Electrophysiological Studies of Human Face Perception. III: Effects of Top-down Processing on Face-specific Potentials. *Cerebral Cortex* 9: 445-58
- Pyke AA, Fincham JM, Anderson JR. 2017. When math operations have visuospatial meanings versus purely symbolic definitions: Which solving stages and brain regions are affected? *NeuroImage* 153: 319-35
- Reilly M, Machado N, Blumstein SE. 2015. Hemispheric lateralization of semantic feature distinctiveness. *Neuropsychologia* 75: 99-108
- Rode G, Cotton F, Revol P, Jacquin-Courtois S, Rossetti Y, Bartolomeo P. 2010. Representation and disconnection in imaginal neglect. *Neuropsychologia* 48: 2903-11
- Rousseaux M, Debrock D, Cabaret M, Steinling M. 1994. Visual hallucinations with written words in a case of left parietotemporal lesion. *Journal of Neurology, Neurosurgery & Psychiatry* 57: 1268-71
- Sasaoka T, Mizuhara H, Inui T. 2014. Dynamic parieto-premotor network for mental image transformation revealed by simultaneous EEG and fMRI measurement. *J Cogn Neurosci* 26: 232-46
- Schulz R, Woermann FG, Ebner A. 2007. When written words become moving pictures: complex visual hallucinations on stimulation of the lateral occipital lobe. *Epilepsy & Behavior* 11: 147-51
- Selimbeyoglu A, Parvizi J. 2010. Electrical stimulation of the human brain: perceptual and behavioral phenomena reported in the old and new literature. *Frontiers in Human Neuroscience* 4
- Shallice T. 1988. *From Neuropsychology to Mental Structure*. New York: Cambridge University Press
- Shepard RN, Metzler J. 1971. Mental Rotation of Three-Dimensional Objects. *Science* 171: 701-3
- Spagna A, Hajhajate D, Liu J, Bartolomeo P. 2020a. Visual mental imagery engages the left fusiform gyrus, but not the early visual cortex: a meta-analysis of neuroimaging evidence. *bioRxiv*: 2020.02.06.937151
- Spagna A, Hajhajate D, Liu J, Bartolomeo P. 2021. Visual mental imagery engages the left fusiform gyrus, but not the early visual cortex: A meta-analysis of neuroimaging evidence. *Neuroscience & Biobehavioral Reviews* 122: 201-17
- Spagna A, Mackie M-A, Fan J. 2015. Supramodal executive control of attention. *Frontiers in psychology* 6: 65
- Spagna A, Wu T, Kim K, Fan J. 2020b. Supramodal executive control of attention: evidence from unimodal and crossmodal dual conflict effects. *Cortex* 133: 266-76
- Steel A, Billings MM, Silson EH, Robertson CE. 2020. A network linking perception and memory systems in posterior cerebral cortex. *bioRxiv*: 2020.05.25.115147
- Stokes M, Thompson R, Cusack R, Duncan J. 2009. Top-down activation of shape-specific population codes in visual cortex during mental imagery. *J Neurosci* 29: 1565-72
- Thompson-Schill S, Aguirre G, Desposito M, Farah M. 1999. A neural basis for category and modality specificity of semantic knowledge. *Neuropsychologia* 37: 671-6
- Thorudottir S, Sigurdardottir HM, Rice GE, Kerry SJ, Robotham RJ, et al. 2020. The Architect Who Lost the Ability to Imagine: The Cerebral Basis of Visual Imagery. *Brain Sciences* 10: 59

- Trojano L, Grossi D, Linden DEJ, Formisano E, Hacker H, et al. 2000. Matching Two Imagined Clocks: the Functional Anatomy of Spatial Analysis in the Absence of Visual Stimulation. *Cerebral Cortex* 10: 473-81
- Vallortigara G, Versace E. 2017. Laterality at the neural, cognitive, and behavioral levels. In *APA handbook of comparative psychology: Basic concepts, methods, neural substrate, and behavior, Vol. 1*, pp. 557-77. Washington, DC, US: American Psychological Association
- VanRullen R, Reddy L. 2019. Reconstructing faces from fMRI patterns using deep generative neural networks. *Communications Biology* 2
- Vignal J, Chauvel P, Halgren E. 2000. Localised face processing by the human prefrontal cortex: stimulation-evoked hallucinations of faces. *Cognitive Neuropsychology* 17: 281-91
- Vignal JP, Maillard L, McGonigal A, Chauvel P. 2007. The dreamy state: hallucinations of autobiographic memory evoked by temporal lobe stimulations and seizures. *Brain* 130: 88-99
- Whittingstall K, Bernier M, Houde JC, Fortin D, Descoteaux M. 2014. Structural network underlying visuospatial imagery in humans. *Cortex* 56: 85-98
- Winlove CIP, Milton F, Ranson J, Fulford J, MacKisack M, et al. 2018. The neural correlates of visual imagery: A co-ordinate-based meta-analysis. *Cortex* 105: 4-25
- Wu T, Spagna A, Chen C, Schulz KP, Hof PR, Fan J. 2020. Supramodal Mechanisms of the Cognitive Control Network in Uncertainty Processing. *Cerebral Cortex* 30: 6336-49
- Yomogida Y, Sugiura M, Watanabe J, Akitsuki Y, Sassa Y, et al. 2004. Mental visual synthesis is originated in the fronto-temporal network of the left hemisphere. *Cerebral Cortex* 14: 1376-83
- Zeman AZ, Della Sala S, Torrens LA, Gountouna VE, McGonigle DJ, Logie RH. 2010. Loss of imagery phenomenology with intact visuo-spatial task performance: a case of 'blind imagination'. *Neuropsychologia* 48: 145-55
- Zvyagintsev M, Clemens B, Chechko N, Mathiak KA, Sack AT, Mathiak K. 2013. Brain networks underlying mental imagery of auditory and visual information. *European Journal of Neuroscience* 37: 1421-34