



**HAL**  
open science

## Delayed Benefit From Aggressive Immunotherapy in Waxing and Waning Anti-IgLON5 Disease

Pauline Shambrook, Adèle Hesters, Clémence Marois, Daniel Zemba, Jérôme Servan, Bertrand Gaymard, Fernando Pico, Cécile Delorme, Catherine Lubetzki, Isabelle Arnulf, et al.

► **To cite this version:**

Pauline Shambrook, Adèle Hesters, Clémence Marois, Daniel Zemba, Jérôme Servan, et al.. Delayed Benefit From Aggressive Immunotherapy in Waxing and Waning Anti-IgLON5 Disease. *Neurology - Neuroimmunology Neuroinflammation*, 2021, 8 (4), pp.e1009. 10.1212/NXI.0000000000001009. hal-03229605

**HAL Id: hal-03229605**

<https://hal.sorbonne-universite.fr/hal-03229605v1>

Submitted on 19 May 2021

**HAL** is a multi-disciplinary open access archive for the deposit and dissemination of scientific research documents, whether they are published or not. The documents may come from teaching and research institutions in France or abroad, or from public or private research centers.

L'archive ouverte pluridisciplinaire **HAL**, est destinée au dépôt et à la diffusion de documents scientifiques de niveau recherche, publiés ou non, émanant des établissements d'enseignement et de recherche français ou étrangers, des laboratoires publics ou privés.

# Delayed Benefit From Aggressive Immunotherapy in Waxing and Waning Anti-IgLON5 Disease

Pauline Shambrook, MD, Adèle Hesters, MD, Clémence Marois, MD, Daniel Zemba, MD, Jérôme Servan, MD, Bertrand Gaymard, MD, PhD, Fernando Pico, MD, Cécile Delorme, MD, Catherine Lubetzki, MD, PhD, Isabelle Arnulf, MD, PhD, Dimitri Psimaras, MD, Jérôme Honnorat, MD, PhD, Ana Gales, MD, and Aurélie Méneret, MD, PhD

**Correspondence**  
Dr. Méneret  
aurelie.meneret@aphp.fr

*Neurol Neuroimmunol Neuroinflamm* 2021;8:e1009. doi:10.1212/NXI.0000000000001009

Anti-IgLON5 disease is a rare disorder characterized by the variable association of movement disorders, sleep disturbances, cognitive impairment, bulbar symptoms, and respiratory dysfunction.<sup>1,2</sup> Pathophysiology likely involves both autoimmune and neurodegenerative processes, and prognosis is considered to be poor.<sup>3,4</sup> Here, we report a case with a waxing and waning course, who eventually responded well to aggressive and sustained immunotherapy.

## MORE ONLINE

### Video

## Case

A 59-year-old woman presented with dysphagia, weight loss, and involuntary movements of the face and the upper limbs. Symptoms were stable for 6 months until she suddenly developed visual hallucinations, episodic nocturnal confusion, and severe insomnia. The diagnostic workup, including a generic autoantibodies panel, was negative. Blood gases were not performed. She was treated with clonazepam, which improved hallucinations and nocturnal behavior disorders. Three months later, she developed hypoxemia and hypercapnia as a consequence of central hypoventilation, discovered during an emergency department visit for confusion. Nocturnal noninvasive ventilation was started. Clinical examination showed diffuse myoclonus (predominant in the upper limbs, face, and tongue), dysarthria, mild parkinsonism and cerebellar signs limiting ambulation (video 1), and mild cognitive impairment (mini-mental state examination score 24 of 30 and frontal assessment battery score 17 of 18). Brain MRI, EEG, CSF, and EMG findings were unremarkable. Video polysomnography showed a major insomnia (total sleep time: 112 minutes/48 hours-recording), simple (4 limbs movements and pedaling) and complex (facial emotional expressions, chewing, and moaning) behaviors during undifferentiated NREM sleep (figure, video 1), absent REM sleep, and persistence of facio-lingual myoclonus during sleep. Video-oculographic recording showed reduced velocity of horizontal saccades without slowing of vertical saccades and an increased antisaccade error rate suggesting prefrontal involvement. Anti-IgLON5 antibodies were positive in serum (IgG1: 1/12,800 and IgG4: negative) and CSF (IgG1: 1/320 and IgG4: 1/10). Twelve months after disease onset, the patient was hospitalized in the intensive care unit for severe fluctuations of vigilance and hypercapnia.

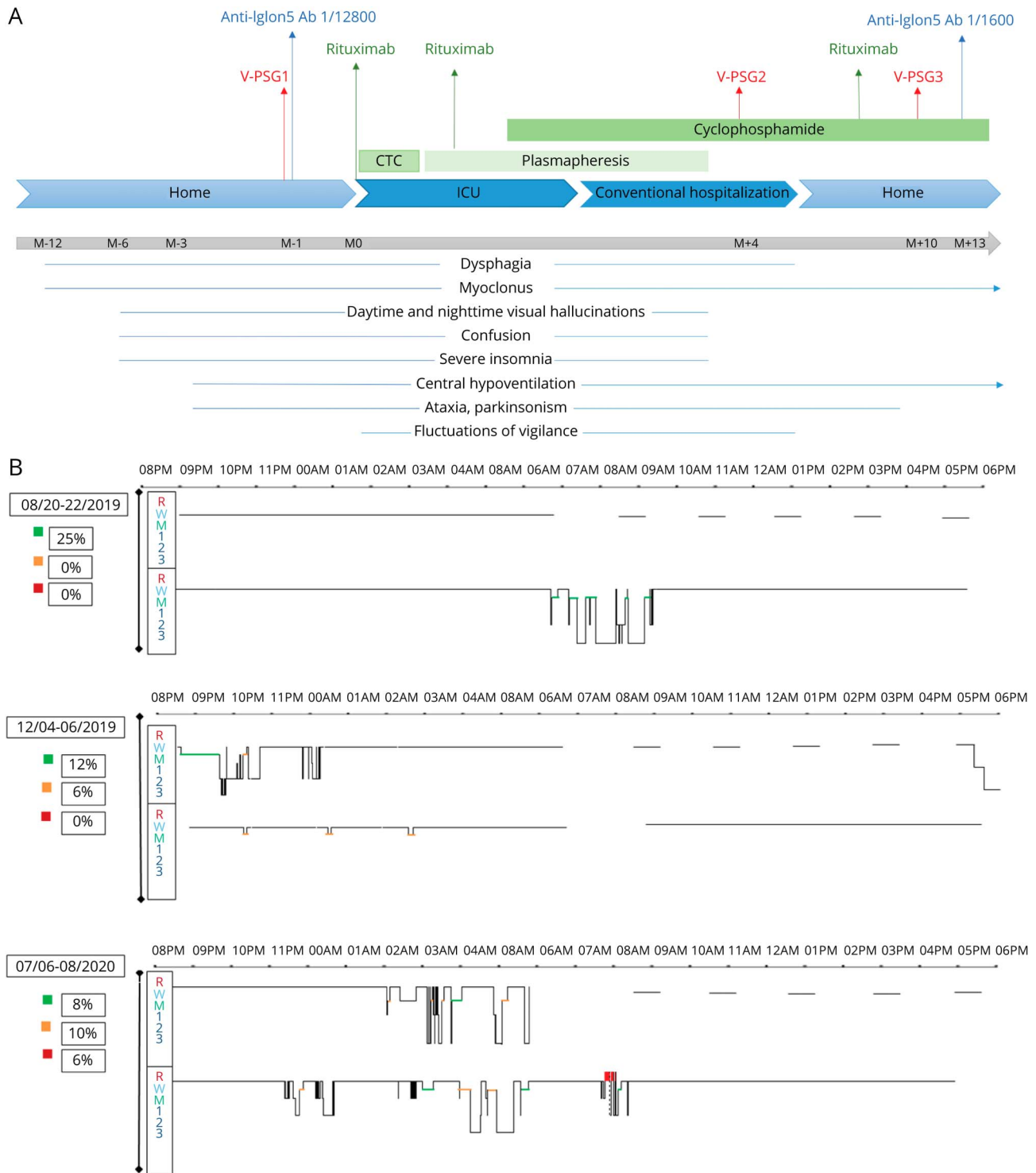
From the Department of Neurology (P.S., A.H., C.M., C.D., C.L., A.M.), Pitié-Salpêtrière Hospital, AP-HP, Paris, France; Department of Neurology (D.Z., J.S., F.P.), Versailles Hospital, Le Chesnay, France; Department of Neurology (D.Z.), CHU Yalgado Ouédraogo, Ouagadougou, Burkina Faso; Department of Neurophysiology (B.G.), Pitié-Salpêtrière Hospital, AP-HP, Paris, France; Sorbonne University (C.L., I.A., A.M.), Paris, France; Sleep Disorder Unit (I.A., A.G.), Pitié-Salpêtrière Hospital, AP-HP, Paris, France; Service de Neurologie 2-Mazarin (D.P.), Groupe Hospitalier Pitié-Salpêtrière et Université Pierre et Marie Curie-Paris 6, AP-HP, Centre de Compétence des Syndromes Neurologiques Paraneoplasiques et Encéphalites Autoimmunes, Paris, France; French Reference Center on Paraneoplastic Neurological Syndromes and Autoimmune Encephalitis (J.H.), Hospices Civils de Lyon, Institut Neuro-MyoGene, INSERM U1217/CNRS UMR5310, Université de Lyon, Université Claude Bernard Lyon 1, France.

Go to [Neurology.org/NN](https://www.neurology.org/NN) for full disclosures. Funding information is provided at the end of the article.

The Article Processing Charge was funded by the CRNS.

This is an open access article distributed under the terms of the Creative Commons Attribution-NonCommercial-NoDerivatives License 4.0 (CC BY-NC-ND), which permits downloading and sharing the work provided it is properly cited. The work cannot be changed in any way or used commercially without permission from the journal.

**Figure** Timeline and Sleep Characteristics Before and After Treatment Onset



(A) Timeline showing disease symptom progression, paraclinical examinations, and treatments over time, expressed in months before and after treatment onset (M0). CTC = corticosteroids, V-PSG = video polysomnography, ICU = intensive care unit. (B) Sleep stages across nighttime and daytime during a consecutive 48-hour polysomnographical monitoring performed in the sleep laboratory, including a first night from 9 PM to 6:30 AM, followed by 5 multiple sleep latency tests and by a 24-hour bed rest procedure aimed at capturing the maximum time asleep per 24 hours. Lights off (LO) are presented in black horizontal bars. The same procedure was repeated before (M0), 4 months (M4), and 10 months (M10) after treatment onset. X axis: time; Y axis: R = REM; W = awake; 1, 2, 3 = N1, N2, and N3 NREM sleep stages, M with 2 different stages = undifferentiated NREM sleep in green and subwakefulness in orange. The patient complained of severe insomnia at M0 and M4, but not at M10 and was always treated with noninvasive pressure ventilation and melatonin (5 mg/d at M0 and 12 mg/d at M4 and M10). In addition, she was on low doses of clonazepam (0.3 mg at bedtime) for the first V-PSG and risperidone 1 mg/d for the following 2.

Immunotherapy was started, including high doses of corticosteroids for 5 days, followed by 15 plasma exchanges over 3 months, together with 4 courses of rituximab, and monthly cycles of cyclophosphamide for 1 year. Low doses of neuroleptics were added to control hallucinations and paranoid thoughts. The patient's condition stabilized, albeit with periods of improvement and worsening, making discharge from the hospital impossible for months. The video polysomnography performed 4 months after starting immunotherapy showed mostly an apparent sleep behavior (eyes closed and snoring) despite a wake (alpha rhythms) EEG, which we call "subwakefulness," intermingled with undifferentiated NREM sleep periods (totaling 127 minutes/48 hours) associated with simple and complex behaviors. Ten months after treatment onset, the patient's condition had considerably improved, with the disappearance of hallucinations and fluctuations of vigilance, cognitive improvement (MMSE score 29 of 30), weight gain, and improvement of walking perimeter to several kilometers, but she still had mild myoclonus and required nocturnal ventilation. In the video polysomnography, total sleep time increased (272 minutes/48 hours), movements and vocalizations with undifferentiated NREM sleep decreased, REM sleep resumed, but subwakefulness periods persisted (figure). At 13 months, anti-IgLON5 antibody levels had dropped in serum (IgG1: 1/1,600, CSF unavailable).

## Discussion

In anti-IgLON5 disease, hypokinetic or hyperkinetic movement disorders are frequently described, including parkinsonism, myoclonus, myorhythmia, dystonia, chorea and tremor as well as ataxia, sometimes associated with supranuclear gaze palsy, making progressive supranuclear palsy and Whipple disease common differential diagnoses.<sup>1-3</sup> However, the phenotype is usually milder at onset, as was the case in our patient, who initially only had dysphagia and myoclonus of the upper limbs and face. Diagnosis must therefore be suspected in adult patients presenting with subacute movement disorders, especially in association with sleep abnormalities, bulbar signs, or respiratory dysfunction. The diagnosis of autoimmune or paraneoplastic encephalopathy is usually evoked in those cases because various movement disorders are often part of the clinical phenotype.<sup>5</sup> However, the correct diagnosis may be missed if not specifically looked for because anti-IgLON5 antibodies are not part of the first-line diagnostic panel in many centers. Polysomnography has major diagnostic value because anti-IgLON5 disease is associated with specific NREM and REM sleep disturbances, including movements and behaviors during sleep and undifferentiated NREM sleep.<sup>6</sup> In addition, our patient also developed a subwakefulness stage containing a slow alpha EEG rhythm (reminiscent of wakefulness) combined with apparent sleep behavior concurrently with clinical improvement and reappearance of REM sleep, suggesting it could be a marker of neuronal functional recovery.<sup>7</sup> Finally, as neuropathology suggests both autoimmune and neurodegenerative processes in anti-IgLON5 disease, immunotherapy is

still debated. Our case demonstrated a good but delayed response to immunotherapy, after several months of waxing and waning, suggesting that early diagnosis as well as aggressive and sustained immunotherapy may be key in this disorder.

## Study Funding

The authors report no targeted funding.

## Disclosure

P. Shambrook, A. Hesters, C. Marois, D. Zemba, J. Servan, B. Gaymard, F. Pico, C. Lubetzki, I. Arnulf, D. Psimaras, J. Honnorat, and A. Gales report no disclosures relevant to the manuscript; A. Méneret received travel funding from Abbvie, Merz; C. Delorme received a research grant from the Federation internationale de l'automobile, travel funding from Merz, Boston Scientific, and Medtronic. Go to Neurology.org/NN for full disclosures.

## Publication History

Received by *Neurology: Neuroimmunology & Neuroinflammation* October 31, 2020. Accepted in final form March 10, 2021.

## Appendix Authors

Name	Location	Contribution
<b>Pauline Shambrook, MD</b>	Department of Neurology, Pitié-Salpêtrière Hospital, AP-HP, Paris, France	Major role in the acquisition of data; analyzed the data; drafted the article for intellectual content
<b>Adèle Hesters, MD</b>	Department of Neurology, Pitié-Salpêtrière Hospital, AP-HP, Paris, France	Major role in the acquisition of data
<b>Clémence Marois, MD</b>	Department of Neurology, Pitié-Salpêtrière Hospital, AP-HP, Paris, France	Major role in the acquisition of data
<b>Daniel Zemba, MD</b>	Department of Neurology, Versailles Hospital, Le Chesnay, France; Yalgado Ouédraogo Hospital, Ouagadougou, Burkina Faso	Major role in the acquisition of data
<b>Jérôme Servan, MD</b>	Department of Neurology, Versailles Hospital, Le Chesnay, France	Major role in the acquisition of data
<b>Bertrand Gaymard, MD, PhD</b>	Department of Neurophysiology, Pitié-Salpêtrière Hospital, AP-HP, Paris, France	Major role in the acquisition of data
<b>Fernando Pico, MD</b>	Department of Neurology, Versailles Hospital, Le Chesnay, France	Major role in the acquisition of data
<b>Cécile Delorme, MD</b>	Department of Neurology, Pitié-Salpêtrière Hospital, AP-HP, Paris, France	Major role in the acquisition of data
<b>Catherine Lubetzki, MD, PhD</b>	Department of Neurology, Pitié-Salpêtrière Hospital, AP-HP, Paris, France; Sorbonne University, Paris, France	Major role in the acquisition of data

Continued

## Appendix (continued)

Name	Location	Contribution
<b>Isabelle Arnulf, MD, PhD</b>	Sleep Disorder Unit, Pitié-Salpêtrière Hospital, AP-HP, Paris, France; Sorbonne University, Paris, France	Interpreted the data; revised the article for intellectual content
<b>Dimitri Psimaras, MD</b>	Service de Neurologie 2-Mazarin, Groupe Hospitalier Pitié-Salpêtrière et Université Pierre et Marie Curie-Paris 6, AP-HP; Centre de Compétence des Syndromes Neurologiques Paraneoplasiques et Encéphalites Autoimmunes, Paris, France	Major role in the acquisition of data
<b>Jérôme Honnorat, MD, PhD</b>	French Reference Center on Paraneoplastic Neurological Syndromes and Autoimmune Encephalitis, Hospices Civils de Lyon, Institut NeuroMyoGene, INSERM U1217/CNRS UMR5310, Université de Lyon, Université Claude Bernard Lyon 1	Major role in the acquisition of data

## Appendix (continued)

Name	Location	Contribution
<b>Ana Gales, MD</b>	Sleep Disorder Unit, Pitié-Salpêtrière Hospital, AP-HP, Paris, France	Major role in the acquisition of data; interpreted the data; revised the article for intellectual content
<b>Aurélie Méneret, MD, PhD</b>	Department of Neurology, Pitié-Salpêtrière Hospital, AP-HP, Paris, France; Sorbonne University, Paris, France	Design and conceptualized study; major role in the acquisition of data; interpreted the data; revised the article for intellectual content

## References

1. Honorat JA, Komorowski L, Josephs KA, et al. IgLON5 antibody: neurological accompaniments and outcomes in 20 patients. *Neurol Neuroimmunol Neuroinflamm*. 2017;4(5):e385. doi: 10.1212/NXI.0000000000000385.
2. Nissen MS, Blaabjerg M. Anti-IgLON5 disease: a case with 11-year clinical course and review of the literature. *Front Neurol*. 2019;10:1056.
3. Sabater L, Gaig C, Gelpi E, et al. A novel non-rapid-eye movement and rapid-eye-movement parasomnia with sleep breathing disorder associated with antibodies to IgLON5: a case series, characterisation of the antigen, and post-mortem study. *Lancet Neurol*. 2014;13(6):575-586.
4. Cabezudo-García P, Mena-Vázquez N, Estivill Torrús G, Serrano-Castro P. Response to immunotherapy in anti-IgLON5 disease: a systematic review. *Acta Neurol Scand*. 2020;141(4):263-270.
5. Honnorat J, Joubert B. Movement disorders in autoimmune encephalitis and paraneoplastic neurological syndromes. *Revue Neurologique*. 2018;174(9):597-607.
6. Gaig C, Iranzo A, Cajochen C, et al. Characterization of the sleep disorder of anti-IgLON5 disease. *Sleep*. 2019;42(9):zsz133.
7. Antelmi E, Ferri R, Iranzo A, et al. From state dissociation to status dissociatus. *Sleep Med Rev*. 2016 Aug;28:5-17.

# Neurology<sup>®</sup> Neuroimmunology & Neuroinflammation

## Delayed Benefit From Aggressive Immunotherapy in Waxing and Waning Anti-IgLON5 Disease

Pauline Shambrook, Adèle Hesters, Clémence Marois, et al.  
*Neurol Neuroimmunol Neuroinflamm* 2021;8;  
DOI 10.1212/NXI.0000000000001009

This information is current as of May 13, 2021

<b>Updated Information &amp; Services</b>	including high resolution figures, can be found at: <a href="http://nn.neurology.org/content/8/4/e1009.full.html">http://nn.neurology.org/content/8/4/e1009.full.html</a>
<b>References</b>	This article cites 7 articles, 1 of which you can access for free at: <a href="http://nn.neurology.org/content/8/4/e1009.full.html##ref-list-1">http://nn.neurology.org/content/8/4/e1009.full.html##ref-list-1</a>
<b>Subspecialty Collections</b>	This article, along with others on similar topics, appears in the following collection(s): <b>All Movement Disorders</b> <a href="http://nn.neurology.org/cgi/collection/all_movement_disorders">http://nn.neurology.org/cgi/collection/all_movement_disorders</a> <b>All Sleep Disorders</b> <a href="http://nn.neurology.org/cgi/collection/all_sleep_disorders">http://nn.neurology.org/cgi/collection/all_sleep_disorders</a> <b>Autoimmune diseases</b> <a href="http://nn.neurology.org/cgi/collection/autoimmune_diseases">http://nn.neurology.org/cgi/collection/autoimmune_diseases</a> <b>Encephalitis</b> <a href="http://nn.neurology.org/cgi/collection/encephalitis">http://nn.neurology.org/cgi/collection/encephalitis</a>
<b>Permissions &amp; Licensing</b>	Information about reproducing this article in parts (figures, tables) or in its entirety can be found online at: <a href="http://nn.neurology.org/misc/about.xhtml#permissions">http://nn.neurology.org/misc/about.xhtml#permissions</a>
<b>Reprints</b>	Information about ordering reprints can be found online: <a href="http://nn.neurology.org/misc/addir.xhtml#reprintsus">http://nn.neurology.org/misc/addir.xhtml#reprintsus</a>

*Neurol Neuroimmunol Neuroinflamm* is an official journal of the American Academy of Neurology. Published since April 2014, it is an open-access, online-only, continuous publication journal. Copyright Copyright © 2021 The Author(s). Published by Wolters Kluwer Health, Inc. on behalf of the American Academy of Neurology.. All rights reserved. Online ISSN: 2332-7812.

