



**HAL**  
open science

## **Strong ALK and PD-L1 positive IHC expression related ALK amplification in an advanced lung sarcomatoid carcinoma: a therapeutic trap?**

Sébastien Gendarme, Lise Matton, Martine Antoine, Khaldoun Kerrou, Anne-Marie Ruppert, Christelle Epaud, Jacques Cadranel, Vincent Fallet

### ► To cite this version:

Sébastien Gendarme, Lise Matton, Martine Antoine, Khaldoun Kerrou, Anne-Marie Ruppert, et al. Strong ALK and PD-L1 positive IHC expression related ALK amplification in an advanced lung sarcomatoid carcinoma: a therapeutic trap?. Lung Cancer, 2020, 152, pp.94-97. 10.1016/j.lungcan.2020.12.022 . hal-03263433

**HAL Id: hal-03263433**

**<https://hal.sorbonne-universite.fr/hal-03263433v1>**

Submitted on 17 Jun 2021

**HAL** is a multi-disciplinary open access archive for the deposit and dissemination of scientific research documents, whether they are published or not. The documents may come from teaching and research institutions in France or abroad, or from public or private research centers.

L'archive ouverte pluridisciplinaire **HAL**, est destinée au dépôt et à la diffusion de documents scientifiques de niveau recherche, publiés ou non, émanant des établissements d'enseignement et de recherche français ou étrangers, des laboratoires publics ou privés.

## Strong ALK and PD-L1 positive IHC expression related *ALK* amplification in an advanced lung sarcomatoid carcinoma: a therapeutic trap?

Sébastien Gendarme<sup>a</sup> ; Lise Matton<sup>a</sup> ; Martine Antoine<sup>b</sup> ; Khaldoun Kerrouc<sup>c</sup> ; Anne-Marie Ruppert<sup>a</sup> ; Christelle Epaud<sup>a</sup> ; Jacques Cadranel<sup>a</sup> ; Vincent Fallet<sup>a</sup>

Affiliations :

<sup>a</sup> Department of Pneumology and Thoracic Oncology, Tenon Hospital, Assistance Publique-Hôpitaux de Paris and GRC 4, Therascan, Sorbonne Université, 75970 Paris, France.

<sup>b</sup> Pathology Department, AP-HP, Groupe Hospitalier HUEP, Hôpital Tenon, Paris, France.

<sup>c</sup> Department of Nuclear Medicine, Tenon Hospital. Sorbonne University, Paris, France.

Address for correspondence: Sébastien Gendarme, Department of Pneumology and Thoracic Oncology, Hôpital Tenon, 4 Rue de la Chine, 75 020 Paris, France; mail: [s-ge@hotmail.fr](mailto:s-ge@hotmail.fr)

This research did not receive any specific grant from funding agencies in the public, commercial, or not-for-profit sectors.

## 1- INTRODUCTION

Lung sarcomatoid carcinoma (LCS) is a rare aggressive Non-Small Lung Cancer (NSCLC), poorly differentiated and containing sarcoma or sarcoma-like elements. It is characterized by high mutations rates such as KRAS, EGFR, ALK or MET and PD-ligand 1 (PD-L1) overexpression [1,2]. *Anaplastic Lymphoma Kinase (ALK)* rearrangement is considered as one of the major oncogenic driver pathway in NSCLC, leading to target therapy [3]. Immunohistochemistry (IHC) is the primary therapy-determining test for *ALK* rearrangement. IHC is validated against Fluorescence in situ Hybridization (FISH) [4]. Occasionally, some discordance may occur in about 5% of cases [5]. In rare cases, this discordance reveal more complex biological mechanism, as 5' deleted pattern, split signals pattern or amplification pattern [6]. *ALK* amplification is defined by the presence of 6 copies or more of ALK per cell in more than 10% of analysed cell [7]. FISH for chromosome centromere 2 (CEP2) could help in order to assess the true *ALK* amplification, excluding the polysomy for chromosome 2. *ALK* amplification was mainly reported as a mechanism of resistance to ALK inhibitors [8,9]. However, *ALK* amplification may, as in our case, be a primary mutation in lung cancer. There is still few data about the management of the genetic pattern of *ALK* other than *ALK* rearrangements.

Here we report a case of NSCLC ALK highly positive in IHC, with initial life-threatening disease progression after beginning ALK tyrosine kinase inhibitors (ALK TKI). Further investigations reveal *ALK* amplification, which is not sensitive to ALK TKI. Dramatic response to immune checkpoint inhibitor (ICI) was then observed.

## 2- CASE REPORT

In November 2018, a 52-year-old woman, current smoker, with no history of disease or family history of cancer was diagnosed with an advanced non-small cell lung carcinoma of the right upper lobe with liver, adrenal and bone metastasis (Figure 1A). Liver biopsy was performed. Pathological and molecular analyses revealed a lung sarcomatoid carcinoma (LSC) highly expressing EML4-ALK (100% - clone 5A4) and PDL1 (60% of tumoral cells - clone E1L3N) on immunohistochemistry (IHC). [Next-Generation DNA Sequencing revealed coexistence of a CTNNB1 \(Catenin Beta 1\); no ALK mutation or other molecular alteration were found.](#)

As recommended [4], ALK tyrosine kinase inhibitor (TKI) i.e. Alectinib (600mg daily) was started as first line treatment on the basis of the strong ALK-IHC. Two weeks later, motor deficit appeared in the lower part of the body due to tumor spinal cord compression in the 3<sup>rd</sup> thoracic vertebrae. Disease progression was confirmed with an increase in size of the primary tumor. Neurosurgical and radiotherapy treatment were performed in emergency with post-operative complications as abscess pneumonia and pulmonary embolism. However, motor deficit in the left leg did not improve.

Then, Vysis *ALK* break part fluorescence *in situ* hybridization (FISH) probe (Abbot Molecular, USA) revealed an *ALK* amplification (87.5% of malignant nuclei > 6 ALK copies in cell for orange fused spots) without *ALK* rearrangement (Figure 2). Alectinib was stopped and patient received pembrolizumab 200mg every 3 weeks as a second line, since January 2019. Then, the motor deficit has decreased with a gradual improvement in her clinical condition. At the present date, the patient has received 21 cycles of immunotherapy with a persistent metabolic response on 18F-FDG PET (positron emission tomography) and a complete resolution of the neurologic deficit (Figure 1B).

### 3- DISCUSSION

Immunohistochemistry is the primary therapy-determining test for *ALK* rearrangement. An IHC result with strong marking (score 3+) is sufficient to indicate targeted treatment and does not require FISH control [4]. Occasionally, as in our case, clinical features such as current smoker or bronchopulmonary cancers other than adenocarcinoma, must raise suspicion of the ALK-IHC validity by performing further molecular tests [10].

Indeed, discrepancies between IHC and FISH are not uncommon because of the technical considerations and biological reasons such as *ALK* amplification, polysomy or type of *ALK* fusion gene [5]. Several clinical cases have, like us, reported cases of *ALK* amplification with positive results in immunohistochemistry and negative results in FISH [11]. This discrepancy is sometimes reversed, with positive results in FISH and negative results in immunohistochemistry, due to the lack of correlation between mRNA/*ALK* protein level and to the lack of fusion protein expression [12]. Although therapeutic responses to ALK-TKI have been reported in cases of mismatch between IHC and FISH, treatment of *ALK*-amplified tumours remains controversial. Several clinical cases raise doubt about the therapeutic response of these cancers to ALK-TKI whether *ALK* amplification occurs as a secondary resistance mechanism or as a primary molecular alteration. (Table 1) In addition, further investigations into the use of clone 5A4 in our study, compared to clone D5F3 in other reported clinical cases, should be realized.

Therapeutic alternatives can then be considered. Although data suggests poor efficacy of immune checkpoint inhibitors (ICI) in *ALK*-rearranged tumours [13], its efficacy remains uncertain in *ALK*-amplified tumours. In our clinical case, the rapid progression after starting Alectinib and the prolonged response to ICI may lead us to consider the PDL1 marker as a real predictor of ICI efficacy in this situation i.e. smoking exposure and sarcomatoid histology.

Indeed, LSC may present mutations such as *KRAS*, *EGFR*, *ALK* and *MET* in more than 70% of cases, and PD-L1 expression in 70%-90% of cases [14]. Little is known on the best therapeutic strategy to apply in case of both molecular alterations and PD-L1 expression. Several clinical cases have reported the efficacy of ICI in LSC with molecular alterations such as *c-MET* amplifications [15]. [In the Immunotarget registry, the objective tumour response to ICI in non-small cell lung cancers by driver alteration was KRAS = 26%, BRAF = 24%, ROS1 = 17%, MET = 16%, EGFR = 12%, HER2 = 7%, RET = 6%, ALK = 0%. \[13\] ALK-rearranged tumours were refractory to ICI despite PDL1 expression. Tumours with ALK rearrangement thus appeared as poor candidates for ICI, even after failure of ALK TKI or chemotherapy. PDL1 marking is often consider as a trap in this situation with a low predictive value of response to ICI. Our clinical case thus demonstrates the unusual response of a tumor with ALK molecular alteration. ALK rearrangements, mutations and amplifications probably need to be apprehended separately on the predictive value of PDL1 and on the response to ICI.](#) To our knowledge, our clinical case is the first one to report a prolonged response to ICI with *ALK* amplification.

[Apart from the expression of PDL1, other factors may explain the response to ICI in our case. Smoking status is often associated with a higher tumor mutation burden. The presence of the CTNNB1 mutation has also been associated with a better response to immunotherapy in other cancers. \[16,17\] This could be explained by the role of CTNNB1 in modulating the activity of NK cells by affecting CD96. Further investigations should be performed to better understand the role of this mutation in non-small cell lung cancer.](#)

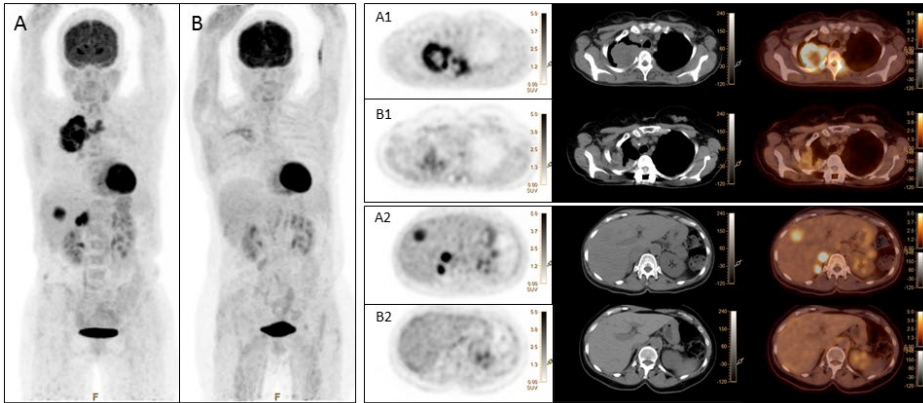
Mis en forme : Police :Italique

Mis en forme : Police :Italique

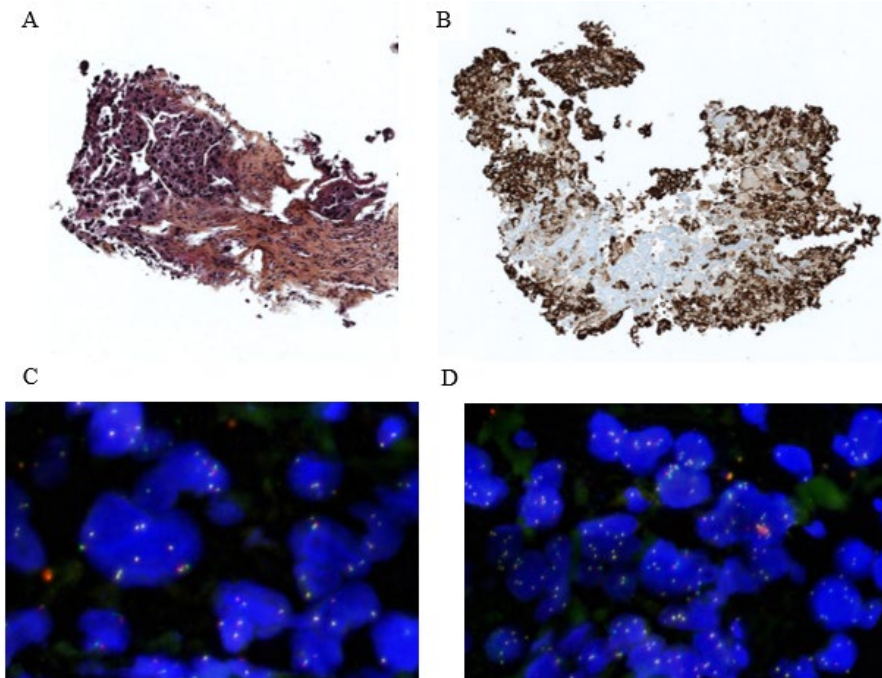
Mis en forme : Anglais (États-Unis)

## CONCLUSION

In case of an unusual phenotype, an ALK-IHC positive test should be confirmed by FISH or ARN/DNA molecular testing before starting an ALK-TKI. The concomitant presence of *ALK* amplification and PD-L1 expression in LSC should not be an impediment to the initiation of ICI.



**Figure 1.** 18F-FDG PET 3D Maximum intensity Projection (3D MIP) anterior views at baseline (A) and after 14 months of treatment with pembrolizumab (B) with baseline (A1, A2) and post therapy (B1, B2) transaxial slices on 18F-FDG PET, CT and fusion PET/CT respectively from left to right passing through the right lung apical mass and invaded T3 vertebra on first row (A1) and same slices after therapy on second row (B1). Transaxial slices passing through the liver and right adrenal gland (2 sites) metastasis on third row (A2) and same slices after therapy on fourth row (B2).



**Figure 2.** Histological analyses of the biopsied sample. Eosin hematoxylin staining is presented at magnification of (A) x 40 and IHC is presented at magnification of (B) x 10. FISH analysis shows no *ALK* translocation (C) but amplification (D).

Table 1. Clinical cases or series of cases reporting clinical and pathological data from subjects with lung cancers with *ALK* amplification  
(M: male; F: female; ADC: adenocarcinoma; SCC: squamous cell carcinoma; BAC: bronchioalveolar carcinoma; LSC: lung sarcomatoid carcinoma; PD: progressive disease, DOD: Died of disease, BA: Break Apart)

Study	Cases	Sex	Histological type of tumor	Smoking	ALK IHC	<i>ALK</i> FISH	<i>ALK</i> FISH Pattern	Treatment	Overall Patient Response
<b>Scattone et al, [6]</b>	1	F	ADC	Yes	Negative (clone D5F3)	Positive	Del 5' 32% Split 16% Gains 64%	Crizotinib	PD
	1	M	ADC	N/A	Negative (clone D5F3)	Positive	Del 5' 80% Split 6% Gains 20% Polysomy 65%	Crizotinib	PD
<b>Pelosi et al, [18]</b>	5	2F / 3M	LSC (4 pleomorphic carcinoma and 1 pulmonary blastoma)	4 current 1 never	Negative	Positive	N/A	Surgery	Early recurrence after radical surgery and died of disease shortly thereafter (N=2)
<b>Salido et al, (8)</b>	11	2F / 9M	5 ADC, 5 SCC, 1 BAC	7 current 3 former 1 never	Negative (clone D5F3)	Positive	N/A	Surgery N = 9 N/A N = 2	N/A
<b>Ilie et al, [11]</b>	2	1F / 1H	ADC	N/A	Positive (clone D5F3)	Negative	BA + high level of <i>ALK</i> polysomy	Chemotherapy	PD



## REFERENCES

- [1] R. Saffroy, V. Fallet, N. Girard, J. Mazieres, D.M. Sibilot, S. Lantuejoul, I. Rouquette, F. Thivolet-Bejui, T. Vieira, M. Antoine, J. Cadranel, A. Lemoine, M. Wislez, MET exon 14 mutations as targets in routine molecular analysis of primary sarcomatoid carcinoma of the lung, *Oncotarget*. 8 (2017) 42428–42437. <https://doi.org/10.18632/oncotarget.16403>.
- [2] N. Pécuchet, T. Vieira, N. Rabbe, M. Antoine, H. Blons, J. Cadranel, P. Laurent-Puig, M. Wislez, Molecular classification of pulmonary sarcomatoid carcinomas suggests new therapeutic opportunities, *Annals of Oncology: Official Journal of the European Society for Medical Oncology*. 28 (2017) 1597–1604. <https://doi.org/10.1093/annonc/mdx162>.
- [3] E.L. Kwak, Y.-J. Bang, D.R. Camidge, A.T. Shaw, B. Solomon, R.G. Maki, S.-H.I. Ou, B.J. Dezube, P.A. Jänne, D.B. Costa, M. Varella-Garcia, W.-H. Kim, T.J. Lynch, P. Fidias, H. Stubbs, J.A. Engelman, L.V. Sequist, W. Tan, L. Gandhi, M. Mino-Kenudson, G.C. Wei, S.M. Shreeve, M.J. Ratain, J. Settleman, J.G. Christensen, D.A. Haber, K. Wilner, R. Salgia, G.I. Shapiro, J.W. Clark, A.J. Iafrate, Anaplastic lymphoma kinase inhibition in non-small-cell lung cancer, *N. Engl. J. Med.* 363 (2010) 1693–1703. <https://doi.org/10.1056/NEJMoa1006448>.
- [4] A. Marchetti, A. Di Lorito, M.V. Pace, M. Iezzi, L. Felicioni, T. D'Antuono, G. Filice, L. Guetti, F. Mucilli, F. Buttitta, ALK Protein Analysis by IHC Staining after Recent Regulatory Changes: A Comparison of Two Widely Used Approaches, Revision of the Literature, and a New Testing Algorithm, *J Thorac Oncol.* 11 (2016) 487–495. <https://doi.org/10.1016/j.jtho.2015.12.111>.
- [5] S. Lantuejoul, I. Rouquette, H. Blons, N. Le Stang, M. Ilie, H. Begueret, V. Grégoire, P. Hofman, A. Gros, S. Garcia, N. Monhoven, M. Devouassoux-Shisheboran, A. Mansuet-Lupo, F. Thivolet, M. Antoine, J.-M. Vignaud, F. Penault-Llorca, F. Galateau-Sallé, A. McLeer-Florin, French multicentric validation of ALK rearrangement diagnostic in 547 lung adenocarcinomas, *Eur. Respir. J.* 46 (2015) 207–218. <https://doi.org/10.1183/09031936.00119914>.
- [6] A. Scattoni, A. Catino, L. Schirosi, L. Caldarola, S. Tommasi, R. Lacalamita, E.S. Montagna, D. Galetta, G. Serio, F.A. Zito, A. Mangia, Discordance between FISH, IHC, and NGS Analysis of ALK Status in Advanced Non-Small Cell Lung Cancer (NSCLC): a Brief Report of 7 Cases, *Transl Oncol.* 12 (2019) 389–395. <https://doi.org/10.1016/j.tranon.2018.11.006>.
- [7] M. Salido, L. Pijuan, L. Martínez-Avilés, A.B. Galván, I. Cañadas, A. Rovira, M. Zanui, A. Martínez, R. Longarón, F. Sole, S. Serrano, B. Bellosillo, M.W. Wynes, J. Albanell, F.R. Hirsch, E. Arriola, Increased ALK gene copy number and amplification are frequent in non-small cell lung cancer, *J Thorac Oncol.* 6 (2011) 21–27. <https://doi.org/10.1097/JTO.0b013e3181fb7cd6>.
- [8] R.C. Doebele, A.B. Pilling, D.L. Aisner, T.G. Kutateladze, A.T. Le, A.J. Weickhardt, K.L. Kondo, D.J. Linderman, L.E. Heasley, W.A. Franklin, M. Varella-Garcia, D.R. Camidge, Mechanisms of resistance to crizotinib in patients with ALK gene rearranged non-small cell lung cancer, *Clin. Cancer Res.* 18 (2012) 1472–1482. <https://doi.org/10.1158/1078-0432.CCR-11-2906>.
- [9] R. Katayama, A.T. Shaw, T.M. Khan, M. Mino-Kenudson, B.J. Solomon, B. Halmos, N.A. Jessop, J.C. Wain, A.T. Yeo, C. Benes, L. Drew, J.C. Saeh, K. Crosby, L.V. Sequist, A.J. Iafrate, J.A. Engelman, Mechanisms of acquired crizotinib resistance in ALK-rearranged lung Cancers, *Sci Transl Med.* 4 (2012) 120ra17. <https://doi.org/10.1126/scitranslmed.3003316>.
- [10] V. Fallet, J. Cadranel, H. Doubre, C. Toper, I. Monnet, T. Chinet, G. Oliviero, G. Foulon, H. De Cremoux, T. Vieira, M. Antoine, M. Wislez, Prospective screening for

Mis en forme : Anglais (Royaume-Uni)

- ALK: clinical features and outcome according to ALK status, *Eur. J. Cancer*. 50 (2014) 1239–1246. <https://doi.org/10.1016/j.ejca.2014.02.001>.
- [11] M.I. Ilie, C. Bence, V. Hofman, E. Long-Mira, C. Butori, L. Bouhlel, S. Lalvée, J. Mouroux, M. Poudenx, J. Otto, C.H. Marquette, P. Hofman, Discrepancies between FISH and immunohistochemistry for assessment of the ALK status are associated with ALK 'borderline'-positive rearrangements or a high copy number: a potential major issue for anti-ALK therapeutic strategies, *Ann. Oncol.* 26 (2015) 238–244. <https://doi.org/10.1093/annonc/mdu484>.
- [12] F. Zito Marino, G. Rocco, A. Morabito, C. Mignogna, M. Intartaglia, G. Liguori, G. Botti, R. Franco, A new look at the ALK gene in cancer: copy number gain and amplification, *Expert Rev Anticancer Ther.* 16 (2016) 493–502. <https://doi.org/10.1586/14737140.2016.1162098>.
- [13] J. Mazieres, A. Drilon, A. Lusque, L. Mhanna, A.B. Cortot, L. Mezquita, A.A. Thai, C. Mascaux, S. Couraud, R. Veillon, M. Van den Heuvel, J. Neal, N. Peled, M. Früh, T.L. Ng, V. Gounant, S. Popat, J. Diebold, J. Sabari, V.W. Zhu, S.I. Rothschild, P. Bironzo, A. Martinez-Marti, A. Curioni-Fontecedro, R. Rosell, M. Lattuca-Truc, M. Wiesweg, B. Besse, B. Solomon, F. Barlesi, R.D. Schouten, H. Wakelee, D.R. Camidge, G. Zalcman, S. Novello, S.I. Ou, J. Milia, O. Gautschi, Immune checkpoint inhibitors for patients with advanced lung cancer and oncogenic driver alterations: results from the IMMUNOTARGET registry, *Ann. Oncol.* 30 (2019) 1321–1328. <https://doi.org/10.1093/annonc/mdz167>.
- [14] C. Domblides, K. Leroy, I. Monnet, J. Mazières, F. Barlesi, V. Gounant, S. Baldacci, B. Menecier, A.-C. Toffart, C. Audigier-Valette, L. Doucet, E. Giroux-Leprieur, F. Guisier, C. Ricordel, O. Molinier, M. Perol, E. Pichon, G. Robinet, D. Templement-Grangerat, A.-M. Ruppert, N. Rabbe, M. Antoine, M. Wislez, Efficacy of Immune Checkpoint Inhibitors in Lung Sarcomatoid Carcinoma, *J Thorac Oncol.* 15 (2020) 860–866. <https://doi.org/10.1016/j.jtho.2020.01.014>.
- [15] M.P. Kotlowska, A.G. Rueda, M.E. Olmedo, A. Benito, A.S. Roldán, M.A. Fernandez Méndez, L. Gorospe, J. Palacios, P. Garrido López, Efficacy of immunotherapy in sarcomatoid lung cancer, a case report and literature review, *Respir Med Case Rep.* 26 (2019) 310–314. <https://doi.org/10.1016/j.rmcr.2019.02.017>.
- [16] C. Zhou, W. Li, J. Shao, J. Zhao, C. Chen, Analysis of the Clinicopathologic Characteristics of Lung Adenocarcinoma With CTNNB1 Mutation, *Front Genet.* 10 (2019) 1367. <https://doi.org/10.3389/fgene.2019.01367>.
- [17] Z. Mo, Y. Wang, Z. Cao, P. Li, S. Zhang, An Integrative Analysis Reveals the Underlying Association Between CTNNB1 Mutation and Immunotherapy in Hepatocellular Carcinoma, *Front Oncol.* 10 (2020) 853. <https://doi.org/10.3389/fonc.2020.00853>.
- [18] G. Pelosi, P. Gasparini, A. Cavazza, G. Rossi, P. Graziano, M. Barbareschi, F. Perrone, M. Barberis, M. Takagi, T. Kunimura, T. Yamada, Y. Nakatani, U. Pastorino, P. Scanagatta, G. Sozzi, M. Garassino, F. De Braud, M. Papotti, Multiparametric molecular characterization of pulmonary sarcomatoid carcinoma reveals a nonrandom amplification of anaplastic lymphoma kinase (ALK) gene, *Lung Cancer.* 77 (2012) 507–514. <https://doi.org/10.1016/j.lungcan.2012.05.093>.