



HAL
open science

Longitudinally Extensive Myelitis Associated With Immune Checkpoint Inhibitors

Alberto Picca, Giulia Berzero, Kevin Bihan, Vincent Jachiet, Edouard Januel, Marc Coustans, Cecile Cauquil, Julie Perrin, Pablo Berlanga, Nora Kramkimel, et al.

► **To cite this version:**

Alberto Picca, Giulia Berzero, Kevin Bihan, Vincent Jachiet, Edouard Januel, et al.. Longitudinally Extensive Myelitis Associated With Immune Checkpoint Inhibitors. *Neurology Neuroimmunology & Neuroinflammation*, 2021, 8 (3), pp.e967. 10.1212/NXI.0000000000000967 . hal-03263503

HAL Id: hal-03263503

<https://hal.sorbonne-universite.fr/hal-03263503v1>

Submitted on 17 Jun 2021

HAL is a multi-disciplinary open access archive for the deposit and dissemination of scientific research documents, whether they are published or not. The documents may come from teaching and research institutions in France or abroad, or from public or private research centers.

L'archive ouverte pluridisciplinaire **HAL**, est destinée au dépôt et à la diffusion de documents scientifiques de niveau recherche, publiés ou non, émanant des établissements d'enseignement et de recherche français ou étrangers, des laboratoires publics ou privés.

Longitudinally Extensive Myelitis Associated With Immune Checkpoint Inhibitors

Alberto Picca, MD, Giulia Berzero, MD, PhD, Kevin Bihan, PharmD, Vincent Jachiet, MD, Edouard Januel, MD, Marc Coustans, MD, Cecile Cauquil, MD, Julie Perrin, MD, Pablo Berlanga, MD, PhD, Nora Kramkimel, MD, PhD, Bethsabée Garel, MD, Perrine Devic, MD, François Ducray, Marion Benazra, MSc, Flavie Bompaire, MD, Delphine Leclercq, MD, Jean-Marie Michot, MD, PhD, Samy Ammari, MD, and Dimitri Psimaras, MD

Correspondence

Dr. Psimaras
dimitri.psimaras@aphp.fr

Neurol Neuroimmunol Neuroinflamm 2021;8:e967. doi:10.1212/NXI.0000000000000967

Abstract

Objective

To define the characteristics and the outcome of myelitis associated with immune checkpoint inhibitors (ICIs).

Methods

We performed a retrospective research in the databases of the French Pharmacovigilance Agency and the OncoNeuroTox network for patients who developed myelitis following treatment with ICIs (2011–2020). A systematic review of the literature was performed to identify similar cases.

Results

We identified 7 patients who developed myelitis after treatment with ICIs (anti-PD1 [n = 6], anti-PD1 + anti-CTLA4 [n = 1]). Neurologic symptoms included paraparesis (100%), sphincter dysfunction (86%), tactile/thermic sensory disturbances (71%), and proprioceptive ataxia (43%). At the peak of symptom severity, all patients were nonambulatory. MRI typically showed longitudinally extensive lesions, with patchy contrast enhancement. CSF invariably showed inflammatory findings. Five patients (71%) had clinical and/or paraclinical evidence of concomitant cerebral, meningeal, caudal roots, and/or peripheral nerve involvement. Despite the prompt discontinuation of ICIs and administration of high-dose glucocorticoids (n = 7), most patients needed second-line immune therapies (n = 5) because of poor recovery or early relapses. At last follow-up, only 3 patients had regained an ambulatory status (43%). Literature review identified 13 previously reported cases, showing similar clinical and paraclinical features. All patients discontinued ICIs and received high-dose glucocorticoids, with the addition of other immune therapies in 8. Clinical improvement was reported for 10 patients.

Conclusion

Myelitis is a rare but severe complication of ICIs that shows limited response to glucocorticoids. Considering the poor functional outcome associated with longitudinally extensive myelitis, strong and protracted immune therapy combinations are probably needed upfront to improve patient outcome and prevent early relapses.

From the Department of Brain and Behavioral Sciences (A.P., G.B.), University of Pavia, Italy; Regional Pharmacovigilance Center (K.B.), Department of Pharmacology, APHP; APHP (V.J., E.J.), Hôpital Saint-Antoine, Paris; CHI de Cornouaille (M.C.), Quimper; Service de Neurologie (C.C.), Hôpital Bicêtre, AP-HP, Le Kremlin-Bicêtre; Hôpitaux Privés de Metz (J.P.), Metz; Gustave Roussy (P.B.), Université Paris-Saclay, Villejuif; Service de Dermatologie (N.K., B.G.), Cochin Hospital AP-HP, Paris; Centre Hospitalier Universitaire Lyon Sud (P.D.), Hospices Civils de Lyon, Pierre-Bénite; Hospices Civils de Lyon (F.D.), Hôpital Neurologique, Bron; Inserm (M.B.), CNRS, UMR S 1127, Institut du Cerveau et de la Moelle épinière (ICM), Paris; OncoNeuroTox Group (F.B.), Hôpital Percy, Clamart; Service de Neuroradiologie (D.L.), AP-HP Pitié-Salpêtrière, Paris; Département d'Innovation Thérapeutique et d'Essais Précoces (J.-M.M.), Gustave Roussy, Villejuif; Department of Diagnostic Radiology (S.A.), Gustave Roussy, Villejuif; and Service de Neurologie 2 (D.P.), Groupe Hospitalier Pitié-Salpêtrière, APHP, Paris, France.

Go to [Neurology.org/NN](https://www.neurology.org/NN) for full disclosures. Funding information is provided at the end of the article.

The Article Processing Charge was funded by the authors.

This is an open access article distributed under the terms of the Creative Commons Attribution-NonCommercial-NoDerivatives License 4.0 (CC BY-NC-ND), which permits downloading and sharing the work provided it is properly cited. The work cannot be changed in any way or used commercially without permission from the journal.

Glossary

CTLA4 = cytotoxic T-lymphocyte-associated protein 4; **ICI** = immune checkpoint inhibitor; **irAE** = immune-related adverse event; **NSCLC** = non-small-cell lung cancer; **PD-1** = programmed death 1; **PDL-1** = programmed death-ligand 1.

Immune checkpoint inhibitors (ICIs) are monoclonal antibodies used for cancer treatment that enhance host immune responses toward tumor cells by blocking signaling pathways responsible for T cell inhibition (cytotoxic T-lymphocyte-associated protein 4 [CTLA4], programmed death 1 [PD-1]/programmed death-ligand 1 [PDL-1]).¹ Despite their remarkable oncological efficacy,¹ ICIs might result in unwanted immune reactions against the self.² Neurologic immune-related adverse events (irAEs) are relatively uncommon, but they might be severely disabling or even life threatening.³ Among them, myelitis seems especially rare, its description remaining limited to isolated cases. Here, we present 7 patients with ICI-related myelitis, together with a systematic review of the literature, with the aim to define the core characteristics and the outcome of this rare condition.

Methods

Present Series

We performed a retrospective research (July 2011–June 2020) in the database of the French Pharmacovigilance Agency and in the database of the OncoNeuroTox network (French network for neurologic complications from oncologic treatments) for cases of myelitis occurring during ICI treatment. Inclusion criteria comprised (1) symptoms of acute transverse myelitis (i.e., bilateral sensory, motor, or autonomic signs or symptoms attributable to spinal cord involvement, peaking between 4 hours and 21 days), (2) symptom onset within 3 months from the last dose of ICIs, (3) spinal cord lesions on MRI compatible with myelitis, and (4) exclusion of other causes of myelopathy (e.g., vascular, neoplastic, infectious, and compressive) after an extensive workup. Clinical and paraclinical data of the patients included in the study were gathered from referring centers and independently reviewed by 2 investigators (A.P. and D.P.). MRI scans were centrally reviewed by an expert neuroradiologist (S.A.). The French national commission for data protection and liberties approved the use of confidential, electronically processed, patient data (reference number 1922081).

Literature Review

We conducted a systematic MEDLINE research according to PRISMA guidelines for all articles published in English up to June 2020, reporting cases of myelitis during ICI treatment (appendix e-1, links.lww.com/NXI/A415). We identified 10 articles, reporting as many individual cases meeting the same inclusion criteria established for our series. Three additional cases were identified screening the proceedings of the AAN, EAN, andECTRIMS congresses (2015–2020).

Data Availability

Additional data can be made available on request to the authors.

Results

Present Series

The main clinical and paraclinical features in our 7 patients are reported in table 1. The cases of 2 patients (patients #1, 4) are being submitted elsewhere as separate publications. Patients were receiving anti-PD1 (pembrolizumab [n = 3], nivolumab [n = 3]) or combination treatments (nivolumab plus ipilimumab [n = 1]) because of refractory (2/7, 29%) or metastatic (5/7, 71%) tumors consisting of non-small-cell lung cancer (NSCLC) in 5 cases. Three patients (3/7, 43%) had received thoracic irradiation involving the spinal cord.

Symptoms of myelitis appeared after a median of 7 cycles of ICIs (range 3–51) and included moderate to severe paraparesis (7/7, 100%), sphincter dysfunction (6/7, 86%), tactile and/or thermic sensory deficits (5/7, 71%), and proprioceptive ataxia (3/7, 43%). At the peak of symptom severity, all patients were nonambulatory (median modified Rankin Scale score: 4).

Spine MRI showed longitudinally extensive lesions (i.e., ≥ 3 metameres) in 6 patients (6/7, 86%), often associated with spinal swelling (figure 1). Contrast enhancement was present in 6 cases (6/7, 86%) and was typically focal and patchy. In patients with a history of spinal irradiation, MRI alterations were primarily centered on irradiated metameres, although they clearly exceeded the radiation field.

CSF analysis commonly showed inflammatory changes, including increased proteins (5/6; median protein levels 1.83 g/L, range 0.32–5.20 g/L), lymphocytic pleocytosis (4/6; median cell count 97 cells/mm³, range 3–900 cells/mm³), and CSF-specific oligoclonal bands (3/6).

Information on CNS autoantibody testing is provided in table e-1, links.lww.com/NXI/A418. One patient tested positive for antigliab fibrillary acidic protein antibodies in the CSF (patient #4), and 2 showed atypical neuronal reactivities on in-house indirect immunofluorescence on rodent brain sections (patient #1, 7) (figure e-1, links.lww.com/NXI/A416). Anti-aquaporin-4 and antimyelin oligodendrocyte glycoprotein antibodies were negative in all patients tested.

Besides signs and symptoms of acute transverse myelitis, 5 patients (5/7, 71%) had clinical, neurophysiologic, and/or radiologic evidence of concomitant brain (patients 4, 6, and 7) (figure 1), meningeal (patients 4 and 7), radicular (patients 1, 3, 6, and 7), and/or peripheral nerve (patient 6) involvement.

All patients discontinued ICI treatment at myelitis diagnosis and received high-dose glucocorticoids, associated with

Table 1 Clinical and Paraclinical Features, Treatment, and Outcome in the 7 Cases of Myelitis Associated With ICI From Our Series

	Patient 1	Patient 2	Patient 3
Age at myelitis onset/sex	57/M	62/F	16/F
Malignancy	NSCLC	NSCLC	Mesenteric IMT
Previous RT involving the spinal cord	Thoracic (66 Gy/33 fr), 13 mo before onset	T4 vertebral body, 13 mo before onset	No
ICI received (cycles)	Nivolumab (12)	Nivolumab (7)	Pembrolizumab (19)
Neurologic syndrome	Myeloradiculitis	Myelitis	Myeloradiculitis
Clinical presentation	Severe paraparesis, neuropathic pain, and sphincter dysfunction	Severe paraparesis, sensory impairment with T11 level, and fecal and urinary incontinence	Moderate paraparesis, gait ataxia, sensory impairment with T6 level, radicular pain, and bladder dysfunction
mRS at symptom nadir	4	5	4
CSF cells (n/μL)	88	NA	3
CSF proteins(g/L)	3.76	NA	0.32
CSF-restricted OCB	Yes	NA	NA
CNS autoantibodies	Atypical antibody reactivity on rodent sections	NA	NA
Spine MRI findings	Multiple T2 hyperintensities at C7-T4 and T11-T12 with associated CE at C7-T2 and T11-T12; CE of filum terminale and caudal roots	Whole-spine T2 hyperintensity with focal CE T4-T6	Multiple T2 hyperintensities C4-C5, C7-T3, and T9-T12 with anterior patchy CE
Brain MRI findings	Unremarkable	Stable known brain metastases and radiation-induced leukoencephalopathy	Unremarkable
First-line treatment	Oral prednisone (1 mg/kg/die) tapered over 4 mo	IV MP	IV MP followed by oral tapering (from 1 mg/kg/die)
Myelitis relapse	Yes (3 weeks after the end of steroid tapering)	No	No
Second-line treatments	IV MP + PLEX (7 sessions) + monthly IV CP (\times 2)	No	No
Outcome at last follow-up	Persistent severe paraparesis	Death due to sepsis	Complete recovery
mRS score at last follow-up	4	6	0
Follow-up from myelitis onset (mo)	18	2	15

Abbreviations: CE = contrast enhancement, CP = cyclophosphamide, fr = fractions, Gy = gray, ICI = immune checkpoint inhibitor, IMT = inflammatory myofibroblastic tumor, IVIG = IV immunoglobulin, MP = methylprednisolone, mRS = modified Rankin Scale, NA = not available, NSCLC = non-small-cell lung cancer, OCB = oligoclonal bands, PLEX = plasmapheresis, RT = radiotherapy.

plasmapheresis in 1 (patient 4). One patient experienced a significant and sustained clinical benefit (patient 3), whereas 5 patients had to shift to second-line treatments because of poor recovery (patients 4, 5, and 7) or an early relapse at steroid tapering (patients 1 and 6; table 1). Second-line agents were started after a median of 20 days from symptom onset and included plasmapheresis (n = 3), cyclophosphamide (n = 2), IV immunoglobulin (IVIg, n = 1), natalizumab (n = 1), and an

association of tocilizumab and ruxolitinib (n = 1). At last follow-up, a median of 6 months after diagnosis, only 3 patients had regained an ambulatory status (3/7, 43%). None of the patients was rechallenged with ICIs.

Literature Review

Our systematic literature review identified 13 previously published cases.^{e1-e13} Clinical and paraclinical features were

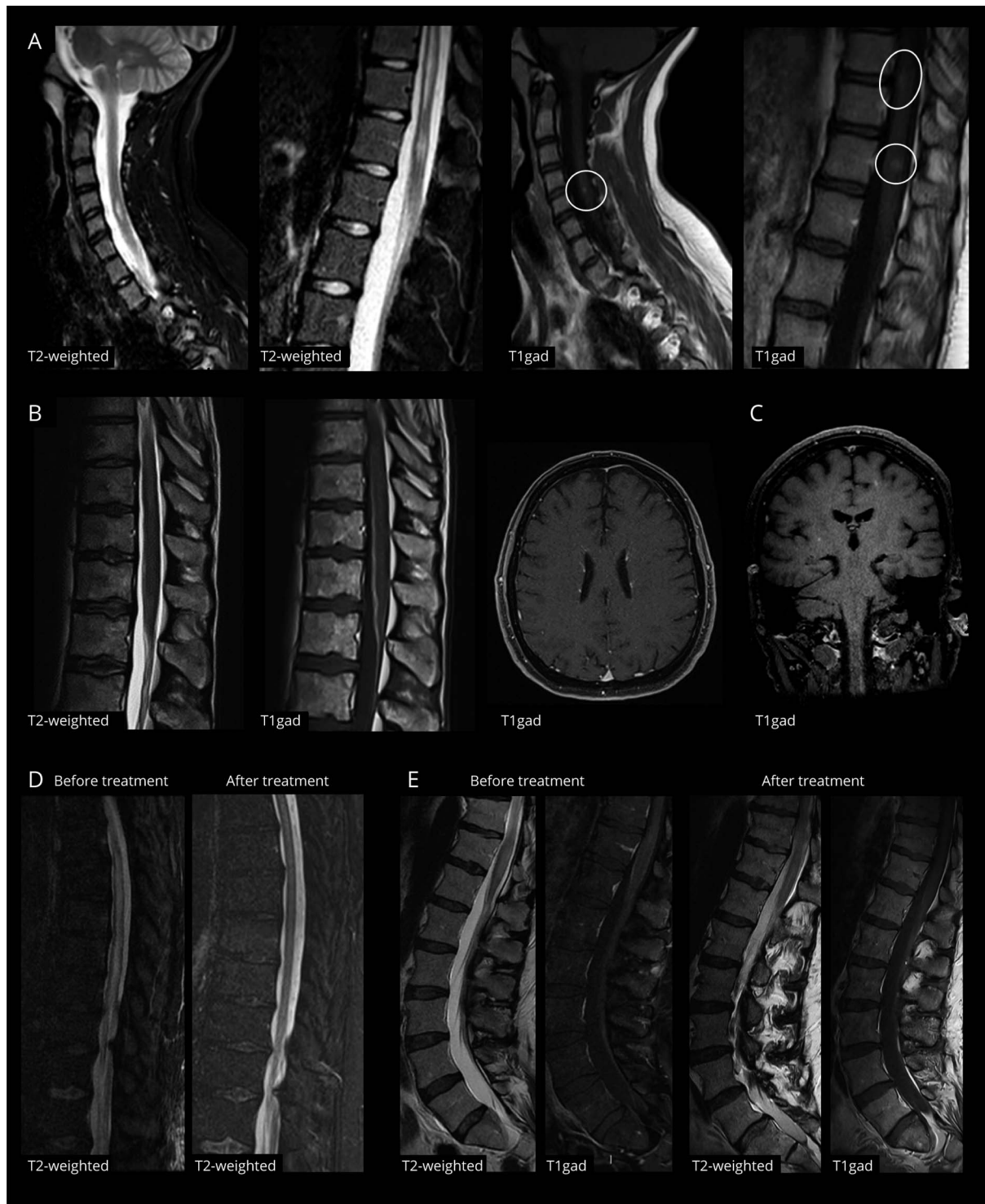
Table 1 (continued)

Patient 4	Patient 5	Patient 6	Patient 7
59/M	61/F	57/M	58/M
NSCLC	NSCLC	NSCLC	Melanoma
No	No	Mediastinal (66 Gy/33 fr), 13 mo before onset	No
Pembrolizumab (5)	Pembrolizumab (5)	Nivolumab (51)	Ipilimumab + nivolumab (4)
Meningoencephalomyelitis	Myelitis	Encephalomyelitis and demyelinating polyradiculoneuritis	Meningoencephalomyelioradiculitis
Severe tetraparesis, bladder dysfunction, neck stiffness, neuropathic pain, dysphagia, and altered consciousness	Moderate to severe paraparesis, left upper limb weakness, proprioceptive ataxia, and lower limb numbness	Severe paraparesis, proprioceptive ataxia, sensory impairment with T12 level, radicular pain, and bladder hyperactivity	Paraplegia, sensory impairment with T10 level, lower limb areflexia, and fecal and urinary retention
5	4	4	4
900	105	5	115
5.2	0.75	1.09	2.57
NA	Yes	Yes	No
Anti-GFAP antibodies	No	No	Atypical antibody reactivity on rodent sections
T2 hyperintensity from C1 to T10; CE of spinal leptomeninges	Focal T2 hyperintensity C3-C4 without CE	Multiple T2 hyperintensities at C3-C6, T2-T3, T8-T11 with faint CE at T8-T11; CE of caudal roots	Multiple T2 hyperintensities at C2, C3, C7-T2, T4-T7, T8-conus with associated patchy CE; CE of spinal leptomeninges and caudal roots
Faint periventricular CE with radial, linear pattern; leptomeningeal CE; bulbar T2 hyperintensity	Stable known brain metastasis	Multiple periventricular, thalamocapsular and right fronto-insular cortex T2 hyperintensities without CE	Multiple bilateral brain hemispheric and cerebellar punctiform, faint CE
IV MP + PLEX (15 sessions), oral prednisone (2 mg/kg/die) tapered over 2 mo	IV MP followed by oral prednisone tapering	IV MP followed by prednisone (1 mg/kg/die) tapered over 6 wk	IV MP, oral prednisone tapering (from 1 mg/kg/die, ongoing)
No	No	Yes (2 weeks after the end of the steroid tapering)	No
Natalizumab (x1)	Monthly IV CP (x6)	Monthly IVIG (x3) and PLEX (5 sessions)	PLEX (1 session), tocilizumab (x2) + ruxolitinib (23 days)
Persistent bladder disorder with need of intermittent urinary catheterization	Persistent disabling left arm and leg weakness and severe proprioceptive ataxia	Persistent leg weakness and hypesthesia and persistent disabling pain	Persistent leg weakness and hypesthesia, urinary retention, and fecal incontinence
2	4	4	3
6	6	6	5

similar to patients in our series (table 2), with contrast-enhancing longitudinally extensive lesions on MRI and inflammatory findings on CSF analysis. Four patients had positive CNS autoantibodies, including 2 with anti-

aquaporin-4 antibodies.^{e3,e5,e9,e11} All patients discontinued ICIs and received high-dose glucocorticoids, alone (8/13, 62%) or in association with other immune therapies (5/13, 38%). Three patients (3/13, 23%) shifted to second-line

Figure 1 MRI Findings in ICI-Associated Myelitis



(A) Spinal MRI at diagnosis in patient 3, showing multiple hyperintensities at C4-C5, T9-T11, and T12 on sagittal T2/STIR sequences, with focal areas of contrast enhancement on T1 sequences after gadolinium injection (circles). (B) Spinal and brain MRI at diagnosis in patient 4, who had positive antibodies to glial fibrillary acidic protein. Spinal MRI showed a faint hyperintensity at T10-T12 on T2/STIR sequences and a marked contrast enhancement of the anterior portion of the dural sac and of filum terminale on T1 sequences after gadolinium injection. Brain MRI in the same patient showed linear rims of contrast enhancement expanding radially from lateral ventricles. (C) Brain MRI at diagnosis in patient 7 showing small punctuate areas of contrast enhancement in bilateral subcortical and deep white matter, without corresponding signal alterations on FLAIR sequences (not shown). (D) Control spinal MRI of the thoracic tract (sagittal T2/STIR sequences) in patient 1, 15 days after starting treatment with high-dose glucocorticoids and plasmapheresis, showing an almost complete resolution of the longitudinally extensive hyperintensity of the spinal cord compared with initial imaging. (E) Control spinal MRI of the lumbar tract (sagittal T2/STIR and T1 sequences after gadolinium injection) in patient 7, 15 days after starting treatment with high-dose glucocorticoids, plasmapheresis, tocilizumab, and ruxolitinib, showing a marked reduction of the hyperintensity and swelling of the conus and of the associated leptomeningeal and caudal root enhancement compared with initial imaging. ICI = immune checkpoint inhibitor.

Table 2 Main Clinical and Paraclinical Features in Patients With Acute Transverse Myelitis During ICI Treatment From Our Present Series and Literature Review

	Present series	Literature review
N	7	13
Age at myelitis onset, median (range)	58 (16–62)	63 (35–75)
Sex ratio (male/female)	1.33 (4/3)	1.60 (8/5)
Malignancy, n (%)	NSCLC, 5/7 (71%) Melanoma, 1/7 (14%) Mesenteric IMT, 1/7 (14%)	Melanoma, 6/13 (46%) NSCLC, 4/13 (31%) Others, 3/13 (23%) ^a
Previous RT involving the spinal cord, n (%)	3/7 (43%)	3/13 (23%)
ICI treatment, n (%)	Anti-PD1, 6/7 (86%) Nivolumab, n = 3 Pembrolizumab, n = 3 Anti-PD1 + anti-CTLA4, 1/7 (14%)	Anti-PD1, 5/13 (38%) Pembrolizumab, n = 3 ^b Nivolumab, n = 2 Anti-PDL1, 2/13 (15%) Atezolizumab, n = 1 Durvalumab, n = 1 Anti-CTLA4, 2/13 (15%) Ipilimumab, n = 3 ^c Anti-PD1 + anti-CTLA4, 2/13 (15%)
Number of ICI cycles received, median (range)	7 (3–51)	3 (1–16)
Symptoms, n (%)	Paraparesis, 7/7 (100%) Sphincter dysfunction, 6/7 (86%) Tactile/thermic sensory deficits, 5/7 (71%) Proprioceptive ataxia, 3/7 (43%)	Paraparesis, 12/13 (92%) Sensory disturbances, 12/13 (92%) Sphincter dysfunction, 12/13 (92%)
Spine MRI findings, n (%)	T2 hypersignal extending for ≥3 metameres, 6/7 (86%) Parenchymal enhancement, 6/7 (86%)	T2 hypersignal extending for ≥3 metameres, 12/13 (92%) Parenchymal enhancement, 8/8 (100%)
CSF findings, n (%)	Increased proteins, 5/6 (83%) Increased cell count, 4/6 (67%)	Increased proteins, 9/10 (90%) Increased cell count, 9/10 (90%)
Involvement of other nervous structures, n (%)	5/7 (71%)	2/13 (15%)
Autoantibodies, n	Anti-GFAP, n = 1 To unknown CNS antigens, n = 2	Anti-AQP4, n = 2 ^{e3,e9} Anti-CV2, n = 1 ^{e11} To unknown antigen with an AQP4-like pattern, n = 1 ^{e5}
First-line treatment, n (%)	High-dose glucocorticoids, 7/7 (100%) Plus plasmapheresis, n = 1	High dose glucocorticoids, 13/13 (100%) Plus plasmapheresis, n = 3 Plus other treatment, n = 4 ^d
Second-line treatments, n (%)	Yes, 5/7 (71%) Plasmapheresis, n = 3 Cyclophosphamide, n = 2 IVIg, n = 1 Natalizumab, n = 1 Tocilizumab plus ruxolitinib, n = 1	Yes, 3/13 (23%) Infliximab, n = 2 Plasmapheresis, n = 2 Cyclophosphamide, n = 1
Myelitis relapse, n (%)	2/7 (29%)	2/13 (15%)
Outcome	Clinical improvement, 2/7 (29%) No improvement, 4/7 (57%) Death due to sepsis, 1/7 (14%)	Clinical improvement, 10/13 (77%) No improvement, 3/13 (23%)

Abbreviations: GFAP = glial fibrillary acidic protein; ICI = immune checkpoint inhibitor, IVIG = IV immunoglobulin, NSCLC = non-small-cell lung cancer, RT = radiation therapy.

^a Others included Hodgkin lymphoma, renal cell carcinoma, and small-cell lung cancer.

^b One patient under pembrolizumab previously received ipilimumab plus nivolumab.

^c One patient under ipilimumab previously received nivolumab.

^d Other treatments included IVIG, cyclophosphamide, rituximab, and bevacizumab (one case each).

treatments, including infliximab (n = 2), plasmapheresis (n = 2), and cyclophosphamide (n = 1). Clinical improvement was reported for 10 patients (10/13, 77%), 7 being ambulatory at

last follow-up (7/9, 78%). Relapses were observed in 2 cases (2/13, 15%).^{e-7,e13} A single patient was rechallenged with ICIs, with no additional toxicity.^{e8}

Discussion

Here, we reported 7 patients developing acute transverse myelitis following ICI treatment, which were identified through an extensive research in 2 independent national databases. Despite the limitations inherent to the retrospective nature of our methodology and the potential biases related to spontaneous notification,⁴ we could estimate that during the evaluated time frame, over 38,000 patients were treated with ICIs in France outside of clinical trials, making of ICI-related myelitis an extremely rare irAE.

Most patients in our series were affected by NSCLC, and almost half had received thoracic radiotherapy. Besides representing one of the most common indications to ICI treatment, NSCLC often requires the administration of local radiotherapy, which invariably delivers a dose to the spinal cord. By potentiating the immune responses elicited by ICIs,⁵ radiotherapy might indeed represent a predisposing factor to the development of myelitis.

Differently from other neurologic irAEs, myelitis was not invariably an early event. Clinical presentation was typical of acute transverse myelitis and was accompanied by inflammatory CSF findings and longitudinally extensive lesions on MRI. Of interest, in most cases, inflammatory changes extended to the brain parenchyma, the leptomeninges and caudal nerve roots, suggesting that it often exists a broader involvement of the nervous system that might have been underestimated in previous reports. A single patient in our series tested positive for known antibodies to neural antigens, although we recognize that screening for CNS antibodies was not always exhaustive (table e-1, links.lww.com/NXI/A418).

All patients in our series and in the literature received high-dose glucocorticoids as first-line treatment, as recommended by current guidelines,⁶ although most of them ultimately needed additional immune therapies because of the lack of functional improvement. This observation suggests that patients with longitudinally extensive myelitis might benefit from stronger upfront immune therapy schemes, as advocated for other threatening irAEs such as the myositis-myocarditis complex.⁷ Despite some data raised concern,⁸ glucocorticoid treatment does not seem to impair tumor control or patient survival⁹ and should be continued for at least 2 months⁶ to substantiate recovery and prevent early relapses.¹⁰ Targeted biological agents, such as natalizumab or tocilizumab, which have recently been experimented in this and other settings,⁷ should help to improve therapeutic results, without a risk of interfering with the antitumor activity of ICIs.

Acknowledgment

This publication uses data collected from all Regional Centers of Pharmacovigilance—organized in a French network of CRPV. The views expressed in this article are those of the authors and do not necessarily represent the ANSM position of the UMC or the World Health Organization. The

information comes from a variety of sources, and the probability that the suspected adverse effect is drug related is not the same in all cases.

Study Funding

The authors report no targeted funding.

Disclosure

Go to Neurology.org/NN for full disclosures.

Publication History

Received by *Neurology: Neuroimmunology & Neuroinflammation* October 26, 2020. Accepted in final form January 7, 2021.

Appendix 1 Authors

Name	Location	Contribution
Alberto Picca, MD	Groupe Hospitalier Pitié-Salpêtrière, Paris, France; University of Pavia, Italy	Designed and conceptualized the study; analyzed the data; and drafted the manuscript for intellectual content
Giulia Berzero, MD, PhD	Groupe Hospitalier Pitié-Salpêtrière, Paris, France; University of Pavia, Italy	Designed and conceptualized the study; analyzed the data; and drafted the manuscript for intellectual content
Kevin Bihan, PharmD	Groupe Hospitalier Pitié-Salpêtrière, Paris, France	Designed and conceptualized the study; analyzed the data; and drafted the manuscript for intellectual content
Vincent Jachiet, MD	Hôpital Saint-Antoine, Paris, France	Interpreted the data; major role in the acquisition of data; and revised the manuscript for intellectual content
Edouard Januel, MD	Hôpital Saint-Antoine, Paris, France	Major role in the acquisition of data and revised the manuscript for intellectual content
Marc Coustans, MD	Centre Hospitalier de Quimper, France	Major role in the acquisition of data and revised the manuscript for intellectual content
Cécile Cauquil, MD	Hôpital Bicêtre, Le Kremlin-Bicêtre, France	Major role in the acquisition of data and revised the manuscript for intellectual content
Julie Perrin, MD	Hôpitaux Privés de Metz, Metz, France	Major role in the acquisition of data and revised the manuscript for intellectual content
Pablo Berlanga, MD, PhD	Gustave Roussy, Villejuif, France	Major role in the acquisition of data and revised the manuscript for intellectual content
Nora Kramkimel, MD, PhD	Hôpital Cochin, Paris, France	Major role in the acquisition of data and revised the manuscript for intellectual content

Continued

Appendix 1 (continued)

Name	Location	Contribution
Bethsabée Garel, MD	Hôpital Cochin, Paris, France	Major role in the acquisition of data and revised the manuscript for intellectual content
Perrine Devic, MD	Centre Hospitalier Universitaire Lyon Sud, Pierre-Bénite, France	Major role in the acquisition of data and revised the manuscript for intellectual content
François Ducray	Hôpital Neurologique Pierre Wertheimer, Bron, France	Major role in the acquisition of data and revised the manuscript for intellectual content
Marion Benazra, MSc	Institut du Cerveau et de la Moelle épinière, Paris, France	Performed and interpreted the immunohistochemical analyses and revised the manuscript for intellectual content
Flavie Bompaire, MD	Hôpital D'Instruction Des Armées Percy, Clamart, France	Major role in the acquisition of data and revised the manuscript for intellectual content
Delphine Leclercq, MD	Groupe Hospitalier Pitié-Salpêtrière, Paris, France	Performed and interpreted the radiologic analyses and revised the manuscript for intellectual content
Jean-Marie Michot, MD, PhD	Gustave Roussy, Villejuif, France	Major role in the acquisition of data and revised the manuscript for intellectual content
Samy Ammari, MD	Gustave Roussy, Villejuif, France	Performed and interpreted the radiologic analyses and revised the manuscript for intellectual content

Appendix 1 (continued)

Name	Location	Contribution
Dimitri Psimaras, MD	Groupe Hospitalier Pitié-Salpêtrière, Paris, France; OncoNeuroTox Group, Paris, France	Designed and conceptualized the study; major role in the acquisition of data; analyzed the data; and drafted the manuscript for intellectual content

References

1. Ribas A, Wolchok JD. Cancer immunotherapy using checkpoint blockade. *Science* 2018;359:1350–1355.
2. Postow MA, Sidlow R, Hellmann MD. Immune-related adverse events associated with immune checkpoint blockade. *N Engl J Med* 2018;378:158–168.
3. Touat M, Talmasov D, Ricard D, Psimaras D. Neurological toxicities associated with immune-checkpoint inhibitors. *Curr Opin Neurol* 2017;30:659–668.
4. Bihan K, Lebrun-Vignes B, Funck-Brentano C, Salem JE. Uses of pharmacovigilance databases: an overview. *Therapie* 2020;75:591–598.
5. Hwang WL, Pike LRG, Royce TJ, Mahal BA, Loeffler JS. Safety of combining radiotherapy with immune-checkpoint inhibition. *Nat Rev Clin Oncol* 2018;15:477–494.
6. National Comprehensive Cancer Network (NCCN). Clinical Practice Guidelines in Oncology. Management of Immunotherapy-Related Toxicities. Version 1.2020. Available at: nccn.org/professionals/physician_gls/default.aspx. Accessed September 20, 2020.
7. Esfahani K, Elkrief A, Calabrese C, et al. Moving towards personalized treatments of immune-related adverse events. *Nat Rev Clin Oncol* 2020;17:504–515.
8. Faje AT, Lawrence D, Flaherty K, et al. High-dose glucocorticoids for the treatment of ipilimumab-induced hypophysitis is associated with reduced survival in patients with melanoma. *Cancer* 2018;124:3706–3714.
9. Petrelli F, Signorelli D, Ghidini M, et al. Association of steroids use with survival in patients treated with immune checkpoint inhibitors: a systematic review and meta-analysis. *Cancers* 2020;12:546.
10. Bruna J, Argyriou AA, Anastopoulou GG, et al. Incidence and characteristics of neurotoxicity in immune checkpoint inhibitors with focus on neuromuscular events: experience beyond the clinical trials. *J Peripher Nerv Syst* 2020;25:171–177.

Additional e-references e1–e13 available at: links.lww.com/NXI/A417.

Neurology[®] Neuroimmunology & Neuroinflammation

Longitudinally Extensive Myelitis Associated With Immune Checkpoint Inhibitors

Alberto Picca, Giulia Berzero, Kevin Bihan, et al.

Neurol Neuroimmunol Neuroinflamm 2021;8;

DOI 10.1212/NXI.0000000000000967

This information is current as of February 26, 2021

Updated Information & Services	including high resolution figures, can be found at: http://nn.neurology.org/content/8/3/e967.full.html
References	This article cites 9 articles, 1 of which you can access for free at: http://nn.neurology.org/content/8/3/e967.full.html##ref-list-1
Subspecialty Collections	This article, along with others on similar topics, appears in the following collection(s): All Immunology http://nn.neurology.org/cgi/collection/all_immunology All Oncology http://nn.neurology.org/cgi/collection/all_oncology Transverse myelitis http://nn.neurology.org/cgi/collection/transverse_myelitis
Permissions & Licensing	Information about reproducing this article in parts (figures, tables) or in its entirety can be found online at: http://nn.neurology.org/misc/about.xhtml#permissions
Reprints	Information about ordering reprints can be found online: http://nn.neurology.org/misc/addir.xhtml#reprintsus

Neurol Neuroimmunol Neuroinflamm is an official journal of the American Academy of Neurology. Published since April 2014, it is an open-access, online-only, continuous publication journal. Copyright Copyright © 2021 The Author(s). Published by Wolters Kluwer Health, Inc. on behalf of the American Academy of Neurology.. All rights reserved. Online ISSN: 2332-7812.

