



**HAL**  
open science

## **Brain metastases in endometrial cancer: a systematic review of the surgical prognostic factors**

Nathan Beucler, Aurore Sellier, Cédric Bernard, Christophe Joubert, Nicolas Desse, Arnaud Dagain

► **To cite this version:**

Nathan Beucler, Aurore Sellier, Cédric Bernard, Christophe Joubert, Nicolas Desse, et al.. Brain metastases in endometrial cancer: a systematic review of the surgical prognostic factors. *European Journal of Obstetrics & Gynecology and Reproductive Biology*, 2021, 258, pp.240-252. 10.1016/j.ejogrb.2021.01.007 . hal-03266673

**HAL Id: hal-03266673**

**<https://hal.sorbonne-universite.fr/hal-03266673>**

Submitted on 22 Jun 2021

**HAL** is a multi-disciplinary open access archive for the deposit and dissemination of scientific research documents, whether they are published or not. The documents may come from teaching and research institutions in France or abroad, or from public or private research centers.

L'archive ouverte pluridisciplinaire **HAL**, est destinée au dépôt et à la diffusion de documents scientifiques de niveau recherche, publiés ou non, émanant des établissements d'enseignement et de recherche français ou étrangers, des laboratoires publics ou privés.

# Brain metastases in endometrial cancer: a systematic review of the surgical prognostic factors

Nathan BEUCLER<sup>\*,1,2,3</sup>, Aurore SELLIER<sup>1,2</sup>, Cédric BERNARD<sup>1</sup>, Christophe  
JOUBERT<sup>1</sup>, Nicolas DESSE<sup>1</sup>, Arnaud DAGAIN<sup>1,4</sup>

\*Corresponding author: nathan.beucler@neurochirurgie.fr - +0033649149620 –

ORCID 0000-0003-3047-4234

*1 Neurosurgery department, Sainte-Anne Military Teaching Hospital, 2 boulevard Sainte-Anne, 83800 Toulon Cedex 9, France*

*2 Ecole du Val-de-Grâce, French Military Health Service Academy, 1 place Alphonse Laveran, 75230 Paris Cedex 5, France*

*3 Neuro-oncology department, Pitié-Salpêtrière University Hospital, AP-HP, Sorbonne University Medical School, 75013 Paris, France*

*4 Val-de-Grâce Military Academy, 1 place Alphonse Laveran, 75230 Paris Cedex 5, France*

## ABSTRACT

**Context:** although endometrial cancer is the fourth most common malignancy in women, dissemination to the brain is an exceptional event in the course of the disease. The aim of this review is to determine the important surgical prognostic factors for patients with endometrial cancer metastatic to the brain.

**Materials and methods:** report of two cases. Medline database was used to conduct a systematic literature review from inception to December 2020 looking for English-language articles focused on brain metastases from endometrial cancer

**Results:** the research yielded 108 articles, among which 23 articles were retained for a total of 87 patients. Mean age was 60 years-old  $\pm 11$  at the time of diagnosis of endometrial cancer, and most of the tumors were aggressive (grade 3) with an advanced-stage disease (FIGO III, IV). At the time of diagnosis of cerebral disease, a single brain metastasis ( $p < 0.0001$ ) and no extra-cerebra metastatic site ( $p = 0.0011$ ) were significant good prognostic factors for the median overall survival. Surgical excision of brain metastasis followed by radiotherapy provided the longest median overall survival compared to radiotherapy and/or chemotherapy, and surgery alone (respectively 32, 5.4 and 4.8 months,  $p < 0.0001$ ). An age of 60-year-old or less was not associated with a better prognosis.

**Conclusion:** This review confirms that surgical excision followed by radiotherapy is a reliable option in patients with a single brain metastasis from endometrial cancer and no extra-cerebral metastatic site. This work could help to adapt the Graded Prognostic Assessment for brain metastases in endometrial cancer.

# MANUSCRIPT

## INTRODUCTION

With an incidence of 88 068 in 2013 in the European Union (7% of all new cancers diagnosed in women), endometrial cancer (EC) is the fourth most common malignancy in women, the most frequent gynaecological tumor in developed countries and is ranked seventh in terms of mortality. [1–3] Mean age at diagnosis is 60 years old and it is revealed in 75% of the cases at an early stage (FIGO I-II) thanks to post-menopause abnormal uterine bleeding; [1,4] at this stage, the 5-year overall survival ranges from 74-91%. The 5-year overall survival falls to 57- 66% in FIGO stage III, and 20-26% in FIGO stage IV. [1,5] Consequently, EC carries a rather good prognosis which is highly correlated with surgical staging including the tumor's size, the extent of myometrial invasion and lymphovascular space involvement, histological type and grade, the presence of local and distant metastases, and the patient's age. Typical metastatic sites include the pelvis, the peritoneum, the lungs and the bones. Exceptionally, the course of the disease is impeded by one or multiple cerebral metastases (0.3-0.9% of the cases) which are associated with a more dismal prognostic. [6–11] To our knowledge, there is only one other contemporary review which included all subtypes of uterus tumors. This review aims to determine the optimal surgical strategy for brain metastases in women suffering from the most common types of advanced EC.

## MATERIALS AND METHODS

### *Case reports*

We report two cases of patients with brain metastasis from EC treated in our institution.

### *Literature review*

We conducted a systematic literature review focused on cerebral metastases from EC on Medline database (<https://pubmed.ncbi.nlm.nih.gov/>) from inception until December 2020. We used the advanced search mode with the following associations of Mesh terms in the

title: (brain metastasis OR brain metastases OR cerebral metastasis OR cerebral metastases OR brain OR cerebral) AND (uterus OR endometrial).

### *Inclusion and exclusion criteria*

All the English-language articles with individual extractable data concerning brain metastasis from EC were included in the quantitative analysis. The case series with no individual extractable data, but relevant information, were retained in the qualitative analysis. The exclusion criteria were articles not written in English, articles not directly relevant to the subject, articles reporting very rare tumoral subtypes, articles that could not be found despite being indexed in Medline, and articles without individual extractable data.

### *Data extraction*

All the articles included in the quantitative analysis were screened in a systematic manner and the following information was extracted as previously planned: patient's age at the time of diagnostic of EC; cancer grade and FIGO stage; treatment including type of surgery, adjuvant radiotherapy, brachytherapy, and chemotherapy; average interval until brain metastasis diagnosis; neurological symptoms; location of brain metastasis, presence of other metastatic sites; treatment of brain metastasis including neurosurgery, radiosurgery, adjuvant radiotherapy or chemotherapy; interval until patient's death or alive at last follow-up. This work was conducted in compliance with the Preferred Reporting Items for Systematic reviews and Meta-Analyses. [12]

### *Primary and secondary endpoints of the study*

The primary endpoint was to define the optimal treatment strategy for brain metastasis from EC. The secondary endpoint was to assess the importance of the usual major preoperative prognostic factors for brain metastases, but this time for EC (including the patient's age, the number of cerebral metastases, and the presence of extra-cerebral metastatic sites).

### *Statistical analyses*

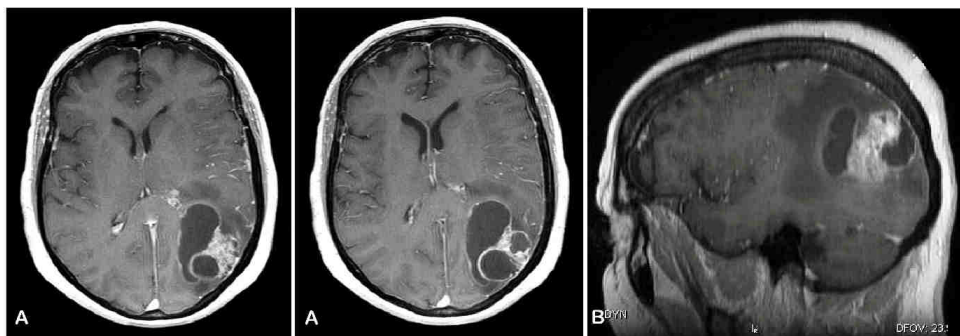
All statistical analyses were conducted using GraphPad Prism 8.0 (GraphPad Software Inc, San Diego, California). Categorical variables were presented as numbers and percentages, and continuous variables were presented as median and interquartile range (IQR). Median overall survival was defined as the time interval between diagnosis of brain metastasis and death from any cause and estimated using the Kaplan-Meier method. Survival rates were

presented in percentages with their 95% confidence interval (95% CI). Differences in survival depending on clinical or radiologic data (age, number of brain metastases and number of extra-cerebral metastatic sites) and on the type of treatment were assessed using the Log-rank (Mantel-Cox) test. A two-sided p-value of less than 0.05 was considered to indicate statistical significance.

## RESULTS

### *Case 1*

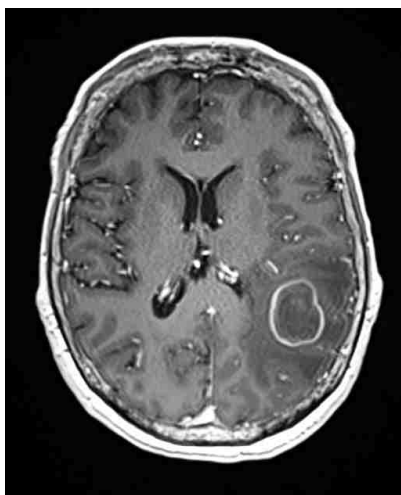
A 70-year-old patient was operated on by hysterectomy for endometrioid adenocarcinoma. Three years later, she presented local recurrence and benefited from total pelvicctomy with healthy margins consistent with a grade 2, FIGO IVA endometrioid adenocarcinoma. The tumor was adherent to the bladder and the rectum, and there was a vaginal fistula. The patient underwent adjuvant pelvic radiotherapy and chemotherapy. Two months later, she presented amnesia and psychomotor retardation. Neuroimaging revealed a parieto-occipital lesion with a heterogeneous nodular and necrotic portion, and a deeper ring-enhanced cystic portion, responsible for a large vasogenic cerebral edema (Fig. 1). She underwent craniotomy and complete resection of this brain lesion which presented a clear cleavage plane with the adjacent cerebral parenchyma. Pathology report was consistent with a metastasis from EC. Immunohistochemical analysis showed estrogen receptors + + + +, progesterone receptors +, CK7+, EMA ++. She benefited from surgical site radiotherapy afterwards. The PET-scan did not reveal any extra-cerebral metastatic site. Anti-epileptic medication (levetiracetam) was stopped 6 years after brain surgery. Nine years after, she is doing well, and she is free of disease.



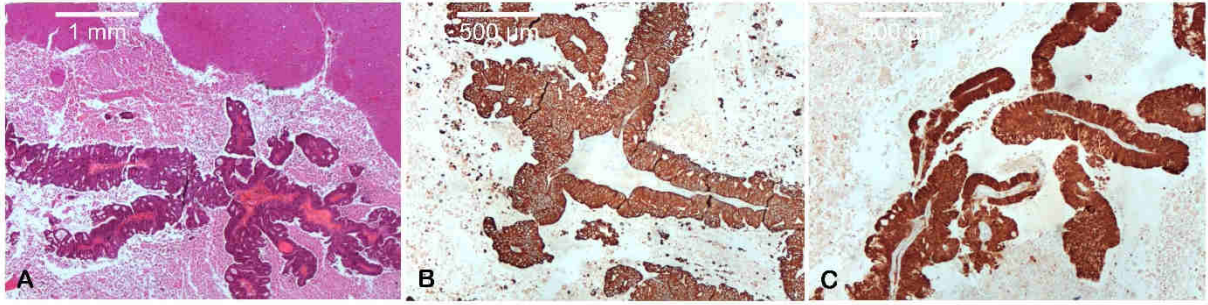**Figure 1.** Post-contrast T1-weighted brain MRI shows a left parietal metastasis with a peripheral nodular portion and large deep ring-enhanced cysts in axial (A) and sagittal (B) view.

## Case 2

A right-handed 53-year-old patient was diagnosed with stage II endometrial adenocarcinoma. She was treated with radiotherapy, chemotherapy (cisplatin) and finally brachytherapy. A few months later, she was diagnosed with cervical lymph node progression and she was treated with a second-line chemotherapy (paclitaxel, carboplatin). Eight months later, subdiaphragmatic lymph nodes appeared and she was treated with a third-line chemotherapy (doxorubicine). Finally, she presented disseminated lymphatic disease (subclavicular fossa, mediastinal, para-aortic) and was treated with a fourth-line chemotherapy (gemcitabine). At this time, she developed motor dysphasia and right hemiparesis. Neuroimaging revealed a lesion in the left parietal lobe with a larger diameter of 26mm, facing the ventricular trigone, with heterogeneous enhancement and responsible for an important vasogenic cerebral edema (Fig. 2). She Underwent craniotomy and resection of the lesion which presented a cleavage plane with the surrounding cerebral parenchyma. The pathology report was consistent with a mildly differentiated (grade 2) endometrial metastasis. Immunohistochemical study revealed CK7+ CKK20+, CDX2+, estrogen receptor- (Fig. 3). After the surgery, the patient presented a transient parietal lobe syndrome with mild alexia and incomplete Wernicke's aphasia, and she was sent to intensive neurological rehabilitation. She benefited from postoperative stereotactic radiosurgery with cyberknife™ on the surgical cavity. After 6 months, her neurological condition improved and there was no evidence of cerebral relapse.



**Figure 2.** Post-contrast T1-weighted brain MRI shows a left parietal ring-enhanced cystic metastasis facing the ventricular trigone.



**Figure 3.** Pathology examination using optical microscope. (A) Adenocarcinomatous tumoral tissue (black arrowheads) within the cerebral parenchyma (white arrowhead) (2.5x magnification). Immunohistochemical examination shows expression of (B) CK7 and (C) P16 (5x magnification).

## LITERATURE REVIEW

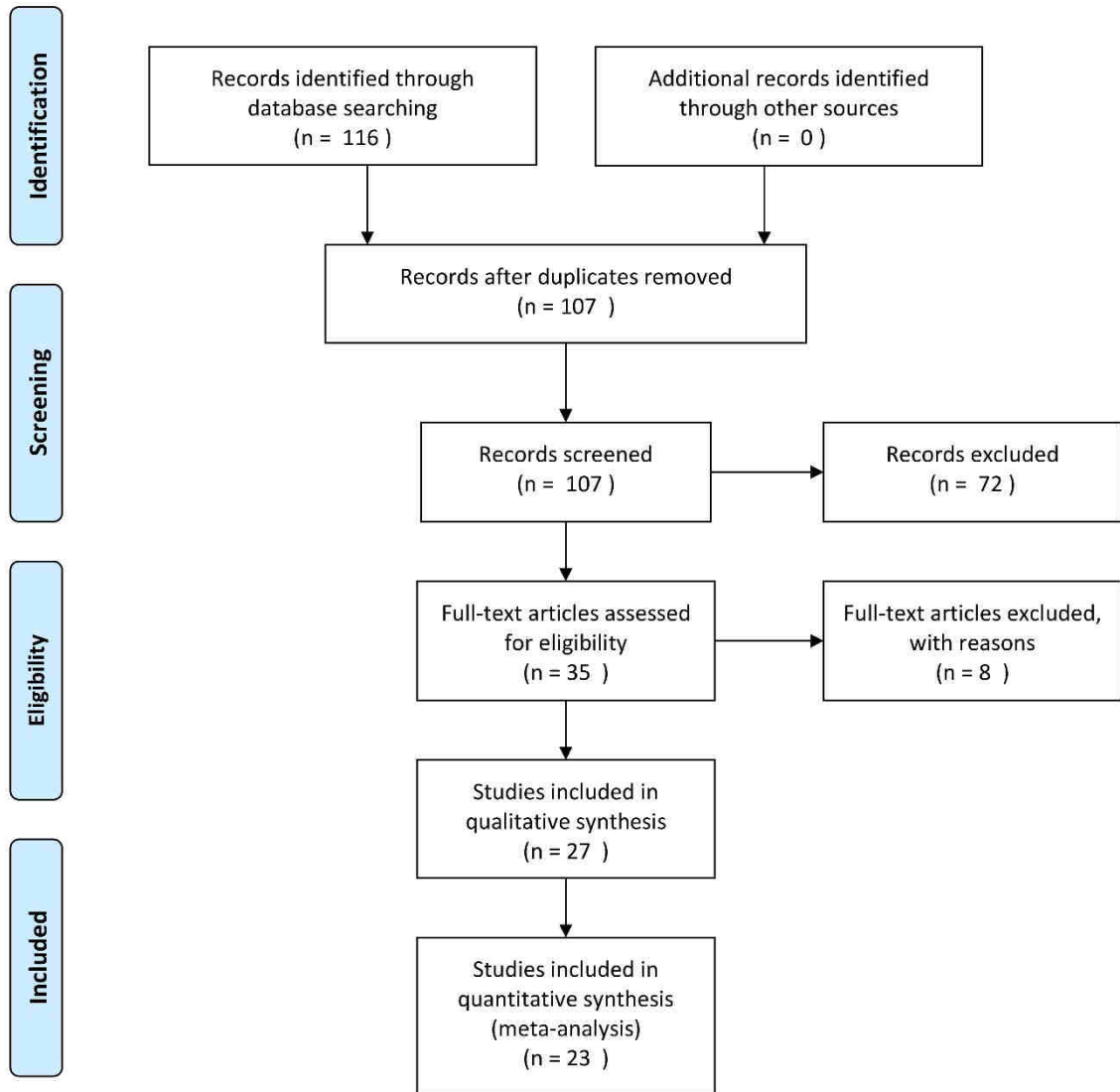
### *Database research*

Reports concerning patient suffering from endometrial malignancy with brain metastases ranged from 1975 to 2019 [6–8,11,13–31]. The research yielded 117 articles, and 108 after exclusion of duplicated works. After the first screening, 72 articles met the exclusion criteria. Among the 36 articles retained, eight articles also met the exclusion criteria after full reading of the content. Among the 28 articles included in the qualitative analysis, 23 articles with extractable individual data (18 case reports -up to 3 patients- and 5 case series) were included in the quantitative analysis. PRISMA flow diagram is provided in Fig. 4. Patients' characteristics, demographics and clinical presentation A total of 87 patients were included in this series.





## PRISMA 2009 Flow Diagram



From: Moher D, Liberati A, Tetzlaff J, Altman DG, The PRISMA Group (2009). Preferred Reporting Items for Systematic Reviews and Meta-Analyses: The PRISMA Statement. PLoS Med 6(7): e1000097. doi:10.1371/journal.pmed1000097

For more information, visit [www.prisma-statement.org](http://www.prisma-statement.org).

Figure 4. PRISMA flowchart for systematic review on Medline database focused on brain metastases from endometrial cancer.

The mean age of the patients at the time of diagnosis of endometrial malignancy was 59 ( $\pm 11$ ) years old. EC was most of the time revealed by post-menopause abnormal uterine bleeding. The most frequent subtype of cancer was endometrial adenocarcinoma (84%, n = 73) followed by serous carcinoma (4.6%, n = 4), clear cell carcinoma (4.6%, n = 4) and rarely mixed müllerian tumor. Half of the tumors were classified as grade 3 (54%, n = 47) and one-sixth as grade 2 (15%, n = 13). Half of the patients suffered from an advanced-stage disease ranked as FIGO III or IV (55%, n = 48). The patients' complete clinical data are provided in Table 3.

Characteristics	Number of patients (percentage) / mean value
Number of patients included	87
Mean age at endometrial cancer diagnosis	59 $\pm$ 11
$\leq$ 60 year-old	46 (52.9%)
Brain met operated on	24 (52.2%)
> 60 year-old	41 (47.1%)
Brain met operated on	18 (43.9%)
<b>Subtypes of cancer</b>	
adenocarcinoma	73 (83.9%)
serous carcinoma	4 (4.6%)
clear cell carcinoma	4 (4.6%)
Other subtypes	6 (6.9%)
<b>Tumor grade</b>	
1	5 (5.7%)
2	13 (14.9%)
3	47 (54%)
<b>Cancer stage</b>	
I	23 (26.4%)
II	7 (8%)
III	30 (34.5%)
IV	18 (20.7%)
<b>Hysterectomy</b>	78 (89.7%)
plus radiotherapy and chemotherapy	24 (30.8%)
plus radiotherapy	21 (27%)
plus chemotherapy	6 (7.7%)
No hysterectomy in prevalent brain mets	3 (3.3%)

**Table 1 part 1.** Patients' characteristics: endometrial cancer

### *Treatment of endometrial cancer*

Total hysterectomy and bilateral adnexectomy was performed in 90% of the patients (n = 78/87). Although systematic pelvic lymphadenectomy with or without para-aortic lymphadenectomy is the standard surgical treatment in non-stage I FIGO EC, it was explicitly reported in only 18% of the patients who were operated on (14/78). Postoperative adjuvant therapy consisted in radiotherapy plus chemotherapy (18 patients), radiotherapy

plus brachytherapy (4 patients), radiotherapy plus brachytherapy and chemotherapy (1 patient), radiotherapy alone (17 patients), and chemotherapy alone (5 patients). Three patients with brain metastasis prevalent to the diagnosis of endometrial malignancy were not operated on (Table 1.1).

Characteristics	Number of patients (percentage) / mean value
<b>Brain metastasis</b>	
Average time to brain metastasis (months)	24.7 ( $\pm$ 35)
Average time to secondary brain metastasis	29.3 ( $\pm$ 36)
Prevalent brain metastasis	10 (11.5%)
Operated on	6 (60%)
Concomitant brain metastasis	3 (3.4%)
Operated on	3 (100%)
Single	51 (58.6%)
Operated on	33 (64.7%)
Two	16 (17.2%)
Operated on	6 (37.5%)
Multiple	20 (23%)
Operated on	3 (15%)
Infratentorial	22 (25.3%)
Operated on	6 (27.3%)
<b>Neurological symptoms</b>	
Focal signs	53 (60.9%)
Hemiparesis (focal sign)	34 (64.2%)
Intracranial hypertension (ICH)	29 (32.2%)
Severe ICH (drowsiness)	3 (10.3%)
Seizures	12 (13.8%)
<b>Other metastatic sites</b>	
Patients free of other metastatic site	35 (40.2%)
Operated on	27 (77%)
Patients with extra-cerebral metastases	52 (59.8%)
Operated on	15 (28.9%)
Lung	31 (35.6%)
Peritoneum	14 (16.1%)
Pelvis	12 (13.8%)
Bone	12 (13.8%)
<b>Brain metastasis treatment</b>	
All craniotomies	42 (48.3%)
Craniotomy + radiosurgery	2 (4.8%)
Craniotomy + radiotherapy	32 (81%)
Craniotomy alone	8 (19%)
Radiosurgery alone	2 (2.3%)
Radiotherapy alone	31 (35.6%)
Palliative care	12 (13.8%)
Mean age	59.2
extreme age ( $\geq$ 79 year-old)	2 (16.7%)
Multiple brain metastases	5 (41.7%)
Deep brain metastases	2 (16.7%)

**Table 1 part 2.** Patients' characteristics: brain metastases

### *Clinical presentation of cerebral metastases*

The average time from EC to the diagnosis of brain metastases was  $25 \pm 35$  months. Fifteen percent of the patients ( $n = 13$ ) presented with "primary" (synchronous) brain metastases; among them, 11.5% ( $n = 10$ ) presented with a prevalent brain metastasis and three percent

(n = 3) with concomitant EC and brain metastasis at diagnosis. The average time between endometrial malignancy and “secondary” (metachronous) brain metastasis was 29 ±36 months for the rest of the 85% of the patients (n = 74) in this review.

The most frequent neurological symptoms were focal signs in 61% of the patients (n = 53), including hemiparesis in 34 patients, symptoms of intracranial hypertension or headaches in 32% of the patients (n = 29), and seizures in 14% of the patients (n = 12). Fifty-nine percent of the patients (n = 51) presented a single brain metastasis, 17% of the patients (n = 16) presented two brain metastases, and 23% (n = 20) presented multiple brain metastases. (Table 1.2)

### *Treatment of cerebral metastases*

Forty eight percent of the patients (n = 42/87) benefited from a neurosurgical procedure. Eighty-one percent of them (n = 32/42) benefited from radiotherapy and five percent (n = 2/42) benefited from radiosurgery. Surgical excision (SE) was the sole treatment for 19% of the patients (n = 8/42). Radiosurgery alone was performed in two percent of the cases (n = 2/87), and radiotherapy alone was performed in 36% of the cases (n = 31/87). With regards to the number of brain metastasis, 65% of the patients (n = 33/51) with a single brain metastasis were operated on, which decreased to 38% (n = 6/16) in case of two brain metastases, and down to 10% (n = 3/20) in case of multiple brain metastases.

With regards to the stage of EC, 40% of the patients (n = 35) presented without any evidence of extra-cerebral disease and 77% of them (n = 27/35) benefited from a neurosurgical procedure. Sixty percent of the patients (n = 52) presented at least one extra-cerebral metastatic site and 29% of them (n = 15/52) were operated on.

### *Outcome*

The median overall survival was 15 months (IQR 2-12) in this series. The patients treated with craniotomy-excision followed by radiotherapy (n = 32) presented a median overall survival of 32 months (IQR 9-48), compared to 5.4 months (IQR 2-6) for patients treated with radiotherapy and/or chemotherapy (n = 31), and 4.8 months (IQR 1.3125-8) for patients treated with surgery alone (n = 8) (p < 0.0001).

The patients with a single brain metastasis (n = 51) presented a median overall survival of 21.7 months (IQR 3.25-27.25) compared to 5.8 months (IQR 1-5) for patients with at least two brain metastases (n = 36) (p < 0.0001). The patients free of extra-cerebral disease (n =

35) presented a median overall survival of 22.9 months (IQR 3.25-29.5) compared to 10 months (IQR 1-8.25) for the patients suffering from extra-cerebral metastases (n = 52) (p = 0.0011).

The patients aged 60 years-old or younger presented a median overall survival of 17 months (IQR 1.8125-15.75) compared to 13 months (IQR 2-9.25) for the patient older than 60 (p = 0.58). Kaplan-Meier estimate are provided in Fig. 5 and Table 2.

<b>Characteristics</b>	<b>Number of patients</b>	<b>Average survival (months)</b>	<b>Statistical significance</b>
<b>Age</b>			P = 0.58
≤ 60	46	17.02	
> 60	41	12.54	
<b>Number of brain metastases</b>			P < 0.0001
1	51	21.4	
>1	36	5.83	
<b>Number of extra-cerebral metastatic sites</b>			P = 0.0011
0	35	22.27	
≥ 1	52	9.96	
<b>Treatment of brain metastasis</b>			P < 0.0001
Surgery + gammaknife	2	84	
Surgery + radiotherapy	32	28.18	
Gammaknife	2	10.5	
Radiotherapy	31	5.02	
Surgery	8	4.75	
Other	12	1.06	

**Table 2.** Significant prognostic factors in patients with brain metastasis from endometrial cancer, based on the criteria from the Graded Prognostic Assessment for brain metastases.

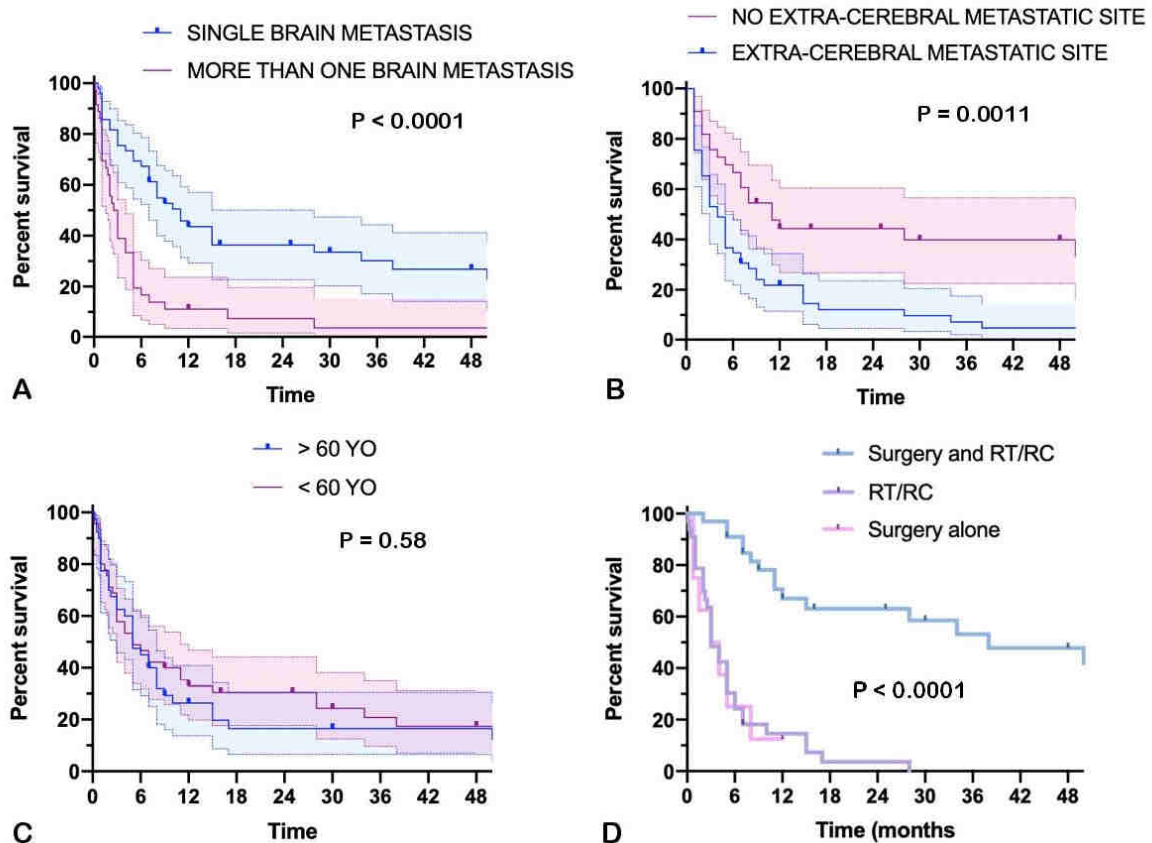


Figure 5. Kaplan-Meier estimate depending on (A) the number of cerebral metastases (one versus at least two), (B) the presence of extra-cerebral metastatic sites (none versus at least one), (C) the age of the patient (60 or less versus more than 60), and (D) the treatment of cerebral metastases (surgery plus radiotherapy versus other treatments).

## DISCUSSION

### *Previous series in the literature*

To our knowledge, there is only one other contemporary review focused on brain metastases from EC which included 98 reported cases. This research was conducted on Medline database with broader inclusion criteria, namely articles written in four different languages (English, French, Spanish and Italian) and including all the subtypes of EC. [8] To ensure some homogeneity in the present study, rare histological subtypes of EC were purposely excluded. Another contemporary monocentric retrospective case series reported the outcome of 30 patients treated for brain metastases from EC and is discussed further below. [32]

### *Pre-operative considerations*

In this review, the presence of a single brain metastasis was identified as a good prognostic factor with a median overall survival of 21.7 months ( $p < 0.0001$ ). In the same way, the absence of extra-cerebral metastatic sites was identified as a good prognostic factor with a median overall survival of 22.9 months ( $p = 0.0011$ ). In our opinion, these are the two most important criteria to be taken into account to further discuss the therapeutic strategy. The treatment of cerebral metastases is exhausting for the patient, whether it is SE of stereotactic radiotherapy, and these two factors illustrate the importance of patient selection. Ideally, SE should be performed for healing purpose of the cerebral disease in patients with a manageable extra-cerebral disease. In other less encouraging situations such as large symptomatic lesions with intracranial hypertension refractory to medical treatment, or multiple lesions with no histological diagnostic, SE may be required for symptomatic and/or for diagnostic purpose. In any event, patients with cannonball brain metastases or with an advanced-stage extra-cerebral disease should not be operated on because they wouldn't even withstand the procedure. Surprisingly, an age of 60-year-old or less was not associated with a better median overall survival ( $p = 0.58$ ).

We purposely chose to ascertain the relevance of these potential prognostic factors in the case of brain metastases from EC because they are recurrently found in the pre-operative scoring systems for brain metastases. The Graded Prognostic Assessment (GPA) score has been defined for six different types of cancers (non-small-cell and small-cell lung cancer, melanoma, breast cancer, renal cell carcinoma, and gastro-intestinal cancer) and variably includes the patient's age, the Karnofsky Performance Status (KPS), the number of cerebral metastases, the presence of extra-cerebral metastatic sites, and the subtype of cancer. [33,34] It displays a strong prognostic value and it is easily applicable in a daily clinical practice. [35] The Recursive Partitioning Analysis score includes the patient's age, the KPS, and the presence of extra-cerebral metastatic sites. [36]. Unfortunately, we could not determine the KPS of the patients in our series because of incomplete clinical data.

### *Surgical considerations*

Most of the time, there is a difference of consistency between the metastasis and the surrounding brain parenchyma and, even though there is not a real capsule, a cleavage plane can be found making "en-bloc" excision feasible. This must be nuanced in cystic metastases where a breach in the cyst's wall may result in the emptying of the content and the collapsing of the tumor, making complete excision tricky. To ensure complete SE, the

surgeon may perform a supra-total excision by removing a thin strip of adjacent parenchyma, or he can refill the metastatic cyst with fibrin glue to pursue the dissection. [37] In our institution, we faced two authentic cystic metastases from EC (Fig. 1 and 2). Nevertheless, only two other cases of cystic metastases were clearly reported in this review. [20,24]

### *Therapeutic strategy for brain metastasis*

In this review, SE followed by radiotherapy provided a better median overall survival than radiotherapy and/or chemotherapy, or surgery alone (respectively 28 months versus 5.2 or 4.8,  $p < 0.0001$ ). Since the 1990s, SE followed by whole brain radiotherapy (WBRT) has proven its benefits for the treatment of a single brain metastasis. [38,39] However, recent advances in targeted therapies have improved the prognosis of cancer patients. Consequently, the neurosurgeon and the radiation therapist now also face the need of preserving the patient's higher cerebral functions. In this context, stereotactic radiosurgery (SRS) has become a valuable therapeutic option in case of metastasis measuring less than 3cm, or in case of multiple small cerebral metastases. [40] The efficiency of SRS is comparable to SE in such case, even for radioresistant brain metastases. [41,42] SRS has also become a possible therapeutic option for cystic metastases. [43] Finally, SRS can be used for the irradiation of the surgical site after SE of a brain metastasis. [44] Thus, SE and SRS can be seen as two useful therapeutic options for patients suffering from brain metastases. [45,46] The former provides immediate mass effect relief for symptomatic large or cystic brain metastases, while the latter provides a less-invasive long-term control over one or multiple smaller lesions. These options must nowadays be preferred in order to defer the neurocognitive impairment induced by WBRT for patients who present longer life expectancy. [47]

Unfortunately, we could not determine the type of radiation therapy received by some of the patients in this review because of a lack of data. Thirty-eight percent of the patients ( $n = 33/87$ ) benefited from WBRT, five percent of the patients ( $n = 4/87$ ) benefited from SRS, and 34% of the patients ( $n = 30/87$ ) benefited from radiotherapy of unknown nature. Patients treated with SE followed by SRS ( $n = 2$ ) seemed to present the longest median overall survival (84 months), followed by SE plus radiotherapy ( $n = 32$ , 32.4 months), radiotherapy and / or chemotherapy ( $n = 43$ , 5.3 months) and finally SE alone ( $n = 8$ , 4.8 months); nevertheless, these results cannot be generalized.



Naturally, the patients with a single brain metastasis and those with no extra-cerebral metastatic sites seemed more likely to benefit from a neurosurgical procedure than the others (65% vs 38% and 77% vs 29%, respectively). It was therefore difficult to ascertain if the positive outcome in the SE plus radiotherapy group was due to the preoperative selection of the patients, the impact of an aggressive surgical strategy, or the possible indolence of the tumor.

Lastly, SE is required in case of etiologic doubt. This is particularly relevant in patients with history of EC because the occurrence of brain metastases is an exceptional event in the natural course of the disease. This can be a supplementary argument toward SE for diagnostic purpose in the case of EC.

Bhambhani et al. presented a monocentric retrospective series of 30 patients treated for brain metastases from EC. [32] All histological subtypes were included. Mean age was 62-year-old and 80% of the patients were diagnosed with FIGO stage III tumors, which is surprisingly more aggressive than the findings in our review. The average time until the diagnosis of brain metastases was 20.8 months. The median overall survival was 6.8 months. Patients treated with SE and SRS (n = 11/30, 37%) presented a median overall survival of 15.7 months compared to 5.6 months for patients treated with SRS alone (n = 17/30, 57%). These results significantly differ from our findings and may be in part explained by the aggressive character of the tumors in the authors' series.

#### *Retrospective analysis of our cases in the light of this review*

The two patients treated in our institution benefited from SE of a single symptomatic brain metastasis and postoperative SRS of the surgical cavity. The first-one was 70 years-old with a single symptomatic brain lesion and was free of extra-cerebral disease. The second-one was 53 years-old with a single symptomatic brain lesion and a slowly progressive disease. In both cases, the SE was performed after multidisciplinary team meeting in the setting of a personalized cancer treatment plan. The long survival of the first patient (nine years) and the good recovery of the second patient let us think that they both met wise inclusion criteria for the SE of the brain metastasis.

#### *Limitations*

This work presents some limits inherent to its retrospective nature. Case reports unconsciously select patients with favourable outcome; thus, the compilation of such

articles may lead to a reporting bias which underestimates the mortality rate. What is more, there is an attrition bias due to the loss of information between the medical file of the patient, the reporting of the case by the sole author and then our own collect of information for this review. There was a lack of data concerning the treatment of EC in some of the case series, as well as for the management of cerebral metastases. Besides, a few works were carried out before SRS was available as an effective treatment for small size metastases. Because of the small size of our series, we could not distinguish all the treatment options in the statistical analysis.

## CONCLUSION

In the light of this review, patients with history of EC who are suffering from a single brain lesion with a controlled systemic disease could benefit from the SE of the lesion for diagnostic purpose, symptomatic relief and as part of the treatment. After confirmation of the diagnosis of cerebral metastasis, the patient should benefit from stereotactic radiotherapy of the surgical site. The neurosurgical indication should be part of a multidisciplinary team meeting; its goal remains the cerebral control of the disease which requires medical treatment afterwards. The Graded Prognostic Assessment (GPA) score provides a simple and reliable tool reflecting the most important factors for whether to perform surgery for brain metastases: it is a score adapted for the six most frequent types of cerebral metastases. Our work could help to adapt the GPA score for brain metastasis in EC. Multicentric prospective trials are required to validate these data.

Author - year	age	type of cancer	FIGO stage	treatment	Interval to CNS meta diagnosis (months)	neurological symptoms	Number of brain mets	brain metastasis location	meningitis	other metastatic sites	surgery	radiotherapy	chemotherapy	Outcome (months)
1 Nakano 1975	72	adenocarcinoma		HYAN	26	ICH, aphasia, right hemiparesis	1	left parieto-occipital			craniotomy-resection	WBRT 30Gy		1
2 Igarashi 1990	64	adenocarcinoma		abscop RT 20 Gy + HYAN + RT 30Gy		right hemiparesis	1	left frontoparietal		para-aortic nodes	craniotomy-resection			0.25 f
3 Sawada 1990	43	adenocarcinoma G1		HYAN, Lymph + RT 30Gy + CxT	0.75	ICH, aphasia	1	left parietal		left obturator node	craniotomy-resection	WBRT 30Gy		84 favourable
4 Kottek 1991	59	clear cell carcinoma G3	IIA	HYAN, Lymph	prevalent	seizure, right hemiparesis	1	right parietal		para-aortic node	craniotomy-biopsy	cranial RT		38 f
5	41	adenocarcinoma G3	IIA	HYAN	prevalent	ICH, ataxia	2	right parietal, cerebellum			resection of frontal, VCS, resection of cerebellar			0.25 f
6	46	adenocarcinoma G3	IA	HYAN + CT	prevalent	seizures	1	left frontoparietal			craniotomy-resection	cranial RT		9 favourable
7 Ishai 1993	51	mixed müllerian tumor		HYAN	8	aphasia, right hemiparesis	1	left frontal			craniotomy-resection	RT		25 favourable
8 Witonski 1993	70	adenocarcinoma		HYAN + RT + CT	24	ICH, drowsiness	2	right and left cerebellar		lungs	craniotomy-resection of right (largest one)	WBRT 30Gy		3 f
9	60	adenocarcinoma		HYAN + CxT	96	ICH, left hemiparesis, drowsiness	2	left temporal, posterior fossa		lungs	VPS, resection of left temporal	pre-op RT 20Gy		1.75 f
10 Ruelle 1994	64	adenocarcinoma G2		HYAN + RT 40Gy + CT	14	ICH, right dysmetria	1	right cerebellar		lungs, bone	craniotomy-resection	RT 55Gy		9 f
11	63	adenocarcinoma G2		HYAN + RT 20Gy	prevalent	left hemiparesis	1	right temporal			craniotomy-resection	RT 45Gy		favourable
12 Cosmo 1996	59	adenocarcinoma G3	IV	HYAN + RT + CT	11	multiple supra-ventricular	M	multiple supra-ventricular		lungs, pelvis	craniotomy-resection			3 f
13	57	adenocarcinoma G3	IB	HYAN + RT	13	right frontal	1	right frontal			craniotomy-resection	WBRT		83 f
14	68	adenocarcinoma G2	IB	HYAN + RT	35	ICH	M	multiple cerebellar			craniotomy-resection	WBRT		3 f
15	49	adenocarcinoma G3	IIA	HYAN + RT	81	left temporal	1	left temporal		lungs, bone	craniotomy-resection	WBRT		2 f
16	57	adenocarcinoma G1	IB	HYAN	36	left frontal	1	left frontal			craniotomy-resection	WBRT		28 f
17	57	adenocarcinoma G2	IC	HYAN + RT	17	left parietal	1	left parietal			craniotomy-resection	WBRT		3 f
18	65	adenocarcinoma G3	IIA	HYAN + RT	8	right occipital	1	right occipital			craniotomy-resection			1 f
19	47	clear cell carcinoma G3	IV	CT	3		M	multiple supra-infratentorial		lungs				1 f
20	51	adenocarcinoma G1	IBC	HYAN + RT + CT	46	multiple supra-infratentorial	M	multiple supra-infratentorial		lungs, liver				1 f
21	63	adenocarcinoma G3	IC	HYAN + RT	58	left occipital	1	left occipital			craniotomy-resection			1 f
22 Martínez 1998	76	adenocarcinoma G3	IB	HYAN + CxT + RT 44Gy	18	left hemiparesis, left HH	1	right supra-ventricular			craniotomy-resection			8 f (refused further treatment)
23 Ogawa 1999	64	adenocarcinoma G2	IB	HYAN, Lymph + RT 30Gy	36	left hemiparesis	M	right parieto-temporal, 3 others supra-ventricular		lungs, para-aortic node		WBRT 30Gy		5 f
24	43	adenocarcinoma G3	IB	HYAN, Lymph + RT 30Gy	19	right hemiparesis, aphasia	M	multiple supra-infratentorial		thoracic and supraclavicular nodes, adrenal gland		WBRT 30Gy		3 f
25 Mahmood 2001	65	adenocarcinoma	IIA	HYAN + RT	21	seizure	2	right parietal, left frontal		bone		WBRT 30Gy		2.25 f
26	44	adenocarcinoma	IB	HYAN + RT + CT	4	ICH, hemiparesis, hemianesthesia	M	multiple supra-infratentorial		bone, lung, liver		WBRT 20Gy		0.25 f
27	66	adenocarcinoma	IIA	HYAN + RT	2	ICH	1	right frontal			craniotomy-resection	WBRT 30Gy		15 f
28	45	adenocarcinoma	IVB	RT + CT	prevalent	ataxia	M	multiple supra-infratentorial			craniotomy-resection	WBRT 30Gy		6 f
29	53	adenocarcinoma	IIIC	HYAN + RT + CT	12	ICH, hemiparesis	1	left occipital			craniotomy-resection	SRT 13Gy + WBRT 37Gy		11 f
30	41	adenocarcinoma	IIIC	HYAN + RT + CT	70	aphasia	2	2 right frontal		peritoneum		WBRT 30Gy		2.25 f
31	44	adenocarcinoma	IVB	RT + CT	0.25	ICH	2	2 left temporal			craniotomy-resection	SRT 22Gy + WBRT 21Gy		1.5 f
32	61	adenocarcinoma	IVB	RT + CT	prevalent	seizure	M	right frontal, right temporal		bone		WBRT 30Gy		1 f
33	47	adenocarcinoma	IVB	HYAN + RT + CT	15.5	seizure, hemianesthesia	M	3 supra-ventricular		peritoneum, lymph nodes		WBRT 30Gy		4 f
34	65	adenocarcinoma	IVB	RT + CT	3	hemiparesis, drowsiness	1	cerebellar			craniotomy-resection	WBRT 30Gy		15 f
35 Pêru 2001	59	adenocarcinoma G1	IIA	HYAN + CT	prevalent	aphasia, right hemiparesis	1	left parietal		peritoneum, pelvic nodes	γSRT then craniotomy-resection	γSRT		120 favourable
36	60	serous carcinoma G3	IIA	HYAN, Lymph + CT	prevalent	headaches, cerebellar syndrome	1	right cerebellar			craniotomy-resection	γSRT		48 favourable
37 Shishani 2003	48	adenocarcinoma G1	IB	HYAN, Lymph + CT	prevalent	ICH, left hemiparesis	1	right parietal			craniotomy-resection	γSRT x 2		48 favourable
38 Elliott 2004	51	adenocarcinoma G1	IB	HYAN, Lymph + RT 30Gy + CT	prevalent	seizure, aphasia, right hemiparesis	1	left temporal			craniotomy-resection	WBRT 32Gy		30 favourable
39 Gien 2004	60	adenocarcinoma G3	IVB	RT	prevalent	aphasia	1	cerebellar		bone		WBRT 20Gy		1 f
40	79	mixed müllerian tumor G2	IB	HYAN	2	hemiparesis, aphasia	M	multiple supra-ventricular				WBRT 20Gy		2 f
41	69	serous carcinoma	IB	HYAN + RT	40	left temporal, cerebellar	2	left temporal, cerebellar		lung		WBRT 20Gy		5 f
42	80	serous carcinoma	IB	HYAN + CT	24	multiple supra-ventricular	M	multiple supra-ventricular		vault		WBRT 30Gy		0.25 f
43	63	clear cell carcinoma G2	IIIC	HYAN, Lymph + RT	8	headaches, hemiparesis, hemianopsia	1	left temporal		lung, liver, peritoneum		WBRT 20Gy		0.5 f
44	48	adenocarcinoma G3	IIIC	HYAN, Lymph + RT	4	ICH	1	cerebellar		supraclavicular node		WBRT 30Gy	CT	5 f
45	48	adenocarcinoma G3	IIIC	HYAN, Lymph + RT + CT	7	ICH, ataxia	2	right parietal, cerebellar				WBRT 30Gy		7 f
46	78	adenocarcinoma G2	IVB	RT	9	hemiparesis	1	right parietal		lung, skin		WBRT 30Gy		7 favourable
47 Salvati 2004	62	adenocarcinoma	IIA	HYAN + RT 30Gy	48	right hemiparesis	1	left parietal			craniotomy-resection	WBRT 30Gy		9 favourable
48	48	adenocarcinoma G3	IB	HYAN + RT + CT	54	seizure	1	left parietal			craniotomy-resection	WBRT	CT	11 f
49	51	clear cell carcinoma G3	IB	HYAN + RT + CT	prevalent	left hemiparesis	1	right frontal		pelvis		WBRT	CT	34 f
50 Lee 2004	54	adenocarcinoma G3	IB	HYAN, Lymph + RT 30Gy	108	seizure	2	left frontal, frontoventricular	yes			WBRT	CT	6.5 f
51 Orta 2006	61	adenocarcinoma	IIIC	HYAN + RT 46Gy + CxT + CT	17	aphasia, amnesia	2	frontal, temporal			craniotomy-resection + biopsies	WBRT 30Gy		64 favourable
52	60	adenocarcinoma	IIA	HYAN	6	right hemiparesis, aphasia	1	frontal			craniotomy-resection	WBRT 20Gy		4 f
53	49	adenocarcinoma	IIIB	HYAN + RT 30Gy + CxT	10	headaches	1	parieto-occipital			craniotomy-resection	WBRT 30Gy		16 favourable
54 Koshen 2015	62	adenocarcinoma G3	IA	HYAN, Lymph + RT 46Gy + CxT	24	headaches	2	left fronto-parietal			stereotactic biopsy	WBRT 30Gy	CT	30 favourable
55 Narasimulu 2015	81	serous carcinoma G3	IA	HYAN, Lymph (refused further treatment)	36	altered mental status	2	right temporo-parietal, left parietal		lung, skin		WBRT		4 f
56	62	adenocarcinoma	IA	HYAN, Lymph (LRTU)	24	right hemiparesis	1	left frontal			craniotomy-resection (surgical site bleeding)	WBRT		1 f
57 Uccella 2016	66	adenocarcinoma G3	IIIC	HYAN	18	headaches	1	left thalamus		bone, lung		γSRT		6 f
58	77	adenocarcinoma G2	IA	HYAN	57	headaches, aphasia	1	right cerebellar			craniotomy-resection	RT		50 f
59	55	adenocarcinoma G3	IIIC	HYAN	5	headaches	1	right thalamus			craniotomy-resection	RT		7 f
60	54	adenocarcinoma G3	IB	HYAN	1	right hemiparesis, aphasia	1	left frontal			craniotomy-resection	RT		12 f
61	65	adenocarcinoma G3	IA	HYAN	6	right hemiparesis	1	right frontal			craniotomy-resection	RT		64 favourable
62	63	adenocarcinoma G3	IVB	concomitant	1	right hemiparesis	2	left parietal, cerebellar			craniotomy-resection	RT		5 f
63	74	adenocarcinoma G1	IB	HYAN	40	headaches, diplopia, ataxia	1	right occipital		lymph nodes		RT		8 f
64	62	adenocarcinoma G3	IIA	HYAN	3	left hemiparesis	1	right parietal			craniotomy-resection	RT		118 favourable
65	65	adenocarcinoma G3	IVB	HYAN	19	seizure, right hemiparesis	M	multiple supra-ventricular		peritoneum		RT		1 f
66	60	undifferentiated G3	IVB	HYAN	5	confusion	1	insula				RT		0 f
67	79	undifferentiated G3	IIA	HYAN	5	confusion	1	hypophysis		lung, liver, para-aortic nodes		RT		1 f
68	42	adenocarcinoma G3	IVB	concomitant	1	headaches	1	left cerebellar			craniotomy-resection	RT		100 favourable
69	78	adenocarcinoma G2	IIIC	HYAN	4	right hemiparesis, aphasia	2	left parietal and occipital		pelvic nodes		RT		1 f
70	74	adenocarcinoma G3	IVB	HYAN	4	right hemiparesis, aphasia	M	multiple supra-infratentorial		lung		RT		5 f
71	80	adenocarcinoma G3	IIA	HYAN	13	upper limbs paresis	M	multiple supra-infratentorial		lung, liver		RT		2 f
72	62	adenocarcinoma G1	IIA	HYAN	5	headaches	2	bilateral occipital				RT		0.5 f
73	52	adenocarcinoma G3	IVB	HYAN	7	seizure, left hemiparesis	M	multiple supra-ventricular		bone, peritoneum, neck		RT	CT	28 f
74	59	adenocarcinoma G3	IB	HYAN	1.5	left hemiparesis	M	multiple supra-infratentorial		lung		RT		28 f
75 Yang 2010	64	adenocarcinoma G2	IA	HYAN	156	left hemiparesis	1	right parietal			craniotomy-resection			12 favourable
76 Monroy 2019	61	adenocarcinoma G3	IB	HYAN, LND + RT + CT	20	headaches, altered mental status	1	right cerebellar		lung, pelvis		RT		3 f
77	66	serous carcinoma G3	II	HYAN, LND + RT + CT	32	seizure, headaches, aphasia, vision	1	right occipital		lung		RT	CT	3 f
78	50	adenocarcinoma G2	IA	HYAN, LND	34	seizure	2	left parietal, right occipital		pelvis, peritoneum		RT		3 f
79	54	adenocarcinoma G3	IVB	RT + CT	7	hemiparesis	1	right parietal		lung, pelvis, peritoneum, bone		RT		7 f
80	71	adenocarcinoma G3	IVB	HYAN + RT + CT	20	confusio, SIADH	1	right frontal		lung, bone		RT	CT	10 f
81	49	adenocarcinoma G3	IIIC	HYAN, LND + RT + CT	57	hemiparesis	M	multiple supra-ventricular		lung, pelvis		RT		2 f
82	45	adenocarcinoma G3	IVB	HYAN + RT + CT	9	SIADH	M	multiple supra-infratentorial		lung, bone		RT		5 f
83	54	serous carcinoma G3	IVB	HYAN, LND + RT + CT	12	headaches, hemiparesis, hemianesthesia	M	multiple supra-ventricular		lung, pelvis, peritoneum		RT	CT	12 favourable
84	82	adenocarcinoma G3	IIIC	HYAN, LND + RT + CT	12	headaches, ataxia, vision	1	left orbital		lung, peritoneum		RT		7 f
85	51	adenocarcinoma G2	IIA	HYAN, LND + RT	199	aphasia	1	left temporal		lung, pelvis, peritoneum		RT		1 f
86	51	adenocarcinoma G2	IA	HYAN + RT	37	headaches, confusion, ataxia	M	right parietal, occipital, c. callosum		lung, peritoneum		RT	CT	9 f
87	33	adenocarcinoma G1	IB	HYAN + CT	110	dizziness, aphasia	1	left temporal		lung		RT		5 f

CAP (cisplatin-adriamycin-cyclophosphamide chemotherapy), CT (chemotherapy), G (grading: G1 well-differentiated, G2 moderately differentiated, G3 poorly differentiated), γSRT (gamma-knife stereotactic radiotherapy), HH (homonymous hemianopsia), HYAN-Lymph (Hy-stereotomy, adnexectomy, pelvic lymphadenectomy), LRTU (lost to follow-up), M (multiple), neoad (neoadjuvant), PE (pulmonary embolism), RT (radiotherapy), SRT (stereotactic radiotherapy), VCS (ventriculocelectomy), VPS (ventriculoperitoneal shunt), WBRT (whole brain radiotherapy)

**Table 3.** Systematic literature review (Medline) focused on brain metastases from endometrial cancer: patients' complete data

## REFERENCES

- [1] P. Morice, A. Leary, C. Creutzberg, N. Abu-Rustum, E. Darai, Endometrial cancer, *The Lancet*. 387 (2016) 1094–1108. [https://doi.org/10.1016/S0140-6736\(15\)00130-0](https://doi.org/10.1016/S0140-6736(15)00130-0).
- [2] R.L. Siegel, K.D. Miller, A. Jemal, Cancer statistics, 2015: Cancer Statistics, 2015, CA: A Cancer Journal for Clinicians. 65 (2015) 5–29. <https://doi.org/10.3322/caac.21254>.
- [3] N. Colombo, E. Preti, F. Landoni, S. Carinelli, A. Colombo, C. Marini, C. Sessa, Endometrial cancer: ESMO Clinical Practice Guidelines for diagnosis, treatment and follow-up, *Annals of Oncology*. 24 (2013) vi33–vi38. <https://doi.org/10.1093/annonc/mdt353>.
- [4] J. Ferlay, I. Soerjomataram, R. Dikshit, S. Eser, C. Mathers, M. Rebelo, D.M. Parkin, D. Forman, F. Bray, Cancer incidence and mortality worldwide: Sources, methods and major patterns in GLOBOCAN 2012: Globocan 2012, *International Journal of Cancer*. 136 (2015) E359–E386. <https://doi.org/10.1002/ijc.29210>.
- [5] S. Pecorelli, Revised FIGO staging for carcinoma of the vulva, cervix, and endometrium, *International Journal of Gynecology & Obstetrics*. 105 (2009) 103–104. <https://doi.org/10.1016/j.ijgo.2009.02.012>.
- [6] G. Cormio, A. Lissoni, G. Losa, G. Zanetta, A. Pellegrino, C. Mangioni, Brain Metastases from Endometrial Carcinoma, *Gynecologic Oncology*. 61 (1996) 40–43. <https://doi.org/10.1006/gyno.1996.0093>.
- [7] L. Gien, J. Kwon, D. Dsouza, J. Radwan, J. Hammond, A. Sugimoto, M. Carey, Brain metastases from endometrial carcinoma: a retrospective study, *Gynecologic Oncology*. 93 (2004) 524–528. <https://doi.org/10.1016/j.ygyno.2004.02.006>.
- [8] S. Uccella, J.M. Morris, F. Multinu, W.A. Cliby, K.C. Podratz, B.S. Gostout, S.C. Dowdy, F. Ghezzi, P.B. Makdisi, G.L. Keeney, M.J. Link, A. Mariani, Primary brain metastases of endometrial cancer: A report of 18 cases and review of the literature, *Gynecologic Oncology*. 142 (2016) 70–75. <https://doi.org/10.1016/j.ygyno.2016.04.013>.
- [9] J.G. Aalders, V. Abeler, P. Kolstad, Recurrent adenocarcinoma of the endometrium: A clinical and histopathological study of 379 patients, *Gynecologic Oncology*. 17 (1984) 85–103. [https://doi.org/10.1016/0090-8258\(84\)90063-5](https://doi.org/10.1016/0090-8258(84)90063-5).
- [10] A.S. Achrol, R.C. Rennert, C. Anders, R. Soffietti, M.S. Ahluwalia, L. Nayak, S. Peters, N.D. Arvold, G.R. Harsh, P.S. Steeg, S.D. Chang, Brain metastases, *Nature Reviews Disease Primers*. 5 (2019). <https://doi.org/10.1038/s41572-018-0055-y>.
- [11] E. Petru, S. Lax, S. Kurschel, F. Gücer, B. Sutter, Long-term survival in a patient with brain metastases preceding the diagnosis of endometrial cancer: Report of two cases and review of the literature, *Journal of Neurosurgery*. 94 (2001) 846–848. <https://doi.org/10.3171/jns.2001.94.5.0846>.

- [12] D. Moher, A. Liberati, J. Tetzlaff, D.G. Altman, The PRISMA Group, Preferred Reporting Items for Systematic Reviews and Meta-Analyses: The PRISMA Statement, *PLoS Medicine*. 6 (2009) e1000097. <https://doi.org/10.1371/journal.pmed.1000097>.
- [13] K.K. Nakano, W.C. Schoene, Endometrial carcinoma with a predominant clear-cell pattern with metastases to the adrenal, posterior mediastinum, and brain, *American Journal of Obstetrics and Gynecology*. 122 (1975) 529–530. [https://doi.org/10.1016/S0002-9378\(16\)33550-5](https://doi.org/10.1016/S0002-9378(16)33550-5).
- [14] Ch. Brezinka, F. Fend, O. Huter, A. Plattner, Cerebral metastasis of endometrial carcinoma, *Gynecologic Oncology*. 38 (1990) 278–281. [https://doi.org/10.1016/0090-8258\(90\)90055-P](https://doi.org/10.1016/0090-8258(90)90055-P).
- [15] M. Sawada, M. Inagaki, M. Ozaki, M. Yamasaki, H. Nakagawa, T. Inoue, N. Terada, A. Wada, Long-term survival after brain metastasis from endometrial cancer, *Jpn. J. Clin. Oncol.* 20 (1990) 312–315.
- [16] K. Kottke-Marchant, M.L. Estes, C. Nunez, Early brain metastases in endometrial carcinoma, *Gynecologic Oncology*. 41 (1991) 67–73. [https://doi.org/10.1016/0090-8258\(91\)90257-6](https://doi.org/10.1016/0090-8258(91)90257-6).
- [17] J.B. Iqbal, J.W. Ironside, Cerebral metastasis from a malignant mixed Müllerian tumour of the uterus, *Histopathology*. 23 (1993) 277–279. <https://doi.org/10.1111/j.1365-2559.1993.tb01202.x>.
- [18] M. Wroński, M. Zakowski, E. Arbit, W.J. Hoskins, J.H. Galicich, Endometrial cancer metastasis to brain: Report of two cases and a review of the literature, *Surgical Neurology*. 39 (1993) 355–359. [https://doi.org/10.1016/0090-3019\(93\)90199-B](https://doi.org/10.1016/0090-3019(93)90199-B).
- [19] A. Ruelle, M. Zuccarello, G. Andrioli, Brain metastasis from endometrial carcinoma. Report of two cases, *Neurosurgical Review*. 17 (1994) 83–87. <https://doi.org/10.1007/BF00309993>.
- [20] R.M. Martín ez-Mañas, M. Brell, J. Rumià, E. Ferrer, Brain Metastases in Endometrial Carcinoma, *Gynecologic Oncology*. 70 (1998) 282–284. <https://doi.org/10.1006/gyno.1998.5021>.
- [21] K. Ogawa, T. Toita, Y. Kakinohana, M. Kamata, H. Moromizato, Y. Nagai, M. Higashi, K. Kanazawa, Y. Yoshii, Palliative Radiation Therapy for Brain Metastases from Endometrial Carcinoma: Report of Two Cases, *Japanese Journal of Clinical Oncology*. 29 (1999) 498–503. <https://doi.org/10.1093/jjco/29.10.498>.
- [22] A.S. Mahmoud-Ahmed, J.H. Suh, G.H. Barnett, K.D. Webster, J.L. Belinson, A.W. Kennedy, The Effect of Radiation Therapy on Brain Metastases from Endometrial Carcinoma: A Retrospective Study, *Gynecologic Oncology*. 83 (2001) 305–309. <https://doi.org/10.1006/gyno.2001.6384>.

[23] s. shiohara, m. ohara, k. itoh, t. shiozawa, i. konishi, Successful treatment with stereotactic radiosurgery for brain metastases of endometrial carcinoma: A case report and review of the literature, *International Journal of Gynecological Cancer*. 13 (2003) 71–76.

<https://doi.org/10.1046/j.1525-1438.2003.13017.x>.

[24] K.S. Elliott, M.E. Borowsky, Y.-C. Lee, C. Rao, O. Abulafia, Prolonged survival in recurrent endometrial carcinoma to the brain, *Gynecologic Oncology*. 95 (2004) 247–251.

<https://doi.org/10.1016/j.ygyno.2004.07.030>.

[25] M. Salvati, E. Caroli, E. Ramundo Orlando, A. Nardone, A. Frati, G. Innocenzi, F. Giangaspero, Solitary Brain Metastases from Uterus Carcinoma: Report of Three Cases, *Journal of Neuro-Oncology*. 66 (2004) 175–178.  
<https://doi.org/10.1023/B:NEON.0000013470.29733.62>.

[26] W.-J. Lee, C.-H. Chen, S.-N. Chow, Brain metastases from early stage endometrial carcinoma 8 years after primary treatment: case report and review of the literature, *Acta Obstetrica et Gynecologica Scandinavica*. 85 (2006) 890–891.  
<https://doi.org/10.1080/00016340600616983>.

[27] S. Orrù, G. Lay, M. Dessì, R. Murtas, M.A. Deidda, M. Amichetti, Brain Metastases from Endometrial Carcinoma: Report of Three Cases and Review of the Literature, *Tumori Journal*. 93 (2007) 112–117. <https://doi.org/10.1177/030089160709300122>.

[28] F. Kouhen, M. Afif, M.E. kabous, F. Raiss, N. Benhmidou, S. Majjaoui, H. Elkacemi, T. Kebdani, N. Benjaafar, Métastase cérébrale d'un cancer de l'endomètre: à propos d'un cas et une revue de la littérature, *Pan African Medical Journal*. 20 (2015).  
<https://doi.org/10.11604/pamj.2015.20.68.6097>.

[29] D.M. Narasimhulu, N. Khulpateea, K. Meritz, Y. Xu, Brain metastasis in two patients with stage IA papillary serous carcinoma of the uterus, *Gynecologic Oncology Reports*. 13 (2015) 1–4. <https://doi.org/10.1016/j.gore.2015.04.002>.

[30] F. Yang, Y. Shao, H. Duan, H. Xu, J. Chen, Brain metastasis from early stage endometrial carcinoma 13 years after primary treatment: a case report and review of the literature, *Int J Clin Exp Pathol*. 12 (2019) 1806–1810.

[31] M.R. Moroney, L.J. Wheeler, B.R. Corr, Clinical presentation of brain metastases from endometrial carcinoma: A case series, *Gynecologic Oncology Reports*. 28 (2019) 79–83.

<https://doi.org/10.1016/j.gore.2019.03.004>.

[32] H.P. Bhambhani, O. Zhou, C. Cattle, R. Taiwo, E. Diver, M.H. Gephart, Brain Metastases from Endometrial Cancer: Clinical Characteristics, Outcomes, and Review of the Literature, *World Neurosurgery*. (2020) S1878875020324621.  
<https://doi.org/10.1016/j.wneu.2020.11.087>.

[33] P.W. Sperduto, N. Kased, D. Roberge, Z. Xu, R. Shanley, X. Luo, P.K. Sneed, S.T. Chao, R.J. Weil, J. Suh, A. Bhatt, A.W. Jensen, P.D. Brown, H.A. Shih, J. Kirkpatrick, L.E. Gaspar, J.B. Fiveash, V. Chiang, J.P.S. Knisely, C.M. Sperduto, N. Lin, M. Mehta, Summary Report on the Graded Prognostic Assessment: An Accurate and Facile

Diagnosis-Specific Tool to Estimate Survival for Patients With Brain Metastases, *Journal of Clinical Oncology*. 30 (2012) 419–425. <https://doi.org/10.1200/JCO.2011.38.0527>.

[34] D.A. Karnofsky, W.H. Abelmann, L.F. Craver, J.H. Burchenal, The use of the nitrogen mustards in the palliative treatment of carcinoma. With particular reference to bronchogenic carcinoma, *Cancer*. 1 (1948) 634–656. [https://doi.org/10.1002/1097-0142\(194811\)1:4<634::AIDCNCR2820010410>3.0.CO;2-L](https://doi.org/10.1002/1097-0142(194811)1:4<634::AIDCNCR2820010410>3.0.CO;2-L).

[35] G.A. Viani, L.G. Bernardes da Silva, E.J. Stefano, Prognostic Indexes for Brain Metastases: Which Is the Most Powerful?, *International Journal of Radiation Oncology\*Biology\*Physics*. 83 (2012) e325–e330. <https://doi.org/10.1016/j.ijrobp.2011.12.082>.

[36] L. Gaspar, C. Scott, M. Rotman, S. Asbell, T. Phillips, T. Wasserman, W.G. McKenna, R. Byhardt, Recursive partitioning analysis (RPA) of prognostic factors in three radiation therapy oncology group (RTOG) brain metastases trials, *International Journal of Radiation Oncology\*Biology\*Physics*. 37 (1997) 745–751. [https://doi.org/10.1016/S0360-3016\(96\)00619-0](https://doi.org/10.1016/S0360-3016(96)00619-0).

[37] T. Okuda, M. Fujita, H. Yoshioka, T. Tasaki, A. Kato, Novel surgical technique to solidify cysttype metastatic brain tumors using autologous fibrin glue for complete resection, *Surgical Neurology International*. 5 (2014) 100. <https://doi.org/10.4103/2152-7806.135304>.

[38] R.A. Patchell, P.A. Tibbs, W.F. Regine, R.J. Dempsey, M. Mohiuddin, R.J. Kryscio, W.R. Markesbery, K.A. Foon, B. Young, Postoperative Radiotherapy in the Treatment of Single Metastases to the Brain: A Randomized Trial, *JAMA*. 280 (1998). <https://doi.org/10.1001/jama.280.17.1485>.

[39] R.A. Patchell, P.A. Tibbs, J.W. Walsh, R.J. Dempsey, Y. Maruyama, R.J. Kryscio, W.R.

Markesbery, J.S. Macdonald, B. Young, A Randomized Trial of Surgery in the Treatment of Single Metastases to the Brain, *New England Journal of Medicine*. 322 (1990) 494–500. <https://doi.org/10.1056/NEJM199002223220802>.

[40] D.W. Andrews, C.B. Scott, P.W. Sperduto, A.E. Flanders, L.E. Gaspar, M.C. Schell, M. Werner-Wasik, W. Demas, J. Ryu, J.-P. Bahary, L. Souhami, M. Rotman, M.P. Mehta, W.J. Curran, Whole brain radiation therapy with or without stereotactic radiosurgery boost for patients with one to three brain metastases: phase III results of the RTOG 9508 randomised trial, *The Lancet*. 363 (2004) 1665–1672. [https://doi.org/10.1016/S0140-6736\(04\)16250-8](https://doi.org/10.1016/S0140-6736(04)16250-8).

[41] D. Rades, J.-D. Kueter, T. Meyners, A. Pluemer, T. Veninga, J. Gliemroth, S.E. Schild, Single brain metastasis: Resection followed by whole-brain irradiation and a boost to the metastatic site compared to whole-brain irradiation plus radiosurgery, *Clinical Neurology and Neurosurgery*. 114 (2012) 326–330. <https://doi.org/10.1016/j.clineuro.2011.10.042>.

- [42] H. Kim, T.-Y. Jung, I.-Y. Kim, S. Jung, K.-S. Moon, S.-J. Park, The Usefulness of Stereotactic Radiosurgery for Radioresistant Brain Metastases, *Journal of Korean Neurosurgical Society*. 54 (2013) 107. <https://doi.org/10.3340/jkns.2013.54.2.107>.
- [43] R.H. Brigell, D.N. Cagney, A.M. Martin, L.A. Besse, P.J. Catalano, E.Q. Lee, P.Y. Wen, P.D. Brown, J.G. Phillips, I.M. Pashtan, S.K. Tanguturi, D.A. Haas-Kogan, B.M. Alexander, A.A. Aizer, Local control after brain-directed radiation in patients with cystic versus solid brain metastases, *J Neurooncol*. 142 (2019) 355–363. <https://doi.org/10.1007/s11060-019-03106-1>.
- [44] G. Minniti, V. Esposito, E. Clarke, C. Scaringi, G. Lanzetta, M. Salvati, A. Raco, A. Bozzao, R. Maurizi Enrici, Multidose Stereotactic Radiosurgery (9 Gy × 3) of the Postoperative Resection Cavity for Treatment of Large Brain Metastases, *International Journal of Radiation Oncology\*Biophysics*. 86 (2013) 623–629. <https://doi.org/10.1016/j.ijrobp.2013.03.037>.
- [45] P. Metellus, E. Bialecki, E. Le Rhun, F. Dhermain, Neurosurgical and radiosurgical decision making in brain metastasis patients in the area of targeted therapies?, *Chin Clin Oncol*. 4 (2015) 19. <https://doi.org/10.3978/j.issn.2304-3865.2015.06.02>.
- [46] E. Le Rhun, et al., Métastases cérébrales de l'adulte, ANOCEF. (2018).
- [47] E.L. Chang, J.S. Wefel, K.R. Hess, P.K. Allen, F.F. Lang, D.G. Kornguth, R.B. Arbuckle, J.M. Swint, A.S. Shiu, M.H. Maor, C.A. Meyers, Neurocognition in patients with brain metastases treated with radiosurgery or radiosurgery plus whole-brain irradiation: a randomised controlled trial, *The Lancet Oncology*. 10 (2009) 1037–1044. [https://doi.org/10.1016/S1470-2045\(09\)70263-3](https://doi.org/10.1016/S1470-2045(09)70263-3).



## COMPETING INTERESTS

N BEUCLER did not receive any funding for this work, and has no conflict of interest to disclose

A SELLIER did not receive any funding for this work, and has no conflict of interest to disclose

C BERNARD did not receive any funding for this work, and has no conflict of interest to disclose

C JOUBERT did not receive any funding for this work, and has no conflict of interest to disclose

N DESSE did not receive any funding for this work, and has no conflict of interest to disclose

A DAGAIN did not receive any funding for this work, and has no conflict of interest to disclose

## ETHICAL APPROVAL

Informed written consent, or oral approval by phone call, was obtained from the patients whose case report are included in the manuscript. They have been given the opportunity to review the manuscript and the attached files, or they have been given a precise description of these contents. This work was conducted in accordance with the Declaration of Helsinki 1964 or its further amendments. For retrospective reviews, the formal approval of an academic or hospital ethical board is not required.

## ACKNOWLEDGEMENTS

We thank Dr Jean-Pierre TERRIER for his expertise in the pathology examination of the surgical samples