



HAL
open science

A cross-sectional study of 502 patients found a diffuse hyperechoic kidney medulla pattern in patients with severe gout

Thomas Bardin, Quang D Nguyen, Khoy M Tran, Nghia H Le, Minh D Do, Pascal Richette, Emmanuel Letavernier, Jean-Michel Correas, Mathieu Resche-Rigon

► To cite this version:

Thomas Bardin, Quang D Nguyen, Khoy M Tran, Nghia H Le, Minh D Do, et al.. A cross-sectional study of 502 patients found a diffuse hyperechoic kidney medulla pattern in patients with severe gout. *Kidney International*, 2021, 99 (1), pp.218-226. 10.1016/j.kint.2020.08.024 . hal-03268489

HAL Id: hal-03268489

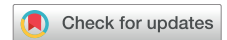<https://hal.sorbonne-universite.fr/hal-03268489>

Submitted on 23 Jun 2021

HAL is a multi-disciplinary open access archive for the deposit and dissemination of scientific research documents, whether they are published or not. The documents may come from teaching and research institutions in France or abroad, or from public or private research centers.

L'archive ouverte pluridisciplinaire **HAL**, est destinée au dépôt et à la diffusion de documents scientifiques de niveau recherche, publiés ou non, émanant des établissements d'enseignement et de recherche français ou étrangers, des laboratoires publics ou privés.

A cross-sectional study of 502 patients found a diffuse hyperechoic kidney medulla pattern in patients with severe gout



see commentary on page 31
OPEN

Thomas Bardin^{1,2,3}, Quang D. Nguyen¹, Khoi M. Tran¹, Nghia H. Le¹, Minh D. Do⁴, Pascal Richette^{2,3}, Emmanuel Letavernier^{5,6}, Jean-Michel Correas^{7,8} and Mathieu Resche-Rigon^{1,9,10}

¹French-Vietnamese Research Center on Gout and Chronic Diseases, Vien Gut Medical Center, Ho Chi Minh City, Vietnam; ²Department of Rheumatology, Hôpital Lariboisière APHP, Paris, France; ³Université de Paris, INSERM U1132, Paris, France; ⁴Center for Molecular Biomedicine, University of Medicine and Pharmacy at Ho Chi Minh City, Vietnam; ⁵Department of Physiology, Hôpital Tenon, APHP, Paris, France; ⁶Sorbonne Université and INSERM, UMR S 1155, Hôpital Tenon, Paris, France; ⁷Department of Radiology, Hôpital Necker, APHP, Paris, France; ⁸Université de Paris, Paris, France; ⁹Department of Biostatistics, Hôpital Saint Louis, APHP, Paris, France; and ¹⁰Université de Paris, UMR U1153 ECSTRA team INERM, Paris, France

We have previously shown that ultrasonography can detect hyperechogenic crystal deposits in the kidney medulla of patients with gout. In this cross-sectional study we investigated the frequency and clinical correlates of hyperechogenic kidney medulla in 502 consecutive primary consultants for gout (ACR/EULAR criteria) at the Vien Gut medical center in Ho Chi Minh City, Vietnam. None of these patients received urate-lowering drugs. Kidney medulla echogenicity on B-mode ultrasonography was compared to that of the kidney cortex. Overall, 36% patients showed a hyperechoic pattern of Malpighi pyramids. On univariate analysis, the pattern was significantly associated with age, estimated gout duration, steroid-dependency, clinical tophi, urate arthropathy, double contour thickness at the scanned joints, coronary heart disease, arterial hypertension, hyperuricemia, proteinuria, leukocyturia, and decreased estimated glomerular filtration rate. On multivariable analysis, the hyperechoic pattern was associated with estimated disease duration, clinical tophi, urate arthropathy, double contour thickness and decreased estimated glomerular filtration rate. No hyperechoic pattern was observed in 515 consecutive consultants without gout. Thus, hyperechoic kidney medulla was frequently demonstrated in Vietnamese patients with tophaceous gout and associated with features of tubulointerstitial nephritis. This finding revives the hypothesis of microcrystalline nephropathy of gout, predominantly seen in untreated gouty patients, which could be an important target for urate-lowering therapy.

Kidney International (2021) **99**, 218–226; <https://doi.org/10.1016/j.kint.2020.08.024>

KEYWORDS: chronic kidney disease; estimated glomerular filtration rate; gout; microcrystalline nephropathy; renal ultrasonography

Correspondence: Thomas Bardin, Service de Rhumatologie, Hôpital Lariboisière, 2 rue Ambroise Paré, 75010 Paris, France. E-mail: thomas.bardin@aphp.fr

Received 18 February 2020; revised 18 August 2020; accepted 27 August 2020; published online 6 September 2020

Copyright © 2020, International Society of Nephrology. Published by Elsevier Inc. This is an open access article under the CC BY-NC-ND license (<http://creativecommons.org/licenses/by-nc-nd/4.0/>).

Gout is closely associated with chronic kidney disease (CKD), impairing prognosis and limiting management options.¹ A meta-analysis of 7 observational studies showed that the prevalence of CKD, defined by eGFR less than 60 ml/min per 1.73 m² among patients with gout, was 24% (95% confidence interval [CI] 19–28).² Chronic renal failure decreases uric acid excretion and favors incident gout,³ but conversely, gout has long been known to impair kidney function. In a Taiwanese study involving more than 650,000 participants with a follow-up of 8 years, gout at baseline was independently associated with increased risk of terminal kidney failure, leading to renal replacement therapy or transplantation (hazard ratio 1.57; 95% CI 1.31–1.79; $P < 0.001$).⁴

Various mechanisms may explain renal impairment in patients with gout. Historically, microcrystalline nephropathy after deposition of monosodium urate or uric acid crystals in the kidney was first believed to play a critical role. Crystal deposits in the renal medulla have been reported since the 1800s⁵ and in several autopsy studies in the 1950s to 1970s.^{6–13} Crystal deposits were seen mainly in patients with gout and rarely in patients without gout¹⁰ with CKD, in whom they could play a role in worsening of kidney function.¹⁴ Histologically, deposits appeared to be surrounded by inflammatory changes, including giant cell granulomas, and associated with interstitial fibrosis, which suggests that they had induced tubulointerstitial nephritis.

The concept of microcrystalline nephropathy was later widely challenged and even denied.^{15–17} Renal biopsy specimens, mainly involving the kidney cortex, very rarely show microcrystal deposits and frequently disclose vascular changes—namely, atherosclerosis and glomerulosclerosis. Gouty nephropathy is now most commonly considered vascular nephropathy because of its frequent association with blood hypertension and hyperuricemia, which, in rodents, induces similar vascular lesions of the kidneys.¹⁸

We recently used US and dual-energy computed tomography to detect the presence of crystal deposits in the renal medulla of 2 patients with severe gout. On B-mode US, deposits appeared hyperechoic and we suggested that US could be useful to detect renal stones and also examine the renal medulla in patients with gout.¹⁹

The purpose of this study was to report renal US findings, notably the presence of a hyperechoic pattern of the renal medulla, in a large sample of Vietnamese patients with untreated gout and to evaluate its correlation with patients' clinical, biochemical, and imaging findings. Result of renal US in patients without gout, who were seen at the same institution, were also analyzed in an attempt to assess specificity of our findings. Finally, a small sample of untreated patients with severe gout was secondarily examined in Paris, France, to determine whether the changes observed in Vietnamese patients could also be seen in another population.

RESULTS

The main features of the 502 consecutive primary consultations for patients for gout included in the study are shown in Table 1 and demonstrate the overall severity of gout in Vietnam as seen in our center. Most patients were males (498), their median age was 46 years (interquartile range 16–87), median estimated disease duration 4 years (IQR, 0–27), and median uricemia 423.2 (IQR, 131.4–1009) $\mu\text{mol/l}$. None of the patients were receiving urate-lowering therapy, even though 39 % had a history of allopurinol use for a generally short period. In total, 279 (55.6%) had clinical tophi, 154 (30.7%) had urate arthropathies, and 43 (10.4%) used daily steroids. Overall, patients were not obese (median body mass index, 25 kg/m^2 (IQR 17.01–37.13); 28 (5.6%) had a history of renal lithiasis, US evidence of renal lithiasis or both; 58 (11.5%) were diabetic (all type 2); 112 (22.3%) had hypertension ($>140/90$ mm Hg); and 5 (1%) had a diagnosis of coronary heart disease. Median eGFR was 78 (IQR 14–129) $\text{ml/min per } 1.73 \text{ m}^2$.

In 181 of 502 patients (36%; 95% CI, 32–40%) patients, B-mode renal US revealed a hyperechoic pattern of Malpighi pyramids compared with the adjacent cortex (Figure 1a), associated with twinkling artifacts on color Doppler US (Figure 1b). Normal US scans are shown in Figure 1c for comparison. The hyperechoic pattern of the renal medulla was linked to patient age, estimated gout duration, steroid dependency, presence of clinical tophi, urate arthropathy (all $P < 0.0001$), coronary heart disease ($P = 0.006$), hypertension ($P = 0.0008$), hyperuricemia ($P = 0.002$), proteinuria ($P = 0.0006$), leukocyturia ($P = 0.0008$), and decreased eGFR ($P < 0.0001$) (Table 1). Supplementary Figure S1 shows large overlap in uricemia and eGFR values between patients with and without hyperechoic renal medulla. Double contour thickness (the grades for each scanned joint or the maximum grade of the 4 scanned joints) was associated with hyperechogenicity of the renal medulla ($P < 0.0001$). The impacts of gout duration (data not shown), uricemia (Figure 2a), and eGFR (Figure 2b) on the presence of hyperechoic renal

medulla were log-linear after log transformation. We also studied the relationship of the creatinine after log transformation (Figure 2c) and concluded that the linearity assumption of the log transformation was not rejected ($P = 0.07$). We found no significant association with urinary pH, uric acid-to-creatinine ratio, fractional clearance of urate, previous history or US finding of kidney stones, kidney cysts, or hematuria.

The results of multivariate analysis are summarized in Figure 3. Renal medulla hyperechogenicity was associated with estimated gout duration (odds ratio [OR], 2.13; 95% CI, 1.55–2.96; $P < 0.0001$), clinical tophi (OR, 7.27; 95% CI, 3.68–15.19; $P < 0.0001$), urate arthropathy (OR, 3.46; 95% CI, 1.99–6.09; $P < 0.0001$), double contour thickness (OR, 1.45; 95% CI, 1.06–1.97; $P < 0.02$), and eGFR (OR, 0.30; 95% CI, 0.09–0.89; $P < 0.034$). There was also a numerical association of serum creatinine with medulla hyperechogenicity, which failed to reach statistical significance (OR, 3.64; 95% CI, 0.92–15.71; $P = 0.07$). Sensitivity analysis with the multiple imputation by chained equation model yielded similar results (Supplementary Figure S2).

We also performed renal US in a short series of 10 patients with untreated or very poorly treated gout or recently treated gout (<3 months) seen at the Lariboisière Hospital in Paris. Diffuse hyperechogenicity of the renal medulla by B-mode US, associated with numerous twinkling artifacts on color doppler US, was observed in 4 patients (Table 2).

Finally, we analyzed the renal US scan systematically performed in 515 consecutive patients who visited the Vien Gut Clinic and in whom gout was excluded to explore the specificity of our findings. These patients included 309 females and 206 males, 27 had treated hypertension, and 79 had type 2 diabetes. Their median age was 51 years (IQR, 43–60; minimum/maximum, 14–84); median serum creatinine, 65.9 (IQR, 55.2–81.8; minimum/maximum, 34.2–570.7) mmol/l ; median eGFR, 99 $\text{ml/min per } 1.73 \text{ m}^2$ (IQR, 87–107); minimum/maximum, 7–143); and median serum uric acid, 315 $\mu\text{mol/l}$ (IQR, 266–366; minimum/maximum, 103–429). Uricemia was greater than 360 $\mu\text{mol/l}$ in 145 patients and greater than 420 $\mu\text{mol/l}$ in 10. None of the 515 patients without gout had a hyperechoic pattern of the renal medulla.

DISCUSSION

Our large cross-sectional study revealed the presence of a diffuse hyperechoic renal medulla in 36% of 502 Vietnamese patients with neglected gout. The finding was observed mainly in tophaceous gout, which involved a large proportion of our patients who had received very little treatment with urate-lowering drugs, and was associated with moderately impaired renal function and urinary features compatible with tubulointerstitial nephritis.

Renal pyramids (renal medulla) contain vasa recti, medullary capillary plexus, loops of Henle, and collecting ducts. In the normal kidney, they can be differentiated from the renal cortex by B-mode US and by hypoechoic status

Table 1 | Main features of the patients with gout; whole cohort and patients with and without hyperechogenic renal medulla

	Patients with available data	All included patients ^a (n = 502)	Normal hypoechoic medulla (n = 321)	Hyperechoic medulla (n = 181)	Hyperechoic vs. hypoechoic medulla P value
Men/women	502	498/4	317/4	181/0	0.30
Age, yr	502	46 [38–56] (16–87)	42 [36–52] (16–84)	53 [44–59] (25–87)	<0.0001
Body mass index, kg/m ²	480	25.01 [22.77–27.04] (17.01–37.13)	25.15 [23.05–27.14] (17.01–36.73)	24.69 [22.19–26.72] (19.07–37.13)	0.28
Gout duration, yr	500	4 [1–8] (0–27)	2 [1–5] (0–27)	7 [4–11] (0–26)	<0.0001
Family history of gout	502	61 (12.2)	39 (12.2)	22 (12.2)	1.00
Clinical tophi	502	279 (55.6)	111 (34.6)	168 (92.8)	<0.0001
Urate arthropathy	502	154 (30.7)	36 (11.2)	118 (65.2)	<0.0001
Double contour thickness maximum grades	502				<0.0001
Absent		2 (0.4)	2 (0.6)	0 (0.0)	
Thin		238 (47.4)	190 (59.3)	48 (26.5)	
Moderate		132 (26.3)	86 (26.8)	46 (25.4)	
Thick		130 (25.9)	43 (13.4)	87 (48.1)	
History of colchicine use	447	171 (38.3)	96 (33.8)	75 (46.0)	0.012
History of allopurinol use	427	161 (37.7)	102 (37.6)	59 (37.8)	1.00
Steroid use	415	43 (10.4)	18 (6.6)	25 (17.5)	0.001
Hypertension	502	112 (22.3)	56 (17.5)	56 (30.9)	0.0008
Coronary heart disease	502	5 (1.0)	0 (0.0)	5 (2.8)	0.006
Cardiac arrhythmia	502	7 (1.4)	7 (2.2)	0 (0.0)	0.053
Diabetes	502	58 (11.5)	35 (10.9)	23 (12.7)	0.56
Diuretics	502	1 (0.2)	1 (0.3)	0 (0.0)	1.00
Urolithiasis	502	28 (5.6)	21 (6.5)	7 (3.9)	0.23
Renal cysts	502	47 (9.4)	25 (7.8)	22 (12.2)	0.11
Serum uric acid, µmol/l	502	423.2 [344.2–488.2] (131.4–1009)	410.4 [336.4–473.9] (131.4–1009)	450.8 [358.3–510.1] (211.8–660.9)	0.001
eGFR, ml/min/1.72 m ²	502	78 [66–88] (14–129)	81 [71–90] (25–19)	70 [60–83] (14–129)	<0.0001
Fractional clearance of uric acid	502	0.063 [0.048–0.081] (0.011–0.184)	0.065 [0.05–0.082] (0.012–0.184)	0.061 [0.045–0.079] (0.011–0.15)	0.10
Urinary uric acid-to-creatinine ratio	502	0.2527 [0.1879–0.3258] (0.0447–0.8209)	0.2588 [0.1907–0.3291] (0.0452–0.8209)	0.2477 [0.1795–0.3164] (0.0447–0.7647)	0.27
Urine pH	502	6 [5.50–6.9] (5–8.5)	6 [5.5–7] (5–8.5)	6 [5.5–6.5] (5–8.5)	0.38
Proteinuria ≥+	502	58 (11.5)	28 (8.7)	30 (16.6)	0.013
Hematuria ≥+	502	21 (4.2)	17 (5.3)	4 (2.2)	0.11
Leukocyturia ≥+	502	62 (12.4)	31 (9.7)	31 (17.1)	0.016

eGFR, estimated glomerular filtration rate.

^aData are median [interquartile range], (minimum/maximum), or n (percent).

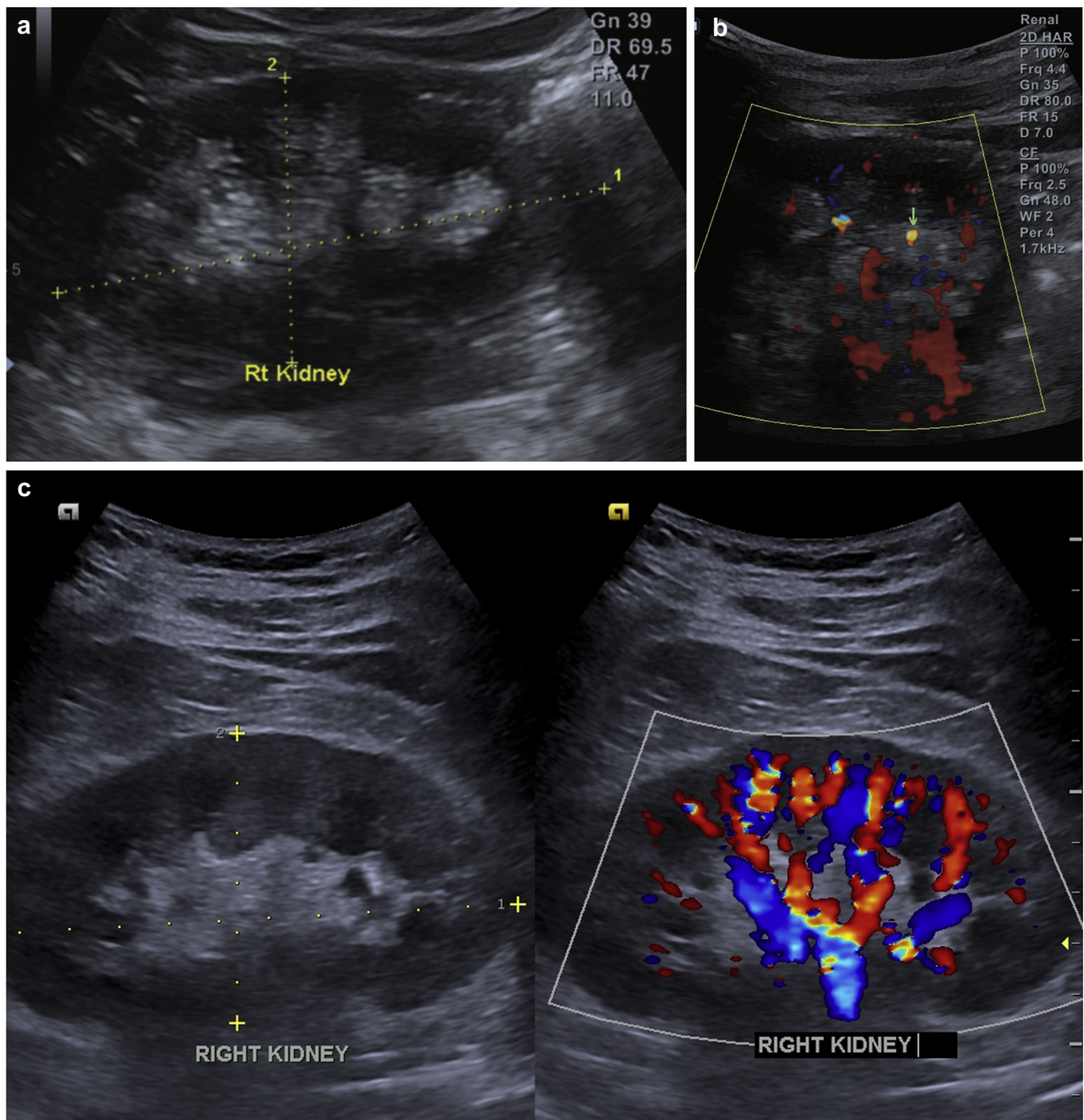


Figure 1 | (a) Diffuse hyperechogenicity of renal medulla on B-mode ultrasonography. (b) Color doppler ultrasonography showing numerous twinkling artifacts (green arrow). (c) Ultrasonographic image of a normal patient. Note that the renal medulla is hypoechoic as compared to the cortex on B-mode scanning, and there is no twinkling artifact on color Doppler. Rt, right.

compared with the renal cortex containing renal glomeruli and proximal and distal tubules, although the cortical echogenicity may be modified by the fluid status of the patient.²⁰ Reversed corticomedullary differentiation (hyperechoic medulla) has been reported as a reversible finding in neonates²¹ and has also been observed in several specific diseases, including medullary nephrocalcinosis as the result of hyperparathyroidism, sarcoidosis, vitamin D intoxication,

medullary sponge kidney, sickle cell anemia, type 1 renal tubular acidosis, Tamm-Horsfall proteinuria, recessive polycystic disease, and hemoglobinuria^{20,22–24} that were not identified in our gouty patients. Hyperechoic medulla appears as a rare finding in unselected adults. In a review of 8000 renal US scans consecutively performed in a Japanese hospital over 2 years, hyperechogenicity of the medullae was observed in only 18 patients, of whom 7 had a diagnosis of gout and 1 of

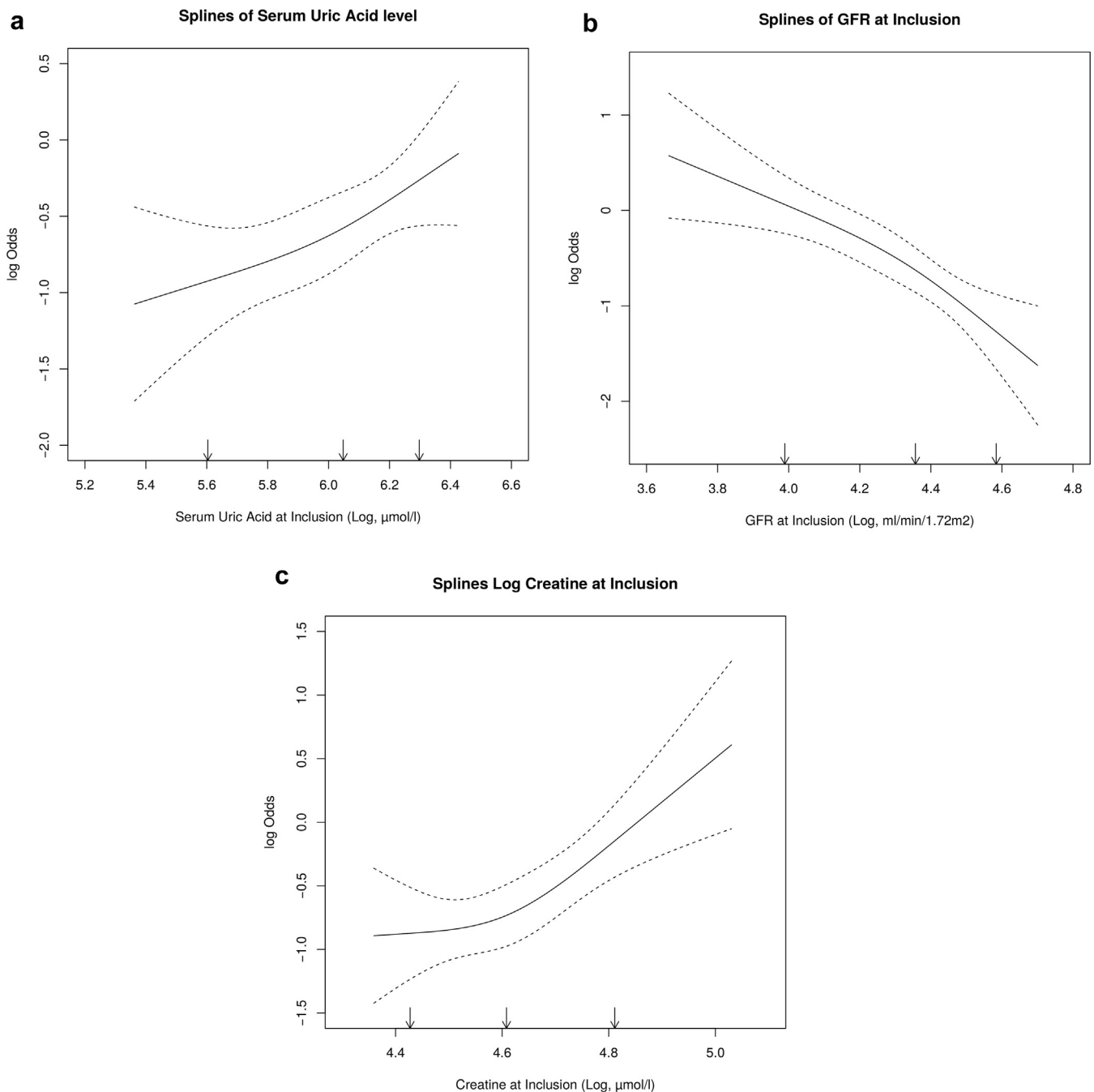


Figure 2 | Relationship using estimated restricted cubic spline function between odds ratios for hyperechogenicity of renal medulla with (a) serum uric acid level log-transformed, (b) estimated glomerular filtration rate by Modification of Diet in Renal Disease log-transformed, and (c) serum creatinine log-transformed. Solid lines correspond to the estimated spline regression and dashed lines to the confidence limits. Arrows correspond to the location of the 3 knots used to estimate the splines. GFR, glomerular filtration rate.

Lesch-Nyhan syndrome.²⁴ In children or young adults with Lesch-Nyhan syndrome, hyperechogenicity of the renal medulla has been well documented and explained by the deposition of various oxypurines in the kidney, including xanthine, which can accumulate during long-standing allopurinol treatment.^{25–28} None of our patients had this syndrome. This hyperechogenic pattern was not found in our controls without gout, reinforcing its relation with gout.

This series of Vietnamese patients with gout at the Vien Gut Medical Center differs from the gouty patients usually seen in the Western world by a younger age of onset, a lower body mass index, a weaker association with the metabolic syndrome, and by an increased severity that can be explained, at least in part, by the lack of urate-lowering drug therapy (Table 1). Our study suggests that untreated long-standing gout is a leading cause of hyperechogenicity of the adult

renal medulla. We found similar features in 4 of 10 French patients whose gout had been long neglected. Although this preliminary study of very selected and rare French gouty patients does not allow estimating the frequency of hyperechoic medulla in France, it shows that hyperechogenicity of the medulla can be seen in a non-Vietnamese population. This observation, together with similar findings in Japan²⁴ and Korea,²⁹ suggests that hyperechoic medulla is a frequent feature of long-standing untreated gout, which is not unique to Vietnamese patients.

The cause of the hyperechogenicity of the kidney medulla frequently observed in our study is uncertain as, for obvious ethical reasons, we did not perform biopsies of the renal medullae. Several lines of evidence support the hypothesis that the hyperechogenicity could relate to the deposition of urate or uric acid crystals, in line with early autopsy observations of these crystals in the medullae of gouty patients at a time when urate-lowering drugs were not available.^{6–13} These early findings have since been questioned when untreated gout became uncommon on the Western world,^{15–17} which may have prevented medullary crystal deposits. Recently we have been able to document by dual-energy computed tomography the presence of uric acid or urate deposits at the site of strongly hyperechoic medullae in 2 patients (1 French and 1 Vietnamese) with tophaceous gout in whom uricemia had remained high for many years.¹⁹ Although the performance of dual-energy computed tomography of the renal medulla has not been ascertained yet, this technique has been shown to have a specificity varying from 0.83 to 0.99 across studies for musculoskeletal deposits of urate in gout^{30,31} and to be able to differentiate uric acid from calcium-containing urinary stones.³² Hyperechoic medulla in our study was observed mainly in gout with large crystal load as suggested by its independent association with long disease duration, clinical tophi, urate arthropathy, and thick double contours

Table 2 | Main features of 10 men with very poorly treated primary gout, explored by kidney ultrasonography at the Paris Necker Hospital

	No hyperechoic medulla	Hyperechoic medulla
	(n = 6)	(n = 4)
Mean age, yr	65.3	65.25
Mean gout duration, yr	15.3	15.75
Number with tophi	2	3
Number with urate arthropathy	2	4
Mean uricemia, $\mu\text{mol/l}$	557.5	525.75
Mean creatinemia (mmol/l)	123.5	125.05
Mean eGFR (ml/min per 1.73 m ²)	59.9	57.6

eGFR, estimated glomerular filtration rate.

One patient in each group had been treated by a urate-lowering drug for less than 3 months.

on joint US scan. The observation of twinkling color artifacts in the hyperechoic areas also reinforces the microcrystalline hypothesis. This artifact, observed on color Doppler US, has been described as a mosaic color pattern behind a strongly reflective irregular structure.³³ Although its source is not clearly understood, it has been reported primarily in association with crystalline urinary stones^{34,35} and can be reproduced in vitro by synthetic crystalline structures.³⁶ Finally, in a few patients we observed the disappearance of renal medulla hyperechogenicity in patients undergoing intensive urate-lowering treatment together with the disappearance of double contours (Figure 4). This suggests that renal microcrystalline deposits could be dissolved by serum urate lowering, as articular deposits are, although a prospective study is needed to investigate the frequency of this finding.

The nature of the crystal species that could be responsible for the hyperechoic medullae of our gouty patients cannot be definitely ascertained from our study. Light microscopic autopsy studies of kidneys from patients with severe gout have

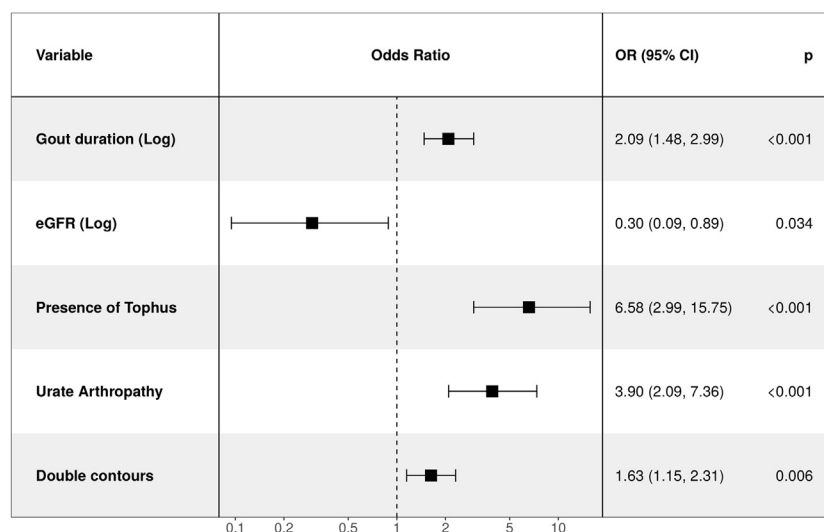


Figure 3 | Forest plot of multivariable logistic model. Hosmer-Lemeshow goodness-of-fit test, $P = 0.96$. Data are displayed using odds ratios and 95% confidence intervals (CIs).

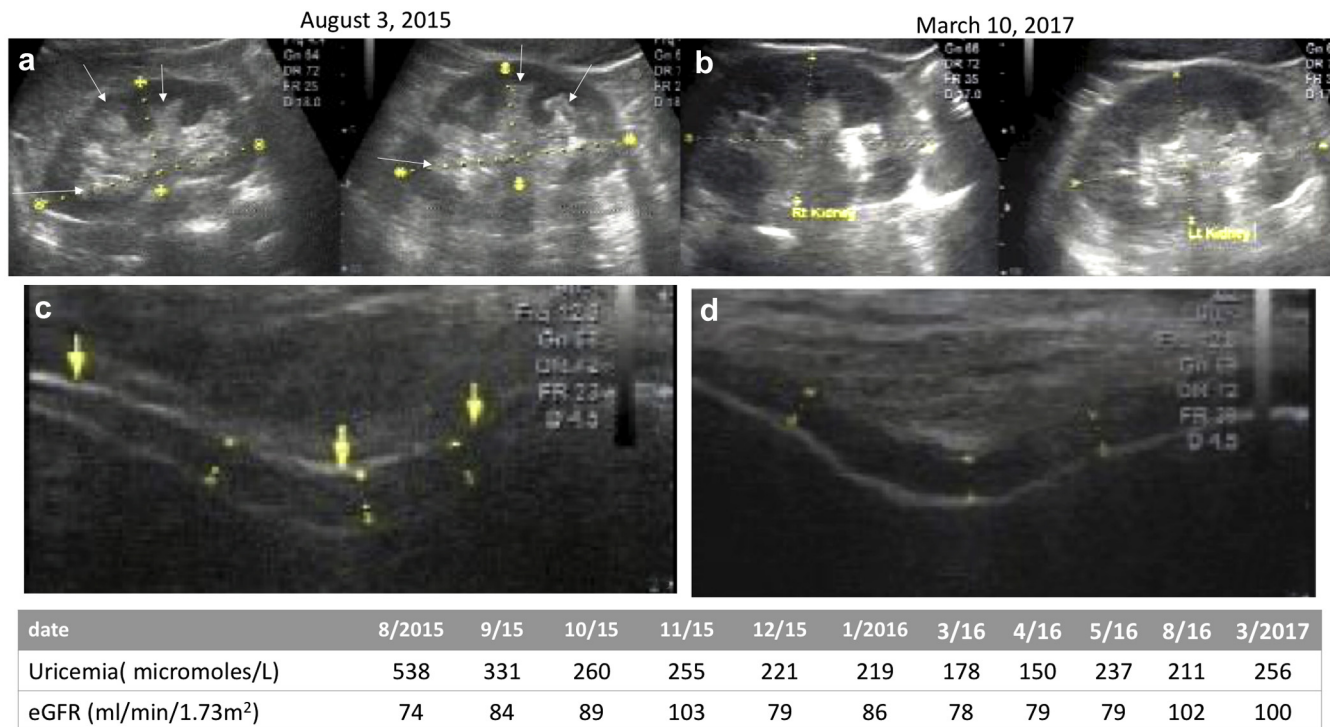


Figure 4 | Follow-up of a Vietnamese patient with gout. Note the improvement of the hyperechogenicity of the renal medullae between August 2015 (a, white arrows) and (b) March 2017, together with disappearance of the double contour at the patellofemoral joint between August 2015 (c, yellow arrows) and March 2017 (d), obtained under persistent uricemia lowering below the 300 μmol/L target (table) by allopurinol therapy. The eGFR seems to parallelly improve (see table below the figure).

identified both interstitial monosodium urate crystals and uric acid crystals obstructing collecting ducts. The lack of association between the medullary images and uric acid lithiasis, low urine pH, high uric acid output, or fractional clearance of urate and their association with long gout duration favors the hypothesis that crystals mostly consisted of interstitial slowly growing monosodium urate crystals and not collecting duct uric acid crystals because the latter are favored by urine acidic pH and high uric acid urine output.

In our study, on univariable analysis hyperechogenic renal medulla was associated with mild proteinuria and leukocyturia. These urine findings are suggestive of the induction of tubulointerstitial nephritis by medullary deposits, a hypothesis consistent with the description in early autopsy studies of medullary fibrosis and giant cell granuloma in the vicinity of crystal deposits.^{6–13} On univariate analysis, the hyperechoic pattern was also associated with hypertension. Therefore, a vascular mechanism, known to be an important factor of kidney function decrease in gout, cannot be excluded from participating in the hyperechoic pattern. However, this appears unlikely because thus far hypertensive kidney has not been included in the above-mentioned list of diseases associated with hyperechoic medulla.^{20,22–24} On univariate and multivariate analyses, deposits were associated with deficient renal function as assessed by low eGFR, although renal insufficiency appeared overall as relatively mild.

Even if our analysis was retrospective, the data were collected prospectively. Other strengths are the inclusion of

a large number of consecutive patients, the paucity of missing data (<10%), and the robustness of our findings shown by sensitivity analysis with multiple imputation. Finally, we emphasize that the patients of the study population were mostly untreated, and thus the prevalence of deposition in the renal medulla could be lower in treated populations.

In conclusion, our findings support the frequent occurrence of hyperechoic medulla in long-standing, untreated gout, a finding that could be a feature of microcrystalline nephropathy. Such nephropathy would not be the only mechanism of kidney damage in hyperuricemia and gout, and other factors, such as vascular involvement and nonsteroidal anti-inflammatory drug toxicity, have been proven to be important. However, the hypothesis that crystal deposits may participate in kidney damage strongly supports early intervention to lower urate levels in gouty patients.

METHODS

Study population and serum and urine biochemistry

This study was approved by the ethics committee of the University of Medicine and Pharmacy at Ho Chi Minh City, Vietnam (approval number 511/DHYD-HDDD). Between September 2016 and March 2017, we prospectively included 502 consecutive Vietnamese patients who presented at the Vien Gut Medical Centre (Ho Chi Minh City, Vietnam) for the first time with a diagnosis of gout according to the American College of Rheumatology/European League Against Rheumatism criteria³⁷ and had not received urate-

lowering drugs, at least during the previous 6 months. The Vien Gut Medical Center is an outpatient clinic devoted to patients with gout in whom a systematic clinical, biochemical, and imaging workup is performed before deciding on the therapeutic strategy. Data on gout features and comorbidities, fasting glycemia, uricemia, serum creatinine level, fractional clearance of uric acid, and laboratory urine stick parameters (pH, proteinuria, leukocyturia, hematuria) are systematically collected and were extracted from electronic files. GFR was estimated by the Modification of Diet in Renal Disease equation.³⁸

Imaging procedure

Radiographs of all joints clinically suspected of urate arthropathy were performed. The US examination included a study of the kidneys, liver, knees, and first metatarsophalangeal joints. US was performed using a linear high-frequency broadband transducer dedicated to musculoskeletal imaging (L3-12), as well as a lower broadband convex transducer for abdominal imaging (C1-6CT) (E-Cube 9 system, Alpinion Medical Systems, Seoul, Korea), in both patients with and without gout in Vietnamese patients. Urate arthropathy was diagnosed by typical destructive changes on radiographs, including gouty erosion. Hyperechogenicity of the renal medulla was diagnosed when echogenicity of Malpighi pyramids was increased on B-mode US compared with the renal cortex. Twinkling artifacts were searched for by using color Doppler US with appropriate settings (mid-pulse repetition frequency). Kidney stones were determined by history taking, kidney US findings, or both. The double contour sign, which indicates crystal deposition at the articular cartilage surface, was graded in 4 grades (none, thin, moderate, and thick) by a single experienced observer (KMT). Double contours were analyzed by keeping these 4 grades in every scanned joint or by looking at the highest grade of all scanned joints of a given patient. Data were anonymized by attributing an identification number to each patient and entered into a computer database.

Statistical analysis

Quantitative data are presented as the median (IQR) and categorical data by number (percent). Groups were compared by Wilcoxon rank sum and Fisher exact tests for quantitative and categorical characteristics, respectively. A multivariable logistic model was used to assess the relation between patient characteristics and the presence of hyperechogenicity of the renal medulla. A backward-forward stepwise selection with a stopping rule based on $P < 0.05$ was used. All variables significant at $P < 0.20$ on univariate analysis were included in the initial multivariable model. ORs and 95% CIs were estimated. For quantitative variables, if non-log-linearity of the effect was suspected, a log transformation was applied. Serum uric acid, duration of gout disease, serum creatinine level, and eGFR were log-transformed. Then the log-linearity assumption was assessed after log transformation by restricted cubic spline functions and tested with the Wald test. The number of knots was fixed to 3. Goodness of fit of the final multivariable model was assessed by the Hosmer-Lemeshow test. The primary analysis was performed with complete cases. Sensitivity analyses were performed with multiple imputation. In total, 20 imputed datasets were generated by multiple imputation chained equation with 20 iterations.³⁹ All variables present in the initial multivariable model were included in the imputation model. Rubin rules were applied to obtain final estimates and tests. All tests were 2-sided,

with values of P less than 0.05 considered statistically significant. Analyses were performed with R version 3.4.1.⁴⁰

Ten patients with untreated gout or very poorly or very recently treated (<3 months) gout were recruited at the Lariboisière Rheumatology Clinic (Paris, France) and underwent renal US at the Necker Hospital using an Aixplorer system (SuperSonic Imagine, Aix-en-Provence, France). Demographic, clinical, biochemical, and radiographic data were extracted from the patients' files.

DISCLOSURE

All the authors declared no competing interests.

ACKNOWLEDGMENTS

Supported by ART-Viggo (TB) and Société Française de Rhumatologie (TB).

SUPPLEMENTARY MATERIAL

Supplementary File (PDF)

Figure S1. (A) Distribution of the of serum uric acid in patients with and without hyperechoic medulla. **(B)** Relationship between serum uric acid and estimated glomerular filtration rate in patients with and without hyperechoic medulla.

Figure S2. Forest plot of multivariable logistic model after multiple imputation by chained equation. Data are displayed using odds ratios and 95% confidence intervals (CIs). eGFR, estimated glomerular filtration rate.

REFERENCES

- Bardin T, Richette P. Impact of comorbidities on gout and hyperuricaemia: an update on prevalence and treatment options. *BMC Med.* 2017;15:123.
- Roughley MJ, Belcher J, Mallen CD, Roddy E. Gout and risk of chronic kidney disease and nephrolithiasis: meta-analysis of observational studies. *Arthritis Res Ther.* 2015;17:90.
- Krishnan E. Chronic kidney disease and the risk of incident gout among middle-aged men: a seven-year prospective observational study. *Arthritis Rheum.* 2013;65:3271–3278.
- Yu KH, Kuo CF, Luo SF, et al. Risk of end-stage renal disease associated with gout: a nationwide population study. *Arthritis Res Ther.* 2012;14:R83.
- Garrod A, B. La goutte, sa nature, son traitement et le rhumatisme goutteux. [Charcot JM, Trans., annotator]. Paris: Adrien Delahaye; 1867.
- Brown J, Mallory GK. Renal changes in gout. *N Engl J Med.* 1950;243:325–329.
- Talbott JH, Terplan KL. The kidney in gout. *Medicine (Baltimore).* 1960;39:405–467.
- Duncan H, Dixon AS. Gout, familial hypericaemia, and renal disease. *Q J Med.* 1960;29:127–135.
- Verger D, Leroux-Robert C, Ganter P, Richet G. [Intra-renal deposits of urate in patients with chronic hyperuricemic renal insufficiency]. *J Urol Nephrol (Paris).* 1967;73:314–318 [in French].
- Bluestone R, Waisman J, Klinenberg JR. The gouty kidney. *Semin Arthritis Rheum.* 1977;7:97–113.
- Emmerson BT, Row PG. Editorial: An evaluation of the pathogenesis of gouty kidney. *Kidney Int.* 1975;8:65–71.
- Linnane JW, Burry AF, Emmerson BT. Urate deposits in the renal medulla. Prevalence and associations. *Nephron.* 1981;29:216–222.
- Barlow KA, Beilin LJ. Renal disease in primary gout. *Q J Med.* 1968;37:79–96.
- Ayoub I, Almaani S, Brodsky S, et al. Revisiting medullary tophi: a link between uric acid and progressive chronic kidney disease? *Clin Nephrol.* 2016;85:109–113.
- Nickeleit V, Mihatsch MJ. Uric acid nephropathy and end-stage renal disease—review of a non-disease. *Nephrol Dial Transplant.* 1997;12(9):1832–1838.
- Reif MC, Constantiner A, Levitt MF. Chronic gouty nephropathy: a vanishing syndrome? *N Engl J Med.* 1981;304:535–536.
- Beck LH. Requiem for gouty nephropathy. *Kidney Int.* 1986;30:280–287.

18. Mazzali M, Kanellis J, Han L, et al. Hyperuricemia induces a primary renal arteriopathy in rats by a blood pressure-independent mechanism. *Am J Physiol Renal Physiol*. 2002;282:F991–F997.
19. Bardin T, Tran KM, Nguyen QD, et al. Renal medulla in severe gout: typical findings on ultrasonography and dual-energy CT study in two patients. *Ann Rheum Dis*. 2019;78:433–434.
20. Shultz PK, Strife JL, Strife CF, McDaniel JD. Hyperechoic renal medullary pyramids in infants and children. *Radiology*. 1991;181:163–167.
21. Jequier S, Kaplan BS. Echogenic renal pyramids in children. *J Clin Ultrasound*. 1991;19:85–92.
22. Nayir A, Kadioglu A, Sirin A, et al. Causes of increased renal medullary echogenicity in Turkish children. *Pediatr Nephrol*. 1995;9:729–733.
23. Quaia E, Correas JM, Mehta M, et al. Gray scale ultrasound, color Doppler ultrasound, and contrast-enhanced ultrasound in renal parenchymal diseases. *Ultrasound Q*. 2018;34:250–267.
24. Toyoda K, Miyamoto Y, Ida M, et al. Hyperechoic medulla of the kidneys. *Radiology*. 1989;173:431–434.
25. Kenney IJ. Renal sonography in long standing Lesch-Nyhan syndrome. *Clin Radiol*. 1991;43:39–41.
26. Rosenfeld DL, Preston MP, Salvaggi-Fadden K. Serial renal sonographic evaluation of patients with Lesch-Nyhan syndrome. *Pediatr Radiol*. 1994;24:509–512.
27. Stevens SK, Parker BR. Renal oxypurine deposition in Lesch-Nyhan syndrome: sonographic evaluation. *Pediatr Radiol*. 1989;19:479–480.
28. Ogawa A, Watanabe K, Minejima N. Renal xanthine stone in Lesch-Nyhan syndrome treated with allopurinol. *Urology*. 1985;26:56–58.
29. Kim MY, Jeon WK, Kim HK, et al. Sonographic findings in gouty nephropathy. *J Korean Radiol Soc*. 1994;31:523–527.
30. Richette P, Doherty M, Pascual E, et al. 2018 Updated European League Against Rheumatism evidence-based recommendations for the diagnosis of gout. *Ann Rheum Dis*. 2020;79:31–38.
31. Gamala M, Jacobs JWG, van Laar JM. The diagnostic performance of dual energy CT for diagnosing gout: a systematic literature review and meta-analysis. *Rheumatology (Oxford)*. 2019;58:2117–2121.
32. Hidas G, Eliahou R, Duvdevani M, et al. Determination of renal stone composition with dual-energy CT: in vivo analysis and comparison with x-ray diffraction. *Radiology*. 2010;257:394–401.
33. Rahmouni A, Bargoin R, Herment A, et al. Color Doppler twinkling artifact in hyperechoic regions. *Radiology*. 1996;199:269–271.
34. Abdel-Gawad M, Kadasne RD, Elsobky E, et al. A prospective comparative study of color Doppler ultrasound with twinkling and non-contrast computerized tomography for the evaluation of acute renal colic. *J Urol*. 2016;196:757–762.
35. Hanafi MQ, Fakhrizadeh A, Jaafaezadeh E. An investigation into the clinical accuracy of twinkling artifacts in patients with urolithiasis smaller than 5 mm in comparison with computed tomography scanning. *J Family Med Prim Care*. 2019;8:401–406.
36. Shang M, Sun X, Liu Q, et al. Quantitative evaluation of the effects of urinary stone composition and size on color Doppler twinkling artifact: a phantom study. *J Ultrasound Med*. 2017;36:733–740.
37. Neogi T, Jansen TLTA, Dalbeth N, et al. 2015 gout classification criteria: an American College of Rheumatology/European League Against Rheumatism collaborative initiative. *Ann Rheum Dis*. 2015;74:1789–1798.
38. Levey AS, Bosch JP, Lewis JB, et al. A more accurate method to estimate glomerular filtration rate from serum creatinine: a new prediction equation. Modification of Diet in Renal Disease Study Group. *Ann Intern Med*. 1999;130:461–470.
39. White IR, Royston P, Wood AM. Multiple imputation using chained equations: issues and guidance for practice. *Stat Med*. 2011;30:377–399.
40. R Core Team (2018). R: A language and environment for statistical computing. Vienna, Austria: R Foundation for Statistical Computing. Available at: <https://www.R-project.org/>.