



HAL
open science

Membranous nephropathy: current understanding of various causes in light of new target antigens

Pierre Ronco, Hanna Debiec

► **To cite this version:**

Pierre Ronco, Hanna Debiec. Membranous nephropathy: current understanding of various causes in light of new target antigens. *Current Opinion in Nephrology and Hypertension*, 2021, 30 (3), pp.287 - 293. 10.1097/mnh.0000000000000697 . hal-03273004

HAL Id: hal-03273004

<https://hal.sorbonne-universite.fr/hal-03273004v1>

Submitted on 28 Jun 2021

HAL is a multi-disciplinary open access archive for the deposit and dissemination of scientific research documents, whether they are published or not. The documents may come from teaching and research institutions in France or abroad, or from public or private research centers.

L'archive ouverte pluridisciplinaire **HAL**, est destinée au dépôt et à la diffusion de documents scientifiques de niveau recherche, publiés ou non, émanant des établissements d'enseignement et de recherche français ou étrangers, des laboratoires publics ou privés.



Membranous nephropathy: current understanding of various causes in light of new target antigens

Pierre Ronco^{a,b} and Hanna Debiec^a

Purpose of review

Membranous nephropathy is an autoimmune disease caused by antibodies mostly directed to podocyte antigens. PLA2R and THSD7A antigens were described in 2009 and 2014 using classical immunochemical techniques. In the last 2 years, thanks to the combination of laser microdissection of glomeruli and mass spectrometry of solubilized digested proteins, several antigens associated with various causes have been described in patients with membranous nephropathy. The purpose of this review is to report on those “new” antigens and to analyse the clinicopathological correlations that make each of this antigen unique.

Recent findings

This article covers the literature of the last 2 years devoted to the description of those new antigens and biomarkers including NELL-1 and Semaphorin 3B in primary membranous nephropathy, and exostosins 1 and 2 and NCAM in lupus class V membranous nephropathy, which will be compared with the previously described antigens. These findings will lead to propose a new classification of membranous nephropathy based on serology and tissue antigen identification that could/should substitute for the classical distinction between primary and secondary membranous nephropathy.

Summary

The discovery of the latest antigens has major implications for the care of patients with membranous nephropathy as they drive the etiologic investigations and provide invaluable markers for treatment monitoring.

Keywords

exostosins 1 and 2, neural cell adhesion molecule 1, neural epidermal growth factor-like 1 protein, semaphorin 3B

INTRODUCTION

Membranous nephropathy is a rare disease affecting the podocytes, which play a key role in controlling the kidney's permeability to proteins. Membranous nephropathy is characterized by the accumulation of immune deposits on the subepithelial (outside) aspect of the glomerular capillary wall, which causes a membrane-like thickening with the formation of spikes. The immune deposits consist of immunoglobulin (Ig) G, of antigens that have long eluded identification, and of the membrane attack complex of complement. There is no infiltration of the glomerulus by inflammatory cells most likely as the immunological conflict takes place outside the glomerular basement membrane. Despite a common histopathological pattern, membranous nephropathy is a heterogeneous disease, occurring either in the absence of an established cause (80% of cases) or in association with clinical conditions, such as infections (hepatitis B), lupus erythematosus, cancer, or

drug intoxication, thus defining the so-called primary and secondary membranous nephropathy, respectively. The discovery of target antigens has introduced an additional layer of heterogeneity as membranous nephropathy can now be defined molecularly by serological studies of antibody or by

^aSorbonne Université, Université Pierre et Marie Curie Paris 06, and Institut National de la Santé et de la Recherche Médicale, Unité Mixte de Recherche S1155, Paris and ^bCentre Hospitalier du Mans, Department of Nephrology, Le Mans, France

Correspondence to Pierre Ronco, MD, PhD. Inserm Unit 1155 Bâtiment Recherche Hôpital Tenon 4 rue de la Chine 75020 Paris, France.
E-mail: pierreronco@yahoo.fr

Curr Opin Nephrol Hypertens 2021, 30:287–293

DOI:10.1097/MNH.0000000000000697

This is an open access article distributed under the terms of the Creative Commons Attribution-Noncommercial-No Derivatives License 4.0 (CCBY-NC-ND), where it is permissible to download and share the work provided it is properly cited. The work cannot be changed in any way or used commercially without permission from the journal.

KEY POINTS

- Recent identification of a bunch of new antigens has been made possible by a technological leap combining laser microdissection of glomeruli and mass spectrometry.
- EXT1/2 is the first biomarker of lupus class V membranous nephropathy; NCAM-1 is the second.
- NELL-1 is the most prevalent antigen after PLA2R in 'primary' membranous nephropathy.
- NELL-1 is the major antigen in cancer-associated membranous nephropathy.
- Semaphorin 3B is the major antigen in childhood membranous nephropathy, with an age of onset often less than 2 years.

biopsy staining of antigen. Here, we will review the latest antigens that have been identified in the last 2 years and discuss how these discoveries question the primary versus secondary classification.

STATE-OF-THE-ART KNOWLEDGE UNTIL 2019

The story of membranous nephropathy antigens was punctuated by two landmark discoveries, that is, identification of the neutral endopeptidase (NEP) antigen and of the phospholipase-A2 receptor (PLA2R) antigen. In 2002, we reported the characterization of the first human podocyte antigen in a rare subset of infants born with membranous nephropathy [1]. The disease developed as the mother was deficient in NEP because of a truncating mutation in the *MME* gene coding for NEP [2], responsible for allo-immunization during pregnancy and transplacental transfer of antibodies to the fetus in the last trimester of pregnancy.

These findings provided the proof of concept that in humans like in the animal model of Heymann nephritis caused by anti-LRP2/megalyn antibodies [3], the podocyte was the target of nephritogenic antibodies. They opened the way to the identification of the major antigen in adult membranous nephropathy, PLA2R [4] followed by that of THSD7A [5], involved in 70–80% and less than 5% of primary membranous nephropathy, respectively. Although these antigens were initially thought to be specific for primary membranous nephropathy, it was further shown that PLA2R-related membranous nephropathy could be associated with replicating hepatitis-B virus infection [6,7] and clinically active sarcoidosis [8]. There are informative case reports where THSD7A is

clearly linked to cancer as it is found in tumor cells and the patient enters remission after efficacious anticancer therapy [9]. These observations were the first suggesting that immunization against PLA2R and THSD7A could occur in the setting of systemic or malignant disease, that is in secondary membranous nephropathy.

2019: ANOTHER TURN IN THE DISCOVERY OF MEMBRANOUS NEPHROPATHY ANTIGENS: LASER MICRODISSECTION OF GLOMERULI AND MASS SPECTROMETRY

Until 2019, antigens were identified by classical immunochemical methods based on western blotting with the patient serum of solubilized glomerular extracts purified on lectin, followed by identification of the reactive antigen by mass spectrometry (MS) of the band excised from the gel. A major technological leap was achieved by Sethi *et al.* at Mayo Clinic based on laser microdissection of glomeruli from PLA2R-negative biopsies followed by MS identification of trypsin-digested proteins. Thus a major difference with the immunochemical methods is that they used paraffin-embedded biopsies, which allows identification of the antigen even in patients with immunologically inactive disease who have cleared the antibody from the circulation.

This approach was extremely fruitful as not less than four new antigens (Fig. 1) were successively identified: exostosins 1 and 2 (EXT1/2), neural epidermal growth factor-like 1 protein (NELL-1), semaphorin 3B (Sema3B), and neural cell adhesion molecule 1 (NCAM1) [10¹¹–13¹¹].

EXOSTOSINS 1 and 2: BIOMARKERS ASSOCIATED WITH AUTOIMMUNE DISEASES

A pilot cohort of 15 PLA2R-negative patients and 7 PLA2R-positive patients was first analyzed by membranous nephropathy, which led to identification of EXT1/2 in five patients all PLA2R-negative, and the presence of EXT1/2 in the immune deposits was confirmed by immunohistochemistry (IHC) [10¹¹]. EXT1/2 form a heterodimeric enzyme called glycosyl transferase, which adds glycosyl residues to the protein back bone of proteoglycans [14]. This explains why the two proteins are found together. IHC was then used to screen a discovery cohort of 304 patients: 21 additional cases all PLA2R-negative were found whereas 95 controls including 40 PLA2R-positive membranous nephropathy, 13 proliferative lupus membranous nephropathy and 42 other glomerulonephritis were all negative. In a replication cohort of 48 patients, 3 out of 16 patients

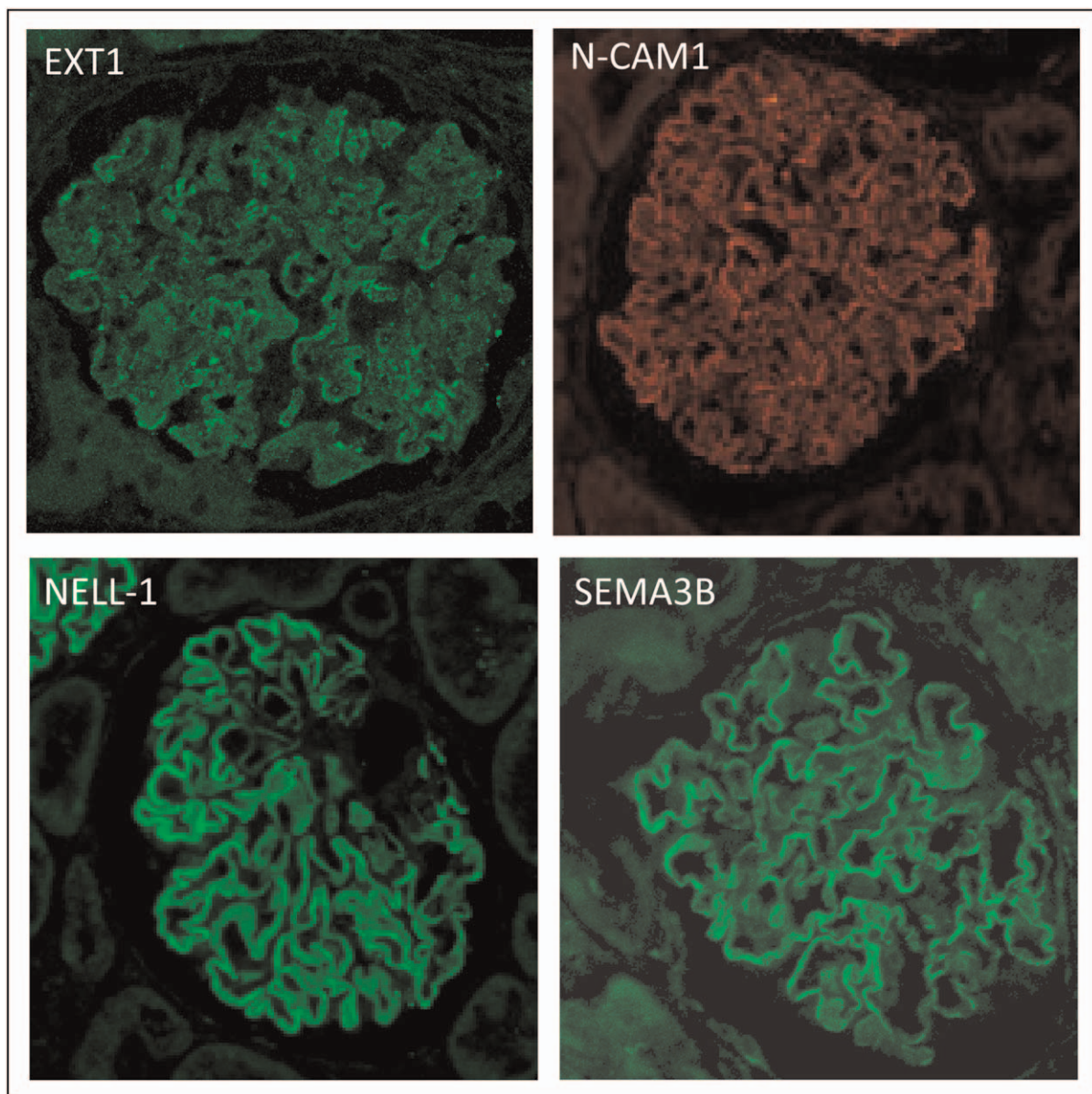


FIGURE 1. Shows the presence of the four biomarker/antigens in immune deposits in membranous nephropathy. Note the granular aspect of the fluorescence on the outer aspect of the glomerular basement membrane. Neural cell adhesion molecule 1 (NCAM1) is adapted from Fig. 3a in Caza *et al.* [13^{***}].

with primary membranous nephropathy were EXT1/2-positive but they all had some sign of auto-immunity on chart review and two patients later developed full-blown clinical lupus; 8 of 18 patients with class V lupus membranous nephropathy but only 1 of 14 patients with a mixed class stained positive for EXT1/2.

The clinical and biopsy findings revealed a distinct pattern from PLA2R-related membranous nephropathy. Eighty-one percent of the patients were women and the average age was 35.7 years. Furthermore, 71% of the patients had abnormal autoimmune findings, such as positive antinuclear,

antidouble-stranded DNA, anti-SSA/SSB, or antiribonucleoprotein antibodies. Nine (35%) patients had a clinical diagnosis of lupus and three (12%) had mixed connective tissue disorder. Biopsy findings revealed features suggestive of a secondary membranous nephropathy related to autoimmune disease in most patients. These included staining for C1q and/or staining for IgA/IgM, subendothelial and mesangial deposits, and tubuloreticular inclusions in endothelial cells on electron microscopy. Furthermore, IgG1 was the dominant IgG with spectral counts significantly greater than for IgG4, the prevailing subclass in PLA2R-associated membranous

nephropathy. Taken together, these findings suggest that EXT1/2 represent potential biomarkers or target antigens in secondary autoimmune membranous nephropathy. However, the term of antigen cannot be used as yet as antibodies could not be detected; this might be because of lack of expression of a neo-epitope on the native recombinant proteins used for detection, or a low titer of antibodies, or another cause. These biomarkers are detected in 30% of pure lupus membranous nephropathy (class V) and are rare in mixed classes. In young, female patients with a diagnosis of primary membranous nephropathy, EXT1/2 staining may anticipate development of lupus disease [10^{***}].

NEURAL CELL ADHESION MOLECULE 1: A 'NEW' ANTIGEN ALSO ASSOCIATED WITH AUTO-IMMUNE DISEASES

NCAM1, a member of the Ig superfamily of proteins (MW, 120 kDa), was identified by Larsen's group [13^{***}] using the same approach as Sethi *et al.* but in addition they performed protein G immunoprecipitation studies from frozen biopsies. NCAM1 was found to colocalize with IgG within glomerular immune deposits. Unlike EXT1/2, antibodies to recombinant NCAM1 were detected in the patients' sera. NCAM1 was detected in 6.6% (14/212) of membranous lupus nephritis with or without proliferative changes and 2% (2/101) of primary membranous nephropathy. In the same study, 15.8% (33/209) of lupus membranous nephropathy stained positive for EXT2. Thus, NCAM1 ranks second in the list of antigens/biomarkers in lupus membranous nephropathy, and more than two-thirds of cases remain orphan without identified antigen.

Clinical and biopsy findings were similar to those of EXT1/2 with an average age of 34 years, 70% of women, frequent staining for IgA, IgM, and C1q, variable staining of IgG subclasses but without predominance of IgG4 in most studied cases, and mesangial deposits by electron microscopy. Neuropsychiatric disease occurred in 8/20 (40%) patients possibly related to NCAM1 expression in the central nervous system [15]. Unexpectedly, it could not be detected in podocytes in normal kidney biopsies or non-NCAM1 membranous nephropathy [13^{***}].

NEURAL EPIDERMAL GROWTH FACTOR-LIKE 1 PROTEIN: A 'NEW' ANTIGEN ASSOCIATED WITH 'PRIMARY' AND CANCER-RELATED MEMBRANOUS NEPHROPATHY

NELL-1 is a secreted, 90-kDa protein expressed in osteoblasts and promoting bone regeneration [16].

An initial pilot MS study showed high spectral counts for NELL-1 in 6 of 35 cases of PLA2R-negative membranous nephropathy while MS failed to detect NELL-1 in 23 PLA2R-positive membranous nephropathy and 88 controls. Twenty-three additional NELL-1-positive cases were identified by IHC in a discovery cohort of 91 PLA2R-negative membranous nephropathy. Thus, 29 of 126 (23%) PLA2R-negative biopsies were positive for NELL-1. Five NELL-1-positive cases out of 84 PLA2R and THSD7A-negative biopsies were further identified in two validation cohorts from France and Belgium. By IHC, bright, granular staining of subepithelial immune deposits was seen in all NELL-1 positive cases whereas all controls including PLA2R and THSD7A stained negative. Interestingly, there was segmental positive staining confirmed by electron microscopy in a few cases. By confocal microscopy, both IgG and NELL-1 colocalized to the glomerular basement membrane. Circulating antibodies against recombinant NELL-1 were detected under non-reducing conditions by western blot in five available sera, no reactivity was seen in control sera and under reducing conditions. Antibodies recognized the dimeric and trimeric forms of NELL-1 that resolved in a nonreactive monomer after reduction. In one patient, antibodies were not detected after successful treatment with rituximab, which suggests correlation of antibody titer with disease activity.

Clinical and biopsy findings showed features of primary membranous nephropathy with a mean age of 63.1 years and a slight male preponderance but differed by the IgG subclass pattern and the association with cancer in the validation cohorts. All four IgG subclasses were detected by MS, with IgG1 being the most abundant and IgG4 the least. Four of the five patients of the discovery cohort had a cancer discovered at the time, or a few months after, the diagnosis of membranous nephropathy. Types of cancer were epidermoid lung cancer, metastatic pancreatic carcinoma, metastatic breast cancer, and infiltrating urothelial carcinoma. In one patient, cure of the cancer induced complete remission of nephrotic syndrome with disappearance of antibodies.

A recent study by Caza *et al.* [17^{***}] confirmed that NELL-1 could be the first candidate antigen in malignancy-associated membranous nephropathy. They reported the largest series of NELL-1-associated membranous nephropathy including 91 patients. They made three important observations: IgG deposits were global but incomplete or segmental in 93.4% of cases, IgG1 subclass was present in all cases whereas IgG4 was detected in only 54%, and a cancer was diagnosed in 33% of cases. Whenever available, the tumor biopsy stained positive for

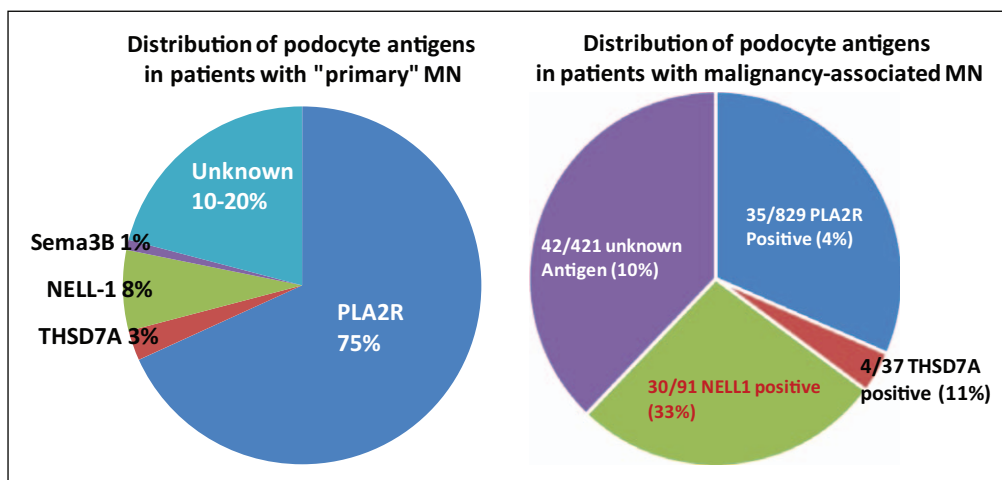


FIGURE 2. Distribution of podocyte antigens in 'primary' (left) and malignancy-associated (right) membranous nephropathy. The piechart on the left is an extrapolation from refs. [11^{••}, 12^{••}, 17^{••}, 18]. Prevalences should be confirmed in future studies. The piechart on the right is adapted from Supplemental Fig. 6 in Caza *et al.* [17^{••}].

NELL-1. A majority of NELL1-associated membranous nephropathy patients with a history of malignancy had concurrent proteinuria and ongoing malignancy ($n = 19/30$).

Caza *et al.* [17^{••}] also specified antigen prevalence in 111 cancer-associated membranous nephropathy identified among 1378 biopsies of 'primary' membranous nephropathy collected over a 5-year period (Fig. 2). Of the 111 biopsies, 35 were PLA2R positive, 4 were THSD7A-positive, 30 were NELL1-positive, and 42 were with unknown antigen. In term of antigen prevalence, NELL-1 came first (33%) followed by THSD7A (11%) whereas PLA2R-positive cases accounted for only 4%. Thus, the finding of NELL-1 in a biopsy should trigger a detailed workup to screen for malignancy as recently discussed for PLA2R-negative patients [19]. The pathophysiology of cancer-associated NELL-1-positive membranous nephropathy remains uncertain. NELL-1 is highly expressed within most tumors associated with membranous nephropathy, yet only a small percentage of patients with these tumors will develop membranous nephropathy. Further studies are needed to determine the genetic background and the triggering event.

In a retrospective analysis of all patients with segmental membranous nephropathy diagnosed at Columbia University from January 2010 to October 2018, 50 cases were identified, representing 2.5% of membranous nephropathy [20^{*}]. Staining for NELL-1 was positive in 5 of 17 cases (29%) available for study while staining for PLA2R, THSD7A, and EXT1 was negative in all biopsies evaluated. Thus NELL-1 appears to be the first antigen in segmental membranous nephropathy.

SEMAPHORIN 3B: A 'NEW' ANTIGEN PREDOMINANT IN PEDIATRIC PATIENTS

Semaphorin 3B is a secreted, 81 kDa protein that belongs to a family of proteins serving varying functions during development and in adults through interactions with their receptors plexin and neuropilin. For this study, we collaborated with pediatricians as in the discovery cohorts, biopsies from children stained positive for Sema3B. In the pediatric cohorts recruited in Paris and Rome, 6/59 (10%) biopsies stained positive for Sema3B whereas they stained negative for PLA2R, THSD7A, NELL-1 and EXT1/2. If we withdraw the 18/59 children with lupus membranous nephropathy, the real prevalence of Sema3B-associated disease among nonlupus patients was 14.9%, thus making Sema3B the first antigen in pediatric membranous nephropathy. In total, we identified 11 patients with Sema3B-associated membranous nephropathy, of which 8 patients were children and 5 patients developed membranous nephropathy on or before the age of 2 years. The average age in adult patients was 36.3 years, much lower than the 'primary' membranous nephropathy age group. All cases showed bright granular staining of Sema3B, which was colocalized with IgG by confocal immunofluorescence. Interestingly, four cases, all pediatric, showed granular deposits of IgG along the tubular basement membrane. Circulating antibodies against Sema3B recombinant protein were detected in four of the five available sera but they unexpectedly reacted with the reduced form only which is in sharp contrast with all other membranous nephropathy antibodies that recognize conformational epitopes destroyed by reduction. All other tested sera

including from controls and patients in remission were negative. Sema3B contains conserved cysteine residues forming intra-subunit disulfide bonds. We hypothesize that disruption of these disulfide bonds could unmask new protein domains that could serve as neopeptides.

Clinical and biopsy findings of Sema3B-positive membranous nephropathy showed diverse features of 'secondary' membranous nephropathy including association with type-1 diabetes and thrombocytopenic purpura, occasional full-house immunofluorescence, and lack of staining for IgG4 in most cases. Additionally, genetic factors were likely involved in two siblings and in a family where the father and one child were affected with the disease. Contrary to Sema3A, which has been shown to regulate slit diaphragm proteins [21], the role and function of Sema3B in the kidney is not known.

It is now possible to have a more precise view of the prevalence of the antigens associated with 'primary' forms of membranous nephropathy (Fig. 2). Although PLA2R is the major auto-antigen in membranous nephropathy, NELL-1 now ranks second before THSD7A and the other antigens. Still 10–20% of cases are with unknown antigen as yet.

PRIMARY VERSUS SECONDARY MEMBRANOUS NEPHROPATHY: SHIFTING FROM ETIOLOGICAL TO SEROLOGICAL CLASSIFICATION

The classification of membranous nephropathy between primary and secondary forms that was justified before the identification of the major antigens has been somewhat overtaken since then. Table 1 recapitulates the various antigens and biomarkers that have been identified. It shows that for each 'serotype', some patients have a secondary form whereas others have as yet a primary form. Identification of the antigen or biomarker is of the utmost importance as it guides the etiological investigation and because circulating antibodies to those antigens provide invaluable tools for treatment monitoring. Consequently, we think that the time has come to propose a new molecular classification of membranous nephropathy based on the target antigen or biomarker identified. When a cause is identified, treatment should first aim at treating the cause. In other cases, preliminary data suggest that response to therapy is about the same as in PLA2R-related membranous nephropathy.

Table 1. Target antigens and biomarkers in patients with membranous nephropathy

	PLA2R1	THSD7A	EXT1/EXT2	NCAM1	NELL-1	Sema3B
UniProt ID	Q13018	Q9UPZ6	Q16394, Q93063	P13591 (120 kDa isoform)	Q92832	Q13214
Size (in amino acids)	1463	1657	746, 718	858	810	749
Compartment	Transmembrane glycoprotein	Transmembrane glycoprotein	Glycosyltransferase in Golgi and secreted	Transmembrane glycoprotein	Secreted	Secreted
Evidence for expression by podocyte	Strong	Strong	Moderate (EXT2 > EXT1)	Weak if any	Weak	Strong Sema3A ??? Sema3B
Presence in subepithelial deposits	Yes	Yes	Yes	Yes	Yes, often segmental	Yes
Circulating Ab	Yes	Yes	No	Yes	Yes	Yes, reduced Ag
Predominant subclass in deposits	IgG4	IgG4	IgG1	IgG1 +/- other subclasses	IgG1	IgG1 / not IgG4
Distinctive associations	Prototype for primary MN	Malignancy in a minority of cases	Lupus (#30%) or other systemic autoimmune disease	Lupus (#7%)	Association with malignancy (NELL-1 in tumor cells)	Pediatric MN; early onset

Adapted from Hayashi and Beck [22]. A comparison of target antigens or pathological biomarkers in subtypes of membranous nephropathy is shown. It is noticeable that the 'new' antigens are secreted except for NCAM, have at best a weak expression in podocytes, are associated with IgG1 deposits, and observed in different settings from PLA2R-associated membranous nephropathy. Bold characters indicate the features that differentiate the newly discovered antigen from PLA2R and THSD7A. EXT1/2, exostosins 1 and 2; MN, membranous nephropathy; NCAM1, neural cell adhesion molecule 1; NELL-1, neural epidermal growth factor-like 1 protein; Sema3B, semaphorin 3B.

CONCLUSION

The discovery of the new membranous nephropathy antigens was recently compared with Moore's law that is a doubling every 2 years in the number of transistors that can be fit onto a computer chip [22]. Even more antigens are in the pipeline, such as protocadherin-7 (PCDH7) and high temperature recombinant protein A1 (HTRA1) presented at the 2020 ASN meeting. Like PLA2R, these 'new' antigens will have a substantial clinical impact. For pathologists, staining of PLA2R-negative paraffin biopsies can now be performed according to the clinical context with the relevant antibodies that are all commercially available. For clinicians, treatment monitoring will be made possible as soon as serological tests will become available.

Acknowledgements

We are greatly indebted to our collaborators who took an important part in the characterization of the 'new' membranous nephropathy antigens: Sanjeev Sethi, Benjamin Madden and Fernando C. Fervenza at Mayo Clinic (Rochester, Minnesota, USA), Marina Vivarelli, Francesca Diomedei-Camassei and Francesco Emma at Bambino Gesù Pediatric Hospital (Rome, Italy), Johan Morelle and Michel Jadoul at Cliniques Universitaires Saint-Luc (Brussels, Belgium), Tim Ulinski at Hôpital Armand-Trousseau (Paris, France) and David Buob at Hôpital Tenon (Paris, France).

Financial support and sponsorship

P.R. is a recipient of European Research Council ERC-2012-ADG_20120314 grant 322947, 7th Framework Programme of the European Community contract 2012-305608 (European Consortium for High-Throughput Research in Rare Kidney Diseases), and the National Research Agency grant MNaims (ANR-17-CE17-0012-01) and SeroNegMN (ANR-20-CE17-0017-01).

Conflicts of interest

There are no conflicts of interest.

REFERENCES AND RECOMMENDED READING

Papers of particular interest, published within the annual period of review, have been highlighted as:

- of special interest
- of outstanding interest

1. Debiec H, Guignon V, Mougnot B, *et al*. Antenatal membranous glomerulonephritis due to antineutral endopeptidase antibodies. *N Engl J Med* 2002; 346:2053–2060.
2. Debiec H, Nauta J, Coulet F, *et al*. Role of truncating mutations in MME gene in fetomaternal allo-immunization and neonatal glomerulopathies. *Lancet* 2004; 364:1252–1259.
3. Kerjaschki D, Farquhar MG. Immunocytochemical localization of the Heymann nephritis antigen (GP330) in glomerular epithelial cells of normal Lewis rats. *J Exp Med* 1983; 157:667–686.
4. Beck LH Jr, Bonegio RG, Lambeau G, *et al*. M-type phospholipase A2 receptor as target antigen in idiopathic membranous nephropathy. *N Engl J Med* 2009; 361:11–21.
5. Tomas NM, Beck LH Jr, Meyer-Schwesinger C, *et al*. Thrombospondin type-1 domain-containing 7A in idiopathic membranous nephropathy. *N Engl J Med* 2014; 371:2277–2287.
6. Xie Q, Li Y, Xue J, *et al*. Renal phospholipase A2 receptor in hepatitis B virus-associated membranous nephropathy. *Am J Nephrol* 2015; 41:345–353.
7. Berchtold L, Zanetta G, Dahan K, *et al*. Efficacy and safety of rituximab in hepatitis B virus-associated PLA2R-positive membranous nephropathy. *Kidney Int Rep* 2017; 3:486–491.
8. Stehlé T, Audard V, Ronco P, Debiec H. Phospholipase A2 receptor and sarcoidosis-associated membranous nephropathy. *Nephrol Dial Transplant* 2015; 30:1047–1050.
9. Hoxha E, Wiech T, Stahl PR, *et al*. A mechanism for cancer-associated membranous nephropathy. *N Engl J Med* 2016; 374:1995–1996.
10. Sethi S, Madden BJ, Debiec H, *et al*. Exostosin 1/exostosin 2-associated membranous nephropathy. *J Am Soc Nephrol* 2019; 30:1123–1136. This study provides the first demonstration that combination of laser microdissection of glomeruli and MS identification of trypsin-digested peptides leads to the discovery of new biomarkers/antigens of membranous nephropathy. EXT1/2 is associated with 20–30% of lupus membranous nephropathy class V.
11. Sethi S, Debiec H, Madden B, *et al*. Neural epidermal growth factor-like 1 protein (NELL-1) associated membranous nephropathy. *Kidney Int* 2020; 97:163–174. This study provides the first identification of NELL-1, which is the major antigen in PLA2R-negative membranous nephropathy, and ranks second before THSD7A in so-called primary membranous nephropathy. It also suggests that deposits may be segmental and associated with malignancy.
12. Sethi S, Debiec H, Madden B, *et al*. Semaphorin 3B-associated membranous nephropathy is a distinct type of disease predominantly present in pediatric patients. *Kidney Int* 2020; 98:1253–1264. This study provides the first identification of Sema3B, which appears to be the major antigen in childhood membranous nephropathy, with a common onset at the age of 2 years or before. Antibodies specific for Sema3B only recognize the reduced protein, which is an exception among the membranous nephropathy antigens.
13. Caza T, Hassen S, Kuperman M, *et al*. Neural cell adhesion molecule 1 is a novel autoantigen in membranous lupus nephritis. *Kidney Int* 2020; doi : 2020.09.016. This study establishes NCAM-1 as the second antigen in lupus membranous nephropathy, associated with about 7% of cases.
14. Busse-Wicher M, Wicher KB, Kusche-Gullberg M. The exostosin family: proteins with many functions. *Matrix Biol* 2014; 35:25–33.
15. Uhlén M, Fagerberg L, Hallström BM, *et al*. Proteomics. Tissue-based map of the human proteome. *Science* 2015; 347:1260419.
16. Zhang X, Zera J, Siu RK, *et al*. The role of NELL-1, a growth factor associated with craniosynostosis, in promoting bone regeneration. *J Dent Res* 2010; 89:865–878.
17. Caza T, Hassen S, Dvanajscak Z, *et al*. NELL1 is a target antigen in malignancy-associated membranous nephropathy. *Kidney Int* 2020. This study establishes that NELL-1 is the major antigen associated with malignancy-related membranous nephropathy. It also confirms two unusual characteristics of NELL-1 associated membranous nephropathy: segmental deposits or incomplete global deposits and predominance of IgG1 in most cases.
18. Hanset N, Aydin S, Demoulin N, *et al*. UCLouvain Kidney Disease Network. Podocyte antigen staining to identify distinct phenotypes and outcomes in membranous nephropathy: a retrospective multicenter cohort study. *Am J Kidney Dis* 2020; 76:624–635.
19. Plaisier E, Ronco P. Screening for cancer in patients with glomerular diseases. *Clin J Am Soc Nephrol* 2020; 15:886–888.
20. Kudose S, Santoriello D, Debiec H, *et al*. The clinicopathologic spectrum of segmental Q1 membranous glomerulopathy Q39. *Kidney Int* 2020; 99:247–255. This retrospective study of segmental membranous nephropathy shows that NELL-1 is the only antigen associated with this rare form of membranous nephropathy so far, accounting for a third of the cases. All other antigens including PLA2R, THSD7A, EXT1/2 are not detected.
21. Guan F, Villegas G, Teichman J, *et al*. Autocrine class 3 semaphorin system regulates slit diaphragm proteins and podocyte survival. *Kidney Int* 2006; 69:1564–1569.
22. Hayashi N, Beck LH Jr. Moore's law for membranous nephropathy. *Kidney Int* 2020; 98:1081–1084.