



HAL
open science

Endoscopic management of anastomotic leak after esophageal or gastric resection for malignancy: a multicenter experience

Rachel Hallit, Mélanie Calmels, Ulriikka Chaput, Diane Lorenzo, Aymeric Becq, Marine Camus, Xavier Dray, Jean Michel Gonzalez, Marc Barthet, Jérémie Jacques, et al.

► To cite this version:

Rachel Hallit, Mélanie Calmels, Ulriikka Chaput, Diane Lorenzo, Aymeric Becq, et al.. Endoscopic management of anastomotic leak after esophageal or gastric resection for malignancy: a multicenter experience. *Therapeutic Advances in Gastroenterology*, 2021, 14, pp.175628482110328. 10.1177/17562848211032823 . hal-03334186

HAL Id: hal-03334186

<https://hal.sorbonne-universite.fr/hal-03334186>

Submitted on 3 Sep 2021

HAL is a multi-disciplinary open access archive for the deposit and dissemination of scientific research documents, whether they are published or not. The documents may come from teaching and research institutions in France or abroad, or from public or private research centers.

L'archive ouverte pluridisciplinaire **HAL**, est destinée au dépôt et à la diffusion de documents scientifiques de niveau recherche, publiés ou non, émanant des établissements d'enseignement et de recherche français ou étrangers, des laboratoires publics ou privés.

Endoscopic management of anastomotic leak after esophageal or gastric resection for malignancy: a multicenter experience

Rachel Hallit^{ID}, Mélanie Calmels, Ulriikka Chaput, Diane Lorenzo, Aymeric Becq, Marine Camus^{ID}, Xavier Dray, Jean Michel Gonzalez, Marc Barthet, Jérémie Jacques, Thierry Barrioz, Romain Legros, Arthur Belle, Stanislas Chaussade, Romain Coriat, Pierre Cattan, Frédéric Prat, Diane Goere and Maximilien Barret

Abstract

Background: Most anastomotic leaks after surgical resection for esophageal or esophagogastric junction malignancies are treated endoscopically with esophageal stents. Internal drainage by double pigtail stents has been used for the endoscopic management of leaks following bariatric surgery, and recently introduced for anastomotic leaks after resections for malignancies. Our aim was to assess the overall efficacy of the endoscopic treatment for anastomotic leaks after esophageal or gastric resection for malignancies.

Methods: We conducted a multicenter retrospective study in four digestive endoscopy tertiary referral centers in France. We included consecutive patients managed endoscopically for anastomotic leak following esophagectomy or gastrectomy for malignancies between January 2016 and December 2018. The primary outcome was the efficacy of the endoscopic management on leak closure.

Results: Sixty-eight patients were included, among which 46 men and 22 women, with a mean \pm SD age of 61 ± 11 years. Forty-four percent had an Ivor Lewis procedure, 16% a tri-incisional esophagectomy, and 40% a total gastrectomy. The median time between surgery and the diagnosis of leak was 9 (6–13) days. Endoscopic treatment was successful in 90% of the patients. The efficacy of internal drainage and esophageal stents was 95% and 77%, respectively ($p=0.06$). The mortality rate was 3%. The only predictive factor of successful endoscopic treatment was the initial use of internal drainage ($p=0.002$).

Conclusion: Endoscopic management of early postoperative leak is successful in 90% of patients, preventing highly morbid surgical revisions. Internal endoscopic drainage should be considered as the first-line endoscopic treatment of anastomotic fistulas whenever technically feasible.

Keywords: anastomotic leak, double pigtail stent, endoscopic management, esophageal cancer, esophageal or gastric cancer, esophagogastric junction adenocarcinoma, gastric cancer, internal drainage, self-expendable metallic stent

Received: 12 November 2020; revised manuscript accepted: 25 June 2021.

Introduction

Although endoscopic resection has become the standard of care for most intramucosal esophageal and gastric neoplasms,^{1,2} surgical resection remains the standard of care for a large proportion of esophageal or gastric cancers.³ Esophagectomy is

performed either *via* a trans-hiatal, a two-field transthoracic (Ivor Lewis) or a three-field transthoracic approach (McKeown),^{4,5} and esophagogastric junction cancers may also be resected by total gastrectomy in cases of major patient comorbidities, increasing the surgical risk of an

Ther Adv Gastroenterol

2021, Vol. 14: 1–10

DOI: 10.1177/
17562848211032823

© The Author(s), 2021.
Article reuse guidelines:
sagepub.com/journals-
permissions

Correspondence to:
Rachel Hallit Department
of Gastroenterology,
Cochin Hospital,
Assistance Publique-
Hôpitaux de Paris and
University of Paris, 27, rue
du Faubourg St Jacques,
Paris, 75014, France
rachelhallit@hotmail.com

Mélanie Calmels
Pierre Cattan
Diane Goere
Digestive Surgery
Department, St Louis
University Hospital,
Assistance Publique
Hôpitaux de Paris and
University of Paris, Paris,
France

Ulriikka Chaput
Aymeric Becq
Marine Camus
Xavier Dray
Sorbonne University,
Endoscopy Unit, AP-HP,
Hôpital Saint-Antoine,
Paris, France

Diane Lorenzo
Gastroenterology
Department, Beaujon
University Hospital,
Assistance Publique-
Hôpitaux de Paris and
University of Paris, Paris,
France

Jean Michel Gonzalez
Marc Barthet
Gastroenterology
Department, North
Hospital, Assistance
Publique – Hôpitaux de
Marseille and University of
Aix-Marseille, Marseille,
France

Jérémie Jacques
Romain Legros
Gastroenterology
Department, Limoges
University Hospital, and
University Limoges,
Limoges, France

Thierry Barrioz
Gastroenterology
Department, Poitiers
University Hospital,
Poitiers, France

Arthur Belle
Stanislas Chaussade
Romain Coriat
Frédéric Prat
Maximilien Barret
Gastroenterology
Department, Cochin
University Hospital,
Assistance Publique-
Hôpitaux de Paris and
University of Paris, Paris,
France

esophagectomy. Anastomotic leaks occur in up to 13.1% of cases after esophagectomy,⁶ and up to 9.8% of cases after total gastrectomy for cancer.⁷ Anastomotic leaks account for 9–30% of early postoperative complications,⁸ and one-third of post-operative deaths.⁹ They also impact patient management by delaying adjuvant treatments.¹⁰ The management of post-operative anastomotic leaks, previously relying on surgical revision – resulting in a 20–40% mortality rate¹¹ – or conservative treatment, progressively switched towards endoscopic therapy. The coverage of the anastomotic defect with endoscopically-placed esophageal stents, combined with surgical or radiological drainage of fluid collections, has been introduced in the 1990s, with a 69–77% success rate.¹²

Endoscopic treatment of gastric fistulas following bariatric surgery, using an internal drainage (ID) consisting in double pigtail stents inserted through the anastomotic defect, has shown excellent results with success rates ranging from 79% to 97%.^{13,14} The concept of ID is to allow the secretions of the collection to drain through and around the double pigtail stent, maintaining the parietal defect open, to avoid a premature closure of the fistula. The double pigtail stent is extracted endoscopically or migrates spontaneously once the cavity is filled with granulation tissue. Therefore, these double pigtail stents have been incorporated into the clinical endoscopic practice of expert centers over the last years. However, their clinical contribution has only been scarcely reported in the setting of esophageal or gastric resections for malignancies.¹⁵ Our aim was to report the overall efficacy of the endoscopic treatment for anastomotic leaks after esophageal or gastric resection for cancer.

Patients and methods

Design

This was a retrospective study conducted in four university hospitals in France. All patients operated by esophagectomy or total gastrectomy, between January 2016 and December 2018 for esophageal, esophagogastric junction and gastric cancers, with endoscopic management of a post-operative anastomotic leak, were included in the study. Patients were identified in each center using a prospectively collected database. The study was approved by our local Ethics Advisory Committee (CLEP no.: AAA-2019-08027). All the patients

provided written informed consent for the procedure and for the publication of their information.

Data collection

Demographic data, disease characteristics, Charlson comorbidity score, and procedural data related to surgery and endoscopy were collected. Post-operative leak was suspected in patients who presented signs of sepsis, a modification in the chest drains output, or a respiratory distress. The time between surgery and the diagnosis of the leak, as well as the diagnostic modality of the leak, and the time before the first treatment were collected as well.

Endoscopic procedures

Upper gastrointestinal endoscopies were performed by gastroenterologists in the endoscopy suite. Patients were under general anesthesia with oro-tracheal intubation. Leaks were identified endoscopically and confirmed by contrast opacification with fluoroscopy. The diameter and location of the orifice, the median number of endoscopic procedures and the healing time were recorded. The type of nutritional support was recorded (enteral, parenteral, or oral nutrition) as well as the use of concurrent medical therapy. Endoscopic treatment consisted of the placement of a self-expandable covered metallic stent (HanaRoStent[®] EBN22080-Z070, ECW22120-Z070, EVC20080-X070, Taewoong Niti-S[™] Beta) to cover the anastomotic defect, an internal drainage using double pigtail stents (Cook[®] Solus or Boston Scientific[®] Advanix 7 or 10 Fr 3–5 cm stents) or a combined therapy with the use of over-the-scope clips in some cases (OVESCO[®] over-the-scope clip 100.10). The number (one or two) and size of the double pigtail stents was chosen depending on the size of the anastomotic defect and the collection. The choice of the endoscopic treatment was left to the endoscopist. Briefly, a large anastomotic defect (>2 cm or one-third of the anastomotic circumference) or any size anastomotic defect associated with areas of necrotic mucosa led to the placement of an esophageal stent. Conversely, smaller anastomotic defects led to the choosing of internal drainage (video 1 online supplemental material). Patients were kept fasting (only water was allowed *per os*), with parenteral nutrition, enteral nutrition on a jejunostomy if available, or enteral nutrition on a nasojejunal or nasoduodenal feeding tube placed during the endoscopy. A follow-up

endoscopy was scheduled after 2–6 weeks. After extraction of the stents, the persistence of a large defect led to the placement of another esophageal stent or double pigtail stents for another 2–6 weeks. In the case of a small (<20 mm) residual anastomotic defect, opacification was performed directly through the fistula using a double-lumen wire-guided catheter (Tandem catheter and Jagwire, Boston, MA, USA): the persistence of an undrained collection led to the placement of a new double pigtail stent, and oral food could be resumed; in some instances of externally-drained collections with a small (<10 mm) non-fibrotic anastomotic defect, typically on esophagojejunal anastomosis, the placement of an over-the-scope clip could be attempted and oral food could be resumed; in the absence of residual collection, with opacification of the space previously occupied by the pigtail stent, no additional endoscopic therapy was performed and oral food could be resumed. Complete healing was defined by the spontaneous migration of all internal drainage material and a normal appearing mucosa on the anastomosis. The presence of an anastomotic stricture was also recorded.

Study endpoints

The primary endpoint was the overall efficacy of the endoscopic management of an anastomotic leak defined by the absence of sepsis, the possibility of a normal oral food intake, the endoscopic healing of the anastomotic defect or fistula, and the absence of residual perianastomotic collection on imaging or external drainage. Primary efficacy was defined as the resolution of the leak after a single endoscopic treatment session. Secondary efficacy was defined as the resolution of the leak after any endoscopic procedure with more than one treatment session. Treatment failure was defined as a persistent leak despite three endoscopic treatment sessions, indicating a surgical revision of the anastomosis or leading to the patient's death.

The secondary endpoints were the respective efficacy of the ID and the esophageal stenting strategies, the number of endoscopic treatment sessions needed to achieve leak closure, the factors associated with treatment success, and the incidence of post-operative stenosis.

Statistical analysis

Data analysis was performed using SPSS statistical software package (version 20, SPSS Inc.,

Chicago, IL, USA). The intention-to-treat analysis included all patients who entered the endoscopic treatment. Descriptive statistics were used to analyze patients' characteristics. Mean [\pm standard deviation (SD)] was used to describe variables showing a normal distribution and the median [interquartile range (IQR)] for variables with a skewed distribution. Chi-squared or Fisher's exact tests for qualitative variables and Mann-Whitney test or Student's *t*-test for quantitative variables were used in the univariate analysis. Multivariable analysis was performed to determine the strength of associations. Odds ratios and 95% confidence intervals were calculated using regression analysis. A two-tailed *p*-value < 0.05 determined a statistically significant result.

Results

Patients' characteristics

Sixty-eight patients, referred for endoscopic treatment of an anastomotic leak after esophagectomy or total gastrectomy, were included in the study from January 2016 to December 2018. There were 46 (68%) men and 22 (32%) women with a mean \pm SD age of 61 ± 11 years, and a median (IQR) Charlson morbidity score of 4 (IQR 3–5). Twelve percent of the patients had an esophageal squamous cell carcinoma ($n=8$) and 84% had an esophageal or gastric adenocarcinoma ($n=57$). Patients' characteristics are detailed in Table 1. Thirty (44%) patients had an Ivor Lewis procedure, 11 (16%) a tri-incisional esophagectomy, and 27 (40%) a total gastrectomy. The resection was histologically complete (R0) in 65 (96%) patients. Thirty-five patients (51%) received a neoadjuvant chemotherapy, eight (12%) received a neoadjuvant chemoradiotherapy, and 25 (37%) did not receive any treatment.

Thirty-two (47%) patients had an enteral nutritional support using a jejunostomy or a nasojejunal feeding tube, 29 (42%) patients had a parenteral nutrition and seven (10%) patients resumed oral food after endoscopic treatment. Twelve patients (18%) developed an anastomotic stricture during follow-up, all successfully managed by endoscopic balloon dilatations.

Diagnosis of the anastomotic leak

The median (IQR) time from the diagnosis of leak to endoscopic treatment was 2 (1–5) days,

Table 1. Patients' characteristics.

Patients' characteristics N=68	ID n=38	SEMS n=30	p value	
Age, years, mean \pm SD	61 \pm 11	62 \pm 9.55	60 \pm 12	0.637
Gender, n (%)				
Male	46 (68)	27 (71)	19 (63)	0.60
Female	22(32)	11 (29)	11 (37)	0.60
Charlson comorbidity score, median (IQR)	(3–5)	4 (2–6)	4 (1–7)	0.564
Preoperative treatment, n (%)				
CRT	8 (12)	3 (8)	5 (17)	0.45
CT	35 (51)	20 (53)	15 (50)	1
None	25 (37)	15 (39)	10 (33)	0.62
Surgical procedure, n (%)				
Ivor Lewis esophagectomy	30 (44)	16 (42)	14 (47)	0.80
Tri-incisional esophagectomy, McKeown	11 (16)	4 (11)	7 (23)	0.19
Total gastrectomy	27 (40)	18 (47)	9 (30)	0.212
Histology, n (%)				
Esophageal squamous cell carcinoma	8 (12)	2 (5)	6 (20)	0.125
Esophageal adenocarcinoma EGJ and gastric	14 (20)	10 (26)	4 (13)	0.23
Adenocarcinoma	43 (63)	24 (64)	19 (64)	1
Other histology	3 (4)	2 (5)	1 (3)	1
Resection margins, n (%)				
R0	65 (96)	37 (97)	28 (93)	0.57
R1	3 (4)	1 (3)	2 (7)	

CRT, chemoradiotherapy; CT, chemotherapy; EGJ, esophagogastric junction; ID, internal drainage; IQR, interquartile range; R0, negative resection margins; R1, positive resection margins; SEMS, self-expandable metallic stent.

and the median (IQR) number of endoscopic procedures was 2 (2–7).

The anastomotic leak was detected on computed tomography in 45 (66%) patients, and clinically

evident in 19 (28%) patients. Only four (6%) cases of anastomotic leak were diagnosed during an upper endoscopy. The median (IQR) time between surgery and the diagnosis of the leak was 9 (6–13) days. A surgical revision of the anastomosis had been attempted before the endoscopy in 10 (17%) patients.

Thirty-five (51%) patients had an anastomotic defect larger than 10mm. Forty-one (60.3%) patients had a perianastomotic collection [following an esophagojejunal anastomosis in 26 (38%) patients and an esophagogastric anastomosis in 31 (45.6%) patients], six (9%) an esophagotracheal or esophagobronchial fistula, and five (7%) patients had an esophagopleural collection. The characteristics of the anastomotic leaks are provided in Table 2.

Outcomes of the endoscopic treatment

Overall, 38 patients were initially treated with internal drainage and 30 patients with an esophageal stent (one patient had an initial combined treatment with ID and stent). The overall efficacy of the endoscopic management of anastomotic leak therapy was 90% (61/68). The primary and secondary efficacy rates were 57% (39/68) and 79% (22/28) respectively.

The ID approach was successful in all 38 patients (100%), of which 24/38 (63%) had a primary treatment success, 12/38 (32%) a secondary treatment success with repeat ID, and 2/38 (5%) a secondary treatment success with over-the-scope clips. The esophageal stent approach was successful in 23/30 (77%) of cases, of which 15/30 (50%) had a primary treatment success, 5/30 (17%) a secondary treatment with repeat esophageal stenting, 2/30 (7%) a secondary treatment success with over-the-scope clips, and 1/30 (3%) a secondary treatment success with ID. The overall efficacy of the endoscopic treatment on leak closure was 90% after a mean \pm SD time of 60 \pm 51 days and a median (range) of 2 (2–7) endoscopic procedures. These results are presented as a flowchart in Figure 1.

Of the seven patients with endoscopic treatment failure, two were initially treated endoscopically with a stent but died of a respiratory distress and/or septic shock. The five remaining patients had a surgical reintervention allowing to close the leak. The six patients who had an enteral airway fistula

were all treated endoscopically with success using esophageal stents. The overall mortality rate was 3% (2/68).

The rate of treatment success was 100% (38/38) versus 77% (23/30) with ID and stent placement, respectively ($p=0.002$). In a univariate analysis including the age, gender, Charlson comorbidity score, type of surgery, resection margins, prior neoadjuvant chemoradiation therapy (CRT), time to the diagnosis of the anastomotic leak, surgical revision before the endoscopic treatment, size of the anastomotic defect, type of nutrition, and the type of endoscopic treatment, only the use of ID as the initial endoscopic treatment modality was associated with treatment success ($p=0.002$). Multivariate analysis including age, gender, time to the diagnosis of the anastomotic leak, size of the fistula, and type of endoscopic treatment did not find any parameters significantly associated with treatment success. The steps of a representative successful treatment sequence are illustrated in Figure 2.

Discussion

The overall efficacy of the endoscopic treatment on anastomotic leak closure was 90% after a median time of 41 days and a median of 2 endoscopic procedures. The clinical efficacy of endoscopic therapy observed in this study is slightly higher than what has been reported in the literature: Schweigert *et al.*,¹⁶ in a study including 22 patients with intrathoracic anastomotic leak following esophago-gastric resection, found that the endoscopic stenting is effective in 80% of patients. Gonzalez *et al.*¹⁰ recently observed in a similar study involving 35 patients that endoscopic stenting for anastomotic leaks following esophagectomy had an overall success rate of 70%. Other reports, including 18–31 patients, showed success rates ranging from 74% to 89% with esophageal stenting.^{17,18}

However, the use of esophageal stents for anastomotic leaks has some limitations: first, esophageal stents may migrate distally, especially given the absence of stricture, which may be a major concern for esophagojejunal anastomoses. Second, the radial expansion of the stent may in some cases increase local ischemia at the level of the anastomosis and widen the defect, or cause esophagorespiratory fistulas. Third, stents tend to retract over time, causing potential leakage of saliva and orally-ingested fluids between the

Table 2. Characteristics and management of the 68 anastomotic leaks and fistulas following esophageal or gastric resection. Characteristics of the 68 anastomotic leaks following esophageal or gastric resection..

Patients' characteristics N=68	ID n=38	SEMS n=30	p value	
Main diagnostic modality, n (%)				
Clinical symptoms	19 (28)	16 (42)	3 (10)	0.006
CT scan	45 (66)	20 (53)	25 (83)	0.01
Endoscopy	4 (6)	2 (5)	2 (7)	1
Time between surgery and diagnosis, days, median (IQR)	9 (6–13)	9.5	8.5	0.98
Median distance of the fistula from dental arches, cm, median (IQR)	32.5 (14–45)	35 (14–40)	27 (15–45)	0.03
Diameter of the anastomotic defect, n (%)				
<1 cm	33 (49)	18 (47)	15 (60)	1
1–2 cm	24 (35)	15 (40)	9 (30)	0.45
>2 cm	11 (16)	5 (13)	6 (10)	0.51
Median time to endoscopic treatment, days, median (IQR)	2 (1–5)	2	2	1
Type of anastomotic leak, n (%)				
Perianastomotic collection				
Esophagogastric anastomosis	31 (46)	17 (45)	14 (47)	1
Esophagojejunal anastomosis	26 (38)	17 (45)	9 (30)	0.315
Esophagotracheal/bronchial fistula	6 (9)	1 (3)	5 (17)	0.08
Esophagopleural fistula	5 (7)	3 (7)	2 (6)	0.45
CT, computed tomography; ID, internal drainage; IQR, interquartile range; SEMS, self-expandable metallic stent.				

digestive wall and the stent itself and into the anastomotic defect. Last, perianastomotic collections need to be drained before the stent is placed, to adequately treat the sepsis.

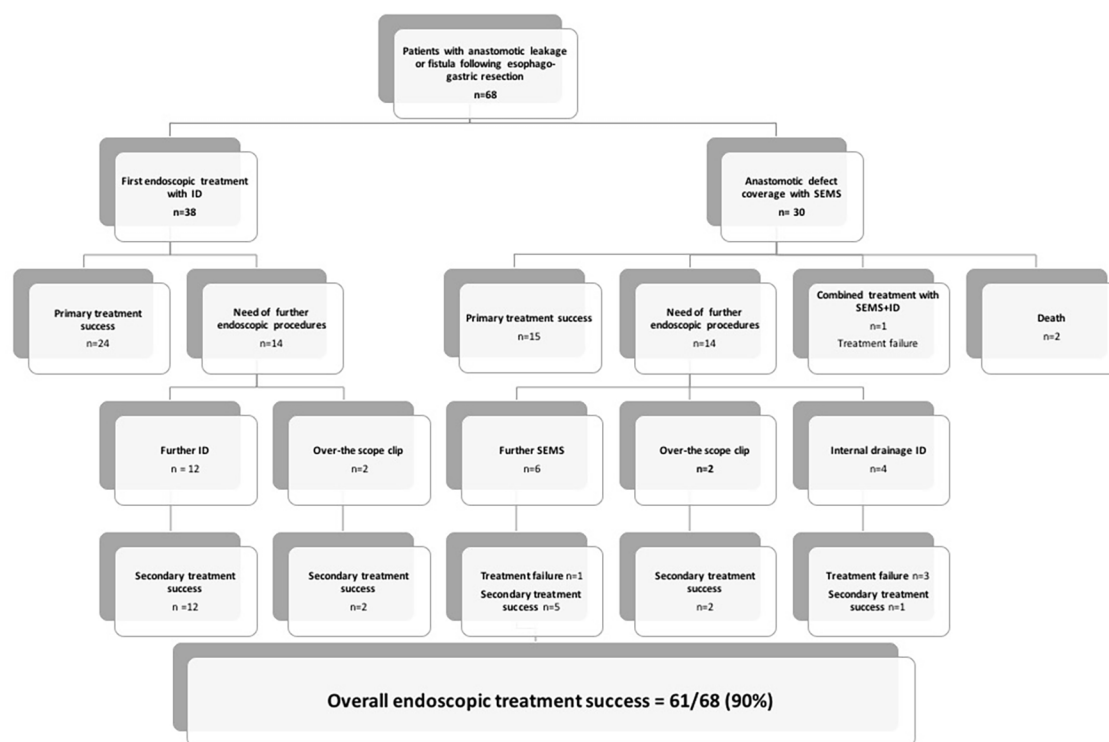


Figure 1. Study flowchart.
ID, internal drainage; SEMS, self-expandable metallic stent.

To our knowledge, this study is the largest to report the use of trans fistular internal drainage for anastomotic leaks after esophageal or gastric resection for cancer. This therapeutic approach, using double pigtail stents originally designed for the drainage of pancreatic pseudocysts,¹⁹ showed excellent success rates for the drainage of abdominal collections following sleeve gastrectomy, with up to 93% fistula closure rates.²⁰ This ID for anastomotic leaks has only been reported in a case series by Donatelli *et al.*,²¹ with 100% clinical efficacy in five patients. Our results suggest a superior efficacy of ID over stenting, with an efficacy of ID even after an initial stent failure. However, the retrospective nature of the study implies a selection bias. The patients with the largest anastomotic defects and/or presenting esophago-tracheal or esophago-bronchial fistulas, or who are clinically unstable, are overrepresented in the stent group. Indeed, considering the risk of migration and obstruction, and the negative pressure in the airways, esophago-respiratory fistulas were all treated by esophageal stents. Endoscopic vacuum therapy (EVT) is another kind of trans fistular endoscopic drainage, introduced in the late 2000s. It is currently routinely used in Germany for the endoscopic therapy of upper gastrointestinal leaks,

including anastomotic leaks after oncologic surgery, with leak closure success rates of 90% and a median treatment period of 17 days.²² Four retrospective studies, comparing EVT with stenting in the treatment of upper gastro-intestinal defects, showed a higher success rate and fewer adverse events with EVT, even in patients with major anastomotic defects.^{23–26} Although highly effective, EVT is not currently available in France. Furthermore, this treatment modality requires a prolonged hospital admission and repeated endoscopic procedures to change the sponge.²⁷

One of the aims of this work was to determine whether variables were associated with a higher success rate of the endoscopic management. In accordance with previous studies,²⁸ we did not identify any impact of the type of surgical resection on the efficacy of the endoscopic treatment. Of note, we did not record any esophageal leak or fistula requiring endoscopic management after trans-hiatal esophagectomy. This is likely due to a lower incidence of anastomotic leak after this type of surgery, the leaks on cervical anastomoses being usually managed conservatively, or drained radiologically or surgically instead of endoscopically. Also, this surgical approach has fallen out of

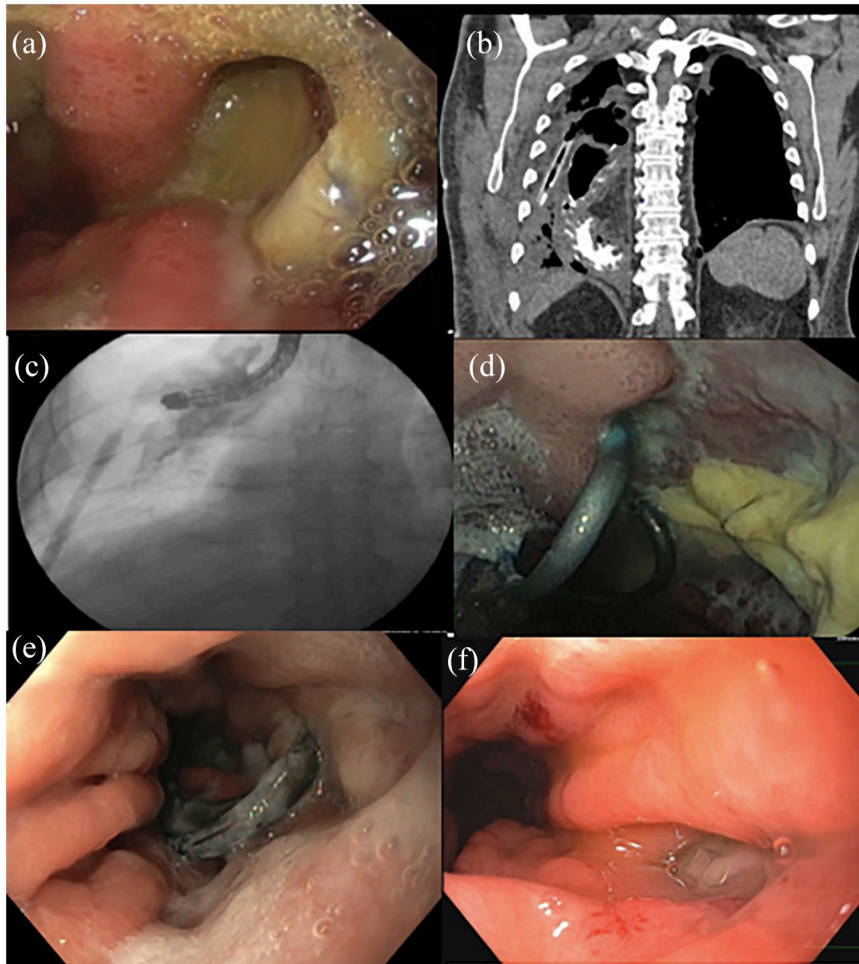


Figure 2. Leak of an esophagogastric anastomosis after Ivor Lewis procedure treated by endoscopic internal drainage (double pigtail stents). (a) Endoscopic view of the leak at the right side of the anastomosis with issue of pus despite external drainage. (b) Computed tomography scanner with oral contrast intake showing a perianastomotic collection and the external drainage. (c) Fluoroscopic view with opacification through the endoscope of a cloudy collection at the right side of the anastomosis. (d) Endoscopic view of the proximal, intraluminal end of the double pigtail stents after 3 weeks. (e) Endoscopic view of the proximal, intraluminal end of the double pigtail stents after 2 months, with almost complete healing of the anastomotic defect around the stents. (f) Endoscopic healing of the fistula after extraction of the double pigtail stents.

favor given its suboptimal oncologic results.²⁹ Neoadjuvant CRT was not significantly associated with the failure of the endoscopic treatment in this study. Neoadjuvant CRT does not increase the risk of anastomotic leak in most studies,^{30–32} as long as radiation doses are below 50 Gy.^{33,34} Similarly to previously published studies,³⁵ we did not identify that neoadjuvant CRT was a risk factor for poor outcome after endoscopic treatment.

The median time between the diagnosis of fistula and the endoscopic treatment was two days, and the median time from surgery to the diagnosis of fistula was nine days. Those two factors were not

associated with the success of endoscopic therapy in our study, possibly because all anastomotic leaks were managed at an early stage in experienced endoscopic referral centers. The median time to achieve a complete healing from the diagnosis of fistulas was 61 days, which is similar to previous reports in the literature.³⁶

This study does not allow to draw any conclusion regarding the optimal feeding protocol during endoscopic therapy of an anastomotic leak. Enteral nutrition is indicated to prevent malnutrition and improve the healing process, through a jejunostomy when available, or a nasoduodenal/

nasojejunal feeding tube. In other cases, parenteral nutrition is provided, and the patient fasts for three to four weeks until the next endoscopy. After the second endoscopy, even if another stent or ID is placed, the collection is usually partially healed, and a soft food diet can be allowed. Importantly, we did not observe any significant relationship between the oral intake and the outcomes of endoscopic treatment. Although most patients had an enteral or parenteral nutrition with long-term administration of antibiotics during the treatment period, all of the seven patients who resumed oral food after the first endoscopic treatment eventually healed their anastomotic leak. This has also been suggested in a recent study by Liu *et al.*,³⁷ which showed that the early oral feeding after esophagectomy does not increase post-operative complications and mortality.

The main limitation of this study was its retrospective design. However, since these patients were managed as inpatients at a single center, most of the follow-up data were available. Second, a strong selection bias can be suspected: indeed, we included patients based on the endoscopy reports: the total number of surgical procedures, the number of patients who were successfully managed conservatively, with interventional radiology, or with surgical revision is unknown. Furthermore, the choice of the endoscopic treatment modality can be determined by the size and the severity of the leak. However, we found both patients groups (ID and self-expandable metallic stent) to be comparable in terms of patient and leak characteristics, except for a higher proportion of esophageal leaks in the ID group, translating into a significantly longer distance of the fistula from dental arches. Third, the endoscopic management is not consensual. While many centers have started placing double pigtail stents, some centers still use esophageal stents as a first line endoscopic therapy. Similarly, the type of nutritional support varied amongst the centers. While some centers favored artificial nutrition during the whole treatment, oral feeding was allowed at day 1 after stent placement in other centers. Finally, the surgical techniques were not standardized among the four centers.

Conclusion

Endoscopic therapy for post-operative anastomotic leak after esophageal or gastric resection is

highly effective and may avoid surgical revision. Endoscopic ID using double pigtail stents is a novel and promising treatment modality, providing better treatment outcomes than esophageal metal stents. Our data support the use of this technique as a primary endoscopic treatment modality, whenever the size of the anastomotic defect allows it. Further studies are needed to clarify the respective role of each endoscopic treatment modality.

Conflict of interest statement

The authors declare that there is no conflict of interest.

Funding

This research received no specific grant from any funding agency in the public, commercial, or not-for-profit sectors.

ORCID iDs

Rachel Hallit  <https://orcid.org/0000-0001-8866-6234>

Marine Camus  <https://orcid.org/0000-0003-2566-3866>

Supplemental material

Video 1 supplemental material for this article is available online.

References

1. Pimentel-Nunes P, Dinis-Ribeiro M, Ponchon T, *et al.* Endoscopic submucosal dissection: European Society of Gastrointestinal Endoscopy (ESGE) guideline. *Endoscopy* 2015; 47: 829–854.
2. Semenkovich TR, Subramanian M, Yan Y, *et al.* Adjuvant therapy for node-positive esophageal cancer after induction and surgery: a multisite study. *Ann Thorac Surg* 2019; 108: 828–836.
3. Wu PC and Posner MC. The role of surgery in the management of oesophageal cancer. *Lancet Oncol* 2003; 4: 481–488.
4. Degisors S, Pasquer A, Renaud F, *et al.*; FREGAT Working Group. Are thoracotomy and/or intrathoracic anastomosis still predictors of postoperative mortality after esophageal cancer surgery?: a nationwide study. *Ann Surg* 2017; 266: 854–862.
5. McMillan RR, Berger A, Sima CS, *et al.* Thirty-day mortality underestimates the risk of early death

- after major resections for thoracic malignancies. *Ann Thorac Surg* 2014; 98: 1769–1775.
6. Kuppusamy MK, Low DE and International Esodata Study Group (IESG). Evaluation of international contemporary operative outcomes and management trends associated with esophagectomy: a 4-year study of >6000 patients using ECCG definitions and the online esodata database. *Ann Surg*. Epub ahead of print 14 October 2020. DOI: 10.1097/SLA.0000000000004309.
 7. Baiocchi GL, Giacomuzzi S, Reim D, *et al.* Incidence and grading of complications after gastrectomy for cancer using the GASTRODATA registry: a European retrospective observational study. *Ann Surg* 2020; 272: 807–813.
 8. Paul S and Bueno R. Section VI: complications following esophagectomy: early detection, treatment, and prevention. *Semin Thorac Cardiovasc Surg* 2003; 15: 210–215.
 9. Urschel JD. Esophagogastrostomy anastomotic leaks complicating esophagectomy: a review. *Am J Surg* 1995; 169: 634–640.
 10. Gonzalez JM, Servajean C, Aider B, *et al.* Efficacy of the endoscopic management of postoperative fistulas of leakages after esophageal surgery for cancer: a retrospective series. *Surg Endosc* 2016; 30: 4895–4903.
 11. Donatelli G, Ferretti S, Vergeau BM, *et al.* Endoscopic Internal Drainage with Enteral Nutrition (EDEN) for treatment of leaks following sleeve gastrectomy. *Obes Surg* 2014; 24: 1400–1407.
 12. Dammaro C, Lainas P, Dumont JL, *et al.* Endoscopic internal drainage coupled to prompt external drainage mobilization is an effective approach for the treatment of complicated cases of sleeve gastrectomy. *Obes Surg* 2019; 29: 2929–2935.
 13. Donatelli G, Cereatti F, Dhumane P, *et al.* Closure of gastrointestinal defects with Ovesco clip: long-term results and clinical implications. *Therap Adv Gastroenterol* 2016; 9: 713–721.
 14. Schweigert M, Solymosi N, Dubecz A, *et al.* Endoscopic stent insertion for anastomotic leakage following oesophagectomy. *Ann R Coll Surg Engl* 2013; 95: 43–47.
 15. Wang S, Liu J, Wang S, *et al.* Adverse effects of anastomotic leakage on local recurrence and survival after curative anterior resection for rectal cancer: a systematic review and meta-analysis. *World J Surg* 2017; 41: 277–284.
 16. Schweigert M, Solymosi N, Dubecz A, *et al.* Emergency oesophagectomy for oesophageal perforation after chemoradiotherapy for oesophageal cancer. *Ann R Coll Surg Engl* 2015; 97: 140–145.
 17. Hünnerbein M, Stroszczyński C, Moesta KT, *et al.* Treatment of thoracic anastomotic leaks after esophagectomy with self-expanding plastic stents. *Ann Surg* 2004; 240: 801–807.
 18. Langer FB, Wenzl E, Prager G, *et al.* Management of postoperative esophageal leaks with the polyflex selfexpanding covered plastic stent. *Ann Thorac Surg* 2005; 79: 398–403.
 19. Saul A, Luna MAR, Chan C, *et al.* EUS-guided drainage of pancreatic pseudocysts offers similar success and complications compared to surgical treatment but with a lower cost. *Surg Endosc* 2016; 30: 1459–1465.
 20. Sportes A, Aireini G, Kamel R, *et al.* Efficacy of endoscopic treatment of post-sleeve gastrectomy fistulas according to the radiological type. *Obes Surg* 2019; 29: 2217–2224.
 21. Donatelli G, Dumont JL, Cereatti F, *et al.* Endoscopic internal drainage as first-line treatment for fistula following gastrointestinal surgery: a case series. *Endosc Int Open* 2016; 4: E647–E651.
 22. Kuehn F, Loske G, Schiffmann L, *et al.* Endoscopic vacuum therapy for various defects of the upper gastrointestinal tract. *Surg Endosc* 2017; 31: 3449–3458.
 23. Hwang JJ, Jeong YS, Park YS, *et al.* Comparison of endoscopic vacuum therapy and endoscopic stent implantation with self-expandable metal stent in treating postsurgical gastroesophageal leakage. *Medicine (Baltimore)* 2016; 95: e3416.
 24. Schniewind B, Schafmayer C, Voehrs G, *et al.* Endoscopic endoluminal vacuum therapy is superior to other regimens in managing anastomotic leakage after esophagectomy: a comparative retrospective study. *Surg Endosc* 2013; 27: 3883–3890.
 25. Brangewitz M, Voigtländer T, Helfritz FA, *et al.* Endoscopic closure of esophageal intrathoracic leaks: stent versus endoscopic vacuum-assisted closure, a retrospective analysis. *Endoscopy* 2013; 45: 433–438.
 26. Mennigen R, Harting C, Lindner K, *et al.* Comparison of endoscopic vacuum therapy versus stent for anastomotic leak after esophagectomy. *J Gastrointest Surg* 2015; 19: 1229–1235.

27. Jung CFM, Hallit R, Müller-Dornieden A, *et al.* Endoscopic internal drainage and low negative-pressure endoscopic vacuum therapy for anastomotic leaks after oncologic upper gastrointestinal surgery. *Endoscopy*. Epub ahead of print 27 January 2021. DOI: 10.1055/a-1375-8151.
28. Huh CW, Kim JS, Choi HH, *et al.* Treatment of benign perforations and leaks of the esophagus: factors associated with success after stent placement. *Surg Endosc* 2018; 32: 3646–3651.
29. Blewett CJ, Miller JD, Young JE, *et al.* Anastomotic leaks after esophagectomy for esophageal cancer: a comparison of thoracic and cervical anastomoses. *Ann Thorac Cardiovasc Surg* 2001; 7: 75–78.
30. Doty JR, Salazar JD, Forastiere AA, *et al.* Postesophagectomy morbidity, mortality, and length of hospital stay after preoperative chemoradiation therapy. *Ann Thorac Surg* 2002; 74: 227–231.
31. Messenger M, Pasquer A, Duhamel A, *et al.* Laparoscopic gastric mobilization reduces postoperative mortality after esophageal cancer surgery. *Ann Surg* 2015; 262: 817–823.
32. Dai YY, Gretschel S, Dudeck O, *et al.* Treatment of oesophageal anastomotic leaks by temporary stenting with self-expanding plastic stents. *Br J Surg* 2009; 96: 887–891.
33. Markar SR, Mackenzie H, Lagergren P, *et al.* Surgical proficiency gain and survival after esophagectomy for cancer. *J Clin Oncol* 2016; 34: 1528–1536.
34. D'Journo XB, Michelet P, Dahan L, *et al.* Indications and outcome of salvage surgery for oesophageal cancer. *Eur J Cardiothorac Surg* 2008; 33: 1117–1123.
35. Aurello P, Berardi G, Moschetta G, *et al.* Recurrence following anastomotic leakage after surgery for carcinoma of the distal esophagus and gastroesophageal junction: a systematic review. *Anticancer Res* 2019; 39: 1651–1660.
36. Alanezi K and Urschel JD. Mortality secondary to esophageal anastomotic leak. *Ann Thorac Cardiovasc Surg* 2004; 10: 71–75.
37. Liu XB, Xing WQ and Sun HB. Early oral feeding following esophagectomy. *J Thorac Dis* 2019; 11(Suppl. 5): S824–S830.