



HAL
open science

Modified Mason–Allen Knot for Arthroscopic Complex Bankart Lesion Repair in Recurrent Anterior Shoulder Instability

Victor Housset, Geoffroy Nourissat

► **To cite this version:**

Victor Housset, Geoffroy Nourissat. Modified Mason–Allen Knot for Arthroscopic Complex Bankart Lesion Repair in Recurrent Anterior Shoulder Instability. *Arthroscopy Techniques*, 2021, 10 (8), pp.e1909 - e1914. 10.1016/j.eats.2021.04.018 . hal-03345378

HAL Id: hal-03345378

<https://hal.sorbonne-universite.fr/hal-03345378v1>

Submitted on 15 Sep 2021

HAL is a multi-disciplinary open access archive for the deposit and dissemination of scientific research documents, whether they are published or not. The documents may come from teaching and research institutions in France or abroad, or from public or private research centers.

L'archive ouverte pluridisciplinaire **HAL**, est destinée au dépôt et à la diffusion de documents scientifiques de niveau recherche, publiés ou non, émanant des établissements d'enseignement et de recherche français ou étrangers, des laboratoires publics ou privés.

Modified Mason–Allen Knot for Arthroscopic Complex Bankart Lesion Repair in Recurrent Anterior Shoulder Instability

Victor Housset, M.D., and Geoffroy Nourissat, M.D., Ph.D.



Abstract: The arthroscopic Bankart repair is a safe and reliable procedure for the treatment of recurrent shoulder instability for the well-indicated patient. Many repair techniques have been described to restore both labral height and width and recreate a dynamic concavity–compression effect. The modified Mason–Allen knot was first described for rotator cuff tear repair and consists of a horizontal mattress knot with a simple vertical stitch on the same anchor. The purpose of this work is to present the use of the modified Mason–Allen knot for the repair of the capsular labral complex during an arthroscopic Bankart procedure.

Recurrent anterior dislocation of the shoulder is a frequent condition among young and active patients and can be caused by many different anatomical lesions, from the classical anterior Bankart tear to more complex capsular–labral tear, which may include posterior and anterior lesions. In the absence of a bony defect, and if the patient does not present any specific risk of postoperative failure, a Bankart repair can be proposed, which has a failure rate of 4% to 35%.¹

The suture anchor is currently the gold standard when considering the surgical treatment of capsular–labral lesions. To ensure the best result for the arthroscopic Bankart repair the capsular labral tissue quality must be assessed as the anterior glenoid neck bone loss. The success of this surgery hinges on the restoration of a satisfying capsule labral anatomy to adequately restore the efficiency of the inferior glenohumeral ligament.^{2–5}

The modified Mason–Allen technique was first described by Schneeberger et al.⁶ for rotator cuff repair, with good clinical outcomes and biomechanical

results.^{7,8} In this indication, it is also known as BRUMA (Bankart lesion Repair Using a modified Mason–Allen stitch) and is defined as the combination of a simple stitch positioned in the middle of a horizontal mattress suture which is supposed to constitute a blockage in order to reduce the risk of cutting through capsular–labral tissue. It is supposed to improve the tissue-holding properties.⁹ A double-loaded suture anchor is needed, and the horizontal mattress suture needs to be performed before the simple vertical stitch.⁹ We already have reported the good long-term outcome at 10 years' follow-up in a previous publication.¹⁰

The rationale of the modified Mason–Allen knot is that it's supposed to prevent failure of the suture by restoring the capsular–labral tension, on the ligament and on the labrum, better than with the use of simple sutures.⁹ The main advantages and disadvantages of both the modified Mason–Allen knot and simple vertical stitch are given in Table 1. The objective of this Technical Note is to show how we use the modified Mason–Allen knot technique during the treatment of an anterior and posterior complex Bankart lesion.

Surgical Technique

Clinical Diagnosis and Imaging

The clinical assessment of the recurrent anterior shoulder instability must be performed with a standard clinical evaluation, including the administration of an anterior apprehension test, a relocation test, hyperlaxity, and associated posterior or multidirectional shoulder instability. Preoperative staging includes

From Clinique Maussins-Nollet, Sorbonne Université, Paris, France.
The authors report that they have no conflicts of interest in the authorship and publication of this article. Full ICMJE author disclosure forms are available for this article online, as [supplementary material](#).

Received February 18, 2021; accepted April 3, 2021.

Address correspondence to Victor Housset, M.D., Clinique Maussins-Nollet, Sorbonne Université, Paris, France. E-mail: victor.housset@hotmail.fr

© 2021 by the Arthroscopy Association of North America. Published by Elsevier. This is an open access article under the CC BY-NC-ND license (<http://creativecommons.org/licenses/by-nc-nd/4.0/>).

2212-6287/21288

<https://doi.org/10.1016/j.eats.2021.04.018>

Table 1. Advantages of the Modified Mason–Allen Stitch Compared With the Simple Stitch

Simple Vertical Stitch	Modified Mason–Allen Stitch
<p>Advantages:</p> <ul style="list-style-type: none"> • Easy to use • Fast procedure • Possibility to perform 2 simple vertical stitches with a double-loaded anchor. • Reliable technique • Adapted for posterior capsulolabral lesion <p>Disadvantages:</p> <ul style="list-style-type: none"> • Risk of cutting through in case of attenuated capsulolabral tissue. • Lesser restoration of the labral height. • No independent fixation of the inferior glenohumeral ligament 	<p>Advantages:</p> <ul style="list-style-type: none"> • Decrease in the risk of cutting through fragile tissue • Better restoration of labral height • Better grip strength and tissue-holding power. <ul style="list-style-type: none"> • Independent fixation of the inferior glenohumeral ligament • Biomechanical strength superior to the simple vertical stitch. • An increase in the contact force between the capsular–labral complex and the glenoid rim bone. <p>Disadvantages:</p> <ul style="list-style-type: none"> • Technically more challenging • Difficulty to proceed for posterior Bankart lesion. • May not be adapted for small capsular–labral lesions • Longer procedure

standard radiographs of the shoulder associated with an arthro-computed tomography scan to identify the Bankart lesion and to ensure the absence of bony lesion, which may contraindicate the arthroscopic repair of the capsulolabral complex.

Patient Positioning

The patient undergoes an ultrasound-guided interscalene brachial plexus block combined with general anesthesia with a laryngeal mask airway. The surgical procure is performed with the patient placed in a supine position with the medial edge of the scapula stabilized on the table. A SPIDER 2 Limb positioner device (Smith & Nephew, Andover, MA) is used to allow the mobilization the operated upper limb, which is included entirely in the surgical field.

Surgical Procedure (With Video Illustration)

The surgical procedure is shown in [Video 1](#). The usual posterior arthroscopic portal in the soft point is made to explore the glenohumeral joint with a 30° scope, associated with a classical anterior instrumental portal in the rotator interval. During exploration, the lesions

of both anterior and posterior capsulolabral complex must be identified ([Fig 1](#)). It is mandatory to make with the rasp a complete release of the labrum both anteriorly and posteriorly by pulling the capsular–labral tissue. After the entire lesion assessment, we use a motorized shaver to remove all the soft tissues from the anterior and medial walls of the glenoid rim, and a rasp is used to perform abrasion of the bone to optimize the healing potency of the ligament. The muscular fibers of the subscapularis are visualized to confirm the good release of soft tissues. An all-suture double loaded anchor (SUTUREFIX ULTRA, 1.7 mm; Smith & Nephew) is placed at the 5-o’clock position. To start the modified Mason–Allen suture, a FIRSTPASS ST (Smith & Nephew) suture passer is used to perform the proximal and the distal passing suture of the mattress suture. A space of approximately 5 mm must be maintained between the 2 suture passages of the mattress knot. The same device is then used to pass the thread for the simple vertical stitch over the mattress knot at its center between the 2 anteriorly passed threads ([Fig 2](#)). The horizontal mattress knot and the classical simple sliding vertical stitch can then be tied. A second modified

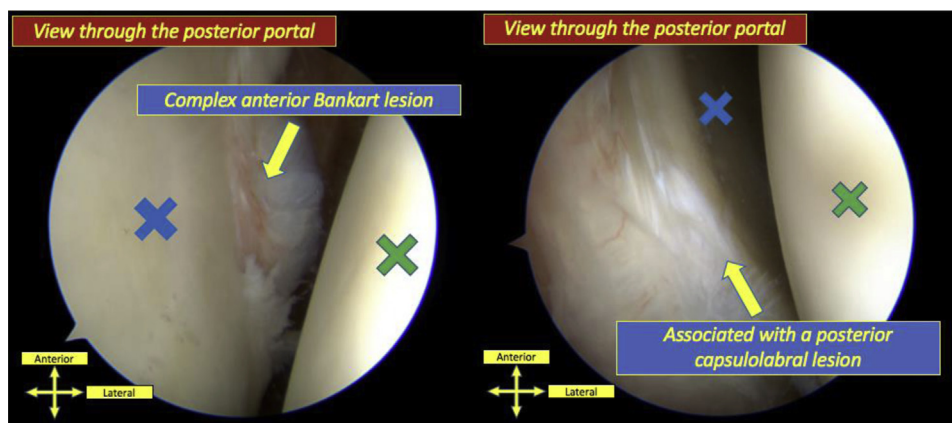


Fig 1. Complex capsular and labral lesions visualized through a classical posterior portal. On the left, an anterior lesion of the labrum is shown, and on the right a posterior lesion of the labrum is shown. The green cross indicates the humeral head, and the blue cross indicates the glenoid cavity. The patient is positioned in the supine position, and this orientation is shown.

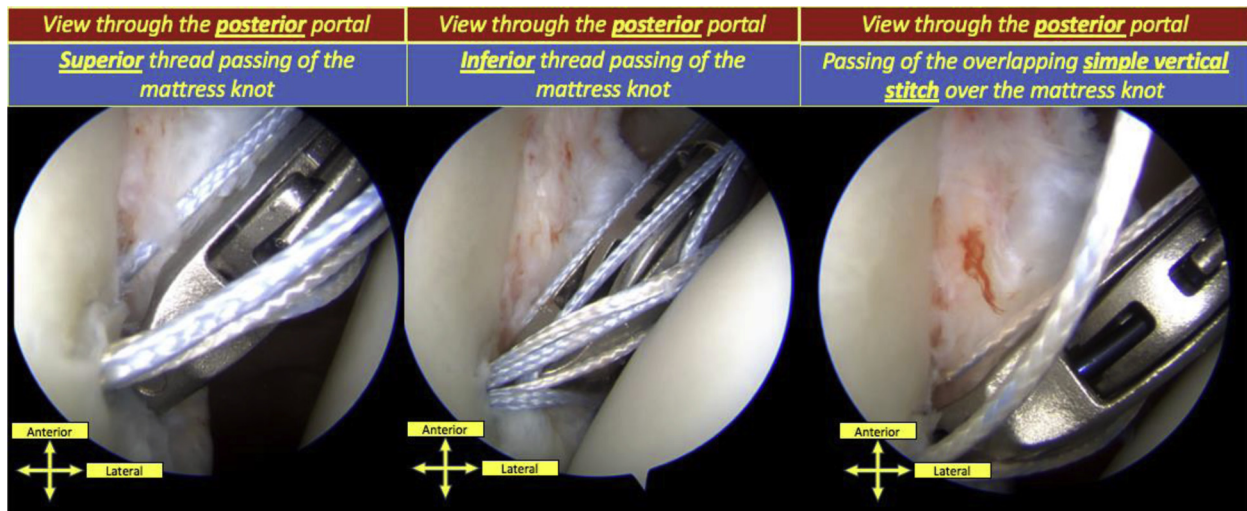


Fig 2. Arthroscopic views of the modified Mason–Allen knot technique for Bankart repair using a specific suture passer device. On the left and in the middle panels, realization of the both superior and inferior passing of the horizontal mattress knot is shown. An approximative length of 5 mm must be maintain between the 2 threads. On the right (white thread), passing of the suture of the vertical simple stitch in the middle of the 2 previous passed threads is shown. We recommend tying the horizontal mattress knot first and then the simple vertical stitch. The patient is positioned in the supine position, and this orientation is shown.

Mason–Allen stitch is always performed more proximally at the 3- or 4-o’clock position following the same procedure at approximately 5 mm superiorly to the previous passage. A classical vertical stitch can be performed on a third suture anchor to conclude the whole suture if there is a proximal extend of the anterior Bankart lesion on the glenoid rim (Fig 3). We recommend the use of a canula in the anterior portal to prevent the entanglement of the suture in the soft tissues.

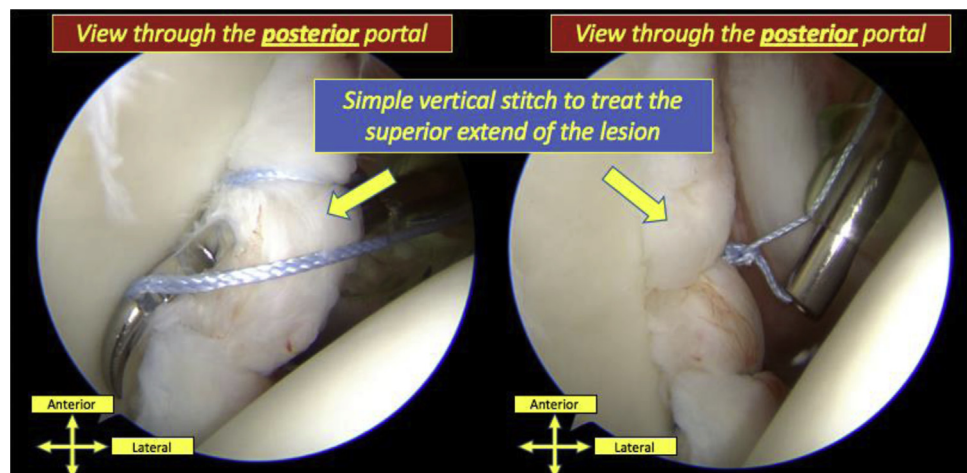
Then the posterior part of the glenoid rim is assessed by switching the scope through the anterior portal. In almost 75% of cases, a posterior Bankart lesion is treated with a Mason–Allen suture. In most cases, a

Sixer hook (DePuy-Mitek, Raynham, MA) must be used because automatic suture retriever is too large to be used in this narrow space. When necessary, classical simple vertical stitches can be used if the posterior Bankart lesion is extend superiorly. At the end of the procedure, good restoration of height and width of the capsulolabral complex can be controlled (Fig 4). The pearls and pitfalls for a stepwise approach to the surgical technique of the modified Mason–Allen knot for a complex labral repair are given in Table 2.

Rehabilitation

The patient is immobilized with a shoulder immobilizer for 3 weeks. Then, the passive physiotherapy

Fig 3. For an extended anterior capsulolabral anterior Bankart lesion, the adjunction of a simple vertical stitch may be needed in adjunction with the modified Mason–Allen knot when there is no space left for the use of an automatic suture retriever. After positioning a single- or double-loaded all-suture anchor in the glenoid bone at the level of the labral lesion, a Sixter hook (DePuy-Mitek) is use to pass the thread (on the left) and can then be classically tied (on the right). The patient is positioned in the supine position, and this orientation is shown.



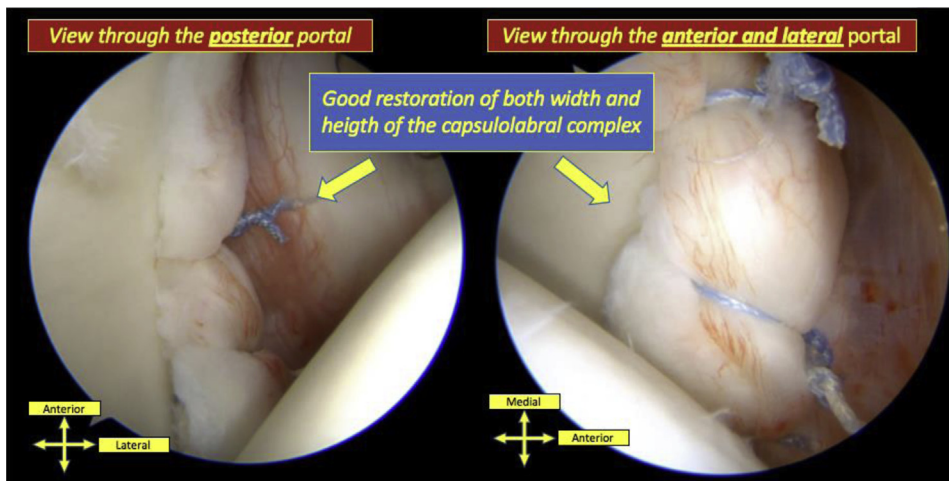


Fig 4. Visualization of the result of 2 modified Mason–Allen knots for the anterior Bankart repair associated with a superior simple vertical stitch for the treatment of a complex anterior Bankart lesion (with the arthroscope positioned in the posterior portal on the left and in the anterior and lateral portal on the right). It is possible to visualize the bump effect following this type of repair with the good restoration of both width and height of the capsulolabral complex. The patient is positioned in the supine position, and this orientation is shown.

without external rotation is follow for 3 weeks. At 6 weeks, active mobilization is permitted and the immobilizer is removed. Patients are monitored with clinical follow-up after 3 weeks and 3, 6, and 12 months.

Discussion

It has been demonstrated that one of the main objectives of the Bankart repair procedure is to restore the labral height, which is in the case of a modified Mason–Allen technique mainly dependent on the horizontal mattress suture.³ It increases the glenohumeral joint stability and achieves better labral anatomy restoration. To stabilize the glenohumeral joint, the restoration of the labral height is important to create a new concavity. Previous anatomical studies have shown that the Mason–Allen suture is associated with better restoration of the labral height, restoring the concavity–compression functions of the labrum, and leading to increased functional outcome and glenohumeral stability.^{3,11,12} In a cadaveric study, Metcalf et al.¹³ measured glenohumeral range of motion, glenolabral depth, and resistance to humeral head displacement

before and after a capsulolabral augmentation and demonstrated an increase in the stability of the humeral head within the glenolabral fossa by local capsular augmentation. They also concluded that the capsulolabral augmentation limits glenohumeral motion due to a simultaneous reduction in capsular laxity.

The prevention of the cutting through the capsular–labral tissue and the improvement of the tissue-holding power was first described by Castagna et al.⁹ They described the MIBA stitch using a double-loaded suture and composed of a horizontal mattress stitch in a “south-to-north” direction in association with an overlapping single vertical stitch passing through the capsular–labral complex to improve the contact force applied on these tissues over the glenoid bone. They concluded that in their clinical experience this procedure led to a good capsular–labral shift with a good grip of this stitch. The surgical time was not increased according to the authors.

The superiority of the horizontal mattress suture over the simple stitch has been demonstrated in previous studies both on the increased stability to the

Table 2. Pearls and Pitfalls for a Stepwise Approach of the Modified Mason–Allen Knot for the Arthroscopic Treatment of Complex Bankart Lesion

Pearls	Pitfalls
<ul style="list-style-type: none"> • Use of an all-suture double loaded suture anchor to preserve the glenoid bone stock • Passage of 3 suture strands with 2 threads for the horizontal mattress knot and 1 for the vertical simple knot • A space of 5 mm between the 2 threads must be maintained for the horizontal mattress knot • If 2 Mason–Allen knots are required, a space of 5 mm must be maintained between the 2 knots • The suture thread must be passed through a similar portion of the capsulolabral tissue as for the simple vertical stitch. • The use of a specific suture retriever may help but is not absolutely necessary 	<ul style="list-style-type: none"> • Entanglement of the treads and loosening of the treads in the soft tissue without the use of a canula • Risk of entanglement of the treads if caution is not taken while tying the knots • Is not adapted for the treatment of posterior capsulolabral lesion due to the lack of space • May not be adapted in case of associated glenoid rim bony lesion

glenohumeral repair by recreating glenolabral concavity and in restoring the labral anatomy and height. Thus, it seems logical to believe that the modified Mason–Allen technique would have an even better mechanical superiority. The second stitch is used to fix the inferior glenohumeral ligament independently of the labrum. It can be useful when the labrum is torn or of bad quality.

In a recent prospective randomized trial study comparing 45 patients allocated to simple vertical stitch with 41 patients allocated to the modified Mason–Allen stitch for the treatment of Bankart lesions, Park et al.¹⁴ didn't succeed in proving the superiority of one of the sutures compared with the other, both on clinical and the radiologic outcomes at least 2 years postoperatively.

Lai et al.¹⁵ also compared retrospectively 65 patients who underwent a hybrid suture to create a Mason–Allen configuration with 38 patients who have had a simple vertical suture technique for an anterior labral repair. At 2 years' follow-up, the both techniques showed similar results concerning the recurrence rate and a significant improvement of the postoperative clinical scores compared with the preoperative ones. The early clinical scores at 3 months' postoperative were thus significantly improved in the group of patients treated with a Mason–Allen suture technique. We reported less than 5% recurrence after such Bankart procedure, with or without Hill–Sachs remplissage, at minimum 10 years' follow-up using the MIBA stitch.¹⁰

Siripipattanamongkol et al.¹⁶ in a retrospective cohort study compared a group of 50 patients who underwent modified Mason–Allen Stitch for arthroscopic Bankart repair with a group of 30 patients who underwent a simple stitch arthroscopic Bankart repair and found in both groups excellent patient satisfaction and shoulder stability restoration at a minimum 2-year follow-up. The modified Mason–Allen stitch was, however, associated with better functional outcomes at the final follow-up, with a significantly improved Walch–Duplay score (87.2 vs 82.0; $P = .035$) and Rowe score (respectively 86.8 vs 76.3; $P = .001$) and a nonsignificant trend for a lower failure rate with, respectively, 6% and 10% ($P = .511$).

The use of a specific suture passer may be a limit of the presented surgical procedure due to it being the most expensive. The use of this specific device may help the surgeon; nevertheless, we do not believe that its use is mandatory.

Conclusions

Long-term clinical studies demonstrate the good clinical outcomes of patients operated with a Mason–Allen labral repair. It provides double independent fixation of the labrum and of the inferior glenohumeral ligament to better restore labral height and

width. It's supposed to improve the contact force applied on repaired capsulolabral tissue over the glenoid bone. It has shown to be a safe and reproducible procedure to treat recurrent anterior instability in both classical isolated anterior Bankart lesions and in more complex anterior and posterior capsulolabral lesions.

References

1. Sheehan AJ, De Beer JF, Di Giacomo G, Itoi E, Burkhart SS. Shoulder instability: State of the art. *J ISAKOS* 2016;1:347.
2. Bahk MS, Karzel RP, Snyder SJ. Arthroscopic posterior stabilization and anterior capsular plication for recurrent posterior glenohumeral instability. *Arthroscopy* 2010;26:1172-1180.
3. Kim JY, Chung SW, Kwak JY. Morphological characteristics of the repaired labrum according to glenoid location and its clinical relevance after arthroscopic Bankart repair: Postoperative evaluation with computed tomography arthrography. *Am J Sports Med* 2014;42:1304-1314.
4. Park JY, Lee SJ, Lhee SH, Oh JH. Change in labrum height after arthroscopic Bankart repair: Correlation with preoperative tissue quality and clinical outcome. *J Shoulder Elbow Surg* 2012;21:1712-1720.
5. Wiesel BB, Gartsman GM, Press CM, et al. What went wrong and what was done about it: Pitfalls in the treatment of common shoulder surgery. *J Bone Joint Surg Am* 2013;95:2061-2070.
6. Schneeberger AG, Beck M, Gerber C. In-vitro stability of rotator cuff repair techniques. *Orthopade* 1995;24:268-274 [in German].
7. Hawi N, Dratzidis A, Kraemer M, et al. Biomechanical evaluation of the simple cinch stitch for arthroscopic rotator cuff repair. *Clin Bio-mech (Bristol, Avon)* 2016;36:21-25.
8. Porto Fde M, Alves MW, de Andrade AL. Evaluation of patients undergoing rotator cuff suture with the modified Mason-Allen technique. *Acta Ortop Bras* 2013;21:167-169.
9. Castagna A, Conti M, Mouhsine E, Delle Rose G, Massazza G, Garbofalo R. A new technique to improve tissue grip and contact force in arthroscopic capsulolabral repair: The MIBA stitch. *Knee Surg Sports Traumatol Arthrosc* 2008;16:415-419.
10. Bastard C, Herisson O, Gaillard J, Nourissat G. Impact of remplissage on global shoulder outcome: A long-term comparative study. *Arthroscopy* 2019;35:1362-1367.
11. Boddula MR, Adamson GJ, Gupta A, McGarry MH, Lee TQ. Restoration of labral anatomy and biomechanics after superior labral anteriorposterior repair: Comparison of mattress versus simple technique. *Am J Sports Med* 2012;40:875-881.
12. Lazarus MD, Sidles JA, Harryman DT 2nd, Matsen FA 3rd. Effect of a chondral-labral defect on glenoid concavity and glenohumeral stability: A cadaveric model. *J Bone Joint Surg Am* 1996;78:94-102.
13. Metcalf MH, Pon JD, Harryman DT 2nd, Loutzenheiser T, Sidles JA. Capsulolabral augmentation increases glenohumeral stability in the cadaver shoulder. *J Shoulder Elbow Surg* 2001;10:532-538.

14. Park JY, Chung SW, Lee JS, Oh KS, Lee JH. Comparison of clinical and radiographic outcomes of vertical simple stitch versus modified Mason–Allen stitch in arthroscopic Bankart repairs: A prospective randomized controlled study. *Am J Sports Med* 2019;47:398-407.
15. Lai MC, Ang FHB, Lee KH, Chang CCP, Lie TTD. Hybrid suture technique vs simple suture technique for antero-inferior labral tears: Two years' clinical outcomes. *Asia Pac J Sports Med Arthrosc Rehabil Technol* 2019;18:6-10.
16. Siripipattanamongkol P, Wongtriratanachai P, Nimkingratana P, Phornphutkul C. Arthroscopic Bankart repair: A matched cohort comparison of the modified Mason Allen method and the simple stitch method. *Asia Pac J Sports Med Arthrosc Rehabil Technol* 2020;22:49-55.