



**HAL**  
open science

## **AA amyloidosis complicating monoclonal gammopathies, an unusual feature validating the concept of "monoclonal gammopathy of inflammatory significance"?**

Alexandre Terré, Magali Colombat, Alexandre Cez, Claire Martin, Carine Diet, Sabine Brechignac, Silvia Oghina, Diane Bodez, Stanislas Faguer, Léa Savey, et al.

### **► To cite this version:**

Alexandre Terré, Magali Colombat, Alexandre Cez, Claire Martin, Carine Diet, et al.. AA amyloidosis complicating monoclonal gammopathies, an unusual feature validating the concept of "monoclonal gammopathy of inflammatory significance"?. *International Journal of Clinical Practice*, 2021, 10.1111/ijcp.14817 . hal-03359330

**HAL Id: hal-03359330**

**<https://hal.sorbonne-universite.fr/hal-03359330v1>**

Submitted on 30 Sep 2021

**HAL** is a multi-disciplinary open access archive for the deposit and dissemination of scientific research documents, whether they are published or not. The documents may come from teaching and research institutions in France or abroad, or from public or private research centers.

L'archive ouverte pluridisciplinaire **HAL**, est destinée au dépôt et à la diffusion de documents scientifiques de niveau recherche, publiés ou non, émanant des établissements d'enseignement et de recherche français ou étrangers, des laboratoires publics ou privés.

**Title:** AA amyloidosis complicating monoclonal gammopathies, an unusual feature validating the concept of “monoclonal gammopathy of inflammatory significance”?

**Authors:** Alexandre Terré<sup>1,13</sup> <https://orcid.org/0000-0002-8295-9068>, Magali Colombat<sup>2</sup>, Alexandre Cez<sup>3</sup>, Claire Martin<sup>4</sup>, Carine Diet<sup>5</sup>, Sabine Brechignac<sup>6</sup>, Silvia Oghina<sup>7</sup>, Diane Bodez<sup>8</sup>, Stanislas Faguer<sup>9</sup>, Léa Savey<sup>1</sup>, Joris Galland<sup>1</sup>, Jean-Jacques Boffa<sup>5</sup>, Gilles Grateau<sup>1,10</sup>, Arnaud Jaccard<sup>11</sup>, David Buob<sup>12</sup>, Sophie Georgin-Lavialle<sup>1,10</sup>.

**Affiliations:**

1 Sorbonne University, AP-HP, Tenon hospital, Department of Internal Medicine, Centre de référence des maladies auto-inflammatoires et des amyloses d'origine inflammatoire (CEREMAIA), GRC -28, Paris, France.

2 CHU Toulouse, Department of Pathology, Toulouse, France

3 Sorbonne University, AP-HP, Tenon Hospital, Department of Nephrology, Paris, France.

4 La Rochelle Hospital, Rheumatology Department, La Rochelle, France

5 Henri Mondor Hospital, Nephrology Department, Creteil, France

6 Avicenne Hospital, Haematology Department, Bobigny, France

7 Henri Mondor Hospital, Cardiology department, National reference centre of cardiac amyloidosis, Creteil, France

8 Centre Cardiologique du Nord, Cardiology Department, Saint-Denis, France

9 Département de Néphrologie et Transplantation d'Organes, CHU de Toulouse, Toulouse, France

10 Inserm UMRS\_933, et laboratoire de génétique, Trousseau hospital, AP-HP, Faculté de médecine - Sorbonne University, Paris, France.

11 CHU Dupuytren, Haematology Department, National Reference Center for AL Amyloidosis Limoges, France

12 Sorbonne University, AP-HP, Tenon Hospital, Department of Pathology, Paris, France

13 Institut Imagine, INSERM U1163, CNRS ERL 8254, Université Paris Descartes, Sorbonne Paris-Cité, Laboratoire d'Excellence GR-Ex, Paris, France.

**Running head:** AA amyloidosis and monoclonal gammopathies.

**Corresponding author:**

Pr Sophie Georgin-Lavialle

Phone number: 33 (1) 56 01 60 77

Address: Department of Internal Medicine, Tenon Hospital, 20, rue de la Chine, 75020 Paris, France

Sorbonne University Assistance Publique-Hôpitaux de Paris.

Centre de référence des maladies auto-inflammatoires et des amyloses inflammatoires (CEREMAIA).

E-Mail: [sophie.georgin-lavialle@aphp.fr](mailto:sophie.georgin-lavialle@aphp.fr)

**Key words:** AA amyloidosis; AL amyloidosis; Mass-spectrometry, Monoclonal gammopathies; paraproteinemia

**Key messages:**

1. What is the new aspect of your work?

In case of amyloidosis, a monoclonal gammopathy is not synonymous of AL amyloidosis.

2. What is the central finding of your work?

AA amyloidosis can complicate monoclonal gammopathies, and mostly lympho-plasmocytic disorders.

3. What is (or could be) the specific clinical relevance of your work? In case of amyloidosis, complicating a monoclonal gammopathy, a careful identification of the amyloid deposits is required. The treatment of AA amyloidosis complicating monoclonal gammopathy can either target the clonal proliferation or the chronic inflammation

**Declarations:**

*Data availability:* The data that support the findings of this study are available from the corresponding author upon reasonable request.

*Funding:* This study had no funding.

*Declaration of interest:* The authors declare they have no compelling interest.

*Ethics:* This study was conducted in compliance with good clinical practices and the Declaration of Helsinki principles. In accordance with French public health laws, written consent was waived. The study was registered at the Commission Nationale de l'Information et des Libertés (number 2216956v0), as requested by French public health laws.

**Word count:**

Abstract: 179 words

Manuscript: words

Number of tables: 1

Number of figures: 2

Supplementary material: 0

## **Abstract**

### Introduction:

AL amyloidosis is caused by the proliferation of an immunoglobulin-secreting B cell clone. AA amyloidosis is a rare complication of chronic inflammation. However, some patients present with diseases combining monoclonal immunoglobulin production and chronic inflammation. The aim of this work was to describe cases of AA amyloidosis associated with monoclonal gammopathies.

### Patients and methods:

We reviewed all patients reported in French national amyloid centers presenting with AA amyloidosis and monoclonal gammopathy and performed a literature review. The quality of AA amyloidosis diagnosis and the causal relationship with monoclonal gammopathy were assessed.

### Results:

In total, 4 patients from our centers and 8 from the literature fulfilled the inclusion criteria. The hematological disorders presenting with monoclonal gammopathy were as follows: Waldenström macroglobulinemia (n=8), Schnitzler syndrome (n=2), multiple myeloma (n=1), and monoclonal gammopathy of undetermined significance (n=1). Treatment strategies varied among the cases, with treatment of the hematological disorder in 4 and anti-inflammatory treatment in 2.

### Conclusion:

Monoclonal gammopathies might be a rare and poorly known cause of AA amyloidosis. Such monoclonal gammopathies could be named “monoclonal gammopathies of inflammatory significance”.

## **Introduction:**

Light-chain amyloidosis (AL amyloidosis) and AA amyloidosis are systemic acquired amyloses with different presentations and evolutions. AL amyloidosis is the consequence of the secretion of monoclonal immunoglobulin light chain with chemical properties allowing deposition in tissues; it is associated with the proliferation of a B cell clone (1). The protein fibrils in AA amyloidosis are derived from the serum amyloid A (SAA) protein, which is an acute-phase reactant. AA amyloidosis is a severe complication of chronic inflammatory diseases, such as inflammatory rheumatisms (2). Although monoclonal gammopathies (MG) were not reported to cause AA amyloidosis in large series (3), there are data suggesting a link between MG and AA amyloidosis. For instance, Schnitzler syndrome (SS) is now recognized as an auto-inflammatory disease associated with MG (4).

However, AA amyloidosis finding by pathological examination in a patient with MG is an unusual situation that requires careful evaluation. Thus, the aim of our study was to report and detail cases of clonal gammopathies presenting with AA amyloidosis and to perform a literature review to clarify this atypical situation.

## **Patients and methods:**

### *Reported cases:*

A retrospective review was performed of all cases of AA amyloidosis presenting with a history of MG before or at the time of AA amyloidosis diagnosis followed in the 3 main French reference centers for amyloidoses (cardiac, AL and AA). For all cases, AA Amyloidosis diagnosis was based on pathological examination, showing positive Congo red-stained deposits with green-yellow birefringence and immunohistochemical staining with anti-SAA antibodies, without significant staining by anti-kappa, anti-lambda, and anti-transthyretin antibodies.

For a case, mass spectrometry analysis was performed to confirm the diagnosis. Spectral count metrics were used to rank the proteins and peptides according to their relative abundance in the sample.

### *Literature review:*

A literature review in PubMed from 1946 to January 2020 was performed to collect additional cases. The search queries are described in Supplementary Material.

All articles reporting AA amyloidosis associated with an MG were screened. Articles not reporting AA amyloidosis were excluded. For articles reporting AA amyloidosis, we used the same inclusion the same criteria as the reported cases. Data were collected by two authors (AT and SGL).

*Causal relationship evaluation:*

We further evaluated the causal relationship between the underlying hematological disease and AA amyloidosis, which had to be diagnosed after or at the same time as the hematological disease. Cases were excluded if another cause for AA amyloidosis was present based on the list provided in a recent review of AA amyloidosis cause (5).

*Ethics:*

This study was conducted in compliance with good clinical practices and the Declaration of Helsinki principles. The study was registered at the Commission Nationale de l'Informatique et des Libertés (declaration number 2216956). In accordance with French public health law, written consent was waived.

**Results:**

A total of 111 references were screened, 94 articles did not mention AA amyloidosis and were excluded, leaving 17 articles and 19 cases of AA amyloidosis associated with an MG for the final description (6–22). Nine cases were excluded because the pathological data available did not meet the inclusion criteria (6–8,11–13,15,16) (immunohistochemistry not described (n=5), presence of another type of amyloidosis associated (n=3), immunohistochemistry not performed (n=1)). Two other cases were excluded because they described another likely cause for AA amyloidosis (ankylosing spondylarthritis (n=1), hepatitis C virus infection (n=1)) (9,10). In our cohort, 8 patients fulfilled the inclusion criteria of histologically proven AA amyloidosis concurrent with MG. Four of them were excluded due to another likely cause for AA amyloidosis (immune disease (n=2), recurrent infections (n=1), and vasculitis (n=1)). The flow chart of the study is presented in Figure 1.

The main characteristics of the 12 included patients are summarized in Table 1. There were 42% women (n=5); the median age at diagnosis of AA amyloidosis was 68.5 years (ranging from 44 to 79 years). Data on organ involvement was available for 9 patients : kidneys were affected in 7 (78%), the gastrointestinal tract in 4 (44%) and the peripheral nervous system in 2 (22%). There was no case of cardiac involvement. AA amyloidosis diagnosis was based on

mass spectrometry in three cases, showing SAA protein deposition without light-chain deposition (patients #1, #5, #6). The results for patient #1 are illustrated in Figure 2. The hematological diseases were as follows: WM (n=8), SS (n=2), MM (n=1), MGUS (n=1). The most frequent isotype was IgM kappa, found in 83% (n=10/12) of the patients. MG was diagnosed before and at the same time as AA amyloidosis in 7 and 5 cases, respectively (median delay between MG and AA amyloidosis 16 months, extreme value 0 to 120 months).

C-reactive protein (CRP) data were available for the 4 patients in this series and was always elevated (median 25 mg/L ranging from 5 to 135 mg/L for a normal <5 mg/L); SAA levels were available for 4 patients and was also always elevated (median 28 mg/L ranging from 10 to 99 mg/L, for a normal <5 mg/L). The treatment strategy was available for 8 patients: treatment targeting the hematological disease for four (50%) (MM (n=1) and WM (n=3)), treatment targeting the IL-1 inflammatory pathway with Anakinra in 2 (25%), and no treatment in 2 patients (25%). The treatment of the hematological malignancy appeared to be effective for controlling amyloidosis symptoms and the inflammation in the three patients showing a hematological response (patients #4, #6, #8, follow-up time respectively 36, 12 and 12 months), whereas the one without hematological response had persistent symptoms leading to death (#7, follow up time 4 months). Even more, a case of WM (#6) reported the disappearance of amyloid deposition after treatment of the hematological malignancy. The cases from our centers (#1, #2) treated with Anakinra had a good control of the inflammation and showed no sign of progression of the AA amyloidosis, but the treatment had no effect on the monoclonal gammopathy with a follow up time of 42 and 62 months.

### **Discussion:**

Although MGs are not believed to represent AA amyloidosis causing conditions, we identified 12 AA amyloidosis cases for which MG was the most likely causative condition. A MG is signaling the presence of clonal B-cell proliferation. It is accompanied by an excess of light chain, in some cases leading to AL amyloidosis (1). Although the light chain itself cannot lead to AA amyloidosis, the underlying hematological disease can be associated with chronic inflammation that can lead to AA amyloidosis.

Several neoplasias have been associated with AA amyloidosis (5). The difficulty with hematological neoplasia with MG is that in the presence of amyloidosis, AL amyloidosis would be the most likely diagnosis. For this study, we selected strictly proven AA amyloidosis cases without suspicion of AL amyloidosis. Organ involvement is also more supportive of AA



amyloidosis than AL amyloidosis (1,2). Thus, one can conclude that our cases were AA amyloidosis. It is difficult to determine the causal relationship of an AA amyloidosis -causing disease, especially in retrospective analysis, though several methods can be used to evaluate this relationship. The first is based on the number of reported cases, as described by *Brunger et al.* (5). Based on this approach, WM and SS would be considered AA amyloidosis -causing diseases (n=8 and n=2 cases, respectively), whereas further cases would be needed for MGUS and MM (n=1 each). The second method is based on the evolution of AA amyloidosis after the treatment of the suspected causing disease. Data were only available for 1 WM case (17) in our study, with amyloid deposition disappearing after treatment.

From a biological point of view, several inflammatory features are associated with MG, suggesting a causal role in the development of AA amyloidosis. Elevated levels of acute-phase reactants such as CRP and SAA have been associated with clonal gammopathies (23). In this series, when available (n=5), acute-phase reactants were elevated in all patients. Moreover, there is evidence for the role of IL-1 $\beta$  and IL-6 in the survival and proliferation of tumor cells in MM and WM (24,25). Indeed, hyperproduction of these inflammatory cytokines in MM and WM may be responsible for low-grade inflammation and lead to AA amyloidosis. Overall, AA amyloidosis might complicate lymphoplasmacytic proliferation rather than plasma cell dyscrasia, as illustrated by the presence of the IgM kappa isotype in 84% (n=10) of the 12 patients. This is another major difference from AL amyloidosis, for which MGUS and MM are leading causes and WM a rarer cause (1).

The best treatment strategy in cases of AA amyloidosis complicating MG remains to be determined. As seen in this series, 2 strategies can be identified. The first is to target clonal proliferation. The second strategy is to target the production of acute-phase reactants and SAA by inhibiting their production, mainly with IL-1 $\beta$  inhibitors. According to our series, both strategies appear to be effective, and the treatment decision should be made according to the stage of the neoplasia and the patient's preferences.

Due to its retrospective design, this study has several limitations, particularly the lack of central pathological reassessment and the absence of systematic mass spectrometry analysis. Further research is needed to confirm the causal relationships found. However, our study underlies the importance of searching for MG while investigating the cause of AA amyloidosis of unknown origin, and to search for AA amyloidosis in monoclonal B-cell diseases associated with inflammation, particularly lymphoplasmacytic diseases. Our findings also highlight the

importance of precise identification of amyloid deposits in the case of monoclonal gammopathy, as those deposits might not always constitute light-chain deposition.

MG complicated with AA amyloidosis might be referred to as “monoclonal gammopathies of inflammatory significance” (MGIS), as we previously suggested for inflammatory symptoms complicating MG (26).

### **Conclusion:**

Some MG, and mostly lymphoplasmacytic disorders (WM and SS), might be a rare and poorly known cause of AA amyloidosis, which we propose to call “monoclonal gammopathies of inflammatory significance”.

**Declaration of interest:** None

**Funding:** No specific funding was received for this work.

### **References:**

1. Merlini G. AL amyloidosis: from molecular mechanisms to targeted therapies. *Hematol Am Soc Hematol Educ Program*. 2017 08;2017(1):1–12.
2. Westermark GT, Fändrich M, Westermark P. AA amyloidosis: pathogenesis and targeted therapy. *Annu Rev Pathol*. 2015;10:321–44.
3. Lachmann HJ, Goodman HJB, Gilbertson JA, Gallimore JR, Sabin CA, Gillmore JD, et al. Natural history and outcome in systemic AA amyloidosis. *N Engl J Med*. 2007 Jun 7;356(23):2361–71.
4. Simon A, Asli B, Braun-Falco M, De Koning H, Ferman J-P, Grattan C, et al. Schnitzler’s syndrome: diagnosis, treatment, and follow-up. *Allergy*. 2013 May;68(5):562–8.
5. Brunger AF, Nienhuis HLA, Bijzet J, Hazenberg BPC. Causes of AA amyloidosis: a systematic review. *Amyloid Int J Exp Clin Investig Off J Int Soc Amyloidosis*. 2020 Mar;27(1):1–12.
6. Grundmann JU, Bonnekoh B, Gollnick H. Extensive haemorrhagic-bullous skin manifestation of systemic AA-amyloidosis associated with IgGlamba-myeloma. *Eur J Dermatol EJD*. 2000 Mar;10(2):139–42.
7. Raghunathan V, Louis D, Wirk B. Gastrointestinal Tract Amyloidosis Presenting With Pneumatosis Intestinalis. *J Clin Med Res*. 2017 Jul;9(7):654–8.

8. Watanabe R, Ito K, Yasuno T, Abe Y, Hamauchi A, Yasunaga T, et al. Persistence of renal function in a patient diagnosed with concurrent amyloid amyloidosis and immunoglobulin light chain amyloidosis. *Nihon Jinzo Gakkai Shi*. 2016;58(5):668–74.
9. Ishikawa H, Nakata K, Aritomi T, Ohkubo K, Migita K, Hamasaki K, et al. Amyloid a protein amyloidosis in a patient with plasma cell dyscrasia. *Intern Med Tokyo Jpn*. 2002 May;41(5):386–91.
10. Quinton R, Siersema PD, Michiels JJ, ten Kate FJ. Renal AA amyloidosis in a patient with Bence Jones proteinuria and ankylosing spondylitis. *J Clin Pathol*. 1992 Oct;45(10):934–6.
11. Riveiro-Barciela M, Martínez-Valle F, Vilardell-Tarrés M. Nephrotic syndrome and lambda light-chain monoclonal gammopathy suggestive of primary amyloidosis with positive staining for AA amyloid. *J Am Geriatr Soc*. 2012 Oct;60(10):1974–5.
12. Vanderschueren S, van der Veen A. The Schnitzler syndrome: chronic urticaria in disguise: a single-centre report of 11 cases and a critical reappraisal of the literature. *Clin Exp Rheumatol*. 2017 Feb;35(1):69–73.
13. Conlon NP, Hayden P, Barnes L, Doran M, O’Shea F, Feighery C. Schnitzler’s syndrome; a case highlighting the complications of long-standing acquired autoinflammation. *Eur J Dermatol EJD*. 2014 Jun;24(3):405–6.
14. Mittal N, Renaut P, Sharma R, Robbie M. Gastrointestinal amyloidosis associated with Schnitzler’s syndrome. *Pathology (Phila)*. 2013;45(4):424–6.
15. Claes K, Bammens B, Delforge M, Evenepoel P, Kuypers D, Vanrenterghem Y. Another devastating complication of the Schnitzler syndrome: AA amyloidosis. *Br J Dermatol*. 2008 Jan;158(1):182–4.
16. Néel A, Henry B, Barbarot S, Masseau A, Perrin F, Bernier C, et al. Long-term effectiveness and safety of interleukin-1 receptor antagonist (anakinra) in Schnitzler’s syndrome: a French multicenter study. *Autoimmun Rev*. 2014 Oct;13(10):1035–41.
17. Muzaffar J, Katragadda L, Haider S, Abdallah A-O, Anaissie E, Usmani SZ. Waldenström’s macroglobulinemia associated with serum amyloid A protein amyloidosis: pitfalls in diagnosis and successful treatment with melphalan-based autologous stem cell transplant. *Acta Haematol*. 2013;130(3):146–9.
18. Gardyn J, Schwartz A, Gal R, Lewinski U, Kristt D, Cohen AM. Waldenström’s macroglobulinemia associated with AA amyloidosis. *Int J Hematol*. 2001 Jul;74(1):76–8.
19. Tatara R, Nagai T, Kobayashi H, Hatano K, Suzuki T, Muroi K, et al. AA amyloidosis associated with macroglobulinemia. *Int J Hematol*. 2010 Nov;92(4):675–7.
20. Ogami Y, Takasugi M, Soejima M, Kuroiwa A, Oma H, Nakano M, et al. Waldenström’s macroglobulinemia associated with amyloidosis and crescentic glomerulonephritis. *Nephron*. 1989;51(1):95–8.

21. Terrier B, Jaccard A, Harousseau J-L, Delarue R, Tournilhac O, Hunault-Berger M, et al. The clinical spectrum of IgM-related amyloidosis: a French nationwide retrospective study of 72 patients. *Medicine (Baltimore)*. 2008 Mar;87(2):99–109.
22. Kihara Y, Hori H, Murakami H, Hatakeyama Y, Yoshikawa I, Hamada T, et al. A case of POEMS syndrome associated with reactive amyloidosis and Waldenström's macroglobulinaemia. *J Intern Med*. 2002 Sep;252(3):255–8.
23. Pelliniemi TT, Irjala K, Mattila K, Pulkki K, Rajamäki A, Tienhaara A, et al. Immunoreactive interleukin-6 and acute phase proteins as prognostic factors in multiple myeloma. Finnish Leukemia Group. *Blood*. 1995 Feb 1;85(3):765–71.
24. Lust JA, Lacy MQ, Zeldenrust SR, Witzig TE, Moon-Tasson LL, Dinarello CA, et al. Reduction in C-reactive protein indicates successful targeting of the IL-1/IL-6 axis resulting in improved survival in early stage multiple myeloma. *Am J Hematol*. 2016;91(6):571–4.
25. Elswa SF, Novak AJ, Ziesmer SC, Almada LL, Hodge LS, Grote DM, et al. Comprehensive analysis of tumor microenvironment cytokines in Waldenstrom macroglobulinemia identifies CCL5 as a novel modulator of IL-6 activity. *Blood*. 2011 Nov 17;118(20):5540–9.
26. Terré A, Talbot A, Louvrier C, Picque JB, Mahévas M, Boutboul D, et al. Monoclonal Gammopathy, Arthralgias, and Recurrent Fever Syndrome: A New Autoinflammatory Syndrome? *J Rheumatol*. 2019 Nov;46(11):1535–9.

## **Tables:**

**Table 1:** Main characteristics of the patients.

Legend: AAA = AA amyloidosis, M = Male, F = Female, WM = Waldenström macroglobulinemia, SS = Schnitzler syndrome, MM = Multiple myeloma, MGUS = monoclonal gammopathy of unknown significance, Ig = Immunoglobulin, GI = Gastrointestinal, PNS = Peripheral nervous system, NA = Not available, HSCT = Hematopoietic stem cell transplantation.

## **Figure legends:**

**Figure 1:** Flow-chart of the study.

Legend: AAA = AA amyloidosis, M = Male, F = Female, WM = Waldenström macroglobulinemia, SS = Schnitzler syndrome, MM = Multiple myeloma, MGUS = monoclonal gammopathy of unknown significance

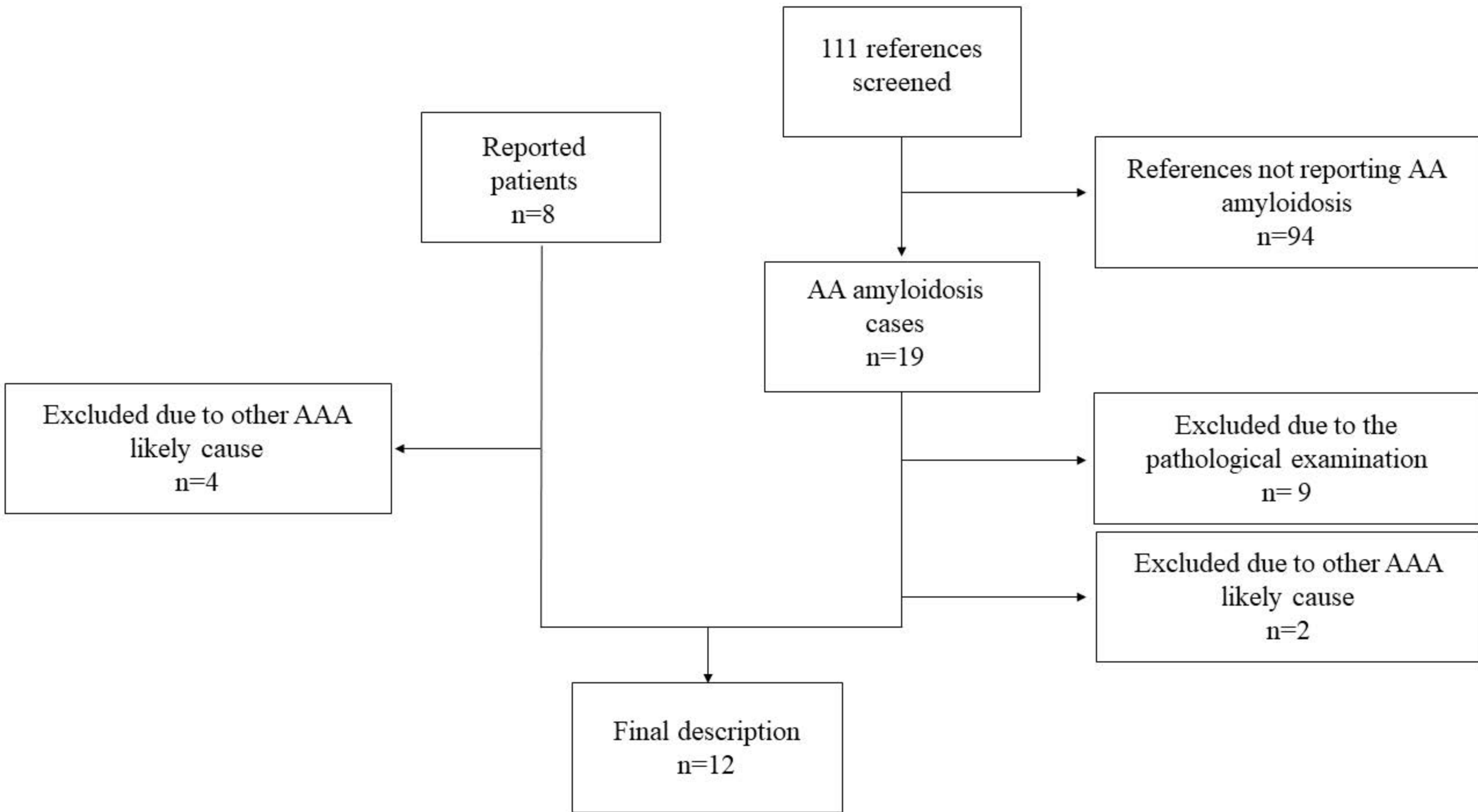
**Figure 2:** Anatomopathological analysis and proteomic results for the minor salivary gland biopsy of Patient 1.

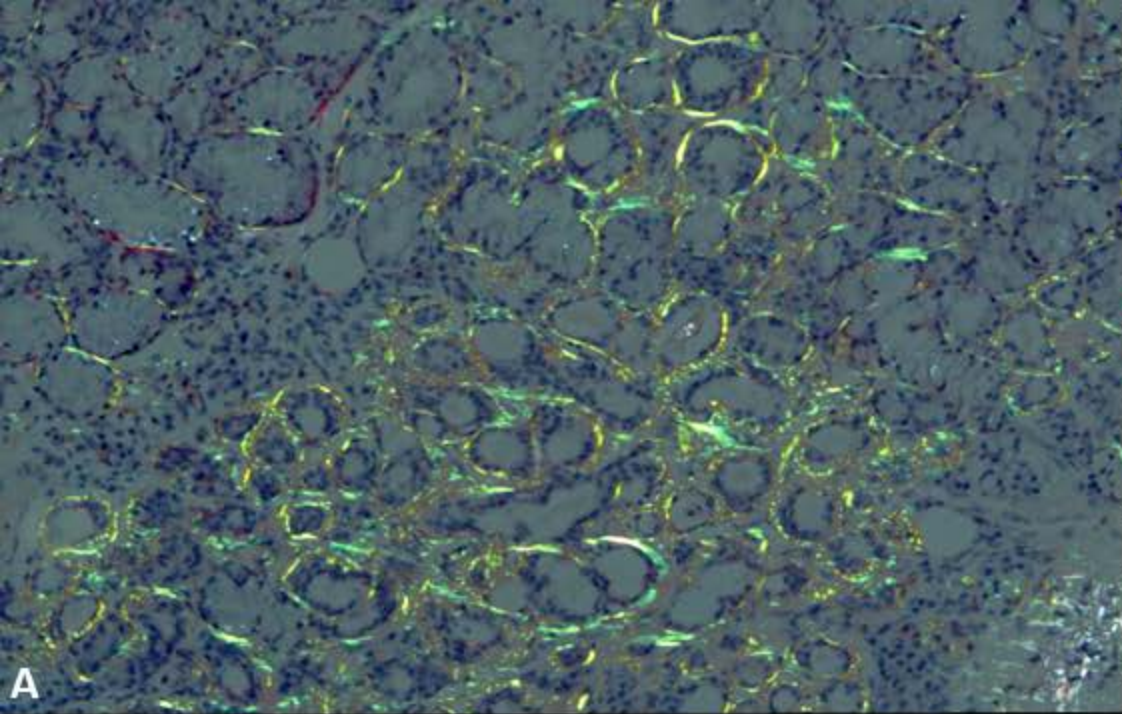
Panel A: Typical yellow-green birefringence of amyloid deposits under polarized light showing abundant amyloid deposits along the basement membrane of salivary acini.

Panel B: Immunostaining with antibodies directed against the serum amyloid A protein, showing an intense marking of amyloid deposits.

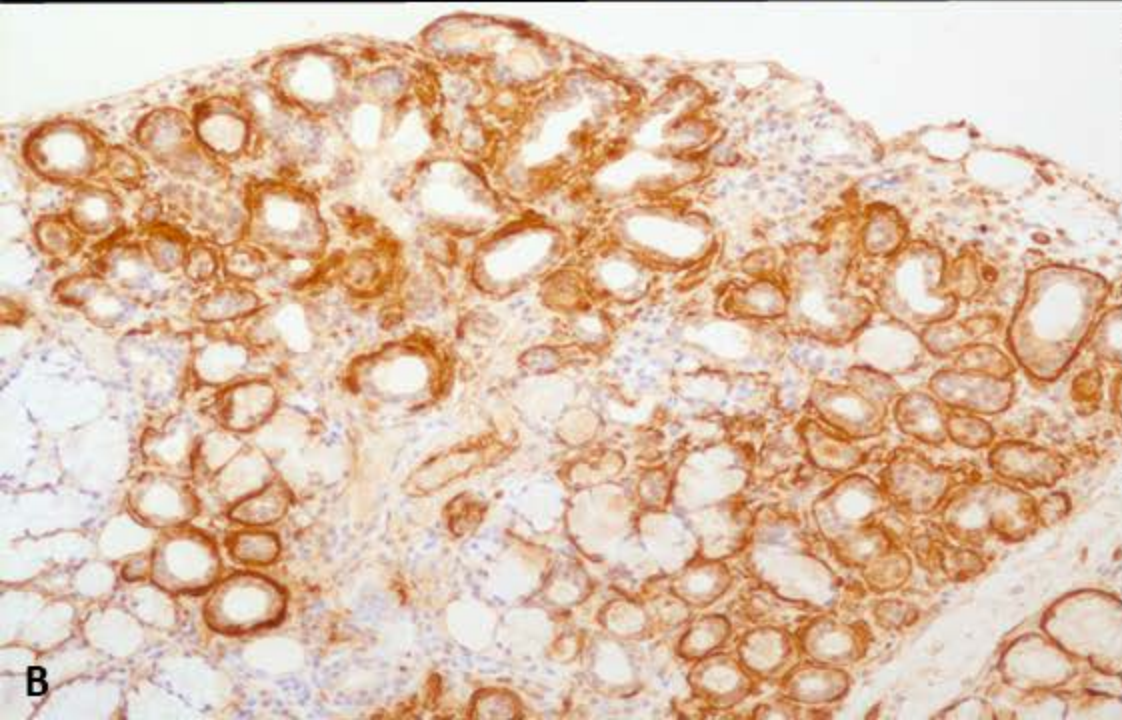
Panel C: Mass spectrometry analysis after laser microdissection of Congo red-positive deposits showed serum amyloid A1 as the dominant protein associated with the serum amyloid P component and apolipoprotein E, two proteins attesting to the amyloid nature of the deposits.







A



B

Protein identified	MS/MS
<b>Serum amyloid A-1</b>	79
Collagen alpha-3(VI) chain	43
<b>Serum amyloid P-component</b>	22
<b>Apolipoprotein E</b>	18
Serum albumin	15
Basement membrane-specific heparan sulfate proteoglycan core protein	14
Vitronectin	12
Lactotransferrin	11
Actin, cytoplasmic 1	10
Collagen alpha-1(VI) chain	10
Vimentin	8
ATP synthase subunit alpha, mitochondrial	8
L-lactate dehydrogenase A chain	8
Clusterin	7
Glyceraldehyde-3-phosphate dehydrogenase	6
Collagen alpha-2(VI) chain	6
Annexin A2	6
Alpha-enolase	6
Prelamin-A/C	6
Sodium/potassium-transporting ATPase subunit alpha-1	6

C



Case	First author	Sex	Age at AAA diagnosis (year)	Type of gammopathy	Isotype	Clinical organ involvement	Delay between gammopathy and AAA diagnosis (month)	CRP (mg/L) at diagnosis N<5	SAA (mg/L) at diagnosis N<5	Treatment
1	This series	M	74	WM	IgM kappa	Kidney	0	135	10	IL1-RA
2	This series	M	64	SS	IgM kappa	Kidney	72	5	16	IL1-RA
3	This series	M	50	MGUS	NA	Kidney, GI tract, PNS	0	31	NA	No treatment
4	This series	F	62	MM	IgA lambda	PNS	25	19	40	MM treatment Melphalan based HSCT
5	Mittal <sup>14</sup>	M	54	SS	IgM kappa	GI tract	120	NA	NA	NA
6	Muzaffar <sup>17</sup>	F	65	WM	IgM kappa	Kidney, GI tract	96	NA	NA	WM treatment Melphalan based HSCT
7	Gardyn <sup>18</sup>	M	79	WM	IgM kappa	Kidney, GI tract	4	NA	NA	WM treatment
8	Tatara <sup>19</sup>	M	44	WM	IgM kappa	GI tract	0	NA	99	WM treatment
9	Ogami <sup>20</sup>	M	74	WM	IgM kappa	Kidney, GI tract	0	NA	NA	No treatment
10	Terrier <sup>21</sup>	F	72	WM	IgM kappa	NA	7	NA	NA	NA
11	Terrier <sup>21</sup>	F	75	WM	IgM kappa	NA	60	NA	NA	NA
12	Terrier <sup>21</sup>	F	79	WM	IgM kappa	NA	89	NA	NA	NA

Legend: AAA = AA amyloidosis, M = Male, F = Female, WM = Waldenstrom macroglobulinemia, SS = Schnitzler syndrome, MM = Multiple myeloma, MGUS = monoclonal gammopathy of unknown significance, Ig = Immunoglobuline, GI = gastro-intestinal, PNS = peripheral nervous system, NA = not available, HSCT = Haematopoietic stem cell transplantation.