



**HAL**  
open science

## **A ruptured cornual pregnancy successfully managed in a patient with a history of oophorectomy and salpingectomy: A rare case report**

Marah Mansour, Amr Hamza, Alhomam Almarzook, Ilda Moafak Kanbour,  
Tamim Alsuliman, Bashar Kurdi

### ► To cite this version:

Marah Mansour, Amr Hamza, Alhomam Almarzook, Ilda Moafak Kanbour, Tamim Alsuliman, et al.. A ruptured cornual pregnancy successfully managed in a patient with a history of oophorectomy and salpingectomy: A rare case report. *Clinical Case Reports*, 2021, 9 (10), 10.1002/ccr3.4934 . hal-03405457

**HAL Id: hal-03405457**

**<https://hal.sorbonne-universite.fr/hal-03405457v1>**

Submitted on 27 Oct 2021

**HAL** is a multi-disciplinary open access archive for the deposit and dissemination of scientific research documents, whether they are published or not. The documents may come from teaching and research institutions in France or abroad, or from public or private research centers.

L'archive ouverte pluridisciplinaire **HAL**, est destinée au dépôt et à la diffusion de documents scientifiques de niveau recherche, publiés ou non, émanant des établissements d'enseignement et de recherche français ou étrangers, des laboratoires publics ou privés.

# A ruptured cornual pregnancy successfully managed in a patient with a history of oophorectomy and salpingectomy: A rare case report

Marah Mansour<sup>1</sup>  | Amr Hamza<sup>2</sup> | AlHomam AlMarzook<sup>3</sup> |  
Ilda moafak kanbour<sup>4</sup> | Tamim Alsuliman<sup>5</sup> | Bashar kurdi<sup>6</sup>

<sup>1</sup>Faculty of Medicine, Tartous University, Tartous, Syrian Arab Republic

<sup>2</sup>Faculty of Medicine, Aleppo University, Aleppo, Syrian Arab Republic

<sup>3</sup>Department of Neurosurgery, Ibn Al-Nafees Hospital, Damascus, Syrian Arab Republic

<sup>4</sup>Department of Obstetrics and Gynecology, Maternity Hospital, Damascus, Syrian Arab Republic

<sup>5</sup>Hematology and Cell Therapy Department, Saint-Antoine Hospital, AP-HP, Sorbonne University, Paris, France

<sup>6</sup>Chair of Department of Obstetrics and Gynecology, Maternity Hospital, Damascus, Syrian Arab Republic

## Correspondence

Marah Mansour, Faculty of Medicine,  
Tartous University, Tartous, Syrian  
Arab Republic.  
Email: marahmohammad66@gmail.  
com

## Funding information

No funding was required

## Abstract

Cornual pregnancy is a rare condition that accounts for approximately 2–4% of ectopic pregnancies worldwide. Herein, we report an unstable case of a 32-year-old woman with a history of oophorectomy and salpingectomy who was admitted for a ruptured cornual pregnancy in the left cornu, which was successfully managed by laparotomy.

## KEYWORDS

cornual pregnancy, ectopic pregnancy, exploratory laparotomy, pfannenstiell incision

## 1 | INTRODUCTION

Ectopic pregnancy is a common and potentially hazardous condition in which a viable ovum implants outside the uterine corpus.<sup>1</sup> Cornual pregnancy (CP) is considered the most troublesome sort of ectopic pregnancy due to low affectability, the explicitness of side effects, and imaging analyses.<sup>2</sup> CP is a rare entity in the general population, particularly in spontaneous pregnancies, and accounts for 2–4% of ectopic pregnancies.<sup>1,2</sup> The exemplary triad of CP—stomach agony, amenorrhea,

and vaginal dying—happens in under 40% of patients.<sup>2</sup> Transvaginal ultrasound and  $\beta$ -HCG are imperative for the early diagnosis of CP.<sup>3</sup> Ultrasonography should be used to establish CP management (particularly three-dimensional ultrasonography). According to the size and viability of the pregnancy, the procedure should be planned.<sup>4</sup> Laparotomy is typically used to manage CP.<sup>3</sup> Adequate suturing of uterine cornua could preclude the risk of rupture during upcoming pregnancies. Decreased blood loss during and after the operation is a priority.<sup>4</sup> Aside from surgical treatment, CP can also be managed

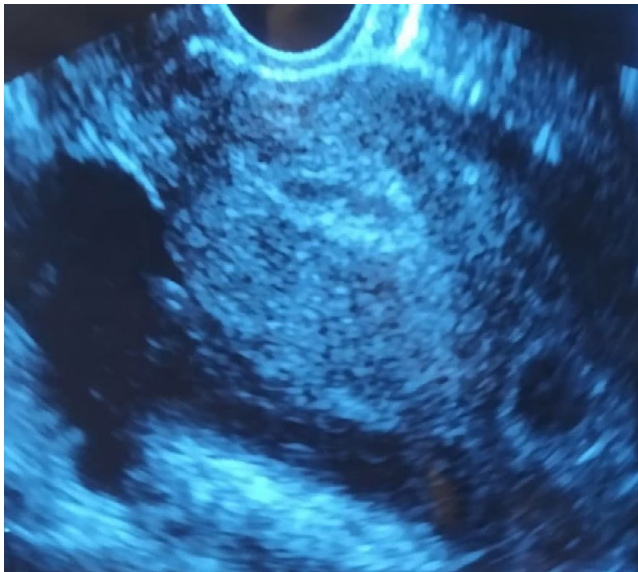
This is an open access article under the terms of the Creative Commons Attribution-NonCommercial-NoDerivs License, which permits use and distribution in any medium, provided the original work is properly cited, the use is non-commercial and no modifications or adaptations are made.

© 2021 The Authors. *Clinical Case Reports* published by John Wiley & Sons Ltd.

conservatively by (systemic or local) methotrexate injections. Methotrexate therapy is typically ineffective in advanced cornual pregnancies with elevated  $\beta$ -HCG levels.<sup>1,3</sup>

## 2 | CASE PRESENTATION

A 32-year-old woman, gravida 5, para 4, and aborta 1, presented to the Department of Obstetrics and Gynecology with severe lower abdominal pain that began approximately 1 day ago and had progressively worsened. The last menstrual period (LMP) was 40 days ago with a medical history of left Fallopian tube pregnancy a year ago, which was successfully managed by oophorectomy and salpingectomy of the left side. Previous pregnancies resulted in uncomplicated spontaneous vaginal deliveries. No history of tobacco, alcohol, allergies, or medications was reported. The vital signs were measured (blood pressure: 100/60 mm Hg, pulse rate: 110/min, and BMI:

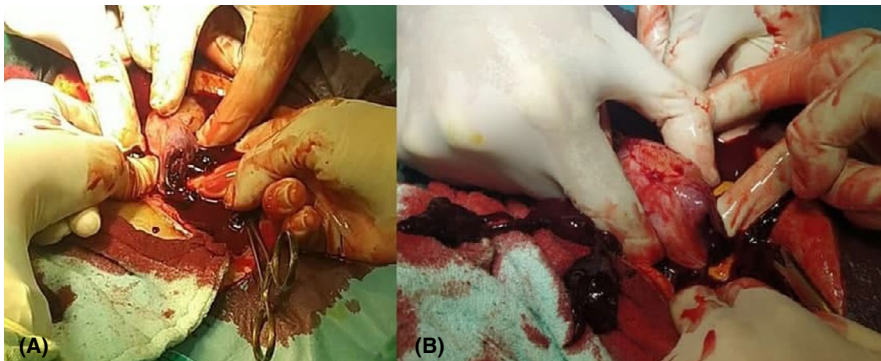


**FIGURE 1** Transvaginal two-dimensional ultrasonography scan in transverse view showing left interstitial ectopic pregnancy

21 kg/m<sup>2</sup>). Laboratory findings were as follows: hemoglobin: 10.3 g/DL, hematocrit: 28.1%, leukocyte count: 20.5/ $\mu$ m, neutrophils: 90%, and platelets: 357/ $\mu$ m,  $\beta$ -HCG: 7503 IU/L. Vaginal examination revealed a closed cervix with no vaginal bleeding, but tenderness to palpation and motion. Ultrasound demonstrated an empty uterus with decidual reaction, and a visible gestational sac located in the left cornu, the 5th-weeks' gestational sac in size (Figure 1), with a moderate amount of peritoneal fluid in Douglas Pouch extends to Morris pouch. An emergency exploratory laparotomy was performed via a Pfannenstiel incision. A ruptured gestational sac located in the left cornu was found, complicated by severe bleeding filling the peritoneal cavity, which was suctioned (Figure 2A,B). The products of conception, gestational sac, and left cornu were successfully eradicated (Figure 3A,B), (Figure 4). The ZZ drainage has been placed in Douglas's pouch and removed one week after surgery. One unit of blood was transfused during surgery. Pathological findings confirmed the diagnosis of ectopic pregnancy (Figure 4). The postoperative period was unremarkable; the patient was discharged 24 h after the surgery in a hemodynamically stable state. After 1 year of follow-up, there were no long-term complications. However, the patient uses oral contraceptives to prevent pregnancy.

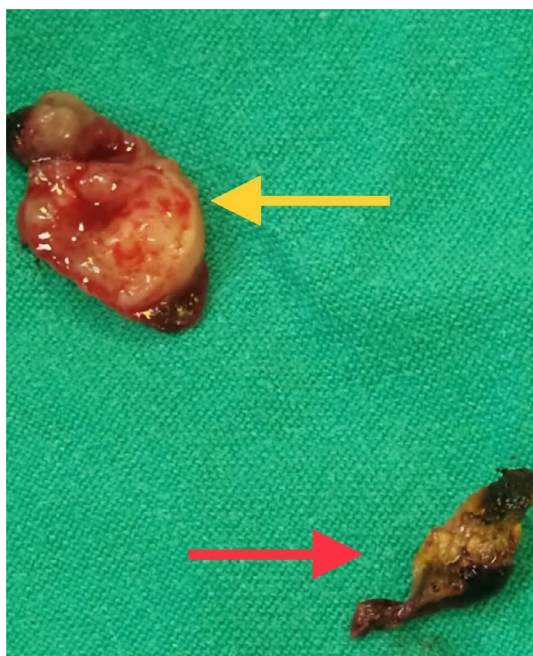
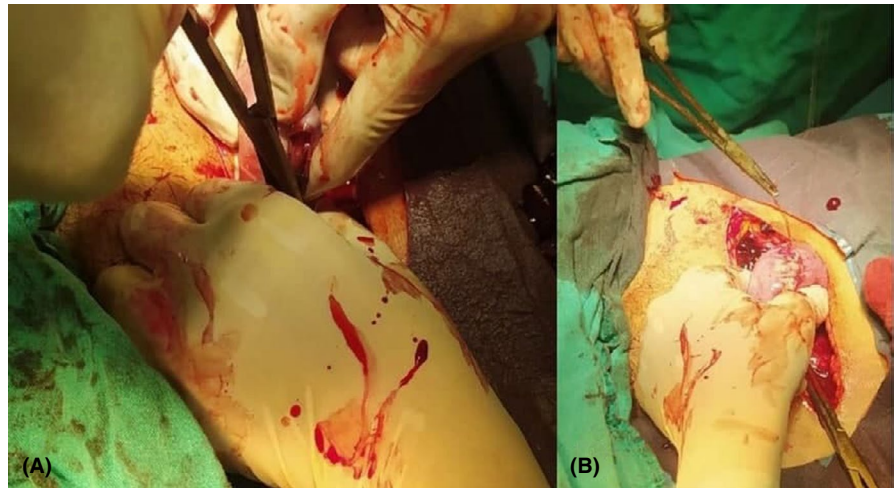
## 3 | DISCUSSION AND CONCLUSION

Cornual pregnancy is considered a rare entity that represents 2–4% of all tubal pregnancies.<sup>5</sup> It could be a life-threatening condition as it tends to rupture in approximately 48.6% of cases, leading to potential consequences on the fetus and the female pregnant.<sup>6</sup> Risk factors of CP include previous ectopic pregnancies, assisted reproductive techniques, tubal anomaly, proximal intra-tubal adhesions, and rarely ipsilateral salpingectomy.<sup>3,5</sup> The symptoms usually occur 9th to 12th weeks after the LMP due to myometrial stretchability. These include discomfort, abdominal pain, and



**FIGURE 2** (A, B): View at the beginning of laparotomy findings showing a ruptured left uterine cornual ectopic pregnancy with showing the abdomen full of clots

**FIGURE 3** (A, B): (A) Performing laparotomy cornual excisions. (B) The final result of surgery interrupted sutures



**FIGURE 4** View showing the resection of the cornual (yellow arrow) with gestational sac (red arrow)

abnormal vaginal bleeding.<sup>7</sup> Despite its complexity, early diagnosis of CP poses the cornerstone of lowering maternal mortality. Clinical features, increased  $\beta$ -HCG, and transvaginal ultrasonography are considered typical diagnostic modalities.<sup>4</sup> However, ultrasonography could distinguish the gestational sac in uterine cornua with increased vascularity (Figure 1).<sup>8</sup> The literature reports a wide variety of treatment approaches. Previous interventions commonly included hysterectomy or cornual resection via laparotomy. However, more conservative laparoscopic approaches have been implemented recently, including cornual resection, cornuostomy, and salpingectomy.<sup>5,9</sup> Of interest, the potential persistent ectopic pregnancy has augmented after the conservative surgical procedures. However, rupture of CP could

stimulate serious intra-abdominal bleeding resulting in hypovolemic shock; therefore, laparotomy could be preferred in hemodynamically unstable patients.<sup>4</sup> Besides surgical treatment, CP can also be managed conservatively by (systemic or local) methotrexate injections. However, its adverse effects could include increasing  $\beta$ -HCG level, persistent abdominal pain, recurrent interstitial pregnancy, toxicity, and a risk of rupture in subsequent pregnancies.<sup>9</sup> Furthermore, the local methotrexate injections appeared to be more efficient.<sup>6</sup> The convenient decline in  $\beta$ -HCG blood level indicates successful management of a CP.<sup>10</sup> Habana et al. discussed the outcomes of females undergoing surgery versus medical treatment, and the results revealed the advantages of surgery in terms of miscarriage (13% versus 50%,  $p < 0.05$ ) and live birth rate (60.9% versus 50%).<sup>7,9</sup> Spontaneous CP after ipsilateral salpingectomy is a very rare entity in which diagnosis is usually delayed. In conclusion, salpingectomy could not eliminate the potential of ipsilateral ectopic pregnancy. Therefore, an early well-organized follow-up of each pregnant with a history of salpingectomy is recommended to avoid potentially fatal consequences.

#### ACKNOWLEDGMENT

Not applicable.

#### AUTHOR CONTRIBUTIONS

Marah Mansour involved in design of study, data collection, data interpretation and analysis, drafting, critical revision, and approval of final manuscript. Amr Hamza involved in data collection, data interpretation and analysis, critical revision, drafting, and approval of final manuscript. AlHomam AlMarzook involved in data interpretation and analysis, critical revision, drafting, and approval of final manuscript. Ilda moafak kanbour involved in data collecting, critical revision, and approval of final manuscript. Tamim Alsuliman involved in drafting, critical revision,

and approval of final manuscript. Bashar kurdi served as the Supervisor, involved in patient care, drafting, critical revision, and approval of final manuscript.

## ETHICAL APPROVAL

Not required for this case report.

## CONSENT

Written informed consent was obtained from the patient for publishing this case report and any accompanying images. A copy of the written consent is available for review by the Editor-in-Chief of this journal on request.

## DATA AVAILABILITY STATEMENT

All data (of this patient) generated during this study are included in this published article and its supplementary information files.

## ORCID

Marah Mansour  <https://orcid.org/0000-0002-6129-5733>

## REFERENCES

1. Oral S, Akpak YK, Karaca N, Babacan A, Savan K. Cornual heterotopic pregnancy after bilateral salpingectomy and uterine septum resection resulting in term delivery of a healthy infant. *Case Rep Obstet Gynecol*. 2014;2014:157030. <https://doi.org/10.1155/2014/157030>. Epub 2014 Nov 5. PMID: 25431713; PMCID: PMC4238269.
2. Dagar M, Srivastava M, Ganguli I, Bhardwaj P, Sharma N, Chawla D. Interstitial and cornual ectopic pregnancy: conservative surgical and medical management. *J Obstet Gynecol India*. 2018;68(6):471-476. <https://doi.org/10.1007/s13224-017-1078-0>. Epub 2017 Nov 28. PMID: 30416274; PMCID: PMC6207538.
3. Maruthini D, Sharma V. A case of live birth after uterine reconstruction for recurrent cornual ectopic pregnancy following IVF treatment. *Case Rep Obstet Gynecol*. 2013;2013:1-6.
4. Pramayadi CT, Bramantyo A, Gunardi ER. Successful procedure in conservative management of interstitial (Cornual) ectopic pregnancy. *Gynecol Minim Invasive Ther*. 2018;7(4):172.
5. Tulandi T, Al-Jaroudi D. Interstitial pregnancy: Results generated from the society of reproductive surgeons registry. *Obstet Gynecol*. 2004;103:47-50.
6. Habana A, Dokras A, Giraldo JL, Jones EE. Cornual heterotopic pregnancy: contemporary management options. *Am J Obstet Gynecol*. 2000;182:1264-1270. <https://doi.org/10.1067/mob.2000.103620>
7. Jourdain O, Fontanges M, Schiano A, Rauch F, Gonnet JM. Prise en charge des autres ectopies annexielles (cornuale, interstitielle, angulaire, ovarienne) [Management of other ectopic pregnancies (cornual, interstitial, angular, ovarian)]. *J Gynecol Obstet Biol Reprod (Paris)*. 2003;32(7 Suppl):S93-S100.
8. Advincola AP, Senapati S. Interstitial pregnancy. *Fertil Steril*. 2004;82(6):1660-1661.
9. Moawad NS, Mahajan ST, Moniz MH, Taylor SE, Hurd WW. Current diagnosis and treatment of interstitial pregnancy. *Am J Obstet Gynecol*. 2010;202:15-29.
10. Zalel Y, Caspi B, Insler V. Expectant management of interstitial pregnancy. *Ultrasound Obstet Gynecol*. 1994;4:238-240.

**How to cite this article:** Mansour M, Hamza A, AlMarzook A, kanbour IM, Alsuliman T, kurdi B. A ruptured cornual pregnancy successfully managed in a patient with a history of oophorectomy and salpingectomy: A rare case report. *Clin Case Rep*. 2021;9:e04934. <https://doi.org/10.1002/ccr3.4934>