



HAL
open science

Osteoarticular Infections Caused by *Erysipelothrix rhusiopathiae*: Case Report and Literature Review

Alexis Maillard, Yara Wakim, Oula Itani, Fateh Ousser, Alexandre Bleibtreu,
Eric Caumes, Gentiane Monsel

► To cite this version:

Alexis Maillard, Yara Wakim, Oula Itani, Fateh Ousser, Alexandre Bleibtreu, et al.. Osteoarticular Infections Caused by *Erysipelothrix rhusiopathiae*: Case Report and Literature Review. Open Forum Infectious Diseases, 2021, 8 (10), pp.ofab461. 10.1093/ofid/ofab461 . hal-03420863

HAL Id: hal-03420863

<https://hal.sorbonne-universite.fr/hal-03420863v1>

Submitted on 9 Nov 2021

HAL is a multi-disciplinary open access archive for the deposit and dissemination of scientific research documents, whether they are published or not. The documents may come from teaching and research institutions in France or abroad, or from public or private research centers.

L'archive ouverte pluridisciplinaire **HAL**, est destinée au dépôt et à la diffusion de documents scientifiques de niveau recherche, publiés ou non, émanant des établissements d'enseignement et de recherche français ou étrangers, des laboratoires publics ou privés.

Osteoarticular Infections Caused by *Erysipelothrix rhusiopathiae*: Case Report and Literature Review

Alexis Maillard,^{1,a} Yara Wakim,^{1,a} Oula Itani,^{1,a} Fateh Ousser,² Alexandre Bleibtreu,^{1,c} Eric Caumes,^{1,3} and Gentiane Monseil¹

¹Department of Infectious and Tropical Diseases, Sorbonne Université, Pitié-Salpêtrière hospital, Assistance Publique–Hôpitaux de Paris, Paris, France, ²Department of Bacteriology and Hygiene, Sorbonne Université, Pitié-Salpêtrière Hospital, Assistance Publique–Hôpitaux de Paris, Paris, France, and ³Inserm Unité Mixte de Recherche-S 1136, Pierre Louis Institute of Epidemiology and Public Health, Paris, France

We present a case of *Erysipelothrix rhusiopathiae* spondylodiscitis in an otherwise healthy man, occurring 1 year after exposure. The patient was cured after 6 weeks of treatment with amoxicillin followed by ciprofloxacin without surgery. *Erysipelothrix rhusiopathiae* can cause severe osteoarticular infections with a delayed presentation following exposure to the pathogen.

Keywords. *Erysipelothrix rhusiopathiae*; osteoarticular infections; spondylodiscitis.

Erysipelothrix rhusiopathiae is a commensal or pathogenic organism in a wide variety of vertebrates and invertebrates that may be transmitted from contact with animals, domestic swine being the main reservoir [1]. *Erysipelothrix rhusiopathiae* is also known to be found in the mucoid exterior slime of fish, from which it can be transmitted by puncture or direct contact with grazed or wounded skin [2]. Three clinical entities are described in humans. The most common form is a localized cutaneous infection (erysiploid) that often self-resolves after a few weeks [3]. More rarely, *E rhusiopathiae* may lead to a diffuse cutaneous infection, or a systemic infection with bacteremia often associated with endocarditis [4, 5].

Erysipelothrix rhusiopathiae-related osteoarticular infections (OAIs) are more common in animals than in humans, in whom 16 cases have been published to date. We report the first case of nontraumatic *E rhusiopathiae* spondylodiscitis in an otherwise healthy man and review the literature.

Received 7 July 2021; editorial decision 22 August 2021; accepted 5 October 2021.

^aA. M., Y. W., and O. I. contributed equally to this work.

Correspondence: Alexis Maillard, Department of Infectious and Tropical Diseases, Pitié-Salpêtrière Hospital, 47 boulevard de l'hôpital, Paris 75013, France (alexis.maillard@aphp.fr).

Open Forum Infectious Diseases® 2021

© The Author(s) 2021. Published by Oxford University Press on behalf of Infectious Diseases Society of America. This is an Open Access article distributed under the terms of the Creative Commons Attribution-NonCommercial-NoDerivs licence (<https://creativecommons.org/licenses/by-nc-nd/4.0/>), which permits non-commercial reproduction and distribution of the work, in any medium, provided the original work is not altered or transformed in any way, and that the work is properly cited. For commercial re-use, please contact journals.permissions@oup.com.

<https://doi.org/10.1093/ofid/ofab461>

CASE REPORT

An otherwise healthy 51-year-old Nigerian man, who works as a cleaner, was admitted to our hospital for a 5-day history of fever and lumbar pain radiating down the left leg. He reported no travel history since arriving in France in 2004, no contact with animals, no consumption of raw meat or unpasteurized dairy products, and no known tuberculosis exposure. Upon examination, he presented tenderness on palpation of the lumbar spine and a positive straight left leg raise test, with no neurological involvement. No cardiac murmur was found. Laboratory examinations showed absolute neutrophil count of 9.3×10^9 cells/L (normal, $<7 \times 10^9$ cells/L), C-reactive protein level (CRP) of 224 mg/L (normal, <5 mg/L), and 5 negative blood cultures. Tuberculin skin test and human immunodeficiency virus serology were negative. Magnetic resonance imaging (MRI) of the spine showed a T2-hyperintense centimetric lesion in the L5–S1 intervertebral disk with gadolinium enhancement in periphery evoking an abscess, together with high T2-weighted signal in adjacent endplates (bone marrow edema). Also, several infracentimetric collections in the anterior and posterior epidural spaces were visible in the MRI, stretching from L5 to S2 and responsible for a spinal stenosis (Figure 1). All 4 bone biopsy samples yielded growth of *E rhusiopathiae*. Transthoracic and transesophageal echocardiography showed no evidence of endocarditis. Additional information collected from the patient revealed that he had sustained a superficial skin cut on the left hand with a fish bone while cooking a raw fish (fish bone stuck in his finger), 1 year prior to admission. The patient did not report any kind of infectious signs and did not seek medical care at that time. The isolate was identified by matrix-assisted laser desorption/ionization–time of flight (MALDI-TOF) and was susceptible to penicillin G, amoxicillin (minimum inhibitory concentration [MIC] <0.05 mg/L), ceftriaxone, meropenem, ciprofloxacin (MIC <0.05 mg/L), and clindamycin, and resistant to gentamicin, vancomycin, and rifampicin. Because of the limited size of the abscesses (infracentimetric) with no neurological impairment, the patient was managed without surgical evacuation. He was treated with intravenous amoxicillin 200 mg/kg/day for 2 weeks, then switched to oral ciprofloxacin 750 mg twice daily for 4 weeks. A computed tomographic scan of the spine performed 10 days after the end of treatment showed a persistent infiltration of soft tissues surrounding the L5–S1 intervertebral disk and stable irregularities of the S1 upper and L5 lower endplates as well as appearance of bone formation, in favor of a reossification. At 2-month follow-up, the patient's back pain had considerably improved and CRP levels had decreased (1.18 mg/L).

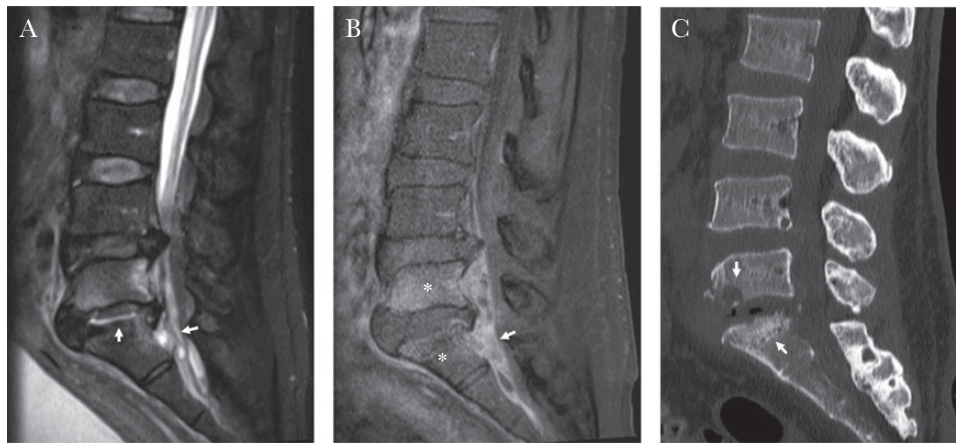


Figure 1. Magnetic resonance imaging (MRI) and computed tomographic (CT) scan examinations before antibiotic therapy. *A* and *B*, T2 (*A*) and injected T1 (*B*) weighted MRI examination of the spine, showing L5–S1 infectious spondylitis with an intervertebral abscess (T2-hyperintense centimetric lesion [fluid] in the L5–S1 disk with gadolinium enhancement in periphery, vertical arrow in *A*) and epidural abscesses (infracentimetric collections in the anterior and posterior epidural space stretching from L5 to S2 and responsible for a spinal stenosis, horizontal arrow in *A* and *B*). Note the enhanced signal in L5 and S1 vertebral bone after gadolinium injection (asterisks, *B*). *C*, CT examination shows bone erosions of vertebral endplates (arrows).

DISCUSSION AND LITERATURE REVIEW

This case confirms that *E rhusiopathiae* can be a cause of spondylodiscitis, even after an extended incubation period and without debilitating conditions. The patient was cured after 6 weeks of antibiotic monotherapy without surgery.

Erysipelothrix spp are pleomorphic, facultative intracellular, nonsporulating gram-positive bacteria and grow on standard media [1]. In humans, septic arthritis, osteomyelitis, and spondylitis due to *E rhusiopathiae* are rare. We found only 16 published cases: 11 septic arthritis (6 native joint infections and 5 prosthetic) [6–16], 1 chronic pubic symphysis [17], and 4 spondylitis or spondylodiscitis [18–21]. All are detailed in [Supplementary Table 1](#).

Overall, *E rhusiopathiae*-related OAIs occurred in patients between 5 and 82 years of age (median, 64.5 [interquartile range 50–70] years), including 11 males (69%) and 13 patients (81%) with debilitating or immunosuppressive conditions such as lupus, diabetes mellitus, cirrhosis, chronic lymphoid leukemia, prostate cancer, hemodialysis, alcoholism, or obesity, including conditions requiring use of systemic corticosteroids. Conversely in our case, the patient was young (51 years old) without any medical conditions. This confirms that *E rhusiopathiae* is able to cause systemic infections among healthy patients, mainly when an animal exposure is reported, as it was in this case.

Thirteen of the 16 patients (75%) with an *E rhusiopathiae*-related OAI reported an animal exposure, including contact with fish ($n = 5$), swine ($n = 2$), or cow ($n = 2$); hunting ($n = 1$); or butchering raw meat ($n = 3$). In our case, the patient reported a puncture with a fish bone 1 year before symptoms occurred. This incubation period is much longer than generally reported. In 9 cases, the animal exposure (farming, butchering, fishing, etc) was still ongoing at the time of first signs. In the

4 cases where a precise inoculation event was reported, 3 occurred within 2 months prior to diagnosis; however, 1 case of pubic symphysis occurred 14 years after a traumatism with a cow horn [17], suggesting that this bacteria can stay latent for a long time. An explanation for this may be that *E rhusiopathiae* could evade phagocytosis with intracellular replication and possess 2 adhesive surface proteins (rspA and rspB). These proteins belong to the same family as the CNA adhesive protein of *Staphylococcus* spp, known to be involved in biofilm formation and endovascular invasion and dissemination [22–24].

Erysipelothrix rhusiopathiae equally caused acute (evolving for 1–14 days) and chronic (evolving for 1–24 months) OAIs with 8 cases each, although previous reports mainly described them as a chronic process [6, 15]. All 10 *E rhusiopathiae*-related cases of arthritis involved a single big joint, either native ($n = 6$) or prosthetic ($n = 5$), mainly the knee ($n = 7$). Of the 5 vertebral infections, 3 involved the lumbar spine, whereas the 2 others were thoracic and cervical. Fever was reported in 8 patients (50%), regardless of whether the infection was acute or chronic. Fever was more frequently described in vertebral infections (100%, including in our case) than in arthritis (36%). Two patients (both with vertebral infections) reported previous cutaneous erysipeloid-like lesions. When available, CRP ranged from 15 mg/L to 224 mg/L, again regardless of whether infection was acute or chronic. Spinal complications (peridural empyema or abscesses both managed with urgent surgical evacuation) occurred in 2 patients.

In all cases of arthritis, microbiological diagnosis relied on synovial fluid or perioperative samples cultures. In vertebral infections, it was obtained from perioperative samples or radiologically guided biopsies and blood culture. When performed, all blood cultures remained sterile in the arthritis cases, and all but 1 yielded growth in the spondylitis cases. Vertebral

infections were frequently associated with endocarditis (2 of 3 with available echocardiography) as opposed to septic arthritis (only 1 doubtful case among 3 with available echocardiography). Identification was based on biochemical testing, sometimes confirmed with a 16S RNA ribosomal RNA polymerase chain reaction assay (n = 5), or using MALDI-TOF (n = 1) as in our case. No reliable serological techniques are available to date.

Management of OAI caused by *E rhusiopathiae* relies on both antibiotics and surgery. All patients with arthritis underwent interventional procedures (arthrotomy, arthroscopic lavage, synovectomy, or repeated arthrocentesis) with prosthesis exchange in all but 1 case involving prosthetic joints. Among vertebral infections, only the 2 patients with neurological complications underwent surgical procedure. Most strains of *E rhusiopathiae* are resistant to glycopeptides, aminoglycosides, and cotrimoxazole but are highly susceptible to penicillin, cephalosporins, clindamycin, and ciprofloxacin [25]. Fifteen of the 16 patients received antibiotics with different regimens, often based on intravenous β -lactam (n = 14) with or without a fluoroquinolone (n = 7), followed by different oral treatments, for a median total duration of 10 weeks (from 3 to 24 weeks). Seven patients were treated with 2 antibiotics. It is noteworthy that 1 patient with a chronic native arthritis was cured by an arthroscopic lavage without antibiotics. In our case, the patient's spine remained stable without neurological impairment and he was managed with a single antibiotic regimen. Based on the MIC of the isolated strain, we chose to use intravenous amoxicillin. After 2 weeks of treatment, we switched the patient to oral antibiotics at discharge [26]. We chose a 4-week course of oral ciprofloxacin to make treatment adherence easier (2 daily intakes) while ensuring a good bone penetration [27]. Overall, all patients, including ours, were considered cured at the end of treatment, except for 1 relapse in a patient with knee monoarthritis 3 months after a 1-stage exchange and ceftriaxone treatment. The patient was finally cured with additional surgery (2-stage exchange) and 3 months of treatment with ceftriaxone and levofloxacin. All together, these results suggest that *E rhusiopathiae* OAI can be safely managed with an antibiotic monotherapy regimen based on either β -lactams or fluoroquinolones.

CONCLUSIONS

Erysipelothrix rhusiopathiae is a rare cause of OAIs, often reported in patients with debilitating conditions and with a history of exposure to the animal reservoir. It can also cause infections in healthy patients, with a delayed presentation following exposure. A single therapy with good bone diffusion may be a sufficient treatment.

Notes

Author contributions. A. M. and Y. W. reported the case and reviewed the literature. A. M., O. I., and Y. W. drafted the first version of the manuscript. All of the authors contributed to, reviewed, and approved the final manuscript. The corresponding author attests that all listed authors meet authorship criteria.

Patient consent statement. According to French law, our report does not include factors necessitating patient consent.

Potential conflicts of interest. A. B. has received congress or symposia fees from or has served as an investigator in clinical studies for Pfizer, Shionogi, Eumedica, Sanofi, Gilead, Astellas, Menarini, and Janssen. All other authors report no potential conflicts of interest. All authors have submitted the ICMJE Form for Disclosure of Potential Conflicts of Interest. Conflicts that the editors consider relevant to the content of the manuscript have been disclosed.

References

- Brooke CJ, Riley TV. *Erysipelothrix rhusiopathiae*: bacteriology, epidemiology and clinical manifestations of an occupational pathogen. *J Med Microbiol* **1999**; 48:789–99.
- Wang Q, Chang BJ, Riley TV. *Erysipelothrix rhusiopathiae*. *Vet Microbiol* **2010**; 140:405–17.
- Veraldi S, Girenti V, Dassoni F, Gianotti R. Erysipeloid: a review. *Clin Exp Dermatol* **2009**; 34:859–62.
- Hua P, Liu J, Tao J, et al. Erysipelothrix rhusiopathiae-induced aortic valve endocarditis: case report and literature review. *Int J Clin Exp Med* **2015**; 8:730–6.
- Drekonja DM. Erysipelothrix bacteremia without endocarditis: rare event or under-reported occurrence? *Diagn Microbiol Infect Dis* **2013**; 77:280–1.
- Hocqueloux L, Poisson DM, Sunder S, et al. Septic arthritis caused by *Erysipelothrix rhusiopathiae* in a prosthetic knee joint. *J Clin Microbiol* **2010**; 48:333–5.
- Dunbar SA, Clarridge JE 3rd. Potential errors in recognition of *Erysipelothrix rhusiopathiae*. *J Clin Microbiol* **2000**; 38:1302–4.
- Allianatos P, Tilentzoglou A, Koutsoukou A. Septic arthritis caused by *Erysipelothrix rhusiopathiae* infection after arthroscopically assisted anterior cruciate ligament reconstruction. *Arthroscopy* **2003**; 19:E26.
- Wong RC, Kong KO, Lin RV, Barkham T. Chronic monoarthritis of the knee in systemic lupus erythematosus. *Lupus* **2003**; 12:324–6.
- Ruiz ME, Richards JS, Kerr GS, Kan VL. *Erysipelothrix rhusiopathiae* septic arthritis. *Arthritis Rheum* **2003**; 48:1156–7.
- Traer EA, Williams MR, Keenan JN. *Erysipelothrix rhusiopathiae* infection of a total knee arthroplasty an occupational hazard. *J Arthroplasty* **2008**; 23:609–11.
- Troelsen A, Møller JK, Bolvig L, et al. Animal-associated bacteria, *Erysipelothrix rhusiopathiae*, as the cause of infection in a total hip arthroplasty. *J Arthroplasty* **2010**; 25:497.e21–3.
- Mukhopadhyay C, Shah H, Vandana KE, et al. A child with *Erysipelothrix* arthritis—beware of the little known. *Asian Pac J Trop Biomed* **2012**; 2:503–4.
- Gazeau P, Rezig S, Quaeset L, et al. *Erysipelothrix rhusiopathiae* knee prosthesis infection. *Med Mal Infect* **2018**; 48:372–3.
- Groeschel M, Forde T, Turvey S, et al. An unusual case of *Erysipelothrix rhusiopathiae* prosthetic joint infection from the Canadian Arctic: whole genome sequencing unable to identify a zoonotic source. *BMC Infect Dis* **2019**; 19:282.
- Bianchi-Llave JL, Pérez-Barrio MP, Borrego-Utiel FJ, Liébana-Cañada A. Septic arthritis caused by *Erysipelothrix rhusiopathiae*. *Enferm Infecc Microbiol Clin* **1996**; 14:452–3.
- Denes E, Camilleri Y, Fiorenza F, Martin C. First case of osteomyelitis due to *Erysipelothrix rhusiopathiae*: pubic osteomyelitis in a gored farmer. *Int J Infect Dis* **2015**; 30:133–4.
- Lorenz ML, Bouton TC, Caliendo AM. First reported case of vertebral osteomyelitis due to *Erysipelothrix rhusiopathiae*. *IDCases* **2018**; 11:3–5.
- Romney M, Cheung S, Montessori V. *Erysipelothrix rhusiopathiae* endocarditis and presumed osteomyelitis. *Can J Infect Dis* **2001**; 12:254–6.
- Belmenouar O, Benahmed A, Hamon R, Arezki E, Beileu DH, Saad H. Spondylodiscite cervicale à *Erysipelothrix rhusiopathiae* chez un cuisinier. *La Revue de Médecine Interne* **2018**; 39:A134.
- Andrychowski J, Jasielski P, Netczuk T, Czernicki Z. Empyema in spinal canal in thoracic region, abscesses in paravertebral space, spondylitis: in clinical course of zoonosis *Erysipelothrix rhusiopathiae*. *Eur Spine J* **2012**; 21(Suppl 4):S557–63.
- Shimoji Y. Pathogenicity of *Erysipelothrix rhusiopathiae*: virulence factors and protective immunity. *Microbes Infect* **2000**; 2:965–72.
- Shimoji Y, Ogawa Y, Osaki M, et al. Adhesive surface proteins of *Erysipelothrix rhusiopathiae* bind to polystyrene, fibronectin, and type I and IV collagens. *J Bacteriol* **2003**; 185:2739–48.
- Arora S, Gordon J, Hook M. Collagen binding proteins of gram-positive pathogens. *Front Microbiol* **2021**; 12:628798.
- Venditti M, Gelfusa V, Tarasi A, et al. Antimicrobial susceptibilities of *Erysipelothrix rhusiopathiae*. *Antimicrob Agents Chemother* **1990**; 34:2038–40.
- Couderc M, Bart G, Coiffier G, et al. Recommandations françaises 2020 sur la prise en charge des arthrites septiques sur articulation native de l'adulte. *Revue du Rhumatisme* **2020**; 87:428–38.
- Landersdorfer CB, Bulitta JB, Kinzig M, et al. Penetration of antibacterials into bone: pharmacokinetic, pharmacodynamic and bioanalytical considerations. *Clin Pharmacokinet* **2009**; 48:89–124.