



HAL
open science

Adult Cerebellar Ataxia, Axonal Neuropathy, and Sensory Impairments Caused by Biallelic SCO2 Variants

Benoit Rucheton, Claire Ewencyk, Pauline Gaignard, Jean-Madeleine de Sainte Agathe, Anne-Laure Fauret, Virginie Saillour, Sarah Leonard-Louis, Valerie Touitou, Fanny Mochel

► **To cite this version:**

Benoit Rucheton, Claire Ewencyk, Pauline Gaignard, Jean-Madeleine de Sainte Agathe, Anne-Laure Fauret, et al.. Adult Cerebellar Ataxia, Axonal Neuropathy, and Sensory Impairments Caused by Biallelic SCO2 Variants. *Neurology Genetics*, 2021, 7 (6), pp.e630. 10.1212/nxg.0000000000000630 . hal-03426463

HAL Id: hal-03426463

<https://hal.sorbonne-universite.fr/hal-03426463>

Submitted on 12 Nov 2021

HAL is a multi-disciplinary open access archive for the deposit and dissemination of scientific research documents, whether they are published or not. The documents may come from teaching and research institutions in France or abroad, or from public or private research centers.

L'archive ouverte pluridisciplinaire **HAL**, est destinée au dépôt et à la diffusion de documents scientifiques de niveau recherche, publiés ou non, émanant des établissements d'enseignement et de recherche français ou étrangers, des laboratoires publics ou privés.

Adult Cerebellar Ataxia, Axonal Neuropathy, and Sensory Impairments Caused by Biallelic *SCO2* Variants

Benoit Rucheton, PharmD,* Claire Ewencyk, MD, PhD,* Pauline Gagnard, PharmD, PhD, Jean-Madeleine de Sainte Agathe, MD, Anne-Laure Fauret, PharmD, PhD, Virginie Saillour, PhD, Sarah Leonard-Louis, MD, PhD, Valerie Toutou, MD, PhD, and Fanny Mochel, MD, PhD

Correspondence

Dr. Mochel
fanny.mochel@upmc.fr

Neurol Genet 2021;7:e630. doi:10.1212/NXG.0000000000000630

SCO2 encodes a 266-amino-acid metallochaperone involved in copper supply for the assembly of cytochrome c oxidase or complex IV (CIV). CIV is the terminal enzyme of the energy-transducing respiratory chain that transfers electrons from reduced cytochrome c to oxygen via 3 copper ions.¹ *SCO2* pathogenic variants were first identified in children with hypertrophic cardiomyopathy, often associated with developmental delay and lactic acidosis² (Figure, A). *SCO2* variants were then reported in children with Leigh syndrome³ and early-onset axonal neuropathy,⁴ possibly associated with cerebellar ataxia⁵ (Figure, A). Here, we report heterozygous missense *SCO2* variants in a 48-year-old patient presenting with a complex neurologic and sensory phenotype comprising cerebellar ataxia, sensory neuronopathy, deafness, pigmentary retinopathy, and cataract.

Case Presentation

Our patient's family history was unremarkable except for hearing loss in his father in his third decade. At age 40 years, our patient was diagnosed with left hearing loss. At age 41 years, he developed slowly progressive gait abnormalities. At age 45 years, he reported vision impairment with prominent hemeralopia, memory loss, and painful legs at night. Neurologic examination at age 45 years revealed moderate cerebellar ataxia—score of 12/40 on the Scale for the Assessment and Rating of Ataxia—, areflexia, and a positive Romberg sign. Brain MRI showed bilateral supratentorial white matter abnormalities and cortical atrophy (eFigures 1, links.lww.com/NXG/A477). Nerve conduction studies revealed a severe bilateral axonal sensitive neuropathy of the 4 limbs. Audiometry showed bilateral perceptive hypoacusis.

Our patient had normal 20/20 visual acuity, but slit lamp examination demonstrated atypical bilateral lens inclusions with opacities. Fundus examination appeared grossly normal, but autofluorescence of the fundus revealed bilateral hyper-autofluorescence of the posterior pole and a patchy area of peripheral hyper fluorescence in the left eye. High-definition optical coherence tomography (OCT) disclosed bilateral hyper reflectivity of the retro-foveal region, located just below the ellipsoid line, with heterogeneity of the photoreceptor line. The electroretinogram revealed alteration of retinal electrogenesis in scotopic conditions consistent with the alterations observed on OCT (Figure, B).

*These authors contributed equally.

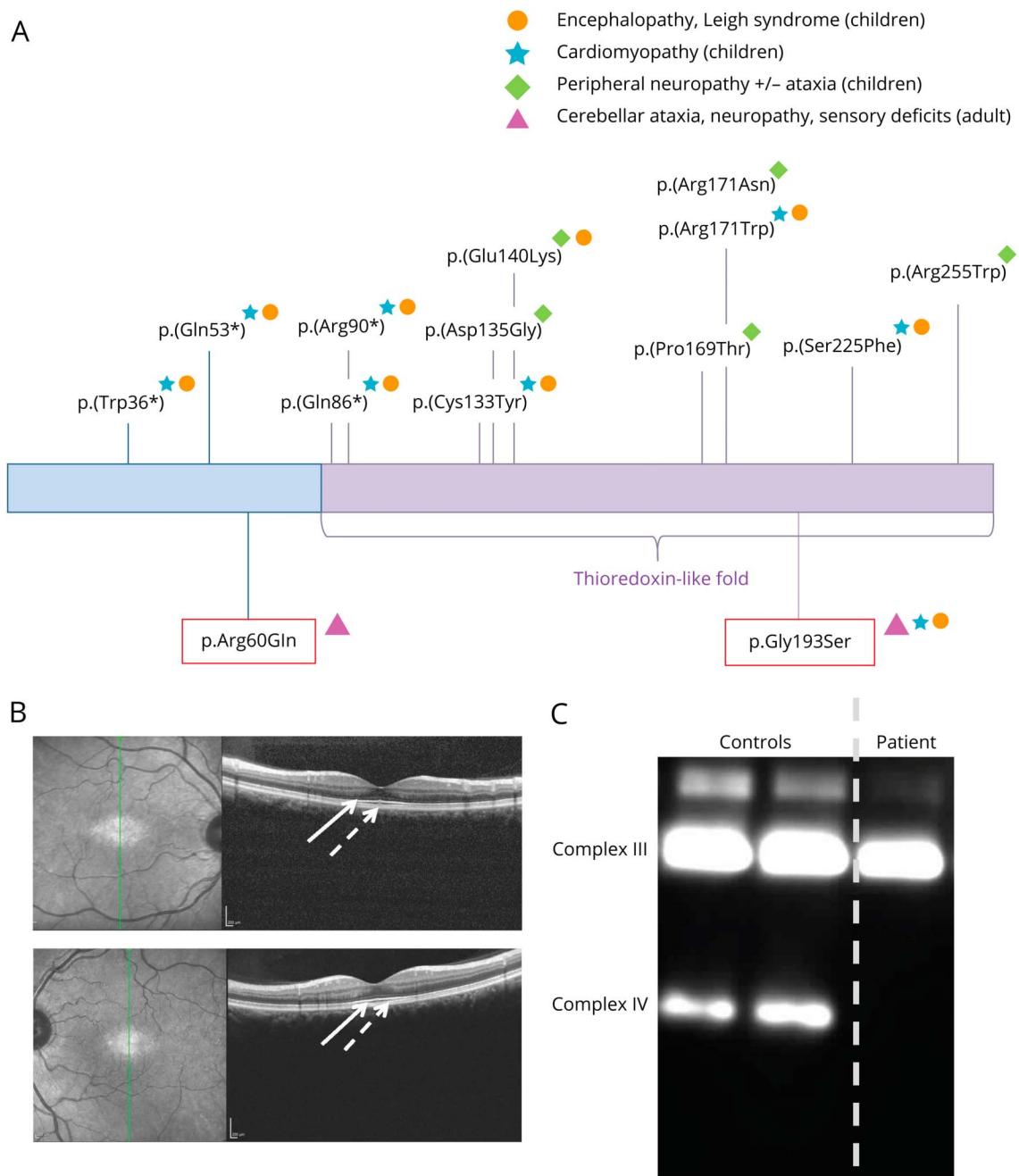
From the AP-HP (B.R.), Groupe Hospitalier Pitié-Salpêtrière, Unité Fonctionnelle Cardiogénétique et Myogénétique Moléculaire et Cellulaire; AP-HP (C.E., F.M.), Groupe Hospitalier Pitié-Salpêtrière, Département de Génétique; Laboratoire de biologie médicale multisites SeqOIA—FMG2025 (B.R., P.G., J.-M.S.A., A.-L.F., V.S.); AP-HP (P.G.), Université Paris Saclay, CHU Bicêtre, Service de Biochimie, Bicêtre; AP-HP (J.-M.S.A., A.-L.F.), Groupe Hospitalier Pitié-Salpêtrière, Unité Fonctionnelle de Neurogénétique; AP-HP (S.L.-L.), Groupe Hospitalier Pitié-Salpêtrière, Laboratoire de Neuropathologie; AP-HP (V.T.), Groupe Hospitalier Pitié-Salpêtrière Département d'Ophthalmologie, DHU Vision et Handicaps; and Institut du Cerveau (ICM) (F.M.), Sorbonne Université, UMR S 1127, Inserm U1127, CNRS UMR 7225, Paris, France.

Go to Neurology.org/NG for full disclosures. Funding information is provided at the end of the article.

The Article Processing Charge was funded by Pitié-Salpêtrière Hospital.

This is an open access article distributed under the terms of the Creative Commons Attribution-NonCommercial-NoDerivatives License 4.0 (CC BY-NC-ND), which permits downloading and sharing the work provided it is properly cited. The work cannot be changed in any way or used commercially without permission from the journal.

Figure Pathogenic *SCO2* Variants and Key Findings in Our *SCO2*-Deficient Patient



(A) Pathogenic *SCO2* variants and related phenotypes. Underlined: previously reported variants; red box: variants of the presented case. (B) High-definition optical coherence tomography of the right (top) and left (bottom) eye, demonstrating bilateral hyper reflectivity of the retro-foveal area (plain arrow), located just below the ellipsoid line, with heterogeneity of the photoreceptor line (dashed arrow). (C) Blue native polyacrylamide gel electrophoresis (BN-PAGE) analysis of mitochondrial enriched fibroblasts of the *SCO2*-deficient patient and two controls using antibodies against respiratory chain complex subunits (complex III: UQCRC2; complex IV: MTCO1 and MTCO2).

CK enzymes were mildly but constantly elevated (range 320–376 U/L, N = 25–195 U/L). Metabolic investigations were normal, as well as molecular analyses of *ATXN 1, 2, 3, 6, 7, and 17, FXN, and NOPS6*. Muscle biopsy showed a few fibers with lipid overload (i.e., lipid droplets) and a few COX negative or pale fibers. Spectrophotometric determination of mitochondrial respiratory chain enzyme activities as a ratio to citrate synthase activity showed

isolated decreased activities of CIV in muscle and fibroblasts (Table).

We then analyzed our patient's leukocyte genomic DNA, after informed consent was obtained, using a next-generation sequencing panel (Roche NibelGen, Madison, WI), comprising the entire coding region and exon-intron junctions of 244 genes associated with mitochondrial diseases, and identified 2

Table Spectrophotometric Assays of Respiratory Chain Activities in Muscle and Fibroblasts

	Muscle	Muscle range	Fibroblasts	Fibroblast range
Activities^a				
CI total	71 ↑	27–53	/	/
CI rotenone sensitive	67 ↑	22–48	/	/
CII	61 ↑	25–45	27 ↑	11–19
CII + CIII	57 ↑	26–42	25	14–29
CIII total	291 ↑	184–242		
CIII antimycin A sensitive	213 ↑	92–166	98 ↑	33–67
CIV	181	109–193	19 ↓	41–81
CS	320 ↑	150–250	54	31–65
Ratios				
CI/CS	0.21	0.13–0.25	/	/
CII/CS	0.19	0.13–0.25	0.50 ↑	0.24–0.38
CIII/CS	0.67	0.55–0.89	1.81 ↑	0.75–1.48
CIV/CS	0.57 ↓	0.65–1.03	0.35 ↓	0.93–1.56

Abbreviation: CIV = complex IV.
Values in bold represent either increased or decreased activities compared with normal ranges.
^a mmol/min/mg protein.

heterozygous missense variants in *SCO2* (NM_005138.3: c.[179G>A];[577G>A]) (Figure, A and eFigure 2, links.lww.com/NXG/A478): (1) a variant of unknown significance—ACMG grading (PM2, PM3, PP2, and BP4)—, c.179G>A p.(Arg60Gln), which modifies a conserved amino acid of the N-terminal domain and predicted as possibly pathogenic by Polyphen; and (2) the c.577G>A p.(Gly193Ser) variant, reported as pathogenic and associated with infantile cardioencephalopathy.⁶ Each parent was heterozygous for a *SCO2* variant. Blue native polyacrylamide gel electrophoresis on the patient's fibroblasts showed an almost complete absence of the CIV band, confirming isolated CIV deficiency (Figure, C). Given the discrepancy between our patient's phenotype and all pediatric patients reported so far with *SCO2* deficiency, the patient and his parents underwent whole-genome sequencing. These independent analyses retrieved both *SCO2* variants, but no other known pathogenic variants associated with cerebellar ataxia, peripheral neuropathy, hearing loss, or retinopathy.

Discussion

We present an adult-onset form of CIV deficiency related to biallelic *SCO2* variants manifesting with a slowly progressive cerebellar ataxia after age 40 years, an axonal sensitive polyneuropathy, and bilateral sensory deficits with deafness, pigmentary retinopathy, and cataract.

Most of the damages caused by CIV deficiency are early and fatal, as reported so far with *SCO2* pathogenic variants with pediatric and rapidly progressive disorders^{2–4} except for 2 children with a slower neurologic course.⁵ A possible explanation for the moderate phenotype of our patient relates to his genotype as he carries 2 missense variants, only 1 of which is located in the thioredoxin domain. Instead, pediatric cases carry either 2 missense variants in the thioredoxin domain or the association of one missense variant in the thioredoxin domain with a truncating variant (Figure, A). Unlike pediatric cases, our patient displayed both hearing and vision impairments with pigmentary retinopathy. Of interest, heterozygous *SCO2* variants were also identified in dominant forms of severe myopia.⁷

Acknowledgment

The authors thank Sandrine Filaut et Laura Legrand for their help with NGS.

Study Funding

No targeted funding reported.

Disclosure

The authors report no disclosures relevant to the manuscript. Go to Neurology.org/NG for full disclosures.

Publication History

Received by *Neurology: Genetics* July 16, 2021. Accepted in final form August 12, 2021.

References

1. Banci L, Bertini I, Ciofi-Baffoni S, et al. A structural characterization of human *SCO2*. *Structure*. 2007;15(9):1132–1140.
2. Sacconi S, Salviati L, Sue CM, et al. Mutation screening in patients with isolated cytochrome c oxidase deficiency. *Pediatr Res*. 2003;53(2):224–230.
3. Szymanska-Debinska T, Karkucinska-Wieckowska A, Piekutowska-Abramczuk D, et al. Leigh disease due to *SCO2* mutations revealed at extended autopsy. *J Clin Pathol*. 2015;68(5):397–399.
4. Rebelo AP, Saade D, Pereira CV, et al. *SCO2* mutations cause early-onset axonal Charcot-Marie-Tooth disease associated with cellular copper deficiency. *Brain*. 2018; 141(3):662–672.
5. Barcia G, Assouline Z, Pennisi A, et al. Cytochrome c oxidase deficiency caused by biallelic *SCO2* mutations in two sibs with cerebellar ataxia and progressive peripheral axonal neuropathy. *Mol Genet Metab Rep*. 2019; 21:100528.
6. Mobley BC, Enns GM, Wong LJ, Vogel H. A novel homozygous *SCO2* mutation, p.G193S, causing fatal infantile cardioencephalomyopathy. *Clin Neuropathol*. 2009;28(2):143–149.
7. Tran-Viet KN, Powell C, Barathi VA, et al. Mutations in *SCO2* are associated with autosomal-dominant high-grade myopia. *Am J Hum Genet*. 2013;92(5):820–826.

Neurology[®] Genetics

Adult Cerebellar Ataxia, Axonal Neuropathy, and Sensory Impairments Caused by Biallelic *SCO2* Variants

Benoit Rucheton, Claire Ewencyk, Pauline Gaignard, et al.

Neurol Genet 2021;7;

DOI 10.1212/NXG.0000000000000630

This information is current as of November 4, 2021

Neurol Genet is an official journal of the American Academy of Neurology. Published since April 2015, it is an open-access, online-only, continuous publication journal. Copyright © 2021 The Author(s). Published by Wolters Kluwer Health, Inc. on behalf of the American Academy of Neurology. All rights reserved. Online ISSN: 2376-7839.



Updated Information & Services	including high resolution figures, can be found at: http://ng.neurology.org/content/7/6/e630.full.html
References	This article cites 7 articles, 1 of which you can access for free at: http://ng.neurology.org/content/7/6/e630.full.html##ref-list-1
Subspecialty Collections	This article, along with others on similar topics, appears in the following collection(s): All Genetics http://ng.neurology.org/cgi/collection/all_genetics Mitochondrial disorders http://ng.neurology.org/cgi/collection/mitochondrial_disorders Peripheral neuropathy http://ng.neurology.org/cgi/collection/peripheral_neuropathy Retina http://ng.neurology.org/cgi/collection/retina Spinocerebellar ataxia http://ng.neurology.org/cgi/collection/spinocerebellar_ataxia
Permissions & Licensing	Information about reproducing this article in parts (figures, tables) or in its entirety can be found online at: http://ng.neurology.org/misc/about.xhtml#permissions
Reprints	Information about ordering reprints can be found online: http://ng.neurology.org/misc/addir.xhtml#reprintsus

Neurol Genet is an official journal of the American Academy of Neurology. Published since April 2015, it is an open-access, online-only, continuous publication journal. Copyright © 2021 The Author(s). Published by Wolters Kluwer Health, Inc. on behalf of the American Academy of Neurology. All rights reserved. Online ISSN: 2376-7839.

