



**HAL**  
open science

## **COVID-19 and thrombotic microangiopathy**

E. V Sluhanchuk, Viktoria O Bitsadze, Jamilya Kh Khizroeva, Maria V Tretyakova, Andrey S Shkoda, Oleg P Artyukov, Valentina I Tsibizova, Alexander L Mishchenko, Kristina N Grigorieva, J.-K. Gris, et al.

► **To cite this version:**

E. V Sluhanchuk, Viktoria O Bitsadze, Jamilya Kh Khizroeva, Maria V Tretyakova, Andrey S Shkoda, et al.. COVID-19 and thrombotic microangiopathy. Akuserstvo, Ginekologia i Reprodukcia, 2020, 10.17749/2313-7347/ob.gyn.rep.2021.265 . hal-03448355

**HAL Id: hal-03448355**

**<https://hal.sorbonne-universite.fr/hal-03448355v1>**

Submitted on 25 Nov 2021

**HAL** is a multi-disciplinary open access archive for the deposit and dissemination of scientific research documents, whether they are published or not. The documents may come from teaching and research institutions in France or abroad, or from public or private research centers.

L'archive ouverte pluridisciplinaire **HAL**, est destinée au dépôt et à la diffusion de documents scientifiques de niveau recherche, publiés ou non, émanant des établissements d'enseignement et de recherche français ou étrangers, des laboratoires publics ou privés.



## COVID-19 and thrombotic microangiopathy

Ekaterina V. Slukhanchuk<sup>1,2</sup>, Viktoria O. Bitsadze<sup>1</sup>, Jamilya Kh. Khizroeva<sup>1</sup>, Maria V. Tretyakova<sup>1</sup>,  
Andrey S. Shkoda<sup>3</sup>, Oleg P. Artyukov<sup>4</sup>, Valentina I. Tsibizova<sup>5</sup>, Alexander L. Mishchenko<sup>1</sup>,  
Kristina N. Grigorieva<sup>1</sup>, Jean-Christophe Gris<sup>1,6</sup>, Ismail Elalamy<sup>1,7,8</sup>, Alexander D. Makatsariya<sup>1</sup>

<sup>1</sup>Sechenov University; 2 bldg. 4, Bolshaya Pirogovskaya Str., Moscow 119991, Russia;

<sup>2</sup>Petrovsky National Research Centre of Surgery; 2 Abrikosovskiy Lane, Moscow 119991, Russia;

<sup>3</sup>Vorokhobov City Clinical Hospital № 67, Moscow Healthcare Department;

2/44 Salyama Adilya Str., Moscow 123423, Russia;

<sup>4</sup>Peoples' Friendship University of Russia; 6 Miklukho-Maklaya Str., Moscow 117198, Russia;

<sup>5</sup>Almazov National Medical Research Centre, Health Ministry of Russian Federation;

2 Akkuratova Str., Saint Petersburg 197341, Russia;

<sup>6</sup>University of Montpellier; 163 Rue Auguste Broussonnet, Montpellier 34090, France;

<sup>7</sup>Medicine Sorbonne University; 12 Rue de l'École de Médecine, 75006 Paris, France;

<sup>8</sup>Hospital Tenon; 4 Rue de la Chine, 75020 Paris, France

**Corresponding author:** Ekaterina V. Slukhanchuk, e-mail: [beloborodova@rambler.ru](mailto:beloborodova@rambler.ru)

### Abstract

As shown by numerous studies conducted during the pandemic, the severe course of COVID-19 is accompanied by multiple organ failure. Cytokine storm, hypercoagulation, complement hyperactivation and other arms comprise the overall picture of the pathogenesis of the severe disease course. The frequent diagnosis of multiple microvascular thrombosis in lung, heart, and kidneys, as well as the presence of platelet-fibrin thrombi there and signs of terminal organ damage, suggest a possible involvement of thrombotic microangiopathy (TMA) in the development of multiple organ failure. In this regard, it is especially important to timely diagnose TMA and start pathogenetic therapy. These measures can significantly reduce mortality due to the novel disease. Heparins and direct oral anticoagulants are the mainstay for prevention and treatment of venous thromboembolism in patients with COVID-19, but their effectiveness in the presence of TMA is questionable. It has been proven that anticoagulants use in critically ill patients with COVID-19 for

---

We are providing this an author-produced version to give early visibility of the article. This manuscript has been accepted for publication and undergone full peer review but has not been through the copyediting, typesetting, pagination and proofreading process, which may lead to differences between this version and the final typeset and edited version of the article.

Мы предоставляем данную авторскую версию для обеспечения раннего доступа к статье. Эта рукопись была принята к публикации и прошла процесс рецензирования, но не прошла процесс редактирования, верстки, присвоения порядковой нумерации и корректуры, что может привести к различиям между данной версией и окончательной отредактированной версией статьи.

prevention of large vessel thrombosis is effective, but their role in the prevention of microthrombosis is not clear. Here we review the currently available information on thrombotic microangiopathy, as well as a review of literature data describing TMA-like conditions in COVID-19, discuss potential pathophysiology of the condition development and proposed therapeutic approaches.

**Key words:** thrombotic microangiopathy, thrombotic thrombocytopenic purpura, COVID-19, ADAMTS-13, thrombocytopenia, von Willebrand factor

**For citation:** Sluhanchuk E.V., Bitsadze V.O., Khizroeva J.Kh., Tretyakova M.V., Shkoda A.S., Artyukov O.P., Tsibizova V.I., Mishchenko A.L., Grigorieva K.N., Gris J.-K., Elalamy E., Makatsariya A.D. COVID-19 and thrombotic microangiopathy. *Akusherstvo, Ginekologia i Reprodukcija = Obstetrics, Gynecology and Reproduction*. 2021;[accepted manuscript]. <https://doi.org/10.17749/2313-7347/ob.gyn.rep.2021.265>.

## COVID-19 и тромботическая микроангиопатия

Е.В. Слуханчук<sup>1,2</sup>, В.О. Бицадзе<sup>1</sup>, Д.Х. Хизроева<sup>1</sup>, М.В. Третьякова<sup>1</sup>, А.С. Шкода<sup>3</sup>,  
О.П. Артюков<sup>4</sup>, В.И. Цибизова<sup>5</sup>, А.Л. Мищенко<sup>1</sup>, К.Н. Григорьева<sup>1</sup>,  
Ж.-К. Гри<sup>1,6</sup>, И. Элалами<sup>1,7,8</sup>, А.Д. Макацария<sup>1</sup>

<sup>1</sup>ФГАОУ ВО Первый Московский государственный медицинский университет имени И.М. Сеченова Министерства здравоохранения Российской Федерации (Сеченовский Университет); Россия, 119991 Москва, ул. Большая Пироговская, д. 2, стр. 4;

<sup>2</sup>ФГБНУ «Российский научный центр хирургии имени академика Б.В. Петровского»; Россия, 119991 Москва, Абрикосовский пер., д. 2;

<sup>3</sup>ГБУЗ «Городская клиническая больница № 67 имени Л.А. Ворохобова Департамента здравоохранения города Москвы»; Россия, 123423 Москва, ул. Саляма Адила, д. 2/44;

<sup>4</sup>ФГАОУ ВО «Российский университет дружбы народов»; Россия, 117198 Москва, ул. Миклухо-Маклая, д. 6;

<sup>5</sup>ФГБУ «Национальный медицинский исследовательский центр имени В.А. Алмазова» Министерства здравоохранения Российской Федерации; Россия, 197341 Санкт-Петербург, ул. Аккуратова, д. 2;

<sup>6</sup>Университет Монпелье; Франция, 34090 Монпелье, ул. Огюста Бруссоне, д. 163;

<sup>7</sup>Медицинский Университет Сорбонны; Франция, 75006 Париж, Улица медицинского факультета, д. 12;

<sup>8</sup>Госпиталь Тенон; Франция, 75020 Париж, Китайская улица, д. 4

*Для контактов:* Екатерина Викторовна Слуханчук, e-mail: [beloborodova@rambler.ru](mailto:beloborodova@rambler.ru)

**Резюме**

Как было показано многочисленными исследованиями, проведенными в период пандемии, тяжелое течение COVID-19 сопровождается полиорганной недостаточностью. Цитокиновый шторм, гиперкоагуляция, гиперактивация комплемента и другие звенья гемостаза составляют общую картину патогенеза тяжелого течения заболевания. Частая диагностика множественных тромбозов микрососудистого русла в таких органах как легкие, сердце и почки, а также присутствие тромбоцитарно-фибриновых тромбов в этих органах и признаки их терминального повреждения наводят на мысль о возможном участии тромботической микроангиопатии (ТМА) в развитии полиорганной недостаточности. В этой связи особенно важно своевременно диагностировать ТМА и начинать патогенетическую терапию. Эти мероприятия способны значительно снизить смертность от нового заболевания. Гепарины и прямые пероральные антикоагулянты являются основой профилактики и лечения венозной тромбоэмболии у пациентов с COVID-19, однако их эффективность при наличии ТМА сомнительна. Доказано, что использование антикоагулянтов у тяжелобольных пациентов с COVID-19 для профилактики тромбоза крупных сосудов эффективно, однако их роль в предотвращении микротромбообразования не ясна. В данной статье проводится обзор имеющейся в настоящее время информации о ТМА, а также обзор данных литературы, описывающих ТМА-подобные состояния при COVID-19, обсуждается возможная патофизиология развития состояния и предполагаемые подходы к терапии.

**Ключевые слова:** тромботическая микроангиопатия, ТМА, тромботическая тромбоцитопеническая пурпура, COVID-19, ADAMTS-13, тромбоцитопения, фактор фон Виллебранда

**Для цитирования:** Слуханчук Е.В., Бицадзе В.О., Хизроева Д.Х., Третьякова М.В., Шкода А.С., Артюков О.П., Цибизова В.И., Мищенко А.Л., Григорьева К.Н., Гри Ж.-К., Элалами Э., Макацария А.Д. COVID-19 и тромботическая микроангиопатия. *Акушерство, Гинекология и Репродукция*. 2021;[принятая рукопись]. <https://doi.org/10.17749/2313-7347/ob.gyn.rep.2021.265>.

Highlights	Основные моменты
What is already known about this subject?	Что уже известно об этой теме?
Numerous studies have shown that the severe course of COVID-19 is accompanied by multiple organ failure. Cytokine storm, hypercoagulation, complement hyperactivation and other processes constitute the pathogenesis of severe course. The frequent detection of multiple microthrombosis in lungs, heart and kidneys, which is often the cause of their terminal damage, suggests a possible addition of thrombotic microangiopathy (TMA) in patients with multiple organ failure.	Многочисленными исследованиями было показано, что тяжелое течение COVID-19 сопровождается полиорганной недостаточностью. Цитокиновый шторм, гиперкоагуляция, гиперактивация комплемента и другие процессы составляют патогенез тяжелого течения. Частое выявление множественных микротромбозов в легких, сердце и почках, зачастую являющихся причиной их терминального повреждения, наводят на мысль о возможном присоединении тромботической микроангиопатии (ТМА) у пациентов с полиорганной недостаточностью.

<b>What are the new findings?</b>	<b>Что нового дает статья?</b>
The article provides a review on the information currently available in the literature on TMA, as well as a review of data on TMA-like conditions in COVID-19, discusses the potential pathophysiology for its development and proposed approaches to therapy.	В статье проводится обзор имеющейся в настоящее время в литературе информации о TMA, а также обзор данных о TMA-подобных состояниях при COVID-19, обсуждается возможная патофизиология развития состояния и предполагаемые подходы к терапии.
<b>How might it impact on clinical practice in the foreseeable future?</b>	<b>Как это может повлиять на клиническую практику в обозримом будущем?</b>
In the setting when TMA does occur, it is extremely important to timely start pathogenetic therapy, which can significantly reduce mortality. Heparins and direct oral anticoagulants are the mainstay for preventing and treating venous thromboembolism in patients with COVID-19, but their effectiveness in the presence of TMA is questionable. The development of this topic can lead to creation of new protocols for management of severe forms of the disease, taking into account the data obtained.	В ситуации, когда TMA действительно имеет место, крайне важно своевременное начало патогенетической терапии, которая способна значительно снизить смертность. Гепарины и прямые пероральные антикоагулянты являются основой профилактики и лечения венозной тромбоземболии у пациентов с COVID-19; однако их эффективность при наличии TMA сомнительна. Разработка данной темы способна привести к созданию новых протоколов ведения тяжелых форм заболевания с учетом полученных данных.

## **Introduction / Введение**

The novel coronavirus disease (COVID-19) pandemic has been developing exponentially since December 2019. The virus responsible for developing acute respiratory syndrome 2 (SARS-CoV-2) belongs to the coronaviridae family (a group of single-stranded positive-sense RNA viruses). It was initially thought that the virus infects only the respiratory tract. However, later, a multiple organ cause of the disease manifested itself, especially in severe cases, with the development of coagulopathy, renal failure, liver dysfunction, arrhythmias, and heart failure [1]. A severe course is more common in older patients, as well as in those suffering from comorbidities.

At the autopsy of patients who died from COVID-19, frequent capillary thrombosis in the lungs, heart, kidneys was detected [2]. The presence of platelet-fibrin thrombi in target organs and signs of their terminal damage suggest that thrombotic microangiopathy (TMA) is involved in the process.

The pathophysiology of this viral infection has been investigated since then. We currently know that the glycoprotein spike on the surface of the SARS-CoV-2 virus interacts with angiotensin-converting enzyme-2 (ACE-2) receptors on the cell surface of various human organs, including the epithelium of the respiratory tract, macrophages, and cardiomyocytes [3]. By activating the receptor, the virus enters cell and starts replication, cell lysis, initiates an inflammatory response with increased concentration of pro-inflammatory cytokines, including interleukins (IL) – IL-6, IL-1, IL-7, IL-8, etc., various glycoproteins – granulocyte colony-stimulating factor (G-CSF), granulocyte-macrophage colony-stimulating factor (GM-CSF), fibroblast growth factor (FGF), vascular endothelial growth factor (VEGF), etc. and acute phase

proteins – procalcitonin, C-reactive protein, fibrinogen, etc. In some cases, systemic inflammation turns into a cytokine storm, followed by coagulopathy. Upon further progression, it starts as an endotheliopathy, the formation of antiphospholipid antibodies, followed by disseminated thrombogenesis [4, 5]. However, there may be other elements in microthrombosis, particularly the TMA, which is evidenced by several publications available in the literature.

## **Thrombotic microangiopathy. History. Main characteristics / Тромботическая микроангиопатия. История вопроса. Основные характеристики**

Thrombotic microangiopathies are a group of diseases characterized by thrombocytopenia, microangiopathic hemolytic anemia (MAGA), and microthrombosis in target organs [6].

### **Thrombotic thrombocytopenic purpura / Тромботическая тромбоцитопеническая пурпура**

Clinically, thrombotic thrombocytopenic purpura (TTP) is manifested by hemolytic anemia, petechial rash, bleeding from genitourinary, gastrointestinal tracts, etc. There may also be nausea, vomiting, and diarrhea [7], neurological disorders (headache, visual impairment, personality disorders, aphasia, coma, hemiparesis, etc.) [8]. Microthrombosis in TTP is found in the kidneys, heart, brain, pancreas, adrenal glands, skin, spleen, and bone marrow. Myocardial infarction, pancreatitis, mesenteric thrombosis, and other symptoms atypical for TTP may also occur in the TTP clinic.

Autoantibodies cause TTP due to alteration in ADAMTS-13 (a disintegrin and metalloproteinase with a thrombospondin type 1 motif, member 13), a plasma metalloproteinase that cleaves von Willebrand factor (vWF) typically and regulates vWF-dependent platelet aggregation. There is a hereditary form of ADAMTS-13 deficiency, leading to the development of congenital TTP.

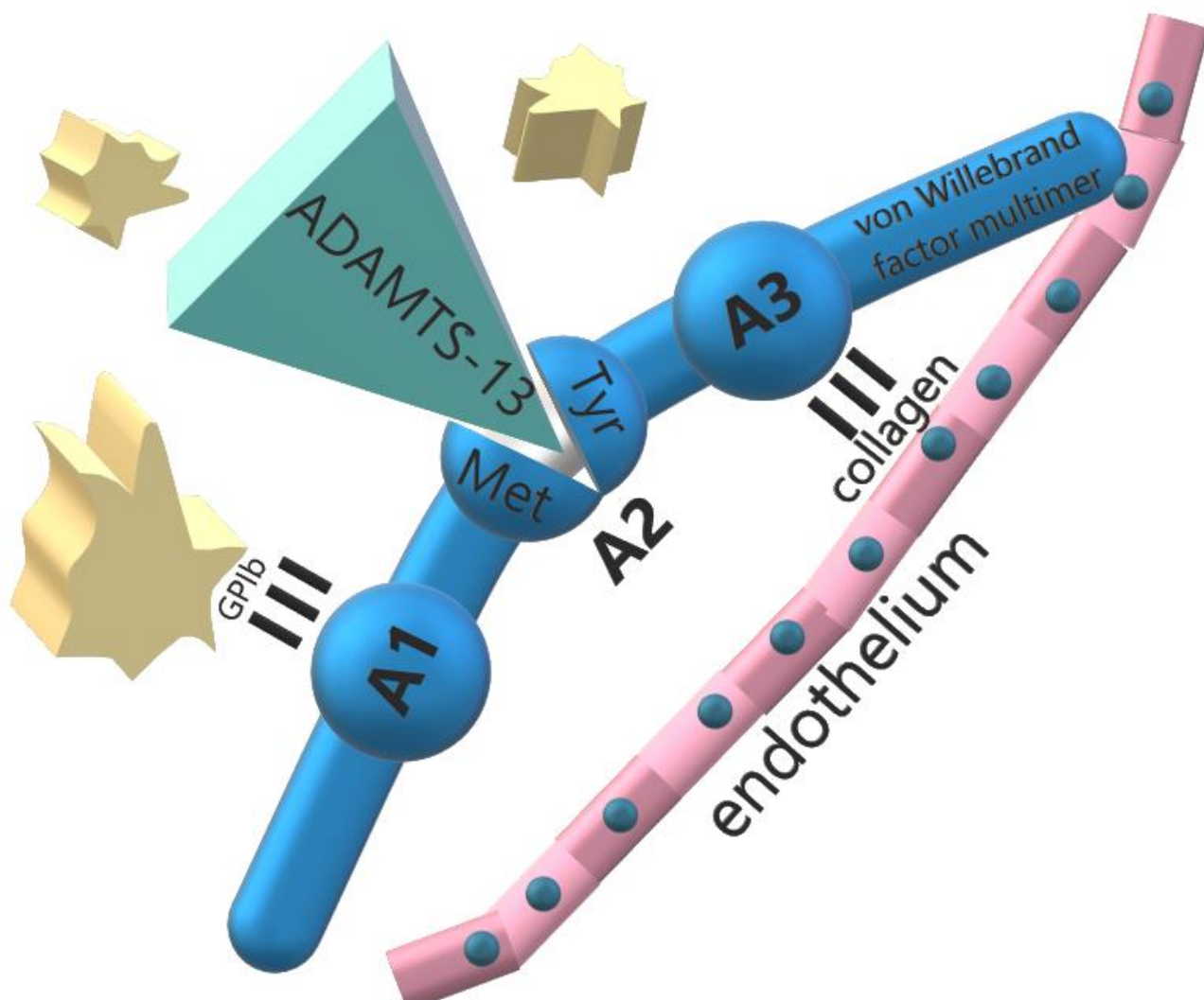
Eli Moschcowitz first described TTP in 1924 [9]. A 16-year-old patient with fever, severe anemia, leukocytosis, petechial rash and hemiparesis, normal renal function (despite albumin, hyaline casts in the urine) fell into a coma and died two weeks after the onset of the first symptoms. The autopsy revealed many hyaline thrombi in the terminal arterioles and capillaries of the heart and kidneys. For many years, this disease was called Moshkovitz's disease. In 1947, it was named thrombocytopenic purpura [10]. In 1966, a review of 272 cases was published, in which the main clinical signs of the disease were identified [11]. Most of the patients were women aged 10 to 39 years. Clinical features included thrombocytopenia, hemolytic anemia with multiple fragmented red blood cells or schistocytes, neurologic abnormalities, kidney damage, and fever. The mortality rate from the disease exceeded 90 %; the median length of hospital stay was only 14 days before death,

and 80 % of patients lived less than 90 days after the onset of symptoms. However, in some cases, there have been episodes of recovery after splenectomy. In 1976, whole blood transfusions began to be used as a therapeutic measure, which caused rapid remission in 8 out of 14 patients [12]. Similar results were obtained after plasmapheresis with plasma replacement [13]. The study showed that plasmapheresis is effective only when plasma is the replacement fluid and is ineffective when only albumin is replaced. In addition, it turned out that even simple plasma infusions without plasmapheresis can induce stable remission, which suggests the need to introduce the missing plasma factor [14].

The relationship between TTP and vWF was identified in 1982 based on studies of the four patients with chronic relapsing disease [15]. Their plasma vWF multimers were much more significant than healthy individuals and matched in size to the vWF multimers secreted by endothelial cells. It was suggested that patients with TTP lack depolymerase activity, possibly a protease or reductase, which shortens the newly synthesized vWF multimers *in vivo* and is involved in the normal distribution of multimers in blood plasma. The absence of this depolymerase results in the maintenance of an “unusually large” vWF, which contributes to excessive intravascular platelet aggregation, thrombocytopenia, and microvascular thrombosis. Plasma exchange therapy provides the missing depolymerase.

In 1996, a candidate depolymerase was identified [16]. Shortly after that, a hereditary deficiency of this metalloproteinase was revealed in children with congenital TTP [17]. In adults with acquired TTP, enzyme inhibitory autoantibodies were later identified [18]. A new enzyme was investigated and named ADAMTS-13, belonging to the ADAMTS family of metalloproteases [19]. Mutations leading to enzyme deficiency and emergence of congenital TTP forms have also been identified [20].

TTP is triggered by unregulated vWF-dependent platelet aggregation. Large vWF multimers mediate platelet adhesion at sites of vascular injury by binding to connective tissue and glycoprotein Ib (GPIb) on the platelet surface. The vWF subunit multimers have a modular structure consisting of 5 types of structural motifs. They bind to collagen through the A3 domain and to platelet GPIb through the A1 domain. When platelets bind to vWF, the vWF multimer stretches, and the Tyr1605–Met1606 bond in the A2 domain becomes accessible to ADAMTS-13 for cleavage. ADAMTS-13 deficiency abrogates further suppression of platelet adhesion leading to widespread microvascular thrombosis [20] (**Fig. 1**).



**Figure 1.** Interaction mechanism between ADAMTS-13, von Willebrand factor, endothelium and platelets [drawn by authors].

**Note:** GPIb – glycoprotein Ib; A1, A2, A3 – domains of von Willebrand factor multimer; Tyr – tyrosine amino acid; Met – methionine amino acid.

**Рисунок 1.** Механизм взаимодействия ADAMTS-13, фактора фон Виллебранда, эндотелия и тромбоцитов [рисунок авторов].

**Примечание:** GPIb – гликопротеин Ib; A1, A2, A3 – домены мультимера фактора фон Виллебранда; Tyr – аминокислота тирозин; Met – аминокислота метионин.

Laboratory diagnosis of TTP is based on detecting MAGA and thrombocytopenia in the absence of other etiological factors. Hemolysis is accompanied by increased reticulocyte count and lactate dehydrogenase (LDH) as well as increased total and unconjugated bilirubin. Microhematuria, erythrocyte casts circulation, and proteinuria is often noted in urine, but plasma creatinine is rarely elevated. Almost all patients have normal magnitude for plasma fibrinogen, prothrombin time (PT), and activated partial thromboplastin time (APTT), reflecting the secondary



role of hypercoagulation. A characteristic morphological feature of TTP is the presence of schistocytes in the blood smear. ADAMTS-13 activity is usually less than 10 % [22].

Diagnostic laboratory tests, including the assessment of ADAMTS-13 activity, the assessment of the presence of an ADAMTS-13 inhibitor, and the assessment of anti-ADAMTS-13 antibodies, can be used both for the differential diagnosis of TTP from other TMAs and for the differential diagnosis of congenital and acquired forms.

The basis of therapy for acquired forms of TTP with an immune component underlying the pathogenesis is replacement plasma transfusion. The effectiveness is associated with both the elimination of antibodies to ADAMTS-13, vWF multimers from the circulation, and the replacement of ADAMTS-13 without a risk of hypervolemia [23] Replacement transfusion courses should be continued until remission occurs (platelet concentration is more than  $150 \times 10^9/L$  for more than 48 hours), LDH concentration decreases, and clinical improvement [24]. In addition to replacement blood transfusion for immune TTP forms, there are used glucocorticoids, rituximab, and caplacizumab.

*Congenital thrombotic thrombocytopenic purpura / Врожденная тромботическая тромбоцитопеническая пурпура*

Congenital TTP, or Upshaw–Shulman syndrome, is caused by an inherited deficiency in ADAMTS-13. I. Schulman et al. [25] and J.D. Upshaw J.D. [26] were the first to describe a congenital disorder resembling TTP, characterized by an autosomal recessive inheritance and manifested as chronic recurrent TMA starting from infancy. Congenital TTP is caused by a defect in the ADAMTS-13 gene in gene 19 on the chromosome 9q34 [27]. Congenital TTP is characterized by a severe ADAMTS-13 deficiency in less than 5 % cases. Gene mutations interfere with the ADAMTS-13 production or secretion. The prevalence of the defect is approximately one per 1 million of the population [28], without sex-bias. Among patients with TTP, congenital forms account for only a few percent. In most children with a congenital defect in the ADAMTS-13 gene, the disease begins in infancy with neonatal jaundice and hemolysis, without detected Rh and ABO conflict. About half of them have a chronic recurrent course. In the other half, symptoms usually appear in adolescence or at age of 20 years. Exacerbations are often triggered by infections, surgery, and other inflammatory diseases [29]. An exacerbation can develop while taking desmopressin, which stimulates the release of vWF from the depot of endothelial cells [30]. The clinic is similar to the acquired form: kidney damage with proteinuria, hematuria, and a slight increase in creatinine. Renal failure develops after prolonged relapse [31]. In women, exacerbations often occur during pregnancy, possibly because the concentration of vWF is elevated in later stages. In the absence of adequate therapy, pregnancy results in spontaneous abortion, stillbirth, or premature birth. The

clinical picture of TTP develops in the III trimester or the postpartum period, while pregnancy losses occur in the II trimester [30].

Congenital TTP is treated with fresh frozen plasma infusions (FFP). The half-life of ADAMTS-13 is 2 to 3 days [32]. The ADAMTS-13 level required to maintain is approximately 5 % of the normal; administration of 5–20 ml/kg of FFP every 2–3 weeks is usually sufficient to maintain ADAMTS-13 at this level [29, 31]. It has been shown that replacement plasma transfusions are more effective than simple plasma administration since the total volume during replacement transfusions is three times larger, and, therefore, the administered ADAMTS-13 factor is also more significant [33]. Factor VIII/vWF concentrates, which contain significant amounts of ADAMTS-13, have been successfully used in patients with severe allergic reactions to plasma [34].

One of the new directions in the therapy of TTP is the use of recombinant ADAMTS-13. Phase I studies involving patients with congenital TTP showed a significant dose-dependent increase in plasma decay vWF products, a decrease in LDH concentration, and normalization of platelet concentration. No antibody synthesis was observed upon administration of recombinant ADAMTS-13 [35]. The half-life of the recombinant form did not differ from that of the natural ADAMTS-13 and was approximately three days. Phase III testing is currently underway (NCT03393975). It has already been shown that recombinant ADAMTS-13 is also effective in patients with inhibitory forms of acquired TTP in the presence of antibodies [36]. There is no doubt that the use of recombinant ADAMTS-13 is a future strategy for the treatment of all TTP forms.

*Hemolytic uremic syndrome, typical form / Гемолитико-уремический синдром, типичная форма*

Hemolytic uremic syndrome (HUS) refers to TMAs and occurs with oliguric or anuric forms of renal failure. The Shiga toxin produced by *Escherichia coli* leads to developing a "typical" form of HUS, which is usually preceded by diarrhea.

In 1955, the term HUS was proposed to denote thrombotic microangiopathy in children with concomitant acute anuria, which is not typical for TTP [37]. HUS was often preceded by diarrhea, and, unlike TTP in adults, the prognosis was relatively favorable. Most of the patients survived and regained normal renal function [38]. Although all cases of HUS occurred predominantly in endemic areas, the cause of HUS was unknown until 1983, when it was first discovered that *Escherichia coli* expresses the Shiga toxin (Stx), which is the cause of hemorrhagic colitis, which can develop into HUS [39–41].

*Escherichia coli* can produce 2 types of structurally similar Shiga toxin. Stx1 is identical to the *Shigella dysenteriae* 1 toxin serotype. Stx2 is approximately 50 % identical in sequence to Stx1. Both toxins consist of pentameric B subunits that bind globotriaosylceramide (Gb3) on the cell surface and one A subunit responsible for cytotoxicity. Pathogenic *Escherichia coli* almost always

expresses the Stx2 variant and, in two-thirds of cases, Stx1 [42]. When *Escherichia coli* colonizes the intestine, it damages the epithelium and secretes Stx, delivered to target organs through the blood, probably by neutrophils. Stx bound to Gb3 on the cell surface undergoes endocytosis and is transported retrogradely via the secretory pathway to the endoplasmic reticulum, where the A subunit is translocated into the cytoplasm. Subunit A is an N-glycosidase that removes a specific base from the large ribosomal subunit, inhibiting protein synthesis and activating the apoptosis response pathway. The predisposition to kidney damage results from high Gb3 expression on tubular epithelial cells, mesangial and endothelial cells.

The typical form of HUS can occur at any age but mainly affects young children. Most cases occur in summer and autumn in rural areas. The incidence is approximately 10–30 per 1 million children per year, depending on the season, location, etc. The typical form of HUS is one of the leading causes of chronic renal failure in children [42].

Clinically, HUS presents with abdominal pain and diarrhea between 2 and 12 days after infection with an average incubation period of 3 to 7 days. Diarrhea can be hemorrhagic. In 15 % of patients, acute onset is followed by the addition of microangiopathic hemolytic anemia, thrombocytopenia, and kidney damage on average 7 days (5 to 13 days) after the onset of diarrhea [42].

Laboratory characteristics of typical HUS include electrolyte imbalance, thrombocytopenia up to  $40 \times 10^9/L$ , increased creatinine, proteinuria, hematuria, oliguria, or anuria. Typically, PT and APTT are regular or minimally lengthened, plasma fibrinogen is normal or increased, and fibrin degradation products are moderately increased [42, 43], and the concentration of ADAMTS-13 is normal. Stool analysis is performed on selective media for *Escherichia coli* O157:H7 and Stx to detect strains other than O157. *E. coli* is found in at least 90 % of patients within the first six days and no more than 30 % of patients later. Fecal leukocytes are not always present and are usually not numerous [42]. Analysis for antibodies to *Escherichia coli* surface antigens at diagnosis and after 2 weeks can facilitate diagnosis in cases where stool analysis is not informative. Antibody titers rise and persist for 8 to 12 weeks.

The main impact of the disease falls on the cortical layer of the kidneys and is often manifested by extensive necrosis. Less commonly, lesions occur in the pancreas, brain, adrenal glands, and myocardium. Microthrombi are more often found in glomerular capillaries and arterioles, and they consist mainly of fibrin and erythrocytes with a small number of platelets [44, 45].

The therapy principles for typical HUS consist of hospitalization, infusion therapy, and transfusion of erythrocytes masses according to indications with dynamic laboratory control. The rationality of antibiotic therapy depends on the stage of the disease [42, 46].

*Atypical hemolytic uremic syndrome / Атипичный гемолитико-уремический синдром*

Hereditary or acquired defects in the regulation of the alternative complement pathway leading to the development of "atypical" forms of HUS (aHUS), not associated with diarrhea caused by the influence of Stx.

For the first time, the distinction between typical diarrhea and atypical forms of HUS was made by scientists P. Barnard and M. Kibel, working with African patients in 1965 [47]. In the 1970s B.S. Kaplan suggested that recurrent familial cases of HUS represent a genetic disorder [48, 49]. Later, patients with aHUS were found to have increased consumption of complement component C3 and factor H deficiency [50]. In 1998, P. Warwicker et al. showed that mutations in complement factor H (CFH) are one of the causes for aHUS development [51], followed by the identification of mutations in other proteins of the alternative complement pathway. These results served as the basis for developing practical therapeutic approaches to the therapy of aHUS with inhibitors of complement activation [52].

The alternative complement pathway is a crucial point in the pathogenesis of aHUS. The complement component C3 can spontaneously convert to C3b and deposit on the cell surface. Normally, C3b is rapidly cleaved and inactivated by the serine protease factor I, and this reaction is accelerated by factor H or membrane cofactor protein (MCP, CD46). These cofactors are structurally and functionally similar, but factor H is a plasma protein and MCP is a transmembrane protein found on the surface of almost all cells. Without inhibition by these inhibitors, C3b interacts with factor B to form a potent C3 convertase, which enhances the deposition of C3b, attracting phagocytes and promoting a complex attack on endothelial membranes. The resulting vascular injury leads to TMA development.

Heterozygous mutations in the alternative complement pathway proteins have been identified in 60–70 % of patients with aHUS. These include loss of function mutations in factor H, MCP, factor I, proteins 1 and 3 associated with CFH (complement factor H-related genes, *CFHR1*, *CFHR3*) and thrombomodulin (TM); and enhancement mutations in factors B and C3. In addition, autoantibodies to factor H have been identified, which are often associated with mutations in *CFHR1* and *CFHR3* genes. There are combined mutations of more than one locus or a combination of autoantibodies to CFH and mutations [53]. Homozygous or complex heterozygous mutations of diacylglycerol kinase  $\epsilon$  (DGKE) cause severe forms of aHUS. The pathogenetic mechanism of the DGKE mutation has not yet been found [54].

Clinically, 20 % of patients have a subacute or chronic course. Mild anemia and thrombocytopenia are usually noted. Patients with aHUS may develop thrombosis, microangiopathy, and renal failure, sometimes with progressive hypertension. Most patients report a possible triggering event, such as viral or bacterial upper respiratory tract infections, gastroenteritis,

or pregnancy [53, 55]. Atypical HUS aggravates pregnancy with the development of obstetric complications such as fetal loss, III trimester pathology, preeclampsia, complications of the postpartum period [56].

Extrarenal symptoms occur in 10–20 % of patients. These include damage to the nervous system, myocardial infarction, pancreatitis, skin necrosis, etc. [53, 55].

The laboratory characteristics of aHUS include hemolysis, thrombocytopenia less than  $40 \times 10^9/L$ , increased plasma creatinine, microhematuria, and proteinuria, anuria. The concentration of complement component C4 is usually normal; C3 may be reduced; 3–7 % of patients have autoantibodies against CFH [53, 55].

Plasma exchange transfusions should be used for therapeutic purposes before aHUS is diagnosed [57]. Eculizumab should be considered once severe ADAMTS-13 deficiency, HUS, and secondary TMAs have been ruled out. Adverse reactions when using eculizumab include infections, fever, hypertension, headache, diarrhea, abdominal pain, nausea, and vomiting. Adverse reactions are frequent but rarely require discontinuation of therapy. Patients should be vaccinated against *Neisseria meningitidis* at least 2 weeks before treatment. If timely vaccination is not possible, antibiotic prophylaxis options are considered. For aHUS treatment caused by autoantibodies to CFH, rituximab and glucocorticoids can be added to eculizumab, which is discontinued after the eculizumab autoantibodies disappear. Transplantation is indicated for patients with end-stage renal disease. Transplantation from living-related donors is usually not performed because donor kidney may be at risk for aHUS, and donor may have the same risk factors as recipient and develop aHUS after kidney removal. Screening for mutations is required before transplantation in order to determine the tactics of subsequent treatment. In situations where patients do not receive eculizumab preventively, aHUS recurs on kidney transplants. Isolated MCP deficiency is an exception, as normal membrane-bound MCP in the transplanted kidney protects it from complement attack [57, 58]. A liver transplant or combined liver and kidney transplant can cure aHUS caused by a deficiency of plasma complement proteins synthesized in the liver. However, the risk and complications of liver transplantation can be avoided by prophylactic treatment with eculizumab after kidney transplantation [57, 58].

#### *Secondary thrombotic microangiopathy / Вторичная тромботическая микроангиопатия*

Secondary TMA can occur concomitantly with cancer, infection, organ transplantation, and drug use, arterial hypertension, vasculitis, catastrophic antiphospholipid syndrome, radiation therapy, chemotherapy, hereditary or acquired metabolic disorders, disseminated intravascular coagulation (DIC), etc. Endothelial damage is the main cause of developing secondary TMA; the mechanisms may differ being not always fully understood. The primary approach to therapy is the

treatment of the underlying disease. A significant deficiency of ADAMTS-13 in secondary TMA has practically never been observed.

TMA occurs in a small group of cancer patients, most often with adenocarcinomas of the pancreas, lung, prostate, stomach, colon, ovary, breast, or cancer metastases from an undiagnosed source. These localizations are also associated with Trousseau's syndrome or paraneoplastic hypercoagulability and thrombosis. In laboratory parameters, PT and APTT are prolonged, and the concentration of fibrin degradation products increases [59, 60]. The abundance of schistocytes has also been described in acute erythroleukemia (61), in which FFP therapy is ineffective [7, 60, 62].

**Table 1.** Types of thrombotic microangiopathy [summarized by the authors].

**Таблица 1.** Виды тромботической микроангиопатии [обобщено авторами].

<b>Disease</b> <b>Заболевание</b>	<b>Etiology</b> <b>Этиология</b>
Acquired thrombotic thrombocytopenic purpura Тромботическая тромбоцитопеническая пурпура приобретенная	Autoimmune disease with antibodies to ADAMTS-13 Аутоиммунное заболевание с наличием антител к ADAMTS-13
Congenital thrombotic thrombocytopenic purpura Врожденная тромботическая тромбоцитопеническая пурпура	Hereditary deficiency of ADAMTS-13 without mutations in ADAMTS-13 structure Наследственный дефицит ADAMTS-13 без мутаций в структуре ADAMTS-13
Hemolytic uremic syndrome, typical form Гемолитико-уремический синдром, типичная форма	Triggered by Shiga toxin produced by <i>Escherichia coli</i> Запускается шига-токсином <i>Escherichia coli</i>
Atypical hemolytic uremic syndrome Атипичная форма гемолитико-уремического синдрома	Alternative complement pathway defects, diacylglycerol kinase $\epsilon$ defects Дефекты альтернативного пути комплемента, дефекты диацилглицеролкиназы $\epsilon$
Secondary thrombotic microangiopathies Вторичные тромботические микроангиопатии	Disseminated intravascular coagulation Синдром диссеминированного внутрисосудистого свёртывания Infections (viral, bacterial, fungal) Инфекции (вирусные, бактериальные, грибковые) Organ transplantation (graft rejection, graft versus host reactions) and synthetic prostheses (mechanical hemolysis when installing aortic or mitral valves) Трансплантация органов (отторжение трансплантата, реакции трансплантат против хозяина) и синтетических протезов (механический гемолиз при установке аортального или митрального клапанов) Oncological diseases Онкологические заболевания Chemotherapy, radiation therapy Химиотерапия, лучевая терапия

	<p>Complications of pregnancy Осложнения беременности</p> <p>Autoimmune diseases (systemic lupus erythematosus and other vasculitis, antiphospholipid syndrome) Аутоиммунные заболевания (системная красная волчанка и другие васкулиты, антифосфолипидный синдром)</p> <p>Medicines (quinine, cyclosporine, gemcitabine, tacrolimus, etc.) Лекарственные средства (хинин, циклоспорин, гемцитабин, такролимус и т. д.)</p> <p>Defects in cobalamin metabolism Дефекты обмена кобаламина</p> <p>Malignant arterial hypertension Злокачественная артериальная гипертензия</p>
--	--

During sepsis, massive endothelial injury occurs with the release of large amounts of vWF multimers. Given a decreased activity of ADAMTS-13, this can lead to TMA development and multiple organ failure while progression of the systemic inflammatory response [63, 64]. In this case, it is suggested to determine blood plasma vWF concentration and ADAMTS-13 activity, since they are the markers of the condition severity and prognostic indicators. Thus, it was shown that in severe septic patients with ADAMTS-13 levels below 43 %, the survival rate was significantly lower, regardless of DIC presence [65].

A decrease in ADAMTS-13 activity can be caused by its depletion due to massive consumption during the escalating inflammation, as well as by the fact that proinflammatory cytokines secreted by leukocytes and endothelial cells activated during inflammation stimulate the release of vWF, IL-8 and tumor necrosis factor alpha (TNF- $\alpha$ ). During concomitant DIC, clotting factors are consumed, particularly factor VIII, which generally also promote vWF proteolysis [66]. Moreover, granule elastase in neutrophil extracellular traps (NETs), which are formed in large numbers during inflammation, can proteolytically degrade ADAMTS-13 [67]. Plasmin also carries out proteolysis of ADAMTS-13 [68]. The concentration of thrombin, plasmin, and reactive oxygen, substances sharply increases in sepsis and systemic inflammatory response, as well as that of specific microbial proteases: This fact can further reduce the enzymatic activity of ADAMTS-13 – [69]. Thrombospondin-1, a matrix glycoprotein whose concentration increases during inflammation, is considered an early marker of sepsis-induced DIC. It regulates the response of activated leukocytes, and their chemotaxis increases. Thrombospondin-1 competes with ADAMTS-13 for the A3 domain of VWF, thereby protecting vWF from proteolysis [70]. Free hemoglobin acts similarly, competing for the A2 domain [71]. Typically, plasminogen destroys vWF complexes with platelets, functioning in conjunction with ADAMTS-13; in the case of a latter deficiency, a block of

fibrinolysis develops [72]. The synthesis of ADAMTS-13 decreases in case of sepsis may also result from the development of liver failure.

DIC can develop as a result of various pathological processes. In contrast to TMA, tissue factor-mediated coagulopathy in DIC leads to generalized thrombin production and activation of all hemostasis components, the formation of multiple fibrin thrombi, multiple organ failure, and bleeding. In patients with DIC in case of sepsis, the activity of ADAMTS-13 is significantly reduced, leading to clinical and laboratory symptoms similar to TTP with severe hemolysis, thrombocytopenia and renal failure [73]. In patients who develop DIC during sepsis, blood vWF concentration is significantly higher, and the activity of ADAMTS-13 is lower than in patients with DIC. In this regard, studies have demonstrated the effectiveness of recombinant ADAMTS-13 in DIC in these cases [74].

#### *Differential diagnosis / Дифференциальная диагностика*

Signs and symptoms of aHUS are the same as in TPP or HUS; however, differential diagnosis of these conditions is essential due to fundamentally different approaches to therapy. Making a correct diagnosis is not always easy. For example, MCP mutations can cause TMA without renal failure, which is compensated for by plasma administration and, therefore, resembles TTP, except for the normal activity of ADAMTS-13 [75]. Some patients with HUS have no diarrhea [76]. It is also necessary to consider a possible presence of factors for secondary TMA development.

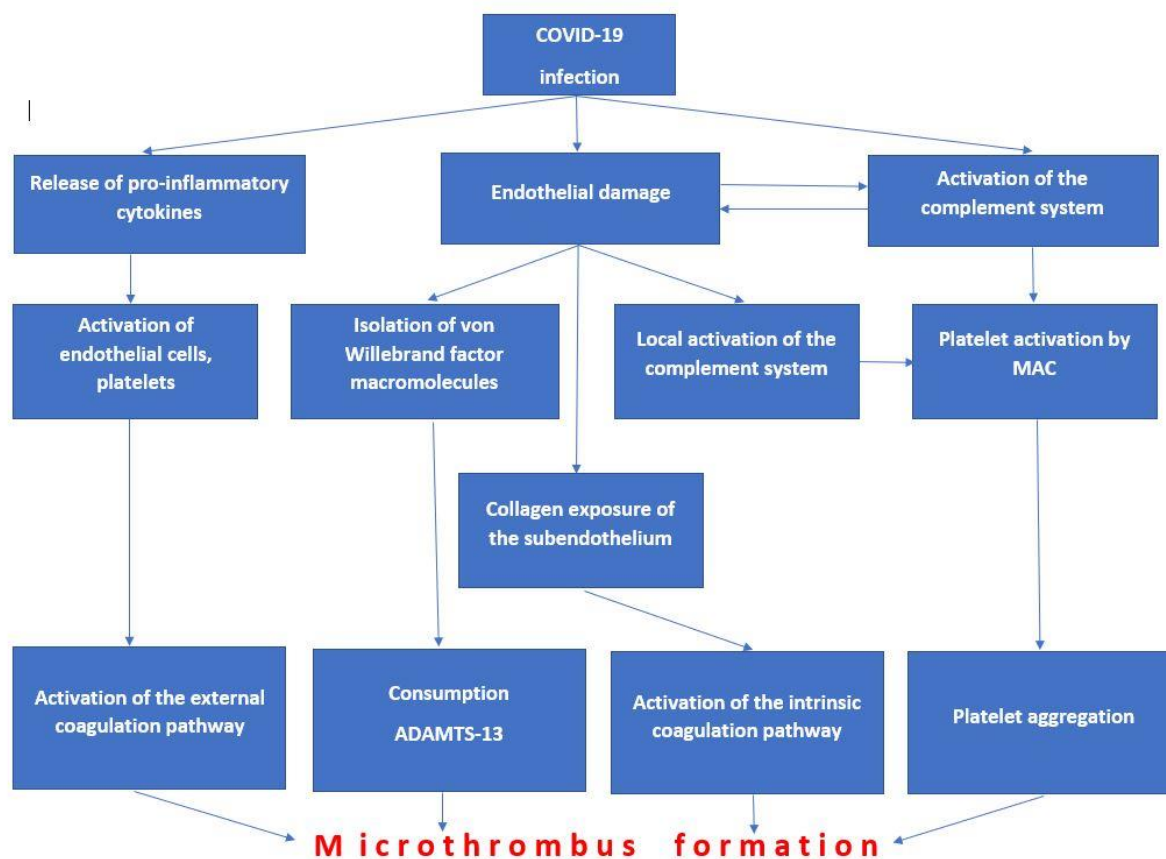
#### **Possible mechanisms of thrombotic microangiopathy development in COVID-19 / Возможные механизмы развития тромботической микроангиопатии при COVID-19**

The complement system uncontrolled activation is the basis of the pathogenesis of TMA in COVID-19 [77]. An alternative pathway for complement activation has been shown to play an essential role in the development of COVID-19-associated TMAs [78]. In patients who died from severe forms of the disease, during the autopsy thrombosis was revealed in the microvascular bed of the skin and lungs associated with the deposition of membrane attack complex (MAC, C5b-9), C4d, and mannan-binding lectin serine peptidase 2 (MASP-2) [78].

E. Bilgin and A.I. Ertenli in their recent publication, proposed the term Inflammatory Thrombosis with Immune Endotheliitis (ITIE) for COVID-19-associated super inflammation with a prothrombotic condition [79]. Endotheliitis disrupts the integrity of the vascular endothelium, which leads to the release of substances such as VEGF, platelet-derived growth factor (PDGF), etc. [80, 81]. Subsequently, they cause activation of the coagulation cascade at the site of inflammation. The authors have introduced a new term to highlight that anti-cytokine therapy will not cope with this situation, and that other goals should be sought, as the name suggests.

**Figure 2** shows a possible mechanism for TMA development in patients with COVID-19.





**Figure 2.** Potential mechanism for thrombotic microangiopathy development in COVID-19.

**Note:** MAC – membrane attack complex.

**Рисунок 2.** Потенциальный механизм развития тромботической микроангиопатии при COVID-19.

**Примечание:** MAC – мембраноатакующий комплекс.

**Facts indicating the participation of thrombotic microangiopathy in the pathogenesis of COVID-19 severe forms / Факты, указывающие на участие тромботической микроангиопатии в патогенезе тяжелых форм COVID**

An increase in LDH and D-dimer, the presence of thrombi in the microcirculatory bed, despite the use of anticoagulants, evidence about a need for further study of the pathogenesis of COVID-19 and considering TMA as a possible cause that can be effectively treated. A prospective observational study demonstrated a significant LDH concentration increase in patients with COVID-19 and acute kidney injury compared with patients with normal renal function ( $p < 0.0001$ ). Although most patients in this study had signs of acute tubular necrosis secondary to ischemia or rhabdomyolysis, the etiology of acute kidney injury was unclear in 13 % of patients. The increase in creatinine did not correspond to hemodynamic disturbances; urinalysis showed signs of acute tubular injury in 11 patients and proteinuria, indicative of glomerular damage in 3

patients. Whether this was due to infection of renal tubule/glomerular epithelial cells with SARS-CoV-2 or the different mechanism remains unclear [82]. One of the possible mechanisms is microvascular thrombosis resulting from TMA attachment, which confirms an increase in the concentration of D-dimer and LDH; however, no kidney biopsy was performed in the study, making this conclusion speculative.

A study from China examined histological sections of the kidneys of 26 patients who died from severe forms of COVID-19. In most cases, light microscopy showed proximal tubular necrosis and erythrocyte aggregates in the capillary lumens. Although the study did not record a single case of TMA, fibrin clots in the glomeruli were described in at least 3 patients who had anemia, increased D-dimer concentration (four times or more), and thrombocytopenia. In 20 of 26 patients, the concentration of D-dimer and platelets were described; of these 20, 14 (70 %) patients had thrombocytopenia, and 20 (100 %) had an increased D-dimer concentration [83].

Most of the published data indicate the presence of microvascular thrombosis in the lungs of patients with COVID-19 [84]. Microthrombosis in the lungs is specific for COVID-19 and is widespread, occurring 9 times more often in patients with COVID-19 than in patients infected with the H1N1 virus [2]. Thus, an Italian study demonstrated the presence of fibrin-platelet thrombi in the lung capillaries in all patients (87 % of 38 cases) [85]. However, based on published data, it is not clear whether all patients with microthrombosis had clinical manifestations of TMA. Only one of 7 autopsies described the combination of platelet-rich fibrin thrombi in the microvasculature with typical signs of TMA. The study lacked assessment of key laboratory parameters of TMA, such as platelet count, renal function assessment, and ADAMTS-13 concentration [86]. Similarly, in another study, only 8 out of 21 cases of thrombosis had clinical signs of TMA [87].

According to research results, the main form of TMA associated with COVID-19 is the complement-dependent form. Of the 10 COVID-19 patients who underwent a kidney biopsy, 2 showed signs of TMA under light and electron microscopy. One of these patients was previously described in the literature [88], another patient received gemcitabine therapy combined with radiation therapy for cervical cancer [89]. Considering that gemcitabine is capable of causing secondary TMAs, COVID-19 could be the second trigger of SARS-CoV-2 infection, realizing a complement defect. In one of the described clinical cases, a patient with progressive renal failure, thrombocytopenia, and MAGA was reported; a low concentration of the complement component H and an increased concentration of CBb and C5b-9 complement components were found in the blood, which predisposed to activation of the alternative pathway [88].

A small number of studies describe TTP-like TMAs in patients with COVID-19. Acquired TTP has been described in a patient with COVID-19 infection associated with the presence of an ADAMTS-13 inhibitor. RNA viruses have previously been identified as the cause of the

development of acquired ADAMTS-13 deficiencies [90]. Another publication describes a patient with COVID-19 and an acquired ADAMTS-13 inhibitor without any other risk factors for developing acquired TTP. In this case, SARS-CoV-2 is the most likely cause of the condition [91]. The third time COVID-19-related TTP was mentioned in a patient with severe complications, including stroke, bleeding, and advanced microvascular thrombosis, with an identified acquired ADAMTS-13 inhibitor [92].

The relatively rare incidence of TTP-like TMAs in patients with COVID-19 suggests the need to consider it as a condition that may potentially occur which should be arrested upon detection. Currently, scientifically based data on the incidence of TTP in COVID-19 is required. A lack of published materials on this issue makes it difficult to extrapolate the findings into a more “realistic” scenario.

TMA in COVID-19 can also result from direct virus damage to the vascular endothelium. A series of cases of three patients with SARS-CoV-2 infection demonstrated damage to the capillary endothelium by the virus with the development of endotheliitis in organs such as the intestines, lungs, and kidneys [93]. Another study described patients with a severe course of COVID-19 and alterations corresponding to TMA in the cerebral cortex on computed tomography and magnetic resonance imaging data [94]. Although far from definitive, the data presented above supports the hypothesis of the TMA involvement in the pathogenesis of severe forms of COVID-19. Whether TMA develops in this case mainly due to complement-mediated damage or if there is some other mechanism remains to be elucidated.

Timely onset of therapy for TMA, especially plasmapheresis, can be life-saving. Diagnosing TTP is challenging due to its varied clinical presentation, overlap with other TMAs, and limited availability of ADAMTS-13 testing. Clinical prognosis scores have been developed to identify the likelihood of severe ADAMTS-13 deficiency and can be used as an adjunct to the clinical presentation for an initial assessment. An ADAMTS-13 activity level of less than 10 % confirms the diagnosis of TTP, but testing takes several days. In such cases, the initial decision should be made without laboratory testing based on the use of some rating scales such as the PLASMIC scale, French scale, or Bentley scale [95–97]. These prognosis scores include critical clinical and laboratory parameters for the pretest probability of severe ADAMTS-13 deficiency. The evaluated components are summarized in **Table 2**.

**Table 2.** Scales for assessing the likelihood of ADAMTS-13 deficiency [95–97].

**Таблица 2.** Шкалы оценки вероятности наличия дефицита ADAMTS-13 [95–97].

<b>Estimated parameter</b> Оцениваемый параметр	<b>PLASMIC scale</b> Шкала PLASMIC	<b>French scale</b> Шкала French	<b>Bentley scale</b> Шкала Bentley

Platelet count Количество тромбоцитов	< 30×10 <sup>9</sup> /L: 1 point < 30×10 <sup>9</sup> /л: 1 балл	≤ 30×10 <sup>9</sup> /L: 1 point < 30×10 <sup>9</sup> /л: 1 балл	> 35×10 <sup>9</sup> /L: minus 30 points > 35×10 <sup>9</sup> /л: минус 30 баллов
Creatinine content Концентрация креатинина	< 177 μmol/L: 1 point < 177 мкмоль/л: 1 балл	≤ 200 μmol/L: 1 point ≤ 200 мкмоль/л: 1 балл	> 177 μmol/L: minus 11.5 points > 177 мкмоль/л: минус 11,5 баллов
Hemolysis parameters Показатели гемолиза	Reticulocytes > 2.5%: 1 point Ретикулоциты > 2,5 %: 1 балл	—	Reticulocytes > 3 %: plus 21 point Ретикулоциты > 3 %: plus 21 points
	Haptoglobin is undetectable: 1 point Гаптоглобин не определяется: 1 балл		
	Indirect bilirubin > 34.2 μmol/L: 1 point Непрямой билирубин > 34,2 мкмоль/л: 1 балл		Indirect bilirubin > 25.7 μmol/L: plus 20.5 points Непрямой билирубин > 25,7 мкмоль/л: плюс 20,5 баллов
Associated conditions Сопутствующие состояния	No active cancer: 1 point Нет активного рака: 1 балл	—	—
	No history of organ and bone marrow transplants: 1 point Нет в анамнезе трансплантаций органов и костного мозга: 1 балл		
International normalized ratio Международное нормализованное отношение	< 1.5: 1 point < 1,5: 1 балл	—	—
Antinuclear antibodies Антинуклеарные антитела	—	Revealed: 1 point Выявлены: 1 балл	—
D-dimer D-димер	—	—	> 4 μg/dL: minus 10 points > 4 мкг/дл: минус 10 баллов
Average erythrocytes volume Средний объем эритроцитов	< 90 fl: 1 point < 90 фл: 1 балл	—	—
<b>Probability of ADAMTS-13 deficiency (Total Score)</b> <b>Вероятность дефицита ADAMTS-13 (по сумме баллов)</b>			

Low Низкая	0–4	0	< 20
Medium Средняя	5	1	20–30
High Высокая	6–7	2–3	> 30

Severe thrombocytopenia and the absence of severe renal dysfunction are significant components that are consistently used in all scoring systems. Inhibitor tests can be used to differentiate between acquired and congenital TTP.

### **Possible approaches to thrombotic microangiopathy therapy in patients with COVID-19 / Возможные подходы к терапии тромботической микроангиопатии у пациентов с COVID-19**

TMA therapy includes four main tools: plasmapheresis, immunosuppression, monoclonal antibodies, and, in the case of secondary TMAs, elimination of the etiological factor [6]. Until the beginning of the last decade, TMA therapy consisted only of plasmapheresis and immunosuppression. However, with the advent of effective therapy in the form of complement inhibitors for complement-mediated TMA and caplacizumab for TTP, there was an urgent need to specify the type of TMA [52, 98]. The lack of specific treatment for COVID-19 infection, the higher mortality in TMA-associated COVID-19 cases, and the availability of effective treatments for TMA are the arguments in favor of exploring possible treatment options for this group of patients. Heparins and direct oral anticoagulants are the basis for preventing venous thromboembolism in patients with COVID-19, but their effectiveness in the presence of TMA is questionable [99, 100]. At the moment, it has been proven that anticoagulants in critically ill patients with COVID-19 to prevent large vessel thrombosis are effective, but their role in the prevention of TMA is not clear [101]. Therapeutic approaches for TMA-associated complications in severe COVID-19 are outlined below.

#### *Glucocorticoids / Глюкокортикоиды*

Traditionally, corticosteroids have been used in combination with plasma in TMA therapy since they can provide rapid immunosuppression in some patients with TTP and acquired aHUS [102].

Effects of corticosteroids in TMA:

- they suppress production of the acquired inhibitors against ADAMTS-13 (acquired TTP) and anti-H-factor antibodies (acquired aHUS) [103];
- they reduce the inflammatory reactions in the endothelium by decreasing cytokines synthesis and the expression of adhesion molecules [104];

– they increase the activity of endothelial NO-synthase and, consequently, increase the synthesis and release of nitric oxide (NO). Platelet aggregation and leukocyte adhesion are suppressed by NO, thereby blocking the progression of thrombotic and inflammatory reactions [105];

– they suppress the activation and amplification of the alternative complement pathway [106].

In addition to the cytopathic effects of SARS-CoV-2, an immune system overreaction in response to the virus significantly contribute to the pathogenesis of severe conditions associated with COVID-19. This is evidenced by an increase in the levels of cytokines (IL-1, IL-6), inflammatory markers (procalcitonin, C-reactive protein), and acute phase proteins (ferritin, fibrinogen). Their increased level indicates a poor prognosis in patients with COVID-19 [107].

A multicenter randomized controlled trial compared the effect of adding dexamethasone (6 mg/day) to a management protocol on a 28-day mortality rate in hospitalized patients with severe COVID-19. In the group of patients with dexamethasone in the protocol used, the 28-day mortality rate was significantly lower [108]. Another small (n = 84), partially randomized, open-label trial showed that methylprednisolone significantly reduced the likelihood of mechanical ventilation, admission to an intensive care unit, and death [109]. In all 3 cases of acquired TTP in COVID-19 described in the literature, methylprednisolone (1 mg/kg/day) was used in combination with plasma inoculation.

*End-stage complement activation inhibitors and other therapies targeting complement components / Ингибиторы терминального этапа активации комплемента и другие виды терапии, направленные на компоненты комплемента*

The effect of viral infection on complement activation has been extensively studied in animal models. Widespread deposition of MAC (C5b-9) complexes was observed on pneumocytes and bronchiolar epithelial cells at autopsy in the MERS-CoV-infected patient. It has been also shown an increase in the concentration of C5a in the blood plasma, which indicates a systemic activation of the terminal complement pathway [110]. An increased concentration of blood plasma C5a was also observed in patients with severe H1N1 influenza, which confirms the role of hyperactivated complement system in the pathogenesis of severe forms of infectious diseases [111]. Studies have shown that administration of complement antagonists to animals infected with MERS-CoV, influenza viruses H1N1, H5N1, etc., complement antagonists led to a less severe course of the infectious process [112–114]. Mice knocked out for C3 protein gene (–/–), upon infection with SARS-CoV, had less pronounced symptoms and histological changes in the lung tissue [115]. A study of the C3 gene knockout in mice infected with influenza A H1N1 or H5N1 virus gained

opposite results. Mice with C3 (–/–) had a more severe course, often fatal [113]. These data indicate the complexity of the processes involving the complement system in viral infections.

Eculizumab, a human monoclonal antibody that binds to the C5 complement protein, has proven to be a discovery in treating paroxysmal nocturnal hemoglobinuria and aHUS [52]. The drug suppresses the terminal complement pathway but retains the functions of early components such as C3a/C3b. Due to this, functions such as virus opsonization and enhanced B- and T-cell immune response are preserved. At the same time, the negative effect of the complement system due to its hyperactivation triggered by a viral infection declines [116].

A small descriptive study in Italy demonstrates 4 cases of eculizumab use in severe COVID-19, during which there was a noticeable clinical improvement with a significant decrease in the concentration of C-reactive protein (from 146 to 35 mg/L) [117]. Currently, several studies are ongoing to assess the effectiveness and safety of eculizumab in patients with severe COVID-19 (NCT04346797, NCT04355494, NCT04288713) [118]. One clinical case describes a 71-year-old patient with severe COVID-19 who, in response to therapy with the C3 complement inhibitor AMY101, demonstrated both improved clinical parameters and normalized laboratory parameters such as LDH and C-reactive protein [119]. A study is also currently underway evaluating the efficacy and safety of AMY-101 in critically ill patients with COVID-19 (NCT04395456) [118].

The anti-complement therapy can play a significant role in TMA-associated severe forms of COVID-19 and other COVID-19 associated complications such as acute respiratory distress syndrome and cytokine storm. However, C3 inhibitors should be used with caution, as they can almost fully paralyze the complement system and lead to a more severe course of the infectious process, as shown in animal studies [113].

#### *Plasma transfusion / Трансфузия плазмы*

FFP transfusion is effective for almost all types of TMA, allowing for the replacement of defective/missing proteins (ADAMTS-3, complement, etc.) [120]. All three patients described in the literature with acquired TTP associated with COVID-19 responded well to plasma therapy [91, 92, 121].

In addition, not of less importance is the question of whether plasma transfusion did lead to inactivation of the antibodies emerged against the virus in patients with COVID-19? However, no data on this use are available yet, but it is tentative to speculate that one of the means to solve it would be inoculation of convalescent plasma from patients with COVID-19 performed between courses of plasma transfusion.

Plasma use in COVID-19 patients with confirmed TMA and severe cases of COVID-19 infection without documented TMA has also demonstrated clinical efficacy by eliminating pro-inflammatory cytokines such as IL-1, IL-6, TNF, etc. [122, 123]. Research is ongoing regarding a

therapeutic value of using replacement plasma transfusion in critically ill patients with COVID-19 (NCT04374539, NCT04441996) [118].

*COVID-19-convalescent plasma / COVID-19-реконвалесцентная плазма*

The question on the effectiveness of using COVID-19-convalescent plasma (CCP) in severe forms of COVID-19 continues to be studied (studies NCT04348656, NCT04340050). A systematic review of small uncontrolled studies and clinical cases has shown that CCP therapy markedly reduces mortality and improves prognosis [124]. CCP is effective due to the following possible mechanisms in the treatment of COVID-19:

- neutralizing antibodies to the virus reducing viral load [125];
- modulating anti-inflammatory cytokines, antibodies against autoantibodies, cytokines, and inflammatory cytokines in order to let the immune system to fight the cytokine storm [126].

Theoretically, it would be reasonable to use CCP instead of FFP or albumin in COVID-19 patients with TMA-like clinical manifestations since TMA therapy would be combined with the introduction of neutralizing antibodies against SARS-CoV-2. However, in practice, the number of CCP is limited and not sufficient to be administered in large volumes.

*Immunosuppressants / Иммуносупрессоры*

Corticosteroids are components of therapy for severe COVID-19, but patients with certain TMAs, such as TTP, may require more aggressive immunosuppression. The simultaneous use of targeted immunosuppressants and corticosteroids significantly increases the risk of infection and associated complications. Rituximab is one of the most commonly used immunosuppressants in the treatment of acquired forms of TTP. Published data on the efficacy of rituximab in patients with COVID-19 are conflicting [127].

*Caplacizumab / Каплацизумаб*

Caplacizumab is an immunoglobulin fragment that binds to the A1 domain of von Willebrand factor, blocking its interaction with the platelet glycoprotein receptor Ib-IX-V, which prevents microvascular thrombosis [128]. Caplacizumab is effective in treating acute and refractory TTP [129], approved by the Food and Drug Administration (FDA) for TTP treatment, and included in the 2020 International Society on Thrombosis and Hemostasis (ISTH) guidelines to combat this disease. The drug is of particular importance in patients with TTP in the presence of COVID-19 since it is not an immunosuppressant [128]. Its use in combination with replacement plasma transfusion and corticosteroids should be considered in patients with TTP and active COVID-19 infection.

*Recombinant ADAMTS-13 / Рекомбинантный ADAMTS-13*



One of the possible therapeutic strategies for TMA-dependent severe COVID-19 and ADAMTS-13 deficiency, or in case of circulating ADAMTS-13 inhibitors, is the use of recombinant ADAMTS-13.

## Conclusion / Заключение

The data published in the world literature during the COVID-19 pandemic indicate that thrombotic complications are the leading cause of morbidity and mortality in severe cases. This fact dictates the need for routine administration of prophylactic or therapeutic doses of anticoagulants. The ineffectiveness of anticoagulants in some cases suggests the presence of additional mechanisms, such as TMA. In these cases, a rational and stepwise approach is necessary; the TMA diagnosis should be considered and, if identified, the appropriate therapy should be applied.

<b>ARTICLE INFORMATION</b>	<b>ИНФОРМАЦИЯ О СТАТЬЕ</b>
<b>Received:</b> 20.10.2021. <b>Accepted:</b> 11.11.2021. <b>Published online:</b> 12.11.2021.	<b>Поступила:</b> 20.10.2021. <b>Принята к печати:</b> 11.11.2021. <b>Опубликована онлайн:</b> 12.11.2021.
<b>Author's contribution</b>	<b>Вклад авторов</b>
All authors contributed equally to the article.	Все авторы внести равный вклад в написание и подготовку рукописи.
All authors have read and approved the final version of the manuscript.	Все авторы прочитали и утвердили окончательный вариант рукописи.
<b>Conflict of interests</b>	<b>Конфликт интересов</b>
The authors declare no conflict of interests.	Авторы заявляют об отсутствии конфликта интересов.
<b>Funding</b>	<b>Финансирование</b>
The review was funded by RFBR, project number 20-04-60274.	Обзор выполнен при финансовой поддержке РФФИ в рамках научного проекта РФФИ №20-04-60274.
<b>Provenance and peer review</b>	<b>Происхождение статьи и рецензирование</b>
Not commissioned; externally peer reviewed.	Журнал не заказывал статью; внешнее рецензирование.

## References / Литература:

1. Zhou F., Yu T., Du R. et al. Clinical course and risk factors for mortality of adult inpatients with COVID-19 in Wuhan, China: a retrospective cohort study. *Lancet*. 2020;395(10229):1054–62. [https://doi.org/10.1016/S0140-6736\(20\)30566-3](https://doi.org/10.1016/S0140-6736(20)30566-3).
2. Ackermann M., Verleden S.E., Kuehnel M. et al. Pulmonary vascular endothelialitis, thrombosis, and angiogenesis in Covid-19. *N Engl J Med*. 2020;383(2):120–8. <https://doi.org/10.1056/NEJMoa2015432>.
3. Cao W., Li T. COVID-19: towards understanding of pathogenesis. *Cell Res*. 2020;30(5):367–9. <https://doi.org/10.1038/s41422-020-0327-4>.
4. Zhang Y., Xiao M., Zhang S. et al. Coagulopathy and antiphospholipid antibodies in patients with Covid-19. *N Engl J Med*. 2020;382(17):e38. <https://doi.org/10.1056/NEJMc2007575>.
5. Beyrouti R., Adams M.E., Benjamin L. et al. Characteristics of ischaemic stroke associated with COVID-19. *J Neurol Neurosurg Psychiatry*. 2020;91(8):889–91. <https://doi.org/10.1136/jnnp-2020-323586>.

6. George J.N., Nester C.M. Syndromes of thrombotic microangiopathy. *N Engl J Med.* 2014;371(7):654–66. <https://doi.org/10.1056/NEJMra1312353>.
7. Hovinga J.A.K., Vesely S.K., Terrell D.R. et al. Survival and relapse in patients with thrombotic thrombocytopenic purpura. *Blood.* 2010;115(8):1500–11; quiz 1662. <https://doi.org/10.1182/blood-2009-09-243790>.
8. Ridolfi R.L., Bell W.R. Thrombotic thrombocytopenic purpura: report of 25 cases and review of the literature. *Medicine (Baltimore).* 1981;60(6):413–28.
9. Moschcowitz E. Hyaline thrombosis of the terminal arterioles and capillaries: a hitherto undescribed disease. *Proc NY Pathol Soc.* 1924;24:21–24.
10. Singer K., Bornstein F.P., Wile S.A. Thrombotic thrombocytopenic purpura: hemorrhagic diathesis with generalized platelet thromboses. *Blood.* 1947;2(6):542–54.
11. Amorosi E.L., Ultmann J.E. Thrombotic thrombocytopenic purpura: report of 16 cases and review of the literature. *Medicine.* 1966;45(2):139–60.
12. Bukowski R.M., Hewlett J.S., Harris J.W. et al. Exchange transfusions in the treatment of thrombotic thrombocytopenic purpura. *Semin Hematol.* 1976;13(3):219–32.
13. Bukowski R.M., King J.W., Hewlett J.S. Plasmapheresis in the treatment of thrombotic thrombocytopenic purpura. *Blood.* 1977;50(3):413–7.
14. Byrnes J.J., Khurana M. Treatment of thrombotic thrombocytopenic purpura with plasma. *N Engl J Med.* 1977;297(25):1386–9. <https://doi.org/10.1056/NEJM197712222972507>.
15. Moake J.L., Rudy C.K., Troll J.H. et al. Unusually large plasma factor VIII: von Willebrand factor multimers in chronic relapsing thrombotic thrombocytopenic purpura. *N Engl J Med.* 1982;307(23):1432–5. <https://doi.org/10.1056/NEJM198212023072306>.
16. Furlan M., Robles R., Lämmle B. Partial purification and characterization of a protease from human plasma cleaving von Willebrand factor to fragments produced by in vivo proteolysis. *Blood.* 1996;87(10):4223–32.
17. Furlan M., Robles R., Solenthaler M. et al. Deficient activity of von Willebrand factor–cleaving protease in chronic relapsing thrombotic thrombocytopenic purpura. *Blood.* 1997;89(9):3097–103.
18. Tsai H.M., Lian E.C. Antibodies to von Willebrand factor–cleaving protease in acute thrombotic thrombocytopenic purpura. *N Engl J Med.* 1998;339(22):1585–94. <https://doi.org/10.1056/NEJM199811263392203>.
19. Zheng X., Chung D., Takayama TK. et al. Structure of von Willebrand factor-cleaving protease (ADAMTS13), a metalloprotease involved in thrombotic thrombocytopenic purpura. *J Biol Chem.* 2001;276(44):41059–63. <https://doi.org/10.1074/jbc.C100515200>.

20. Levy G.G., Nichols W.C., Lian E.C. et al. Mutations in a member of the ADAMTS gene family cause thrombotic thrombocytopenic purpura. *Nature*. 2001;413(6855):488–94. <https://doi.org/10.1038/35097008>.
21. Scheiflinger F., Knöbl P., Trattner B. et al. Nonneutralizing IgM and IgG antibodies to von Willebrand factor–cleaving protease (ADAMTS-13) in a patient with thrombotic thrombocytopenic purpura. *Blood*. 2003;102(9):3241–3. <https://doi.org/10.1182/blood-2003-05-1616>.
22. Bianchi V., Robles R., Alberio L. et al. Von Willebrand factor–cleaving protease (ADAMTS13) in thrombocytopenic disorders: a severely deficient activity is specific for thrombotic thrombocytopenic purpura. *Blood*. 2002;100(2):710–3. <https://doi.org/10.1182/blood-2002-02-0344>.
23. Pereira A., Mazzara R., Monteagudo J. et al. Thrombotic thrombocytopenic purpura/hemolytic uremic syndrome: a multivariate analysis of factors predicting the response to plasma exchange. *Ann Hematol*. 1995;70(6):319–23. <https://doi.org/10.1007/BF01696619>.
24. Picod A., Provôt F., Coppo P. Therapeutic plasma exchange in thrombotic thrombocytopenic purpura. *Presse Med*. 2019;48(11 Pt 2):319–27. <https://doi.org/10.1016/j.lpm.2019.08.024>.
25. Schulman I., Pierce M., Lukens A., Currimbhoy Z. Studies on thrombopoiesis. I. A factor in normal human plasma required for platelet production; chronic thrombocytopenia due to its deficiency. *Blood*. 1960;16:943–57.
26. Upshaw J.D. Congenital deficiency of a factor in normal plasma that reverses microangiopathic hemolysis and thrombocytopenia. *N Engl J Med*. 1978;298(24):1350–2. <https://doi.org/10.1056/NEJM197806152982407>.
27. Zheng X.L., Sadler J.E. Pathogenesis of thrombotic microangiopathies. *Annu Rev Pathol*. 2008;3:249–77. <https://doi.org/10.1146/annurev.pathmechdis.3.121806.154311>.
28. Miyata T., Kokame K., Matsumoto M., Fujimura Y. ADAMTS13 activity and genetic mutations in Japan. *Haemostaseologie*. 2013;33(2):131–7. <https://doi.org/10.5482/HAMO-12-11-0017>.
29. Furlan M., Lämmle B. Aetiology and pathogenesis of thrombotic thrombocytopenic purpura and haemolytic uraemic syndrome: the role of von Willebrand factor-cleaving protease. *Best Pract Res Clin Haematol*. 2001;14(2):437–54. <https://doi.org/10.1053/beha.2001.0142>.
30. Veyradier A., Meyer D., Loirat C. Desmopressin, an unexpected link between nocturnal enuresis and inherited thrombotic thrombocytopenic purpura (Upshaw–Schulman syndrome). *J Thromb Haemost*. 2006;4(3):700–1. <https://doi.org/10.1111/j.1538-7836.2005.01768.x>.

31. Loirat C., Girma J.-P., Desconclois C. et al. Thrombotic thrombocytopenic purpura related to severe ADAMTS13 deficiency in children. *Pediatr Nephrol.* 2009;24(1):19–29. <https://doi.org/10.1007/s00467-008-0863-5>.
32. Furlan M., Robles R., Morselli B. et al. Recovery and half-life of von Willebrand factor-cleaving protease after plasma therapy in patients with thrombotic thrombocytopenic purpura. *Thromb Haemost.* 1999;81(1):8–13.
33. Rock G.A., Shumak K.H., Buskard N.A. et al. Comparison of plasma exchange with plasma infusion in the treatment of thrombotic thrombocytopenic purpura. Canadian Apheresis Study Group. *N Engl J Med.* 1991;325(6):393–7. <https://doi.org/10.1056/NEJM199108083250604>.
34. Scully M., Hunt B.J., Benjamin S. et al. Guidelines on the diagnosis and management of thrombotic thrombocytopenic purpura and other thrombotic microangiopathies. *Br J Haematol.* 2012;158(3):323–35. <https://doi.org/10.1111/j.1365-2141.2012.09167.x>.
35. Scully M., Knöbl P., Kentouche K. et al. Recombinant ADAMTS-13: first-in-human pharmacokinetics and safety in congenital thrombotic thrombocytopenic purpura. *Blood.* 2017;130(19):2055–63. <https://doi.org/10.1182/blood-2017-06-788026>.
36. Plaimauer B., Hovinga J.A.K., Juno C. et al. Recombinant ADAMTS13 normalizes von Willebrand factor-cleaving activity in plasma of acquired TTP patients by overriding inhibitory antibodies. *J Thromb Haemost.* 2011;9(5):936–44. <https://doi.org/10.1111/j.1538-7836.2011.04224.x>.
37. Gasser C., Gautier E., Steck A. et al. Hemolytic-uremic syndrome: bilateral necrosis of the renal cortex in acute acquired hemolytic anemia. *Schweiz Med Wochenschr.* 1955;85(38–39):905–9. [Article in German].
38. Kiibel M., Barnard P. The haemolytic-uraemia syndrome: a survey in Southern Africa. *S Afr Med J.* 1968;42(27):692–8.
39. Karmali M., Petric M., Steele B., Lim C. Sporadic cases of haemolytic-uraemic syndrome associated with faecal cytotoxin and cytotoxin-producing *Escherichia coli* in stools. *Lancet.* 1983;321(8325):619–20. [https://doi.org/10.1016/s0140-6736\(83\)91795-6](https://doi.org/10.1016/s0140-6736(83)91795-6).
40. O'Brien A., Lively T., Chen M. et al. *Escherichia coli* 0157:H7 strains associated with haemorrhagic colitis in the United States produce a *Shigella dysenteriae* 1 (Shiga) like cytotoxin. *Lancet.* 1983;1(8326 Pt 1):702. [https://doi.org/10.1016/s0140-6736\(83\)91987-6](https://doi.org/10.1016/s0140-6736(83)91987-6).
41. Riley L.W., Remis R.S., Helgerson S.D. et al. Hemorrhagic colitis associated with a rare *Escherichia coli* serotype. *N Engl J Med.* 1983;308(12):681–5. <https://doi.org/10.1056/NEJM198303243081203>.

42. Tarr P.I., Gordon C.A., Chandler W.L. Shiga-toxin-producing *Escherichia coli* and haemolytic uraemic syndrome. *Lancet*. 2005;365(9464):1073–86. [https://doi.org/10.1016/S0140-6736\(05\)71144-2](https://doi.org/10.1016/S0140-6736(05)71144-2).
43. Proesmans W. The role of coagulation and fibrinolysis in the pathogenesis of diarrhea-associated hemolytic uremic syndrome. *Semin Thromb Hemost*. 2001;27(3):201–5. <https://doi.org/10.1055/s-2001-15249>.
44. Hosler G.A., Cusumano A.M., Hutchins G.M. Thrombotic thrombocytopenic purpura and hemolytic uremic syndrome are distinct pathologic entities: a review of 56 autopsy cases. *Arch Pathol Lab Med*. 2003;127(7):834–9. <https://doi.org/10.5858/2003-127-834-TTPAHU>.
45. Inward C.D., Howie A.J., Fitzpatrick M.M. et al. Renal histopathology in fatal cases of diarrhoea-associated haemolytic uraemic syndrome. British Association for Paediatric Nephrology. *Pediatr Nephrol*. 1997;11(5):556–9. <https://doi.org/10.1007/s004670050337>.
46. Menne J., Nitschke M., Stingele R. et al. Validation of treatment strategies for enterohaemorrhagic *Escherichia coli* O104: H4 induced haemolytic uraemic syndrome: case-control study. *BMJ*. 2012;345:e4565. <https://doi.org/10.1136/bmj.e4565>.
47. Barnard P., Kibel M. The haemolytic-uraemic syndrome of infancy and childhood. A report of eleven cases. *Cent Afr J Med*. 1965;11:4–11.
48. Kaplan B.S., Chesney R.W., Drummond K.N. Hemolytic uremic syndrome in families. *N Engl J Med*. 1975;292(21):1090–3. <https://doi.org/10.1056/NEJM197505222922102>.
49. Kaplan B.S. Hemolytic uremic syndrome with recurrent episodes: an important subset. *Clin Nephrol*. 1977;8(6):495–8.
50. Thompson R., Winterborn M. Hypocomplementaemia due to a genetic deficiency of beta 1H globulin. *Clin Exp Immunol*. 1981;46(1):110. <https://doi.org/>
51. Warwicker P., Goodship T.H., Donne R.L. et al. Genetic studies into inherited and sporadic hemolytic uremic syndrome. *Kidney Int*. 1998;53(4):836–44. <https://doi.org/10.1111/j.1523-1755.1998.00824.x>.
52. Legendre C., Licht C., Muus P. et al. Terminal complement inhibitor eculizumab in atypical hemolytic-uremic syndrome. *N Engl J Med*. 2013;368(23):2169–81. <https://doi.org/10.1056/NEJMoa1208981>.
53. Noris M., Caprioli J., Bresin E. et al. Relative role of genetic complement abnormalities in sporadic and familial aHUS and their impact on clinical phenotype. *Clin J Am Soc Nephrol*. 2010;5(10):1844–59. <https://doi.org/10.2215/CJN.02210310>.
54. Lemaire M., Frémeaux-Bacchi V., Schaefer F. et al. Recessive mutations in DGKE cause atypical hemolytic-uremic syndrome. *Nat Genet*. 2013;45(5):531–6. <https://doi.org/10.1038/ng.2590>.

55. Fremeaux-Bacchi V., Fakhouri F., Garnier A. et al. Genetics and outcome of atypical hemolytic uremic syndrome: a nationwide French series comparing children and adults. *Clin J Am Soc Nephrol.* 2013;8(4):554–62. <https://doi.org/10.2215/CJN.04760512>.
56. Fakhouri F., Roumenina L., Provot F. et al. Pregnancy-associated hemolytic uremic syndrome revisited in the era of complement gene mutations. *J Am Soc Nephrol.* 2010;21(5):859–67. <https://doi.org/10.1681/ASN.2009070706>.
57. Taylor C.M., Machin S., Wigmore S.J., Goodship T.H.; a working party from the Renal Association, the British Committee for Standards in Haematology and the British Transplantation Society. Clinical practice guidelines for the management of atypical haemolytic uraemic syndrome in the United Kingdom. *Br J Haematol.* 2010;148(1):37–47. <https://doi.org/10.1111/j.1365-2141.2009.07916.x>.
58. Noris M., Remuzzi G. Managing and preventing atypical hemolytic uremic syndrome recurrence after kidney transplantation. *Curr Opin Nephrol Hypertens.* 2013;22(6):704–12. <https://doi.org/10.1097/MNH.0b013e328365b3fe>.
59. Sack G.H., Levin J., Bell W.R. Trousseau's syndrome and other manifestations of chronic disseminated coagulopathy in patients with neoplasms: clinical, pathophysiologic, and therapeutic features. *Medicine (Baltimore).* 1977;56(1):1–37.
60. Elliott M.A., Letendre L., Gastineau D.A. et al. Cancer-associated microangiopathic hemolytic anemia with thrombocytopenia: an important diagnostic consideration. *Eur J Haematol.* 2010;85(1):43–50. <https://doi.org/10.1111/j.1600-0609.2010.01448.x>.
61. Domingo-Claros A., Larriba I., Rozman M. et al. Acute erythroid neoplastic proliferations. A biological study based on 62 patients. *Haematologica.* 2002;87(2):148–53.
62. Zheng X.L., Kaufman R.M., Goodnough L.T., Sadler J.E. Effect of plasma exchange on plasma ADAMTS13 metalloprotease activity, inhibitor level, and clinical outcome in patients with idiopathic and nonidiopathic thrombotic thrombocytopenic purpura. *Blood.* 2004;103(11):4043–9. <https://doi.org/10.1182/blood-2003-11-4035>.
63. Hyseni A., Kemperman H., de Lange D.W. et al. Active von Willebrand factor predicts 28-day mortality in patients with systemic inflammatory response syndrome. *Blood.* 2014;123(14):2153–6. <https://doi.org/10.1182/blood-2013-08-508093>.
64. Kerchberger V.E., Ware L.B. The role of circulating cell-free hemoglobin in sepsis-associated acute kidney injury. *Semin Nephrol.* 2020;40(2):148–59. <https://doi.org/10.1016/j.semnephrol.2020.01.006>.
65. Martin K., Borgel D., Lerolle N. et al. Decreased ADAMTS-13 (A disintegrin-like and metalloprotease with thrombospondin type 1 repeats) is associated with a poor prognosis in sepsis-

- induced organ failure. *Crit Care Med.* 2007;35(10):2375–82. <https://doi.org/10.1097/01.ccm.0000284508.05247.b3>.
66. Cao W., Krishnaswamy S., Camire R.M. et al. Factor VIII accelerates proteolytic cleavage of von Willebrand factor by ADAMTS13. *Proc Natl Acad Sci U S A.* 2008;105(21):7416–21. <https://doi.org/10.1073/pnas.0801735105>.
67. Mikes B., Sinkovits G., Farkas P. et al. Elevated plasma neutrophil elastase concentration is associated with disease activity in patients with thrombotic thrombocytopenic purpura. *Thromb Res.* 2014;133(4):616–21. <https://doi.org/10.1016/j.thromres.2014.01.034>.
68. Crawley J.T., Lam J.K., Rance J.B. et al. Proteolytic inactivation of ADAMTS13 by thrombin and plasmin. *Blood.* 2005;105(3):1085–93. <https://doi.org/10.1182/blood-2004-03-1101>.
69. Chen J., Fu X., Wang Y. et al. Oxidative modification of von Willebrand factor by neutrophil oxidants inhibits its cleavage by ADAMTS13. *Blood.* 2010;115(3):706–12. <https://doi.org/10.1182/blood-2009-03-213967>.
70. Lopez-Dee Z., Pidcock K., Gutierrez L.S. Thrombospondin-1: multiple paths to inflammation. *Mediators Inflamm.* 2011;2011. <https://doi.org/10.1155/2011/296069>.
71. Studt J.-D., Hovinga J.A.K., Antoine G. et al. Fatal congenital thrombotic thrombocytopenic purpura with apparent ADAMTS13 inhibitor: in vitro inhibition of ADAMTS13 activity by hemoglobin. *Blood.* 2005;105(2):542–4. <https://doi.org/10.1182/blood-2004-06-2096>.
72. Tersteeg C., de Maat S., De Meyer S.F. et al. Plasmin cleavage of von Willebrand factor as an emergency bypass for ADAMTS13 deficiency in thrombotic microangiopathy. *Circulation.* 2014;129(12):1320–31. <https://doi.org/10.1161/CIRCULATIONAHA.113.006727>.
73. Ono T., Mimuro J., Madoiwa S. et al. Severe secondary deficiency of von Willebrand factor–cleaving protease (ADAMTS13) in patients with sepsis-induced disseminated intravascular coagulation: its correlation with development of renal failure. *Blood.* 2006;107(2):528–34. <https://doi.org/10.1182/blood-2005-03-1087>
74. Kopic A.N., Hollriegl W., Plaimauer B. et al. Subcutaneous administration of ADAMTS13. US Patent App. 16/567,048; 2020.
75. Rossio R., Lotta L.A., Pontiggia S. et al. A novel CD46 mutation in a patient with microangiopathy clinically resembling thrombotic thrombocytopenic purpura and normal ADAMTS13 activity. *Haematologica.* 2015;100(3):e87–9. <https://doi.org/10.3324/haematol.2014.111062>.
76. Gianviti A., Tozzi A.E., De Petris L. et al. Risk factors for poor renal prognosis in children with hemolytic uremic syndrome. *Pediatr Nephrol.* 2003;18(12):1229–35. <https://doi.org/10.1007/s00467-003-1262-6>.

77. Joseph A., Cointe A., Mariani Kurkdjian P. et al. Shiga toxin-associated hemolytic uremic syndrome: a narrative review. *Toxins (Basel)*. 2020;12(2):67. <https://doi.org/10.3390/toxins12020067>.
78. Magro C., Mulvey J.J., Berlin D. et al. Complement associated microvascular injury and thrombosis in the pathogenesis of severe COVID-19 infection: a report of five cases. *Transl Res*. 2020;220:1–13. <https://doi.org/10.1016/j.trsl.2020.04.007>.
79. Bilgin E., Ertenli A.I. Proposal of a new nomenclature for the underlying pathogenetic mechanism of severe coronavirus disease-19: “inflammatory thrombosis with immune endotheliitis – ITIE”. *Rheumatol Int*. 2021;41(3):679–80. <https://doi.org/10.1007/s00296-020-04768-1>.
80. Meizlish M.L., Pine A.B., Goshua G. et al. Circulating markers of angiogenesis and endotheliopathy in COVID-19. *medRxiv*. 2020;2020.06.29.20140376. <https://doi.org/10.1101/2020.06.29.20140376>. Preprint.
81. Teuwen L.-A., Geldhof V., Pasut A., Carmeliet P. COVID-19: the vasculature unleashed. *Nat Rev Immunol*. 2020;20(7):389–91. <https://doi.org/10.1038/s41577-020-0343-0>.
82. Mohamed M.M., Lukitsch I., Torres-Ortiz A.E. et al. Acute kidney injury associated with coronavirus disease 2019 in urban New Orleans. *Kidney360*. 2020;1:614–22. <https://doi.org/10.34067/KID.0002652020>.
83. Su H., Yang M., Wan C. et al. Renal histopathological analysis of 26 postmortem findings of patients with COVID-19 in China. *Kidney Int*. 2020;98(1):219–27. <https://doi.org/10.1016/j.kint.2020.04.003>
84. Fox S.E., Akmatbekov A., Harbert J.L. et al. Pulmonary and cardiac pathology in African American patients with COVID-19: an autopsy series from New Orleans. *Lancet Respir Med*. 2020;8(7):681–6. [https://doi.org/10.1016/S2213-2600\(20\)30243-5](https://doi.org/10.1016/S2213-2600(20)30243-5).
85. Carsana L., Sonzogni A., Nasr A. et al. Pulmonary post-mortem findings in a series of COVID-19 cases from northern Italy: a two-centre descriptive study. *Lancet Infect Dis*. 2020;20(10):1135–40. [https://doi.org/10.1016/S1473-3099\(20\)30434-5](https://doi.org/10.1016/S1473-3099(20)30434-5).
86. Rapkiewicz A.V., Mai X., Carsons S.E. et al. Megakaryocytes and platelet-fibrin thrombi characterize multi-organ thrombosis at autopsy in COVID-19: a case series. *EClinicalMedicine*. 2020;24:100434. <https://doi.org/10.1016/j.eclinm.2020.100434>.
87. Menter T., Haslbauer J.D., Nienhold R. et al. Postmortem examination of COVID-19 patients reveals diffuse alveolar damage with severe capillary congestion and variegated findings in lungs and other organs suggesting vascular dysfunction. *Histopathology*. 2020;77(2):198–209. <https://doi.org/10.1111/his.14134>.
88. Jhaveri K.D., Meir L.R., Chang B.S.F. et al. Thrombotic microangiopathy in a patient with COVID-19. *Kidney Int*. 2020;98(2):509–12. <https://doi.org/10.1016/j.kint.2020.05.025>.



89. Sharma P., Uppal N.N., Wanchoo R. et al. COVID-19–associated kidney injury: a case series of kidney biopsy findings. *J Am Soc Nephrol.* 2020;31(9):1948–58. <https://doi.org/10.1681/ASN.2020050699>.
90. da Silva R.L. Viral-associated thrombotic microangiopathies. *Hematol Oncol Stem Cell Ther.* 2011;4(2):51–9. <https://doi.org/10.5144/1658-3876.2011.51>.
91. Hindilerden F., Yonal-Hindilerden I., Akar E., Kart-Yasar K. Covid-19 associated autoimmune thrombotic thrombocytopenic purpura: report of a case. *Thromb Res.* 2020;195:136–8. <https://doi.org/10.1016/j.thromres.2020.07.005>.
92. Capecchi M., Mocellin C., Abbruzzese C. et al. Dramatic presentation of acquired thrombotic thrombocytopenic purpura associated with COVID-19. *Haematologica.* 2020;105(10):e540. <https://doi.org/10.3324/haematol.2020.262345>.
93. Varga Z., Flammer A.J., Steiger P. et al. Endothelial cell infection and endotheliitis in COVID-19. *Lancet.* 2020;395(10234):1417–18. [https://doi.org/10.1016/S0140-6736\(20\)30937-5](https://doi.org/10.1016/S0140-6736(20)30937-5).
94. Nicholson P., Alshafai L., Krings T. Neuroimaging findings in patients with COVID-19. *AJNR Am J Neuroradiol.* 2020;41(8):1380–3. <https://doi.org/10.3174/ajnr.A6630>.
95. Bentley M.J., Lehman C.M., Blaylock R.C. et al. The utility of patient characteristics in predicting severe ADAMTS13 deficiency and response to plasma exchange. *Transfusion.* 2010;50(8):1654–64. <https://doi.org/10.1111/j.1537-2995.2010.02653.x>.
96. Coppo P., Schwarzinger M., Buffet M. et al. Predictive features of severe acquired ADAMTS13 deficiency in idiopathic thrombotic microangiopathies: the French TMA reference center experience. *PLoS One.* 2010;5(4):e10208. <https://doi.org/10.1371/journal.pone.0010208>.
97. Bendapudi P.K., Hurwitz S., Fry A. et al. Derivation and external validation of the PLASMIC score for rapid assessment of adults with thrombotic microangiopathies: a cohort study. *Lancet Haematol.* 2017;4(4):e157–e164. [https://doi.org/10.1016/S2352-3026\(17\)30026-1](https://doi.org/10.1016/S2352-3026(17)30026-1).
98. Brocklebank V., Wood K.M., Kavanagh D. Thrombotic microangiopathy and the kidney. *Clin J Am Soc Nephrol.* 2018;13(2):300–17. <https://doi.org/10.2215/CJN.00620117>.
99. Sciascia S., Yazdany J., Dall'Era M. et al. Anticoagulation in patients with concomitant lupus nephritis and thrombotic microangiopathy: a multicentre cohort study. *Ann Rheum Dis.* 2018;78(7):1014–6. <https://doi.org/10.1136/annrheumdis-2018-214559>.
100. Go R.S., Winters J.L., Leung N. et al. Thrombotic microangiopathy care pathway: a consensus statement for the Mayo clinic complement alternative Pathway-Thrombotic microangiopathy (CAP-TMA) Disease-Oriented group. *Mayo Clin Proc.* 2016;91(9):1189–211. <https://doi.org/10.1016/j.mayocp.2016.05.015>.

101. Rico-Mesa J.S., Rosas D., Ahmadian-Tehrani A. et al. The role of anticoagulation in COVID-19-induced hypercoagulability. *Curr Cardiol Rep.* 2020;22(7):53. <https://doi.org/10.1007/s11886-020-01328-8>.
102. Bell W.R., Braine H.G., Ness P.M., Kickler T.S. Improved survival in thrombotic thrombocytopenic purpura–hemolytic uremic syndrome: clinical experience in 108 patients. *N Engl J Med.* 1991;325(6):398–403. <https://doi.org/10.1056/NEJM199108083250605>.
103. Dane K., Chaturvedi S. Beyond plasma exchange: novel therapies for thrombotic thrombocytopenic purpura. *Hematology Am Soc Hematol Educ Program.* 2018;2018(1):539–47. <https://doi.org/10.1182/asheducation-2018.1.539>.
104. Zielińska K.A., Van Moortel L., Opendakker G. et al. Endothelial response to glucocorticoids in inflammatory diseases. *Front Immunol.* 2016;7:592. <https://doi.org/10.3389/fimmu.2016.00592>.
105. Weiler J., Packard B. Methylprednisolone inhibits the alternative and amplification pathways of complement. *Infect Immun.* 1982;38(1):122–6. <https://doi.org/10.1128/iai.38.1.122-126.1982>.
106. Limbourg F.P., Huang Z., Plumier J.-C. et al. Rapid nontranscriptional activation of endothelial nitric oxide synthase mediates increased cerebral blood flow and stroke protection by corticosteroids. *J Clin Invest.* 2002;110(11):1729–38. <https://doi.org/10.1172/JCI15481>.
107. Ruan Q., Yang K., Wang W. et al. Clinical predictors of mortality due to COVID-19 based on an analysis of data of 150 patients from Wuhan, China. *Intensive Care Med.* 2020;46(5):846–8. <https://doi.org/10.1007/s00134-020-05991-x>.
108. RECOVERY Collaborative Group; Horby P., Lim W.S., Emberson J.R. et al. Dexamethasone in hospitalized patients with Covid-19. *N Engl J Med.* 2021;384(8):693–704. <https://doi.org/10.1056/NEJMoa2021436>.
109. Corral-Gudino L., Bahamonde A., Arnaiz-Revillas F. et al. GLUCOCOVID: a controlled trial of methylprednisolone in adults hospitalized with COVID-19 pneumonia. *medRxiv.* June 18, 2020. Preprint. <https://doi.org/10.1101/2020.06.17.20133579>.
110. Zaki A.M., van Boheemen S., Bestebroer T.M. et al. Isolation of a novel coronavirus from a man with pneumonia in Saudi Arabia. *N Engl J Med.* 2012;367(19):1814–20. <https://doi.org/10.1056/NEJMoa1211721>.
111. Ohta R., Torii Y., Imai M. et al. Serum concentrations of complement anaphylatoxins and proinflammatory mediators in patients with 2009 H1N1 influenza. *Microbiol Immunol.* 2011;55(3):191–8. <https://doi.org/10.1111/j.1348-0421.2011.00309.x>.

112. Jiang Y., Zhao G., Song N. et al. Blockade of the C5a–C5aR axis alleviates lung damage in hDPP4-transgenic mice infected with MERS-CoV. *Emerg Microbes Infect.* 2018;7(1):1–12. <https://doi.org/10.1038/s41426-018-0063-8>.
113. O'Brien K.B., Morrison T.E., Dundore D.Y. et al. A protective role for complement C3 protein during pandemic 2009 H1N1 and H5N1 influenza A virus infection. *PLoS One.* 2011;6(3):e17377. <https://doi.org/10.1371/journal.pone.0017377>.
114. Sun S., Zhao G., Liu C. et al. Inhibition of complement activation alleviates acute lung injury induced by highly pathogenic avian influenza H5N1 virus infection. *Am J Respir Cell Mol Biol.* 2013;49(2):221–30. <https://doi.org/10.1165/rcmb.2012-0428OC>.
115. Gralinski L.E., Sheahan T.P., Morrison T.E. et al. Complement activation contributes to severe acute respiratory syndrome coronavirus pathogenesis. *mBio.* 2018;9(5):e01753–18. <https://doi.org/10.1128/mBio.01753-18>.
116. Stoermer K.A., Morrison T.E. Complement and viral pathogenesis. *Virology.* 2011;411(2):362–73. <https://doi.org/10.1016/j.virol.2010.12.045>.
117. Diurno F., Numis F., Porta G. et al. Eculizumab treatment in patients with COVID-19: preliminary results from real life ASL Napoli 2 Nord experience. *Eur Rev Med Pharmacol Sci.* 2020;24(7):4040–7. [https://doi.org/10.26355/eurrev\\_202004\\_20875](https://doi.org/10.26355/eurrev_202004_20875).
118. Home. ClinicalTrials.gov. Available at: <https://clinicaltrials.gov>.
119. Mastaglio S., Ruggeri A., Risitano A.M. et al. The first case of COVID-19 treated with the complement C3 inhibitor AMY-101. *Clin Immunol.* 2020;215:108450. <https://doi.org/10.1016/j.clim.2020.108450>.
120. Winters J.L. Plasma exchange in thrombotic microangiopathies (TMAs) other than thrombotic thrombocytopenic purpura (TTP). *Hematology Am Soc Hematol Educ Program.* 2017;2017(1):632–8. <https://doi.org/10.1182/asheducation-2017.1.632>.
121. Albiol N., Awol R., Martino R. Autoimmune thrombotic thrombocytopenic purpura (TTP) associated with COVID-19. *Ann Hematol.* 2020;99(7):1673–4. <https://doi.org/10.1007/s00277-020-04097-0>.
122. Khamis F., Al-Zakwani I., Al Hashmi S. et al. Therapeutic plasma exchange in adults with severe COVID-19 infection. *Int J Infect Dis.* 2020;99:214–8. <https://doi.org/10.1016/j.ijid.2020.06.064>.
123. Gucyetmez B., Atalan H.K., Sertdemir I. et al. Therapeutic plasma exchange in patients with COVID-19 pneumonia in intensive care unit: a retrospective study. *Crit Care.* 2020;24(1):492. <https://doi.org/10.1186/s13054-020-03215-8>.

124. Wang Y., Huo P., Dai R. et al. Convalescent plasma may be a possible treatment for COVID-19: a systematic review. *Int Immunopharmacol.* 2021;91:107262. <https://doi.org/10.1016/j.intimp.2020.107262>.
125. Casadevall A., Joyner M.J., Pirofski L.-A. A randomized trial of convalescent plasma for COVID-19 – potentially hopeful signals. *JAMA.* 2020;324(5):455–7. <https://doi.org/10.1001/jama.2020.10218>.
126. Rojas M., Rodríguez Y., Monsalve D.M. et al. Convalescent plasma in Covid-19: Possible mechanisms of action. *Autoimmun Rev.* 2020;19(7):102554. <https://doi.org/10.1016/j.autrev.2020.102554>.
127. Guilpain P., Le Bihan C., Foulongne V. et al. Rituximab for granulomatosis with polyangiitis in the pandemic of covid-19: lessons from a case with severe pneumonia. *Ann Rheum Dis.* 2021;80(1):e10. <https://doi.org/10.1136/annrheumdis-2020-217549>.
128. Callewaert F., Roodt J., Ulrichs H. et al. Evaluation of efficacy and safety of the anti-VWF Nanobody ALX-0681 in a preclinical baboon model of acquired thrombotic thrombocytopenic purpura. *Blood.* 2012;120(17):3603–10. <https://doi.org/10.1182/blood-2012-04-420943>.
129. Scully M., Cataland S.R., Peyvandi F. et al. Caplacizumab treatment for acquired thrombotic thrombocytopenic purpura. *N Engl J Med.* 2019;380(4):335–46. <https://doi.org/10.1056/NEJMoa1806311>.

#### **About the authors:**

**Ekaterina V. Slukhanchuk** – MD, PhD, Associate Professor, Department of Obstetrics and Gynecology, Filatov Clinical Institute of Children’s Health, Sechenov University, Moscow Russia; Obstetrician-Gynecologist, Department of Abdominal Surgery and Oncology 2, Petrovsky National Research Centre of Surgery, Moscow, Russia. E-mail: [beloborodova@rambler.ru](mailto:beloborodova@rambler.ru). ORCID: <https://orcid.org/0000-0001-7441-2778>.

**Victoria O. Bitsadze** – MD, Dr Sci Med, Professor of RAS, Professor, Department of Obstetrics and Gynecology, Filatov Clinical Institute of Children’s Health, Sechenov University, Moscow, Russia. ORCID: <https://orcid.org/0000-0001-8404-1042>. Scopus Author ID: 6506003478. Researcher ID: F-8409-2017.

**Jamilya Kh. Khizroeva** – MD, Dr Sci Med, Professor, Department of Obstetrics and Gynecology, Filatov Clinical Institute of Children’s Health, Sechenov University, Moscow, Russia. ORCID: <https://orcid.org/0000-0002-0725-9686>. Scopus Author ID: 57194547147. Researcher ID: F-8384-2017.

**Maria V. Tretyakova** – MD, PhD, Obstetrician-Gynecologist, Assistant, Department of Obstetrics and Gynecology, Filatov Clinical Institute of Children's Health, Sechenov University, Moscow, Russia. ORCID: <https://orcid.org/0000-0002-3628-0804>.

**Andrey S. Shkoda** – MD, Dr Sci Med, Professor, Chief Physician, Vorokhobov City Clinical Hospital № 67, Moscow, Russia. ORCID: <https://orcid.org/0000-0002-9783-1796>.

**Oleg P. Artyukov** – MD, PhD, Associate Professor, Department of Nervous Diseases and Neurosurgery, Peoples' Friendship University of Russia, Moscow, Russia. ORCID: <https://orcid.org/0000-0001-7758-4006>.

**Valentina I. Tsibizova** – MD, PhD, Obstetrician-Gynecologist, Research Laboratory of Operative Gynecology, Institute of Perinatology and Pediatrics; Physician, Department of Functional and Ultrasound Diagnostics, Almazov National Medical Research Centre, Saint Petersburg, Russia. ORCID: <https://orcid.org/0000-0001-5888-0774>.

**Alexander L. Mishchenko** – MD, Dr Sci Med, Professor, Department of Obstetrics and Gynecology, Filatov Clinical Institute of Children's Health, Sechenov University, Moscow, Russia.

**Kristina N. Grigoreva** – MD, Medical Resident, Department of Obstetrics and Gynecology, Filatov Clinical Institute of Children's Health, Sechenov University, Moscow, Russia. ORCID: <https://orcid.org/0000-0002-7756-8935>.

**Jean-Christophe Gris** – MD, Dr Sci Med, Professor, Department of Obstetrics and Gynecology, Filatov Clinical Institute of Children's Health, Sechenov University, Moscow, Russia; University of Montpellier, Montpellier, France. ORCID: <https://orcid.org/0000-0002-9899-9910>. Scopus Author ID: 7005114260. Researcher ID: AAA-2923-2019.

**Ismail Elalamy** – MD, Dr Sci Med, Professor, Department of Obstetrics and Gynecology, Filatov Clinical Institute of Children's Health, Sechenov University, Moscow, Russia; Professor, Medicine Sorbonne University, Paris, France; Director of Hematology, Department of Thrombosis Center, Hospital Tenon, Paris, France. ORCID: <https://orcid.org/0000-0002-9576-1368>. Scopus Author ID: 7003652413. Researcher ID: AAC-9695-2019.

**Alexander D. Makatsariya** – MD, Dr Sci Med, Academician of RAS, Professor, Head of the Department of Obstetrics and Gynecology, Filatov Clinical Institute of Children's Health, Sechenov University, Moscow, Russia. ORCID: <https://orcid.org/0000-0001-7415-4633>. Scopus Author ID: 57222220144. Researcher ID: M-5660-2016.

#### **Сведения об авторах:**

**Слуханчук Екатерина Викторовна** – к.м.н., доцент кафедры акушерства и гинекологии Клинического института детского здоровья имени Н.Ф. Филатова ФГАОУ ВО Первый Московский государственный медицинский университет имени И.М. Сеченова Министерства здравоохранения Российской Федерации (Сеченовский Университет), Москва,

Россия; врач акушер-гинеколог отделения абдоминальной хирургии и онкологии 2, ФГБНУ «Российский научный центр хирургии имени академика Б.В. Петровского», Москва, Россия. E-mail: [beloborodova@rambler.ru](mailto:beloborodova@rambler.ru). ORCID: <https://orcid.org/0000-0001-7441-2778>.

**Бицадзе Виктория Омаровна** – д.м.н., профессор РАН, профессор кафедры акушерства и гинекологии Клинического института детского здоровья имени Н.Ф. Филатова ФГАОУ ВО Первый Московский государственный медицинский университет имени И.М. Сеченова Министерства здравоохранения Российской Федерации (Сеченовский Университет), Москва, Россия. ORCID: <https://orcid.org/0000-0001-8404-1042>. Scopus Author ID: 6506003478. Researcher ID: F-8409-2017.

**Хизроева Джамиля Хизриевна** – д.м.н., профессор кафедры акушерства и гинекологии Клинического института детского здоровья имени Н.Ф. Филатова ФГАОУ ВО Первый Московский государственный медицинский университет имени И.М. Сеченова Министерства здравоохранения Российской Федерации (Сеченовский университет), Москва, Россия. ORCID: <https://orcid.org/0000-0002-0725-9686>. Scopus Author ID: 57194547147. Researcher ID: F-8384-2017.

**Третьякова Мария Владимировна** – к.м.н., врач акушер-гинеколог, ассистент кафедры акушерства и гинекологии Клинического института детского здоровья имени Н.Ф. Филатова ФГАОУ ВО Первый Московский государственный медицинский университет имени И.М. Сеченова Министерства здравоохранения Российской Федерации (Сеченовский университет), Москва, Россия. ORCID: <https://orcid.org/0000-0002-3628-0804>.

**Шкода Андрей Сергеевич** – д.м.н., профессор, главный врач ГБУЗ «Городская клиническая больница № 67 имени Л.А. Ворохобова Департамента здравоохранения города Москвы», Москва, Россия. ORCID: <https://orcid.org/0000-0002-9783-1796>.

**Артюков Олег Петрович** – к.м.н., доцент кафедры нервных болезней и нейрохирургии ФГАОУ ВО «Российский университет дружбы народов», Москва, Россия. ORCID: <https://orcid.org/0000-0001-7758-4006>.

**Цибизова Валентина Ивановна** – к.м.н., акушер-гинеколог НИЛ оперативной гинекологии Института перинатологии и педиатрии; врач отделения функциональной и ультразвуковой диагностики ФГБУ «Национальный медицинский исследовательский центр имени В.А. Алмазова» Министерства здравоохранения Российской Федерации, Санкт-Петербург, Россия. ORCID: <https://orcid.org/0000-0001-5888-0774>.

**Мищенко Александр Леонидович** – д.м.н., профессор кафедры акушерства и гинекологии Клинического института детского здоровья имени Н.Ф. Филатова ФГАОУ ВО Первый Московский государственный медицинский университет имени И.М. Сеченова

Министерства здравоохранения Российской Федерации (Сеченовский Университет), Москва, Россия.

**Григорьева Кристина Николаевна** – ординатор кафедры акушерства и гинекологии Клинического института детского здоровья имени Н.Ф. Филатова ФГАОУ ВО Первый Московский государственный медицинский университет имени И.М. Сеченова Министерства здравоохранения Российской Федерации (Сеченовский университет), Москва, Россия. ORCID: <https://orcid.org/0000-0002-7756-8935>.

**Гри Жан-Кристоф** – д.м.н., профессор кафедры акушерства и гинекологии Клинического института детского здоровья имени Н.Ф. Филатова ФГАОУ ВО Первый Московский государственный медицинский университет имени И.М. Сеченова Министерства здравоохранения Российской Федерации (Сеченовский университет), Москва, Россия; профессор гематологии, университет Монпелье, Монпелье, Франция. ORCID: <https://orcid.org/0000-0002-9899-9910>. Scopus Author ID: 7005114260. Researcher ID: AAA-2923-2019.

**Элалами Исмаил** – д.м.н., профессор кафедры акушерства и гинекологии Клинического института детского здоровья имени Н.Ф. Филатова ФГАОУ ВО Первый Московский государственный медицинский университет имени И.М. Сеченова Министерства здравоохранения Российской Федерации (Сеченовский университет), Москва, Россия; профессор медицинского Университета Сорбонны, Париж, Франция; директор гематологии Центра Тромбозов, Госпиталь Тенон, Париж, Франция. ORCID: <https://orcid.org/0000-0002-9576-1368>. Scopus Author ID: 7003652413. Researcher ID: AAC-9695-2019.

**Макацария Александр Давидович** – д.м.н., профессор, академик РАН, зав. кафедрой акушерства и гинекологии Клинического института детского здоровья имени Н.Ф. Филатова ФГАОУ ВО Первый Московский государственный медицинский университет имени И.М. Сеченова Министерства здравоохранения Российской Федерации (Сеченовский Университет), Москва, Россия. ORCID: <https://orcid.org/0000-0001-7415-4633>. Scopus Author ID: 57222220144. Researcher ID: M-5660-2016.