



HAL
open science

Profound bilateral deafness complicating aortic arch surgery

Fabienne Carré, Elisabeth Mamelle, Suzanne Ferrier, Paul Achouh

► **To cite this version:**

Fabienne Carré, Elisabeth Mamelle, Suzanne Ferrier, Paul Achouh. Profound bilateral deafness complicating aortic arch surgery. *Interactive Cardiovascular and Thoracic Surgery*, 2021, 32 (2), pp.330-332. 10.1093/icvts/ivaa256 . hal-03507748

HAL Id: hal-03507748

<https://hal.sorbonne-universite.fr/hal-03507748v1>

Submitted on 3 Jan 2022

HAL is a multi-disciplinary open access archive for the deposit and dissemination of scientific research documents, whether they are published or not. The documents may come from teaching and research institutions in France or abroad, or from public or private research centers.

L'archive ouverte pluridisciplinaire **HAL**, est destinée au dépôt et à la diffusion de documents scientifiques de niveau recherche, publiés ou non, émanant des établissements d'enseignement et de recherche français ou étrangers, des laboratoires publics ou privés.

Title

Profound bilateral deafness complicating aortic arch surgery

Authors

Fabienne CARRÉ¹, Elisabeth MAMELLE², Suzanne FERRIER¹, Paul ACHOUH³

Institutions

1 : ENT department, Georges Pompidou European Hospital, AP-HP, 20-40, rue Leblanc, 75015 Paris and Université de Paris, France

2 : ENT department, AP-HP, Sorbonne Université, Hôpital Rothschild, 5 rue Santerre, Paris, France

3 : Cardiovascular surgery department, Georges Pompidou European Hospital, AP-HP, 20-40, rue Leblanc, 75015 Paris, and Université de Paris, France

Corresponding author

Fabienne CARRÉ

Fabienne.carre@aphp.fr

Word count: 996

Abstract

Hearing loss is a rare complication of cardiac surgery; bilateral profound deafness has never been reported. A 45-year-old male presented with profound bilateral sudden deafness following arch surgery and frozen elephant trunk. Patient's presentation, surgery details, and etiological mechanisms are discussed.

Keywords

Bilateral deafness

Extracorporeal circulation

Circulatory arrest

Frozen elephant trunk

Introduction

Sudden sensorineural hearing loss (SSNHL) is defined as hearing loss of more than 30 dB in at least three contiguous audiometric frequencies developing in less than 3 days. It is most often unilateral, with a prevalence of 5 to 27 cases per 100,000 people [1]. In adults, most cases are idiopathic. The etiopathogenic mechanisms are still unknown and supposed to be multifactorial. Distal microcirculation damage is incriminated. Risk factors similar to those of cardiovascular disease have been suggested. Bilateral SSNHL accounts for only 5% of cases and represents a medical emergency.

We describe the first case of profound bilateral SSNHL following aortic arch surgery under circulatory arrest and use of a "frozen elephant trunk" (FET).

Observation

A 45-year-old African patient, with no past medical history and normal preoperative hearing, was referred and managed surgically a week after a type A aortic dissection. The intervention consisted of replacement of the ascending aorta and arch using a 10 cm long "frozen elephant trunk" (Thoraflex®, Terumo) and separate reimplantation of the brachiocephalic arterial trunk and left common carotid artery. The left subclavian artery was not reimplanted. The procedure was performed under moderate hypothermic circulatory arrest (minimal bladder temperature at 24.6°C and minimal oesophageal temperature at 21.9°C) and bilateral antegrade cerebral perfusion. Extracorporeal circulation (ECC) time was 188 minutes, aortic cross-clamping 102 minutes and circulatory arrest time 31 minutes. The patient was reoperated within 48 hours for haemostasis.

Upon extubation, the patient reported profound bilateral deafness. Tinnitus were associated. Otoscopy was normal. Specialized neurological examination found an isolated cerebellar syndrome.

Tonal audiometry found severe to profound bilateral and symmetrical hearing loss. Vocal audiometry found no speech intelligibility. Temporal bone CT-scan was normal. The cerebral MRI found multiple small superficial and deep infarctions associated with micro-bleedings (Figure 2). The multiplicity and size of infarctions evoked an embolic mechanism.

The serological assessment found an old cured toxoplasmosis, negative hepatitis B and C serologies, as well as negative HSV and VZV PCR. The patient benefited from a 5-day corticosteroid treatment at 1 mg/kg/day, combined with an antiplatelet treatment.

At one-month follow-up, the patient showed bilateral slight improvement with a twenty-decibels gain and a bell-shaped vocal audiometry (Figure1) and described an auditory fatigue. These data supported a retrocochlear component such as auditory neuropathy.

Discussion

This is the first reported case of profound bilateral SSNHL complicating cardiac surgery with circulatory arrest and placement of a FET.

The pathophysiological factors most commonly associated with bilateral SSNHL are toxic, neoplastic, vascular and autoimmune. Bilateral SSNHL is associated with an overall mortality rate of 16% [1].

A limited number of articles have studied the association of hearing loss with ECC, reporting few cases of unilateral SSNHL [2]. Only one case of mild bilateral SSNHL,

spontaneously resolving within 24 hours, has been reported after ECC for mitral repair [3]. No SSNHL have been described after aortic surgery with circulatory arrest or placement of a FET.

The pathophysiological hypotheses for hearing loss are based on micro-embolic mechanism, a state of underlying hypercoagulability and intraoperative hypotension leading to cerebral hypoperfusion [4]. The most likely explanation in this case is bilateral occlusion of the cochlear branch of the internal auditory artery, provoking ischemia of the cochlea and cochlear nerve, resulting in an endo and retrocochlear deafness. Cerebral hypoperfusion during circulatory arrest may have aggravated the ischemic phenomenon.,. This hypothesis is supported by MRI, which shows other micro-embolic lesions, even if no cochlear lesion or internal auditory canal is highlighted. Neurovascular complications affect 1 to 3% of patients after cardiac surgery with ECC. Aortic arch and supra-aortic vessels surgeries are particularly at risk. This risk increases after circulatory arrest and especially in the context of aortic dissection, reaching an incidence of 10 to 15% [5]. Otherwise, no ototoxicity is reported with the anaesthesia protocol or preoperative antibiotics used in this case.

Conclusion

We report the first case of profound bilateral SSNHL complicating cardiac surgery with circulatory arrest and placement of FET. Little is known about the auditory consequences of such procedures. Prospective studies should be led to identify such adverse effects.

Funding: none

Declaration of interest: none declared.

Figure 1.

Postoperative cerebral MRI. A. Diffusion-weighted sequence: multiple punctate hypersignals related to recent ischemic lesions. B. T2* sequence: cortical micro-bleedings (arrow). C. T2 sequence: integrity of hearing structures.

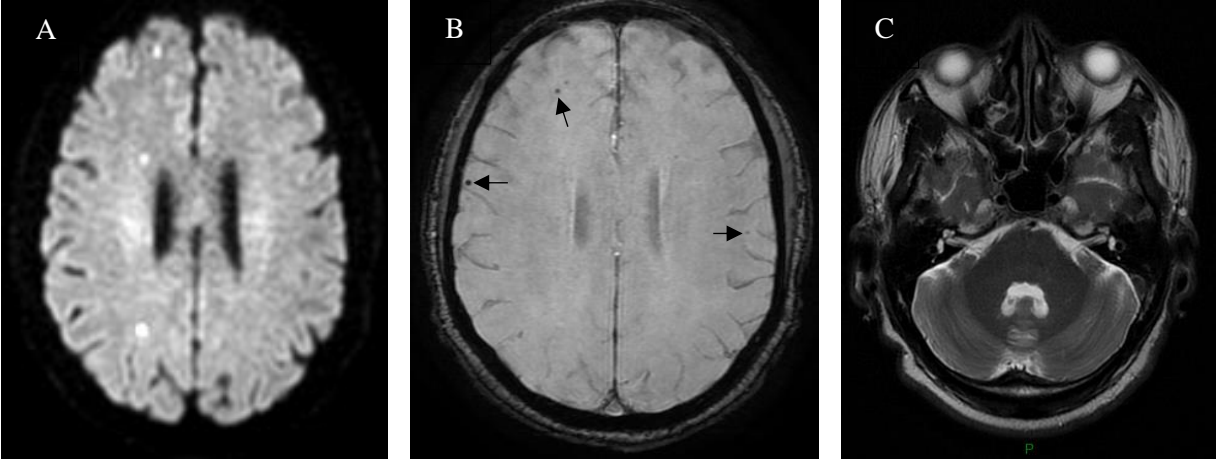
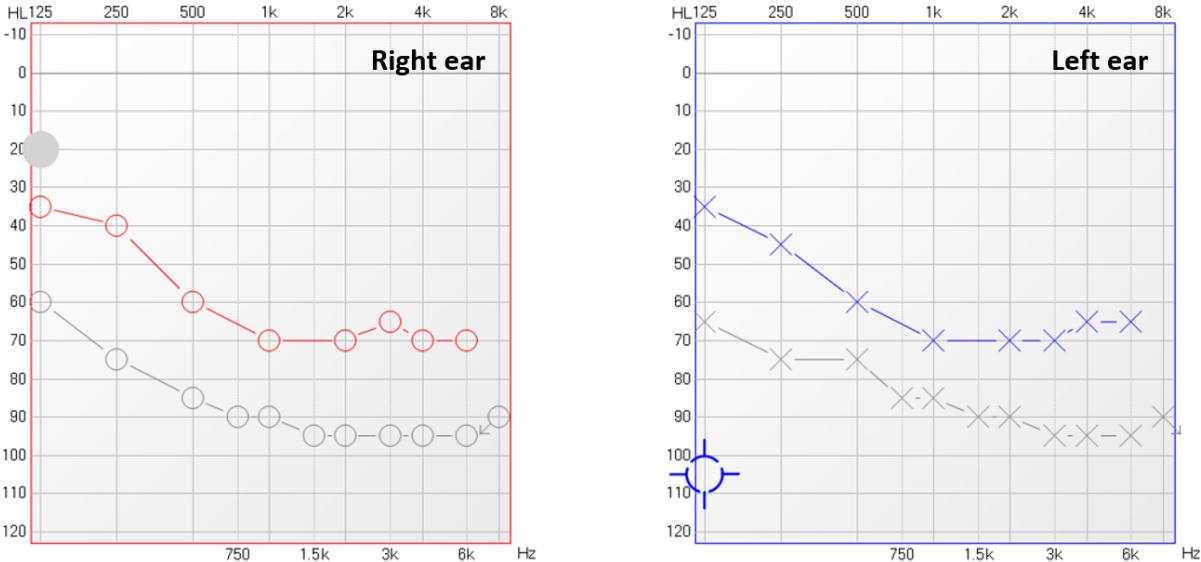


Figure 2.

Tonal audiometry at day 7 (grey) and day 30 (coloured) from cardiac surgery.



References

- [1] Chandrasekhar SS, Tsai Do BS, Schwartz SR, Bontempo LJ, Faucett EA, Finestone SA, et al. Clinical Practice Guideline: Sudden Hearing Loss (Update). *Otolaryngol Head Neck Surg* 2019;161:S1-45.
- [2] Walsted A, Andreassen UK, Berthelsen PG, Olesen A. Hearing loss after cardiopulmonary bypass surgery. *Eur Arch Otorhinolaryngol* 2000;257:124–7.
- [3] Son HJ, Joh JH, Kim WJ, Chin JH, Choi DK, Lee EH, et al. Temporary bilateral sensorineural hearing loss following cardiopulmonary bypass -A case report-. *Korean J Anesthesiol* 2011;61:162–5.
- [4] Shapiro MJ, Purn JM, Raskin C. A study of the effects of cardiopulmonary bypass surgery on auditory function. *Laryngoscope* 1981;91:2046–52.
- [5] Evangelista A, Isselbacher EM, Bossone E, Gleason TG, Eusanio MD, Sechtem U, et al. Insights From the International Registry of Acute Aortic Dissection: A 20-Year Experience of Collaborative Clinical Research. *Circulation* 2018;137:1846–60.