



HAL
open science

Anti-RNP antibodies delineate a subgroup of myositis: A systematic retrospective study on 46 patients

Nadège Wesner, Akinori Uruha, Shigeaki Suzuki, Kubéraka Mariampillai,
Benjamin Granger, Nicolas Champtiaux, Aude Rigolet, Yoland Schoindre,
Sylvain Lejeune, Perrine Guillaume-Jugnot, et al.

► **To cite this version:**

Nadège Wesner, Akinori Uruha, Shigeaki Suzuki, Kubéraka Mariampillai, Benjamin Granger, et al..
Anti-RNP antibodies delineate a subgroup of myositis: A systematic retrospective study on 46 patients.
Autoimmunity Reviews, 2020, 19, 10.1016/j.autrev.2020.102465 . hal-03523398

HAL Id: hal-03523398

<https://hal.sorbonne-universite.fr/hal-03523398>

Submitted on 12 Jan 2022

HAL is a multi-disciplinary open access archive for the deposit and dissemination of scientific research documents, whether they are published or not. The documents may come from teaching and research institutions in France or abroad, or from public or private research centers.

L'archive ouverte pluridisciplinaire **HAL**, est destinée au dépôt et à la diffusion de documents scientifiques de niveau recherche, publiés ou non, émanant des établissements d'enseignement et de recherche français ou étrangers, des laboratoires publics ou privés.



Anti-RNP antibodies delineate a subgroup of myositis: A systematic retrospective study on 46 patients



Inflammatory myopathies are a heterogeneous group of autoimmune diseases ranging from muscle-specific diseases to systemic disorders. Myositis can occur as a specific entity or as a part of a spectrum of non-specific connective tissue disorders, including mixed connective tissue disease and systemic lupus erythematosus. Myositis-specific antibodies (MSAs) or non-specific/associated antibodies (MAAs) are autoantibodies frequently described with myositis. Presence of MSA allows to create homogeneous patient subgroups [1]. Nevertheless, the potential ability of MAAs to individualize homogeneous subgroups of myositis remains unknown. Anti-U1 small nuclear ribonucleoprotein particle (RNP) antibodies are among the most prevalent MAAs (approximately 15%) [2]. Despite its relatively frequent prevalence, anti-RNP antibody-positive (RNP⁺) myositis patients have been poorly described [3–5]. We analyze accurately the anti-RNP+ clinical phenotype, including muscle (with pathological analysis) and extra-muscle manifestations, and compare to myositis without RNP antibodies (anti-RNP-).

This international (French-Japanese) multicentric retrospective study included patients diagnosed with myositis accordingly to Bohan and Peter criteria [6] and anti-RNP antibody positivity. The anti-RNP-control cohort included myositis patients excepted those with inclusion body myositis (because of its very distinct phenotype [7]). Anti-RNP+ patients were defined based on positive RNA immunoprecipitation as previously described [8]. Muscle samples were analyzed by two independent experts in myopathology (S.L. and A.U.). Unsupervised descriptive methods on anti-RNP+ patients or on the global cohort of myositis patients (anti-RNP+ and anti-RNP-) were performed as previously reported [7]. Multiple comparison correction for bivariate analysis was controlled by Benjamini-Hochberg procedure. Multivariate analysis was described with the adjusted *p* value of the V-test if available. A *p*-value ≤ .05 was considered significant.

Anti-RNP+ patients (*n* = 46; 20 French and 26 Japanese) were predominantly female (83%) with a mean age of 53 years [43–67]. Muscular and extramuscular manifestations are described in Table 1. Anti-RNP+ patients were diagnosed with mixed connective tissue disease (37/46, 80%) or systemic lupus erythematosus (9/46, 20%). > 90% of anti-RNP+ patients had proximal weakness that was frequently severe. The CK levels were high (2395 [999–4382] UI/L) and 10/46 (22%) patients had CK levels higher than 7000 UI/L.

The predominant lesions on muscle biopsy were myofiber necrosis

and/or myofiber regeneration (Fig. 1), sarcolemmal C5-b9 deposits and positive membranous diffuse staining of major histocompatibility complex-class I (MHC-I). Unsupervised hierarchical analysis of 207 myositis patients (anti-RNP- *n* = 174 and anti-RNP+ *n* = 33) identified four different clusters. Cluster 1 consisted of patients with mainly an anti-synthetase syndrome with anti-Jo1 antibody. Cluster 2 included 70% of all anti-RNP+ patients by positioning RNP+ variable (V test *p* value < .0001). Raynaud phenomenon (16/17, 94%, V test *p* < .0001) and puffy hands (16/17, 94%, V test *p* < .0001) were the two main associated symptoms. Cluster 3 contained a majority of patients with immune necrotizing myopathies. Interestingly, this cluster gathered the remaining anti-RNP+ patients, highlighting the phenotype proximity of these two entities. Finally, in cluster 4 patients had a dermatomyositis pattern with the classical dermatomyositis skin rash.

Six variables/predictors were significantly associated to the presence of anti-RNP+: absence of MSAs (OR 0.096, 95% CI 0.023–0.332), absence of muscle inflammation (OR 0.188, 95% CI 0.05–0.617), absence of typical dermatomyositis skin rash (OR 0.069, 95% CI 0.006–0.398), less disturbed pulmonary function tests (OR 0.126, 95% CI 0.026–0.475), presence of puffy hands (OR 11.136, 95% CI 1.489–123.405) and Raynaud phenomenon (OR 4.805, 95% CI 1.117–24.127).

Clinico-pathological patterns of anti-RNP+ myositis consisted of severe necrotizing myositis associated with frequent extra-muscular manifestations associating Raynaud phenomenon and/or puffy hands, arthralgia and/or interstitial lung disease. Anti-RNP+ myositis is a separate entity that differentiates them from the well-known subgroups of myositis (dermatomyositis, anti-synthetase syndrome and immune-mediated necrotizing myopathies [9]) even if this entity shares some common features with IMNM especially in the pathological field [10]. The extra-muscular manifestations of anti-RNP+ myositis patients are those of the spectrum of mixed connective tissue disease or systemic lupus erythematosus.

We also found that a minority of anti-RNP+ patients presented MSAs and when present they consisted primarily of anti-SRP and anti-OJ antibodies. It must be highlighted that in these cases, patients presented both phenotypes. If anti-RNP antibody delineates a subgroup of patients, it must be emphasized that standard immune-assay for anti-RNP detection bring frequent false-positive results. Since immunoprecipitation cannot be performed routinely, the results of stan-

Table 1
Muscular and extra-muscular features of anti-RNP⁺ patients.

	N (IQR or %)
Age at diagnosis (years)	48 (35–62)
Females	38/46 (83%)
Extra-muscular features	
Raynaud phenomenon	23/46 (50%)
Puffy hands/sclerodermic hands	14/46 (30%)
Arthralgia	21/28 (75%)
Arthritis	8/22 (36%)
Dyspnea	17/46 (37%)
Pulmonary hypertension	5/17 (29%)
Interstitial lung disease	18/43 (42%)
Pleural effusion	1/40 (2.5%)
FVC (%)	80 (59–102)
DLCO (%)	56 (44–67)
Pericardial effusion	8/25 (32%)
LVEF (%)	70 (66–70)
Esophageal impairment	17/28 (61%)
Muscular features	
Clinical	
Proximal weakness	41/46 (89%)
Distal weakness	13/45 (29%)
Manual muscle testing (five MRC score)	3 (3–4)
CK level (UI/L)	2395 (999–4382)
Myogenic syndrome (EMG)	31/37 (84%)
Pathological	
Necrosis/regeneration	35/42 (83%)
Internal nuclei \geq 5%	23/42 (55%)
Perivascular inflammatory infiltration	16/42 (38%)
MHC-I-positive muscle fibers	36/42 (85%)
Diffuse	27/42 (64%)
Scattered	6/42 (14%)
Peri-fascicular enhance	3/42 (7%)
Sarcolemmal deposits of C5-b9	20/38 (53%)
Peri-fascicular dominance	4/38 (11%)
Auto-antibodies	
Myositis-specific antibodies	12/46 (26%)
Anti-SRP	5/12 (42%)
Anti-OJ	4/12 (33%)
Anti-JO1	1/12 (8%)
Anti-MDA5	1/12 (8%)
Anti-HMGCR	1/12 (8%)
Myositis-associated antibodies	24/46 (52%)
Anti-Sm	7/46 (15%)
Anti-native DNA	5/46 (11%)
Anca	2/46 (4%)
Anti-SSA 52/60	14/46 (30%)
Anti-SSB	1/46 (2%)
Anti-Ku	3/46 (7%)

standard immunoassay must be interpreted with the clinico-pathological data as well as with the immunofluorescence pattern of anti-nuclear antibody detection.

To conclude, anti-RNP⁺ myositis appears to be a distinct subgroup of idiopathic inflammatory myopathies. However, some anti-RNP⁺ patients are close to IMNM. This finding emphasizes that the importance of auto-antibodies in myositis classification is not limited to myositis-specific antibodies.

Declaration of Competing Interest

No specific funding was received from any funding bodies in the public, commercial or not-for-profit sectors to carry out the work described in this article.

The authors have declared no conflicts of interest.

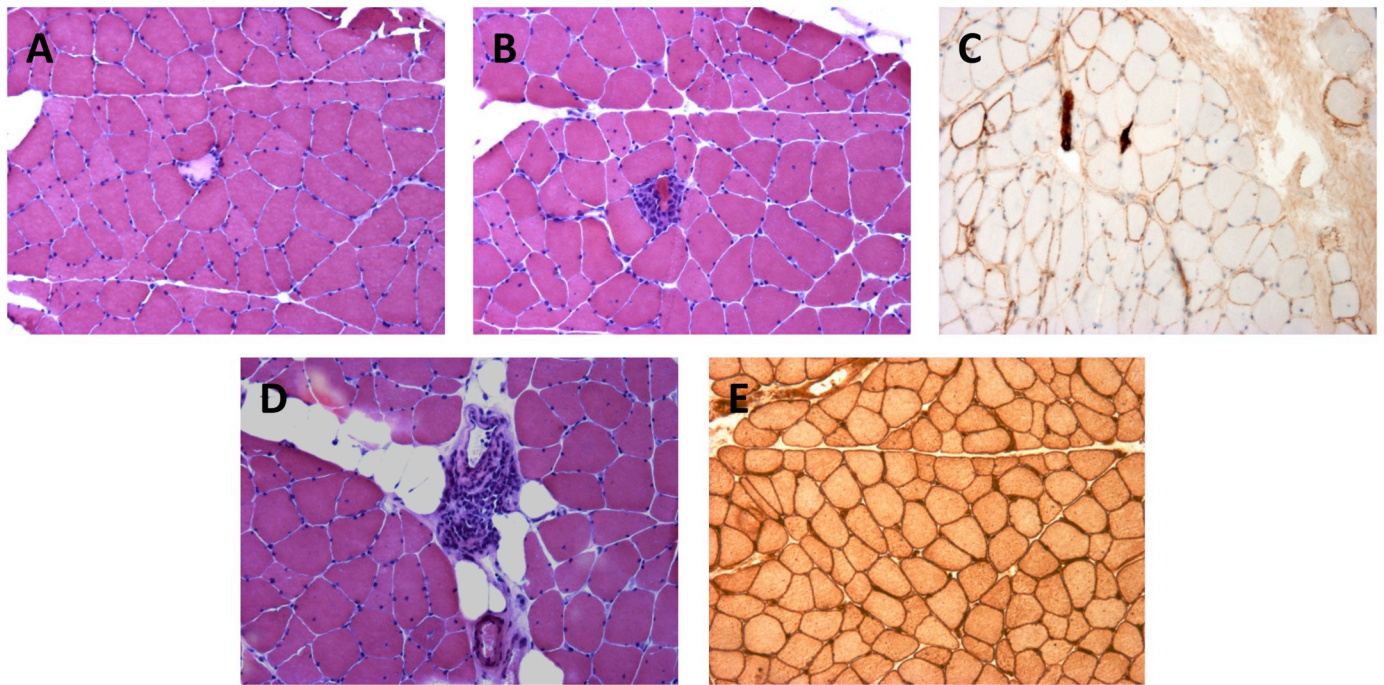


Fig. 1. Pathological features of anti-RNP+ myositis. Necrotic muscle fibers (A) and myophagocytosis (B) are observed in an anti-ribonucleoprotein (RNP)⁺ patient, without any specific distribution (dystrophin 2 immunohistochemical staining eosin counterstaining). Deposits of membrane attack complex (C5b-9) on the sarcolemma of myofibers (C). Inflammatory infiltrates are localized in perivascular areas (D). Major histocompatibility complex-1 (MHC-1) expression is diffusely positive (E) (MHC-1 immunohistochemical staining).

References

- [1] Benveniste O, Stenzel W, Allenbach Y. Advances in serological diagnostics of inflammatory myopathies. *Curr Opin Neurol* 2016;29(5):662–73.
 - [2] Brouwer R, Hengstman GJ, Vree Egberts W, Ehrfeld H, Bozic B, Ghirardello A, et al. Autoantibody profiles in the sera of European patients with myositis. *Ann Rheum Dis* 2001 Feb;60(2):116–23.
 - [3] Lundberg I, Nennesmo I, Hedfors E. A clinical, serological, and histopathological study of myositis patients with and without anti-RNP antibodies. *Semin Arthritis Rheum* 1992 Oct;22(2):127–38.
 - [4] Coppo P, Clauvel JP, Bengoufa D, Oksenhendler E, Lacroix C, Lassoued K. Inflammatory myositis associated with anti-U1-small nuclear ribonucleoprotein antibodies: a subset of myositis associated with a favourable outcome. *Rheumatology (Oxford)* 2002 Sep;41(9):1040–6.
 - [5] Casal-Dominguez M, Pinal-Fernandez I, Corse AM, Paik J, Albayda J, Casciola-Rosen L, et al. Muscular and extramuscular features of myositis patients with anti-U1-RNP autoantibodies. *Neurology* 2019 Mar 26;92(13):e1416–26.
 - [6] Bohan A, Peter JB. Polymyositis and dermatomyositis (first of two parts). *N Engl J Med* 1975 Feb 13;292(7):344–7.
 - [7] Mariampillai K, Granger B, Amelin D, Guiguet M, Hachulla E, Maurier F, et al. Development of a new classification system for idiopathic inflammatory myopathies based on clinical manifestations and myositis-specific autoantibodies. 11. 2018.
 - [8] Suzuki S, Yonekawa T, Kuwana M, Hayashi YK, Okazaki Y, Kawaguchi Y, et al. Clinical and histological findings associated with autoantibodies detected by RNA immunoprecipitation in inflammatory myopathies. *J Neuroimmunol* 2014 Sep 15;274(1–2):202–8.
 - [9] Lundberg IE, Tjärnlund A, Bottai M, Werth VP, Pilkington C, de Visser M, et al. European League Against Rheumatism/American College of Rheumatology classification criteria for adult and juvenile idiopathic inflammatory myopathies and their major subgroups. *Ann Rheum Dis* 2017;76(12):1955–64.
 - [10] Anquetil C, Boyer O, Wesner N, Benveniste O, Allenbach Y. Myositis-specific autoantibodies, a cornerstone in immune-mediated necrotizing myopathy. *Autoimmun Rev* 2019 Mar;18(3):223–30.
- Nadège Wesner^{a,1}, Akinori Uruha^{a,b,1}, Shigeaki Suzuki^c, Kubéraka Mariampillai^a, Benjamin Granger^d, Nicolas Champiaux^a, Aude Rigolet^a, Yoland Schoindre^e, Sylvain Lejeune^f, Perrine Guillaume-Jugnot^a, Matthieu Vautier^a, Baptiste Hervier^a, Anne Simon^a, Françoise Granier^g, Laure Gallay^h, Ichizo Nishinoⁱ, Olivier Benveniste^a, Yves Allenbach^{a,*}
- ^a Department of Internal Medicine and Clinical Immunology, Sorbonne Université, University Pierre et Marie et Curie, APHP, Hôpital Pitié-Salpêtrière, Paris, France
- ^b Department of Neurology, Tokyo Metropolitan Neurological Hospital, 2-6-1, Musashidai, Fuchu, 183-0042 Tokyo, Japan
- ^c Department of Neurology, Keio University School of Medicine, 35 Shinanomachi, Shinjuku-ku, 160-8582 Tokyo, Japan
- ^d Department of Public Health, Pitié Salpêtrière Hospital, 84 Boulevard de l'Hôpital, 75013 Paris, France
- ^e Internal Medicine Department, Foch Hospital, 40 Rue Worth, 92150 Suresnes, France
- ^f Internal Medicine Department, Avicennes Hospital, 125, rue de Stalingrad, 93000 Bobigny, France
- ^g Internal Medicine Department, Centre Hospitalier François Quesnay, 62 rue Saint Vincent, 78201 Mantes la Jolie, France
- ^h Internal Medicine Department, Hospices Civils de Lyon, Neuro-Myo-Gène Institut, INSERM U1217, 68008 Lyon, France
- ⁱ Department of Neuromuscular Research, National Institute of Neuroscience and Department of Genome Medicine Development, Medical Genome Center National Center of Neurology and Psychiatry, 4-1-1 Ogawa-Higashi, Kodaira, 187-8551 Tokyo, Japan
- E-mail address: yves.allenbach@aphp.fr (Y. Allenbach).

* Corresponding author at: Pitié Salpêtrière Hospital, 84 Boulevard de 31 l'Hôpital, 75013 Paris, France.

¹ These authors contributed equally to the work.