



HAL
open science

Diagnostic potential of sarcoplasmic myxovirus resistance protein A expression in subsets of dermatomyositis

Akinori Uruha, Yves Allenbach, J-L Charuel, Lucile Musset, Audrey Aussy, Olivier Boyer, Kuberaka Mariampillai, Océane Landon-Cardinal, Camille Rasmussen, Loïs Bolko, et al.

► To cite this version:

Akinori Uruha, Yves Allenbach, J-L Charuel, Lucile Musset, Audrey Aussy, et al.. Diagnostic potential of sarcoplasmic myxovirus resistance protein A expression in subsets of dermatomyositis. *Neuropathology and Applied Neurobiology*, 2018, 45, pp.513 - 522. 10.1111/nan.12519 . hal-03523507

HAL Id: hal-03523507

<https://hal.sorbonne-universite.fr/hal-03523507v1>

Submitted on 12 Jan 2022

HAL is a multi-disciplinary open access archive for the deposit and dissemination of scientific research documents, whether they are published or not. The documents may come from teaching and research institutions in France or abroad, or from public or private research centers.

L'archive ouverte pluridisciplinaire **HAL**, est destinée au dépôt et à la diffusion de documents scientifiques de niveau recherche, publiés ou non, émanant des établissements d'enseignement et de recherche français ou étrangers, des laboratoires publics ou privés.



DR AKINORI URUHA (Orcid ID : 0000-0002-4758-183X)

PROFESSOR OLIVIER BOYER (Orcid ID : 0000-0002-7591-307X)

PROFESSOR WERNER STENZEL (Orcid ID : 0000-0002-1143-2103)

Article type : Original Article

Diagnostic potential of sarcoplasmic MxA expression in subsets of dermatomyositis

Akinori Uruha¹, Yves Allenbach², Jean-Luc Charuel³, Lucile Musset³, Audrey Aussy⁴,
Olivier Boyer⁴, Kuberaka Mariampillai², Océane Landon-Cardinal², Camille Rasmussen²,
Loïs Bolko², Thierry Maisonobe⁵, Sarah Leonard-Louis⁵, Shigeaki Suzuki⁶, Ichizo Nishino⁷,
Werner Stenzel⁸, Olivier Benveniste².

1. Paris-Sorbonne University, National Institute of Health and Medical Research (INSERM),
Mixed Research Unit (UMR) 974, Center of Research in Myology, Institute of Myology,
Pitié-Salpêtrière University Hospital, Paris, France.

2. Department of Internal Medicine and Clinical Immunology, Paris-Sorbonne University,
Public Assistance-Hospitals of Paris (APHP), Pitié-Salpêtrière University Hospital,
INSERM, UMR974, Inflammation-Immunopathology-Biotherapy Department (DHU I2B),
and Reference Center for Neuromuscular Pathologies, Institute of Myology, Paris, France

3. Department of Immunology, Immunochemistry & Autoimmunity Laboratory, APHP,
Pitié-Salpêtrière University Hospital, Paris, France

4. Department of Immunology, Rouen University Hospital, Rouen Normandie University,
INSERM, Rouen, France

This article has been accepted for publication and undergone full peer review but has not
been through the copyediting, typesetting, pagination and proofreading process, which may
lead to differences between this version and the Version of Record. Please cite this article as
doi: 10.1111/nan.12519

This article is protected by copyright. All rights reserved.

5. APHP, Pitié-Salpêtrière University Hospital, Reference Center for Neuromuscular Pathologies, East Paris, Institute of Myology, Paris, France

6. Department of Neurology, Keio University School of Medicine, Tokyo, Japan

7. Department of Neuromuscular Research, National Institute of Neuroscience, and Department of Genome Medicine Development, Medical Genome Center, National Center of Neurology and Psychiatry, Tokyo, Japan

8. Department of Neuropathology, Charité-Universitätsmedizin, Berlin, Germany

Corresponding author

Dr. Yves Allenbach. Department of Internal Medicine and Clinical Immunology, Paris-Sorbonne University, APHP, Pitié-Salpêtrière University Hospital, INSERM, UMR974, DHU I2B, and Reference Center for Neuromuscular Pathologies, East Paris, Institute of Myology, Paris, France.

Tel: +33 142161088. Fax: +33 142161058. E-mail: yves.allenbach@aphp.fr

Keywords

Dermatomyositis; myxovirus resistance protein A; type 1 interferon; muscle pathology; autoantibody; diagnostic marker

A short running title

Sarcoplasmic MxA expression in DM subsets

Abstract

Aims To elucidate the diagnostic value of sarcoplasmic expression of myxovirus resistance protein A (MxA) for dermatomyositis (DM) specifically analyzing different DM subforms, and to test the superiority of MxA to other markers.

Methods Immunohistochemistry for MxA and retinoic acid-inducible gene I (RIG-I) was performed on skeletal muscle samples and compared with the item presence of perifascicular atrophy (PFA) in 57 DM patients with anti-Mi-2 (n=6), -TIF1- γ (n=10), -NXP2 (n=13), -MDA5 (n=10), or -SAE (n=1) autoantibodies and with no detectable autoantibody (n=17). Among the patients, 9 suffered from cancer and 22 were juvenile-onset type. Disease controls included antisynthetase syndrome-associated myositis (ASS, n=30), immune-mediated necrotizing myopathy (n=9), and inclusion body myositis (n=5).

Results Sarcoplasmic MxA expression featured 77% sensitivity and 100% specificity for overall DM patients, while RIG-I staining and PFA reached respectively 14% and 59% sensitivity and 100% and 86% specificity. In any subset of DM, sarcoplasmic MxA expression showed higher sensitivity than RIG-I and PFA. Some anti-MDA5 antibody-positive DM samples distinctively showed a scattered staining pattern of MxA. No ASS samples had sarcoplasmic MxA expression even though 6 patients had DM skin rash.

Conclusions Sarcoplasmic MxA expression is more sensitive than PFA and RIG-I expression for a pathological diagnosis of DM, regardless of the autoantibody-related subgroup. In light of its high sensitivity and specificity, it may be considered a pathological

hallmark of DM *per se*. Also, lack of MxA expression in ASS supports the idea that ASS is a distinct entity from DM.

Abbreviations

ASS = antisynthetase syndrome, CI = confidence interval, DM = dermatomyositis, ENMC = European Neuromuscular Center, HLA = human leukocyte antigen, HMGCR = 3-hydroxy-3-methylglutaryl-CoA reductase, IBM = inclusion body myositis, IMNM = immune-mediated necrotizing myopathy, ISG15 = interferon-stimulated gene 15, MDA5 = melanoma differentiation-associated gene 5, MHC = major histocompatibility complex, MxA = myxovirus resistance A, NXP2 = nuclear matrix protein 2, PFA = perifascicular atrophy, PM = polymyositis, RIG-I = retinoic acid-inducible gene I, SRP = signal recognition particle, TIF1- γ = transcription intermediary factor 1 gamma, SAE = small ubiquitin-like modifier activating enzyme

Introduction

A diagnosis of dermatomyositis (DM) is achieved multidisciplinarily by clinical evaluation, autoantibody measurement in sera, and morphological analysis of skeletal muscle [1, 2]. Muscle biopsy plays an important role to validate and complement clinical and serological diagnosis, and to diagnose clinically atypical or seronegative patients.

Perifascicular atrophy (PFA; a cluster of atrophic myofibers in the perifascicular region) has been held as a gold standard item to so-called 'definite diagnosis' of DM in many classification schemes [3, 4]. However, the sensitivity of PFA is limited, mainly because muscle biopsy samples of DM patients may not always include PFA due to its patchy

distribution or due to poorly affected biopsy site [1]. Also, PFA or PFA-like lesions can be seen in antisynthetase syndrome (ASS) [2, 5-7]. Although mostly small regenerating fibers in perifascicular regions make up the lesion, it may occasionally be difficult to clearly differentiate between PFA of DM and that of ASS-associated myositis or other inflammatory myopathies harboring atrophic fibres in the periphery of the fascicles (e.g. Shulman Syndrome) [8-10].

Recently we reported that immunohistochemical detection of myxovirus resistance protein A (MxA) on the sarcoplasm of myofibers is a sensitive pathological marker of DM [11, 12]. The sensitivity and specificity of sarcoplasmic MxA expression were 71% and 98%, revealing that it had a higher sensitivity than that of PFA and complement membrane attack complex (C5b-9) deposition on capillaries (47% and 35%, respectively) with an equal or higher specificity [11]. MxA is one of the type 1 interferon-inducible proteins, which plays an important role in the pathogenesis of DM but presumably not of other idiopathic inflammatory myopathies, similar to the proteins retinoic acid-inducible gene I (RIG-I) and interferon-stimulated gene 15 (ISG15) [13-17]. However, the comparison with MxA and other interferon-inducible proteins in terms of the utility as a pathological marker has not been explored to date. Here, we specifically address the issue of sarcoplasmic MxA expression in subsets of DM defined by the DM-specific autoantibodies. Since each of these DM subsets harbors particular features in muscle pathology as well as clinical aspects [2], it will be significant to clarify whether MxA staining patterns differ in these subgroups.

Methods

Patients and materials

We enrolled 57 consecutive DM patients (median and range of age at biopsy: 38.5 [28-84] years, sex ratio [male : female] 1:1.8 in adult; 6 years [2-13], 1:0.8 in children) who were diagnosed with definite, probable, or possible DM based on the European Neuromuscular Centre (ENMC) criteria [18] in the French, German and Japanese biopsied muscle repositories (Pitié-Salpêtrière University Hospital/Institute of Myology, Charité-Universitätsmedizin, and National Center of Neurology and Psychiatry). 40 patients were positive for any DM-specific autoantibody (anti-Mi-2, transcription intermediary factor 1 gamma [TIF1- γ], nuclear matrix protein 2 [NXP2], melanoma differentiation antigen 5 [MDA5] or small ubiquitin-like modifier activating enzyme [SAE]) and 17 had no detectable autoantibody. Out of the DM patients, 22 patients who developed the disease and underwent muscle biopsy before 18 years of age were categorized as juvenile DM. 9 adult patients had cancer occurring within three years before or after the diagnosis of DM: 4 with anti-Mi-2 antibodies, 4 with anti-TIF1- γ antibodies, and 1 with no detectable autoantibody. Juvenile DM and cancer-associated DM were defined as previously reported [3, 19]. Among 53 DM patients (4 patients without detailed information about muscular symptoms were excluded), 5 patients had no muscle weakness - 2 patients had only myalgia and 3 patients were amyopathic. 9 out of 31 patients had severe muscle weakness (Medical Research Council scale 3 or weaker), though information about degree of muscle weakness was not available in all juvenile patients. 9 DM patients had no skin rash with only pathological changes of muscles. As controls, other major forms of idiopathic inflammatory myopathies (antisynthetase syndrome-associated myositis [ASS], immune-mediated necrotizing myopathy [IMNM], inclusion body myositis [IBM]) and molecularly confirmed muscular

dystrophies were included. ASS and IMNM were defined by presence of the typical clinical syndrome/ symptoms including a characteristic skeletal muscle deficit and the presence of disease-specific autoantibodies. IBM was diagnosed when patients met criteria for clinicopathologically defined IBM according to the ENMC criteria [20]. We selected 30 patients with ASS (65 [13-85] years of age at biopsy: median and range, sex ratio [male : female] 1:1.7), 9 with IMNM (4 positive for anti-signal recognition particle [SRP] and 5 positive for anti-3-hydroxy-3-methylglutaryl-CoA reductase [HMGCR] autoantibodies) (39 [10-61] years of age, 1:0.8), 5 with IBM (63 [57-69] years of age, 1:0.7), and 7 with muscular dystrophy (3 with dystrophinopathy and 4 with dysferlinopathy) (39 [6-80] years of age, 1:0.4). The autoantibodies in their sera were measured by means of RNA and protein immunoprecipitation for anti-aminoacyl transfer RNA synthetase antibodies (anti-OJ, -EJ, and -KS), addressable laser bead immunoassay for anti-TIF1- γ , -SRP, and -HMGCR antibodies, or line-immunoassay (D-Tek, Belgium) for the others as previously described [5, 21-25]. We chose subjects in a consecutive manner within each disease group and investigated their frozen skeletal muscle samples that were first biopsied. The biopsy sites were determined by attending physicians. 4 DM (2 adult anti-TIF1- γ , 1 adult anti-NXP2, and 1 juvenile anti-NXP2) and 2 adult ASS patients had received treatment (corticosteroid and/or methotrexate in DM; corticosteroid in ASS) at the time of biopsy. All muscle samples were kept at -80°C freezers. When the samples needed to be transferred, they were put in a box with 3 kg or more of dry ice, shipped overnight (< 24h) and immediately stored into a -80°C freezer on arrival.

Histologic analysis

We performed immunohistochemistry for MxA and RIG-I on 7- μ m-thick muscle sections using the antibodies (MxA: Mx1/2/3 [H-285, sc-50509], 1:100 dilution, Santa Cruz Biotechnology, USA; RIG-I: RIG-I Monoclonal Antibody [2M6F10, MA5-16254], 1:20 dilution, Thermo Fisher Scientific, USA; ISG15: Anti-ISG15 antibody [ab14374], Abcam, USA) and *i*VIEW DAB Detection Kit (Ventana Medical Systems, USA). Appropriate biotinylated secondary antibodies were used and diaminobenzidine visualization of the peroxidase reaction product on a Benchmark XT immunostainer (Ventana) were carried out in a standardized manner as described previously [26]. All staining procedures were performed in the same laboratory of the department of Neuropathology, Charité-Universitätsmedizin, Germany. Staining of the sarcoplasm was considered positive, excluding necrotic and regenerating fibers as previously described [11]. Fibers with faint staining results were considered MxA-negative. When stained fibers were restricted to less than five fiber layers in the periphery of fascicles, we defined such a pattern as a perifascicular distribution (even if they occupied a whole small fascicle). When stained fibers were spread over a wider area, the pattern was defined as a diffuse or scattered distribution. PFA was defined by the presence of at least one muscle fascicle possessing a cluster of small fibers that occupied more than 60% of the fibers along the edge of the fascicle [27, 28]. The pathological assessment (consensus agreement) was performed by at least two experts in muscle pathology (AU and WS). AU was not blinded to clinical diagnosis, autoantibody profile, and antibody used for staining. WS was not blinded to the antibody used for staining.

Statistical analysis

Sensitivity and specificity for a diagnosis of DM with their 95% confidence intervals (CIs) were calculated with GraphPad Prism version 6.0 (GraphPad Software, USA). On specificity calculation, the total number of patients with idiopathic inflammatory myopathies except for DM was used as the denominator. Also difference of number of samples positive for MxA among independent DM subgroups were assessed by Fisher's exact test. To compare diagnostic power of MxA staining in a diagnosis of DM compared to PFA, we used McNemar's test with online McNemar's test calculator of GraphPad Software (<https://www.graphpad.com/quickcalcs/McNemar1.cfm>). Values of $p < 0.05$ were considered significant.

Ethical Approval

The study was approved by the ethic committee of Pitié-Salpêtrière University Hospital. All the material used in this study was obtained for diagnostic purpose and permitted for scientific use with written informed consent.

Results

The patients' skeletal muscle biopsies positive for sarcoplasmic expression of MxA, RIG-I, and presence of PFA are summarized in **figure 1** and **table 1**. The sensitivity and specificity of sarcoplasmic MxA expression for overall DM patients were 77% (44/57, 95% CI: 65-86) and 100% (44/44, 95% CI: 92-100), respectively. Meanwhile, sarcoplasmic RIG-I expression showed 14% (8/57, 95% CI: 7-25) of sensitivity and 100% (44/44, 95% CI: 92-100) of specificity, and presence of PFA exhibited 59% (33/56, 95% CI: 46-71) of sensitivity

and 86% (37/43, 95% CI: 73-93) of specificity for overall DM (one DM and one ASS samples which showed mostly longitudinally cut myofibers were excluded in the analysis of PFA). In addition to the higher sensitivity, McNemar's test supported the superiority of MxA over PFA in a diagnosis of DM ($p = 0.02$). 4 out of 6 patients with RIG-I expression were positive for anti-TIF1- γ autoantibodies in patients' sera. All muscular dystrophy samples were negative for MxA or RIG-I expression on sarcoplasm.

We tried to evaluate the diagnostic value of sarcoplasmic expression of ISG15, but we could not reach an optimal condition for the immunohistochemistry in terms of diagnostic use; indeed, an intense staining could be found in perifascicular areas of some DM samples, but ubiquitous staining of ISG15 was seen not only in DM samples but also in some non-DM samples including muscular dystrophy (data not shown). Therefore, we considered that the diagnostic use would be limited.

In every DM subset, sarcoplasmic MxA expression had a higher sensitivity than sarcoplasmic RIG-I expression and presence of PFA. In anti-TIF1- γ autoantibody-positive DM and juvenile DM, all samples showed sarcoplasmic MxA expression. By contrast, it was found only in 50% (5/10) of anti-MDA5 autoantibody-positive samples, although the sensitivity was still higher than those of the other markers. As for the difference between autoantibody-related subgroups, only TIF1- γ group versus MDA5 group showed statistically significant difference ($p = 0.03$). When limited to non-MDA5 DM patients, 83% (39/47) of the DM samples were positive for sarcoplasmic MxA expression. Also, MxA-positive samples were more common in the juvenile DM group than the adult DM group (22/22 versus 22/34, $p = 0.002$). McNemar's test indicated superiority of MxA over PFA in the juvenile DM group ($p = 0.04$), although statistically significant differences were not observed in other groups. In the DM group with no detectable autoantibody, sarcoplasmic MxA expression was positive in 76% (13/17) of the samples: 100% (7/7) in

juvenile DM and 60% (6/10) in adult DM. 78% (7/9) of DM patients with severe muscle weakness showed MxA expression while 64% (14/22) of DM patients with milder or no muscle weakness showed MxA expression ($p = 0.68$). All of the 9 DM patients without skin rash were positive for MxA staining. All non-DM juvenile samples were negative for sarcoplasmic MxA expression (2 with ASS, 1 with IMNM, and 3 with muscular dystrophy). All of the 4 treated DM patients' samples were positive for MxA while both of the 2 treated ASS samples were negative for it.

The MxA expression was often highlighted in perifascicular areas, but the stained fibers were not restricted to these areas in 43% (19/44) of DM samples with sarcoplasmic MxA expression, showing a diffuse or scattered distribution pattern (**figure 2, table 2**). A scattered distribution pattern was observed exclusively in anti-MDA5 autoantibody-positive DM (3 out of 5 MxA-positive samples). As for RIG-I, 2 out of 8 samples with sarcoplasmic RIG-I expression showed a diffuse distribution pattern, and the others exhibited a perifascicular pattern (**online supplementary table e-1**).

23 DM patients lacked PFA (2 patients with anti-TIF1- γ autoantibodies, 4 with anti-NXP2, 3 with anti-Mi-2, 7 with anti-MDA5, 1 with anti-SAE, and 6 with no detectable autoantibody). Amongst them, 65% (15/23) were positive for sarcoplasmic MxA expression; negative samples were seen in 2 with anti-NXP2, 1 with anti-Mi-2, 3 with anti-MDA5, and 2 with no detectable autoantibody patients. Meanwhile, 9% (2/23) were positive for sarcoplasmic RIG-I expression; one was associated with anti-TIF1- γ autoantibody and another had no detectable autoantibody. McNemar's test demonstrated the superiority of MxA staining as well ($p = 0.0009$).

6 out of 25 ASS patients with available information had Heliotrope rash and/or Gottron's sign/papule, but none of them showed staining of MxA in their muscle samples.

Discussion

The present study has demonstrated that sarcoplasmic MxA expression has a higher sensitivity for a pathological diagnosis of DM than sarcoplasmic RIG-I expression or the presence of PFA, regardless of the diagnostic DM subgroups evaluated by autoantibodies combined with morphological patterns. The sensitivity and specificity for overall DM patients (respective 77% and 100%) were consistent with those in the previous study using a different cohort which revealed 71% of sensitivity and 98% of specificity [11], further corroborating its high potential as a pathological marker for DM. Although pathological changes of DM are generally conspicuous in perifascicular areas [1, 2, 15, 29-31], myofibers with MxA overexpression were seen beyond perifascicular regions in nearly half of the DM samples positive for sarcoplasmic MxA expression, representing the value of MxA immunostaining to increase diagnostic sensitivity and accuracy. Practically, improvement of pathological diagnosis for DM without PFA is particularly important. In this regard, 65% of DM patients without PFA were positive for sarcoplasmic MxA expression, and its diagnostic superiority over PFA was statistically demonstrated. This can be considered one of the most significant contributions to the practice for diagnostic pathological evaluation of myositis patients.

The diagnostic value of sarcoplasmic MxA expression for DM patients without any identified DM-specific autoantibody is of particular interest. The present study showed 76% sensitivity in the DM group with no detectable autoantibody, implying sarcoplasmic MxA expression could provide corroboration of the diagnosis of such patients as well as PFA (65% sensitivity), though its superiority over PFA was not proven in McNemar's test.

RIG-I and ISG15 are known to be upregulated in muscle cells of DM patients as well as MxA [13-17]. The present findings suggest a more important benefit from the use of MxA immunostaining in pathological practice rather than the use of these other markers.

Nevertheless, this difference might be due to the chemical properties of the antibody products for immunohistochemistry on frozen muscle samples. In addition to less sensitivity of sarcoplasmic RIG-I expression, all but one sample was negative for RIG-I in DM without PFA. Another report concerning RIG-I on DM muscles revealed that, while RIG-I expression showed a higher sensitivity than PFA, it was also observed in 11% of non-DM patients, which lowered its specificity [29]. Taken altogether, the findings of these two independent studies suggest that the use of RIG-I as a pathological marker could possess shortcomings in terms of sensitivity or specificity.

Anti-MDA5 autoantibody-positive DM had relatively low sensitivity of sarcoplasmic MxA expression (50% in anti-MDA5 DM versus 83% in the other DM) and also characteristically showed a scattered distribution pattern of MxA-positive fibers in some samples. Anti-MDA5 DM is known to exhibit clinical and morphological features different from classic DM [32]. Morphological differences include the rare presence of PFA and less obvious capillary C5b-9 deposition, as well as less frequent detection of tubuloreticular inclusions by electron microscopy, thereby making pathological diagnosis challenging. The sensitivity of immunohistochemistry for MxA in anti-MDA5 DM observed in this study may seem unsatisfactory, yet could still be useful compared to conventional pathological markers.

A recent study in the juvenile DM registry of 103 patients reported that expression of MxA protein on myofibers was identified in 61.2%, which is lower than the percentage in this study [33]. The difference could be explained by the different inclusion criteria (the Bohan and Peter criteria in the former and the ENMC criteria in the latter) and different anti-MxA antibody products for immunostaining. Also, the previous study showed the association

between the MxA expression level and muscle disease activity [33]. Although information on disease activity was not available in this study, the possible difference of disease activity might influence the percentages of positive MxA staining.

ASS is associated with anti-aminoacyl transfer RNA synthetase autoantibodies and clinically with myositis, characteristic skin lesion (mechanic's hands are typical, but heliotrope rash and Gottron's signs/papules can also be seen), Raynaud phenomenon, interstitial lung disease, arthritis/arthritis, and systemic symptom such as fever [1, 2, 7, 21, 34]. Some of the clinical features and a pathological finding of perifascicular reinforcement of human leukocyte antigen (HLA)-ABC (major histocompatibility complex [MHC] class I) expression on the sarcoplasm are shared with DM, yet ASS has a unique myopathological phenotype. In contrast to DM, perifascicular pathology is characterized by necrosis and regeneration rather than degenerative atrophic changes [5-7]. Sarcoplasmic expression of HLA-DR (MHC class II) with perifascicular reinforcement and perimysial connective tissue fragmentation are also characteristic [5, 31, 35]. Ultrastructurally, myonuclear actin filament inclusions are observed exclusively in ASS [7]. Taken altogether, these morphological differences suggest that ASS should be considered as a distinct entity from DM [2]. The present study demonstrated that ASS lacked sarcoplasmic MxA expression, supporting the idea that ASS is an independent entity among idiopathic inflammatory myopathies. Moreover, ASS muscle samples sometimes show PFA-like lesions as mentioned previously. In this study, 21% of the ASS samples possessed PFA according to the definition, but none of them had sarcoplasmic MxA expression. Also, even ASS patients with heliotrope rash and Gottron's signs/papules were all negative for MxA. These findings indicate that MxA is a highly distinctive marker to morphologically differentiate DM from ASS.

Accepted Article

It has been reported that not only sarcoplasm but also intramuscular capillaries and other blood vessels are highlighted by MxA immunostain [13]. Indeed, positively stained blood vessels were often seen in DM samples in this study as well (**figure 2A, B**). However, blood vessels often showed faint and equivocal staining even in non-DM samples, making interpretation difficult (**online supplementary figure e-1**). We therefore did not take capillary MxA staining further into account.

There are several limitations in this study. The previous studies demonstrated the overexpression of type 1 IFN-related genes in DM muscle tissue including MxA, ISG-15, and RIG-I by means of transcriptome analyses and immunohistochemistry [13-16, 33]. The current study was based upon these findings. However, positive controls of the immunostainings were not included in those studies and the current study. Therefore, theoretically, to solidly certify that the positive staining is indeed a specific expression of the MxA protein, some additional experiments (e.g. blocking experiments) would be informative. This is a limitation of this study as well as the previous studies. Also, the MxA polyclonal antibody used in the present study was discontinued by the company and is no longer available. Nonetheless, we confirmed that the company's MxA monoclonal antibody alternate could be used comparably, although higher concentrations will be required [12]. Again, we stained some samples in this study with the alternate and validated that it could work for immunohistochemistry, showing the same staining pattern with 1:4 dilution of the antibody product (data not shown). In the above-mentioned study of juvenile DM patients, another monoclonal MxA antibody was used with a lower concentration [33]. In the pathological assessment, the observers were not totally blinded to clinical diagnosis, autoantibody profile, and antibody used for staining. Finally, there remains a possibility of false-negative results in the autoantibody tests evaluated by line-immunoassay because they were not confirmed by immunoprecipitation assay, which is the original and more sensitive method to detect the

autoantibodies although not suitable for routine use in the clinical setting due to the technical complexity [36].

In conclusion, we have expanded previous results on the diagnostic utility of sarcoplasmic MxA expression in DM and clearly shown that MxA can serve as a very sensitive marker, regardless of the DM subsets. In light of its high sensitivity and specificity, it may be considered a pathological hallmark of DM. Also, scattered MxA expression pattern may be specific to anti-MDA5 DM though further investigations are necessary to be more conclusive. Lack of sarcoplasmic MxA expression in ASS, even with DM skin rash, supports the idea that ASS is a distinct entity from DM.

Figure legend

Figure 1. Sensitivity of the pathological findings in dermatomyositis patients

Ab = autoantibody; DM = dermatomyositis; JDM = juvenile dermatomyositis; AdDM = adult dermatomyositis; Cancer = dermatomyositis associated with cancer; MxA = myxovirus resistance protein A; PFA = perifascicular atrophy; RIG-I = retinoic acid-inducible gene I.

Figure 2. Immunohistochemistry for myxovirus resistance protein A and retinoic acid-inducible gene I

(A) Sarcoplasmic myxovirus resistance protein A (MxA) expression is seen preferentially in perifascicular atrophic myofibers. MxA is located also on blood vessel walls. Anti-TIF1- γ autoantibody-positive dermatomyositis (DM). (B) Myofibers with sarcoplasmic MxA expression are diffusely distributed. MxA on blood vessel walls is also seen. Anti-NXP2

autoantibody-positive DM. (C) Myofibers with relatively mild sarcoplasmic MxA expression are scattered. Anti-MDA5 autoantibody-positive DM. (D) Sarcoplasmic MxA expression is seen mainly in perifascicular area but expands to the central area of the fascicle. Anti-Mi-2 autoantibody-positive DM. (E) Sarcoplasmic retinoic acid-inducible gene I expression in perifascicular area. Anti-NXP2 autoantibody-positive DM. (F) Expression of MxA (left) and retinoic acid-inducible gene I (right) are negative or just faint on atrophic fibers in perifascicular area in antisynthetase syndrome-associated myositis. Asterisks indicate necrotic fibers.

Supplementary figure e-1

Intramuscular blood vessels are modestly stained by immunohistochemistry for myxovirus resistance protein A. The expression is not highlighted on myofibers. Antisynthetase syndrome-associated myositis.

Acknowledgements

The authors thank Petra Matylewski in Charité-Universitätsmedizin, Kazu Iwasawa in National Center of Neurology and Psychiatry, and Angéline Madelaine in Institute of Myology for their excellent technical assistance.

Ethical Approval

The study was approved by the ethic committee of Pitié-Salpêtrière University Hospital. All the material used in this study was obtained for diagnostic purpose and permitted for scientific use with written informed consent.

Author Contributions

AU: Conceptualization and design of the study, data analysis and interpretation, literature review, and drafting the manuscript. YA: design of the study, data interpretation, and manuscript revision for intellectual content. JC, LM, AA, and OBo, SS: autoantibody evaluation and manuscript revision for intellectual content. KM, OL, CR, LB, TM, SL, IN: collection of samples and clinical data and manuscript revision for intellectual content. WS: collection of samples, pathological analysis and manuscript revision for intellectual content. OBe: supervision of all aspects, including conceptualization and design of the study, data analysis and interpretation, and manuscript preparation.

Disclosure

A. Uruha reports a grant from The Uehara Memorial Foundation. YA, JC, LM, AA, OBo, KM, OL, CR, LB, TM, SL, SS, IN, WS, and OBe report no disclosure relevant to the manuscript.

Study Funding

This study was supported by the French Muscular Dystrophy Association.

This article is protected by copyright. All rights reserved.

References

1. Uruha A, Suzuki S, Nishino I. Diagnosis of dermatomyositis: Autoantibody profile and muscle pathology. *Clin Exp Neuroimmunol* 2017;8:302-312.
2. Allenbach Y, Benveniste O, Goebel HH, et al. Integrated classification of inflammatory myopathies. *Neuropathol Appl Neurobiol* 2017;43:62-81.
3. Lundberg IE, Tjärnlund A, Bottai M, et al. 2017 European League Against Rheumatism/American College of Rheumatology classification criteria for adult and juvenile idiopathic inflammatory myopathies and their major subgroups. *Ann Rheum Dis* 2017;76:1955-1964.
4. Lundberg IE, Miller FW, Tjärnlund A, Bottai M. Diagnosis and classification of idiopathic inflammatory myopathies. *J Intern Med* 2016;280:39-51.
5. Mescam-Mancini L, Allenbach Y, Hervier B, et al. Anti-Jo-1 antibody-positive patients show a characteristic necrotizing perifascicular myositis. *Brain* 2015;138:2485-2492.
6. Uruha A, Suzuki S, Suzuki N, et al. Perifascicular necrosis in anti-synthetase syndrome beyond anti-Jo-1. *Brain* 2016;139:e50.
7. Stenzel W, Preuße C, Allenbach Y, et al. Nuclear actin aggregation is a hallmark of anti-synthetase syndrome-induced dysimmune myopathy. *Neurology* 2015;84:1346-1354.
8. Pehl D, Preusse C, Rinnenthal J, et al. Perifascicular pathology in eosinophilic fasciitis with muscle involvement. *Neuromuscul Disord* 2015;25:S310.
9. Verity MA, Bulpitt KJ, Paulus HE. Neuromuscular manifestations of L-tryptophan-associated eosinophilia-myalgia syndrome: a histomorphologic analysis of 14 patients. *Hum Pathol* 1991;22:3-11.
10. Thornell LE, Bjelle A. Eosinophilic fasciitis: an ultrastructural and immunohistochemical study of the intermediate filament protein skeleton in regenerating muscle fibres. *Neuropathol Appl Neurobiol* 1981;7:435-449.

11. Uruha A, Nishikawa A, Tsuburaya RS, et al. Sarcoplasmic MxA expression: a valuable marker of dermatomyositis. *Neurology* 2017;88:493-500.
12. Uruha A, Suzuki S, Nishino I. Author update: Sarcoplasmic MxA expression: A valuable marker of dermatomyositis. *Neurology* 2017;89:215.
13. Greenberg SA, Pinkus JL, Pinkus GS, et al. Interferon alpha/beta-mediated innate immune mechanisms in dermatomyositis. *Ann Neurol* 2005;57:664-678.
14. Salajegheh M, Kong SW, Pinkus JL, et al. Interferon stimulated gene 15 (ISG15) conjugates proteins in dermatomyositis muscle with perifascicular atrophy. *Ann Neurol* 2010;67:53-63.
15. Suárez-Calvet X, Gallardo E, Nogales-Gadea G, et al. Altered RIG-I/DDX58-mediated innate immunity in dermatomyositis. *J Pathol* 2014;233:258-268.
16. Preuße C, Allenbach Y, Hoffmann O, et al. Differential roles of hypoxia and innate immunity in juvenile and adult dermatomyositis. *Acta Neuropathol Commun* 2016;4:45.
17. De Luna N, Suárez-Calvet X, Lleixà C, et al. Hypoxia triggers IFN-I production in muscle: Implications in dermatomyositis. *Sci Rep* 2017;7:8595.
18. Hoogendijk JE, Amato AA, Lecky BR, et al. 119th ENMC international workshop: trial design in adult idiopathic inflammatory myopathies, with the exception of inclusion body myositis, 10-12 October 2003, Naarden, The Netherlands. *Neuromuscul Disord* 2004;14:337-345.
19. Zahr ZA, Baer AN. Malignancy in myositis. *Curr Rheumatol Rep* 2011;13:208-215.
20. Rose MR. ENMC IBM Working Group. 188th ENMC International Workshop: inclusion body myositis, 2–4 December 2011, Naarden, the Netherlands. *Neuromuscul Disord* 2013;23:1044-1055.
21. Noguchi E, Uruha A, Suzuki S, et al. Skeletal muscle involvement in antisynthetase syndrome. *JAMA Neurol* 2017;74:992-999.

22. Suzuki S, Hayashi YK, Kuwana M, et al. Myopathy associated with antibodies to signal recognition particle: disease progression and neurological outcome. *Arch Neurol* 2012;69:728-732.
23. Suzuki S, Satoh T, Yasuoka H, et al. Novel autoantibodies to a voltage-gated potassium channel Kv1.4 in a severe form of myasthenia gravis. *J Neuroimmunol* 2005;170:141-149.
24. Benveniste O, Drouot L, Jouen F, et al. Correlation of anti-signal recognition particle autoantibody levels with creatine kinase activity in patients with necrotizing myopathy. *Arthritis Rheum* 2011;63:1961-1971.
25. Allenbach Y, Drouot L, Rigolet A, et al. Anti-HMGCR autoantibodies in European patients with autoimmune necrotizing myopathies: inconstant exposure to statin. *Medicine (Baltimore)* 2014;93:150-157.
26. Preuße C, Goebel HH, Held J, et al. Immune-mediated necrotizing myopathy is characterized by a specific Th1-M1 polarized immune profile. *Am J Pathol* 2012;181:2161-2171.
27. Varsani H, Charman SC, Li CK, et al. Validation of a score tool for measurement of histological severity in juvenile dermatomyositis and association with clinical severity of disease. *Ann Rheum Dis* 2015;74:204-210.
28. Wedderburn LR, Varsani H, Li CK, et al. International consensus on a proposed score system for muscle biopsy evaluation in patients with juvenile dermatomyositis: a tool for potential use in clinical trials. *Arthritis Rheum* 2007;57:1192-1201.
29. Suárez-Calvet X, Gallardo E, Pinal-Fernandez I, et al. RIG-I expression in perifascicular myofibers is a reliable biomarker of dermatomyositis. *Arthritis Res Ther* 2017;19:174.
30. Braczynski AK, Harter PN, Zeiner PS, et al. C5b-9 deposits on endomysial capillaries in non-dermatomyositis cases. *Neuromuscul Disord* 2016;26:283-291.

31. Aouizerate J, De Antonio M, Bassez G, et al. Myofiber HLA-DR expression is a distinctive biomarker for antisynthetase-associated myopathy. *Acta Neuropathol Commun* 2014;2:154.
32. Allenbach Y, Leroux G, Suárez-Calvet X, et al. Dermatomyositis with or without anti-melanoma differentiation-associated gene 5 antibodies: common interferon signature but distinct NOS2 expression. *Am J Pathol* 2016;186:691-700.
33. Sponkanaporn S, Deakin CT, Schutz PW, et al. Expression of myxovirus-resistance protein A: a possible marker of muscle disease activity and autoantibody specificities in juvenile dermatomyositis. *Neuropathol Appl Neurobiol* 2018 [Epub ahead of print] doi: 10.1111/nan.12498.
34. Hamaguchi Y, Fujimoto M, Matsushita T, et al. Common and distinct clinical features in adult patients with anti-aminoacyl-tRNA synthetase antibodies: heterogeneity within the syndrome. *PLoS ONE* 2013;8:e60442.
35. Mozaffar T, Pestronk A. Myopathy with anti-Jo-1 antibodies: Pathology in perimysium and neighbouring muscle fibres. *J Neurol Neurosurg Psychiatry* 2000;68:472-478.
36. Fujimoto M, Watanabe R, Ishitsuka Y, et al. Recent advances in dermatomyositis-specific autoantibodies. *Curr Opin Rheumatol* 2016;28:636-644.

Table 1. Positive ratio of the pathological findings in dermatomyositis and controls.

	n	MxA, % (n)	PFA, % (n)	RIG-I, % (n)
DM	57*	77 (44)	59 (33)	14 (8)
TIF1- γ	10	100 (10)	80 (8)	40 (4)
NXP2	13	85 (11)	69 (9)	15 (2)
Mi-2	6	67 (4)	50 (3)	0 (0)
MDA5	10*	50 (5)	22 (2)	0 (0)
SAE	1	- (1)	- (0)	- (0)
Ab (-)	17	76 (13)	65 (11)	12 (2)
Juvenile	22	100 (22)	73 (16)	9 (2)
Adult	35*	63 (22)	50 (17)	17 (6)
Cancer	9	78 (7)	67 (6)	33 (3)
Without PFA	23	65 (15)	-	9 (2)
ASS	30*	0 (0)	21 (6)	0 (0)
IMNM	9	0 (0)	0 (0)	0 (0)
IBM	5	0 (0)	0 (0)	0 (0)
Muscular dystrophy	7*	0 (0)	0 (0)	0 (0)

*: Sample numbers for analysis of PFA are 56 in whole DM, 9 in MDA5, 34 in Adult, and 29 in ASS, 6 in Muscular dystrophy.

Ab = autoantibody; DM = dermatomyositis; PFA = perifascicular atrophy; ASS = antisynthetase syndrome; IMNM = immune-mediated necrotizing myopathy; IBM = inclusion body myositis; MxA = myxovirus resistance protein A; RIG-I = retinoic acid-inducible gene I.

Table 2. Distribution pattern of myofibers with sarcoplasmic expression of myxovirus resistance protein A.

	n	Perifascicular	Diffuse	Scattered
DM	44	25	16	3
TIF1- γ	10	8	2	0
NXP2	11	5	6	0
Mi-2	4	3	1	0
MDA5	5	0	2	3
SAE	1	1	0	0
Ab (-)	13	8	5	0
Juvenile	22	10	11	1
Adult	22	15	5	2
Cancer	8	6	2	0
Without PFA	15	5	7	3

Ab = autoantibody; DM = dermatomyositis; PFA = perifascicular atrophy. The definition of the distribution patterns (perifascicular, diffuse, and scattered) is explained in the Methods section.

Figure 1

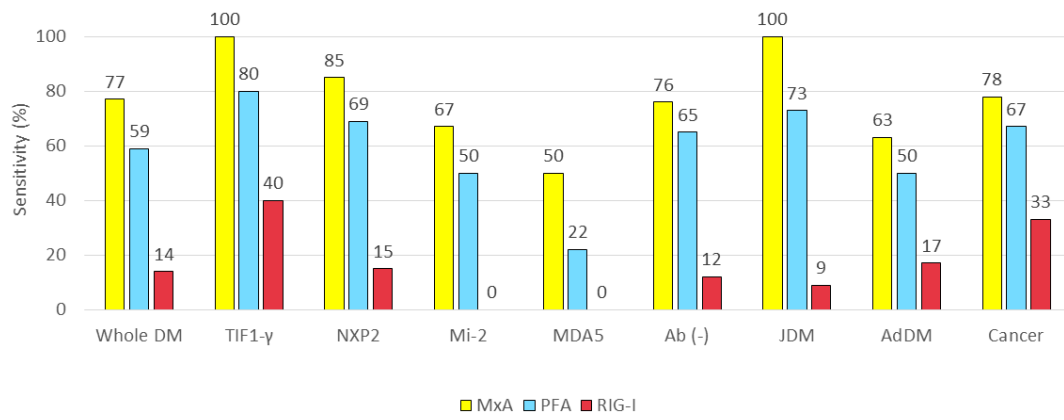


Figure 2

