



HAL
open science

ECCO Position on harmonization of Crohn's disease mucosal histopathology

F Magro, J Sabino, F Rosini, M Tripathi, P Borralho, P Baldin, S Danese, A Driessen, I O Gordon, M Iacucci, et al.

► **To cite this version:**

F Magro, J Sabino, F Rosini, M Tripathi, P Borralho, et al.. ECCO Position on harmonization of Crohn's disease mucosal histopathology. *Journal of Crohn's and Colitis*, 2022, pp.jjac006. 10.1093/ecco-jcc/jjac006 . hal-03528473

HAL Id: hal-03528473

<https://hal.sorbonne-universite.fr/hal-03528473v1>

Submitted on 17 Jan 2022

HAL is a multi-disciplinary open access archive for the deposit and dissemination of scientific research documents, whether they are published or not. The documents may come from teaching and research institutions in France or abroad, or from public or private research centers.

L'archive ouverte pluridisciplinaire **HAL**, est destinée au dépôt et à la diffusion de documents scientifiques de niveau recherche, publiés ou non, émanant des établissements d'enseignement et de recherche français ou étrangers, des laboratoires publics ou privés.

ECCO Position on harmonization of Crohn's disease mucosal histopathology

AUTHORS

Magro F¹, Sabino J², Rosini F³, Tripathi M⁴, Borralho P⁵, Baldin P⁶, Danese S⁷, Driessen A⁸, Gordon IO⁹, Iacucci M¹⁰, Noor N¹¹, Svrcek M¹², Peyrin-Biroulet L¹³, and Feakins R¹⁴

¹ Department of Biomedicine, Unit of Pharmacology and Therapeutics, Faculty of Medicine, University of Porto, Portugal

² Department of Gastroenterology and Hepatology, University Hospitals, KU Leuven, Leuven, Belgium

³ Pathology Unit, IRCCS, S. Orsola-Malpighi University Hospital, Bologna, Italy

⁴ Department of Histopathology, Cambridge University Hospitals NHS Foundation Trust, Cambridge, UK

⁵ Department of Pathology, Hospital Cuf Descobertas, Lisboa and Faculdade de Medicina da Universidade de Lisboa, Lisbon, Portugal

⁶ Department of Pathology, Cliniques Universitaires St-Luc, Université Catholique de Louvain, Brussels, Belgium

⁷ Gastroenterology and Endoscopy, IRCCS Ospedale San Raffaele and University Vita-Salute San Raffaele Milano, Italy

⁸ Department of Pathology, University Hospital Antwerp, University of Antwerp, Edegem, Belgium

⁹ Department of Pathology, Robert J. Tomsich Pathology and Laboratory Medicine Institute, Cleveland Clinic Foundation, Cleveland, Ohio

© The Author(s) 2022. Published by Oxford University Press on behalf of European Crohn's and Colitis Organisation.

This is an Open Access article distributed under the terms of the Creative Commons Attribution-NonCommercial License (<https://creativecommons.org/licenses/by-nc/4.0/>), which permits non-commercial re-use, distribution, and reproduction in any medium, provided the original work is properly cited. For commercial re-use, please contact journals.permissions@oup.com

¹⁰ Institute of Translational Medicine, Institute of Immunology and Immunotherapy, NIHR

Birmingham Biomedical Research Centre, University Hospitals NHS Foundation Trust, University of Birmingham, Birmingham, UK

¹¹ Department of Gastroenterology, Addenbrooke's Hospital, Cambridge University Hospitals NHS Trust, Cambridge, United Kingdom

¹² Sorbonne Université, AP-HP, Hôpital Saint-Antoine, Department of Pathology, 184 rue du Faubourg Saint-Antoine, Paris, France

¹³ Department of Gastroenterology, Nancy University Hospital, Vandoeuvre-Les-Nancy, France

¹⁴ Department of Cellular Pathology, Royal Free Hospital, London, UK

ABBREVIATIONS

CD: Crohn's disease

CGHAS: Colonic global histological disease activity score

CRP: C-reactive protein

ECAP: Extent, chronicity, activity plus

ECCO: European Crohn's and Colitis Organisation

FC: Faecal calprotectin

GHAS: Global Histological Disease Activity Score

GI: Gastrointestinal

IBD: Inflammatory bowel disease

IGHAS: Ileal global histological disease activity score

UC: Ulcerative colitis

ABSTRACT

In inflammatory bowel disease [IBD], mucosal healing is a major therapeutic target and a reliable predictor of clinical course. However, endoscopic mucosal healing is not synonymous with histological healing, and the additional benefits of including histological remission as a target are unclear.

In Crohn's disease [CD], there are few studies highlighting the value of histological remission as a therapeutic target. Histological activity can persist in CD patients who are in endoscopic remission, and the absence of histological activity may be associated with lower relapse rates. Therefore, standardization of procedures to evaluate CD histological activity is desirable. Topics that would benefit from standardization and harmonization include biopsy procedures, biopsy-processing techniques, the content of histological scores, and the definitions of histological remission, histological response, and histological activity.

In line with these needs, the European Crohn's and Colitis Organisation [ECCO] assembled a consensus group with the objective of developing position statements on CD histology based on published evidence and expert consensus.

There was agreement that definitions of histological remission should include absence of erosion, ulceration, and mucosal neutrophils; that the absence of neutrophilic inflammation is an appropriate histological target in CD; that CD histological scores, such as Global Histological Disease Activity Score, lack formal validation; and that histological scoring systems for ulcerative colitis, including the Geboes Score, Roberts Histopathology Index, and Nancy Histological Index, can be used for scoring intestinal biopsies in CD patients.

Keywords: histology; mucosal histopathology; Crohn's disease; standardization.

INTRODUCTION

In inflammatory bowel disease [IBD], endoscopic mucosal healing constitutes evidence of resolution of the inflammatory process, is a reliable predictor of clinical course, and represents an important therapeutic target.^{1,2} The depth of mucosal healing necessary to produce long-term clinical remission is unknown and it is uncertain whether healing should be evaluated by endoscopy, histology, or both modalities. However, histological activity may persist in patients with endoscopic mucosal healing and histological remission may be a better predictor than endoscopic remission of clinical outcome.³ Much of the evidence is from studies of ulcerative colitis [UC].

In Crohn's disease [CD], histological activity may be present in up to one third of intestinal biopsies from patients with endoscopic mucosal healing.⁴ However, evidence regarding the value of histological remission as a therapeutic target is even more sparse in CD than in UC. In some reports, the absence of both histological and endoscopic inflammation in CD after therapy was associated with lower relapse rates.^{5,6} Therefore, minimum standards for the assessment of histology in CD mucosal biopsies are desirable. Aspects of randomized controlled trials and observational studies that would benefit from standardization include biopsy strategies; the approach to the analysis of various intestinal segments; the histological findings to be evaluated; the methods for the calculation of ileal and colonic histology scores; and the definitions of histological response and remission.

The European Crohn's and Colitis Organisation [ECCO] set up a consensus group to adopt position statements regarding CD mucosal histopathology. Details of the methodology are presented in the Supplementary Materials. The overall aim of the group was the standardization and harmonization on the assessment of mucosal histology in CD.

BIOPSY PROCEDURES AND PROCESSING

Statement 1. A reliable histological diagnosis and assessment of Crohn's disease [CD] mucosa requires ileocolonoscopy, with segmental biopsies from the endoscopically most severely affected area [including the edges of ulcers] and from uninflamed segments [EL-3].

Ileocolonoscopy, with segmental targeted biopsies, is considered the most reliable diagnostic procedure for CD, enabling diagnosis, classification, assessment of severity, determination of extent, and differentiation from other inflammatory conditions.

Statement 2. A minimum of two biopsies, from each segment of five sites in colorectum and terminal ileum, in different specimen containers, should be taken and the site of origin should be clearly identifiable [EL-3].

The current recommendation is to obtain at least two specimens at ileocolonoscopy from six segments [terminal ileum, ascending colon, transverse colon, descending colon, sigmoid colon, and rectum] in separate vials.⁷ Targeted biopsies should be taken from the edge of any ulcer and from macroscopically normal mucosa.⁷⁻¹²

There is disagreement about the benefits of routine oesophagogastroduodenoscopy with segmental targeted biopsies in adult patients with a first diagnosis of CD and without upper gastrointestinal [GI] symptoms.¹³⁻¹⁵ A prospective registry study reported a high prevalence of upper GI involvement in asymptomatic CD patients, suggesting a role for standard upper GI endoscopy in the evaluation of disease extent and in guiding management.¹⁵ Upper GI endoscopy with biopsies should be

recommended in symptomatic patients with suspected CD, especially when there is difficulty in reaching a diagnosis. Since upper GI involvement by IBD, and in particular by CD, is more common in paediatric than in adult patients, upper GI tract endoscopy should be considered in children with suspected IBD.¹⁶

Statement 3. Biopsy samples for the diagnosis of Crohn's disease [CD] should be accompanied by the patient's demographic data, clinical history, symptoms, comorbidities, microbiological and serological data, treatment history, and endoscopic findings [EL-5].

After collection, endoscopic biopsies should be immersed immediately in a fixative solution and sent to the pathology laboratory with adequate labelling and a detailed request form containing demographic data, symptoms, comorbidities, endoscopic findings, drug history, and available microbiological and serological information. Biopsy series can be mounted on cellulose acetate strips to maintain orientation of the mucosa [submucosal side down], enabling an accurate histological assessment.¹⁷ In routine practice, haematoxylin and eosin staining is appropriate and sufficient for the diagnosis and assessment of IBD. The ideal number of levels to be analysed is not established. Recommendations range from two to six.⁷ Serial sections and step sections, from different levels, are the best method for optimizing the accuracy of assessment and for increasing the detection of focal mucosal alterations.⁷

HISTOLOGICAL ASSESSMENT: OVERVIEW

Statement 4. In Crohn's disease [CD], it is appropriate to consider (i) the degree of architectural change/distortion; (ii) the degree of lamina propria chronic inflammation (lymphocytes and plasma cells); (iii) basal plasmacytosis; (iv) lamina propria and epithelial neutrophils; (v) epithelial damage; (vi) granulomas; and (vii) erosions and ulcers [EL-2].

In general, histological evaluation of CD biopsies considers the density and distribution of lymphocytes and plasma cells in the lamina propria, lamina propria neutrophils, neutrophil cryptitis, neutrophil crypt abscesses, erosion, ulceration, mucin depletion, crypt architecture, crypt atrophy, and granulomas.¹⁸

Statement 5. When assessing histological disease activity in the observational study setting, blinding of the pathologist to clinical and endoscopic information may help with objective assessment [EL-3].

Several studies include blinding of the pathologist to clinical and or endoscopic information, with the aim of achieving unbiased optimal assessment of histological changes [Supplementary Table 1].^{19–28}

In some studies, pathologists were also blinded to the treatment that the patients received [Supplementary Table 1].^{29–31}

PROGNOSTIC VALUE OF HISTOLOGY

Statement 6. There is evidence that histological findings are associated with the course of Crohn's disease [CD] [EL-4].

Statement 7. Lack of histological activity in an endoscopic biopsy may not reflect inactivity or remission in Crohn's disease [CD] patients [EL-5].

Statement 8. Histological remission in Crohn's disease [CD] patients in endoscopic remission is associated with better clinical outcomes [EL-4].

In UC, histological activity may predict higher rates of relapse in patients in endoscopic remission.³² However, the prognostic value, if any, of histological activity and histological remission in CD is less clear. The presence of certain histological features is associated with poorer disease course and prognosis.^{5,33–36} Asymptomatic patients may exhibit histological disease activity,³⁷ and this may impact disease outcomes. However, definitions of histological activity and remission differ between studies and comparisons are difficult.

In a retrospective study of 62 patients with CD in clinical remission, those with histological activity had a higher rate of flares.⁵ In a retrospective study of 101 patients with isolated ileal CD, histological remission was associated with a lower risk of clinical relapse, escalation of medication, and corticosteroid use.⁶ A study of 215 patients in clinical and endoscopic remission, in which all patients achieved remission through treatment optimization, showed that histological remission was associated with a lower risk of relapse [Supplementary Table 1].³⁸

Several studies evaluated the association between histological and endoscopic scores; the correlation levels ranged from 0.154 to 0.86^{19,20,29,39-53} and resulted from the application of different scores without standardization [Supplementary Table 1 and Supplementary Table 2].^{44,46,47}

Statement 9. CD is typically discontinuous and transmural and can extend beyond the reach of the endoscope. Therefore, a biopsy of Crohn's disease [CD] mucosa may not be representative of disease activity [EL-5].

The discontinuous and patchy nature of CD and the possibility of involvement of any part of the GI tract^{49,54,55} increase the risk of sampling error and create difficulties regarding access to abnormal and clinically relevant areas during endoscopy and biopsy. Furthermore, CD is a transmural process. Therefore, endoscopic assessment and biopsy appearances may not represent clinically relevant changes occurring in layers beneath the mucosa.^{51,56}

INDIVIDUAL HISTOLOGICAL FEATURES

Statement 10. Neutrophils are not normally present within the lamina propria or epithelium of the intestinal mucosa [EL-3].

Statement 11. Histological activity in Crohn's disease [CD] is defined by neutrophilic inflammation of the epithelium, lamina propria, or both. The absence of neutrophilic inflammation is an appropriate histological target [EL-3].

Neutrophils are not normally present within the lamina propria or epithelium of the intestinal mucosa and have been used to define active disease. Assessment of neutrophilic inflammation in these regions may have similar reproducibility in CD and in UC, but this requires confirmation.^{57,58}

Statement 12. Basal plasmacytosis, mucosal eosinophils, and granulomas are not recommended as markers of histological activity or histological remission in Crohn's disease [CD] [EL-4].

Statement 13. Eosinophils should not be used as a marker of histological activity for Crohn's disease [CD] due to the lack of reproducibility between pathologists and lack of supportive data [EL-4].

Basal plasmacytosis is considered the earliest histological feature in CD. Although this is a predictive marker of disease outcome in some studies, the data are not consistent.³²

Eosinophils are normally present within the ileal and colonic lamina propria, and their number decreases gradually towards the distal colon and rectum, with possible seasonal variation. Agreement on how to define an increase in eosinophils is difficult to achieve due to these variations, lack of reproducibility, and suboptimal interobserver agreement.⁵⁹⁻⁶¹ Furthermore, studies of the prognostic value of eosinophils in IBD focused mainly on UC and yielded inconsistent results.^{59,61}

Statement 14. Epithelioid granulomas should not be considered as markers of histological activity in Crohn's disease [CD]. However, they may be used as a prognostic marker [EL-4].

Epithelioid granulomas do not represent a marker of histological activity, but they may be a prognostic marker in CD patients. The presence of granulomas may be associated with increased use

Manuscript Doi: 10.1093/ecco-jcc/jjac006
of steroids and higher rates of hospitalization and surgery.^{34,35} Higher rates of ileocolic disease, upper GI disease, perianal disease, and penetrating disease have been reported in patients with granulomas.³⁴

HISTOLOGICAL SCORES FOR CROHN'S DISEASE

Statement 15. There is no mucosal histological disease activity score that is both specific for Crohn's disease [CD] and validated [EL-5].

More than 14 histological indexes have been proposed for CD [Supplementary Table 2].^{5,17,19,23-31,47,49,51,62-64} The ideal histological score should be able to assess disease activity, demonstrate restoration of chronic inflammation to normality, and distinguish between quiescent colitis and histological normalization.

CD scores differ considerably regarding the number of segments, the anatomical location [colon vs ileum], and the histological features that they evaluate.¹⁸ The major limitation is that none of these scores are fully validated or widely accepted as applicable to clinical trials or clinical practice.^{18,54,65,66}

Statement 16. Histological healing in the intestine varies with the distribution of disease activity in Crohn's disease [CD] [EL-3].

Statement 17. In Crohn's disease [CD], it is appropriate to score the ileum and colon separately given that patients may present with differential involvement [EL-2].

Statement 18. A histological scoring scheme for Crohn's disease [CD] should be applicable to both ileal and colorectal mucosa [EL-5].

Statement 19. The histological score for each segment should be based on the biopsy fragment that is the most affected. The ideal method to calculate a global colonic score, i.e. summing vs averaging the segmental scores, has not yet been determined [EL-4].

As histological healing and the clinical implications of healing may vary according to disease location, assessment of the degree of disease activity in the ileum and in the different segments of the large bowel is necessary. For example, the EXTEND trial demonstrated that patients with moderate-to-severe active disease who received adalimumab showed better mucosal healing in the colon than in the ileum after 52 weeks of treatment [Supplementary Table 1].⁶⁷

Statement 20. The Global Histological Activity Score [GHAS], which is the most commonly used histological scoring system in Crohn's disease [CD], lacks formal validation studies [EL-3].

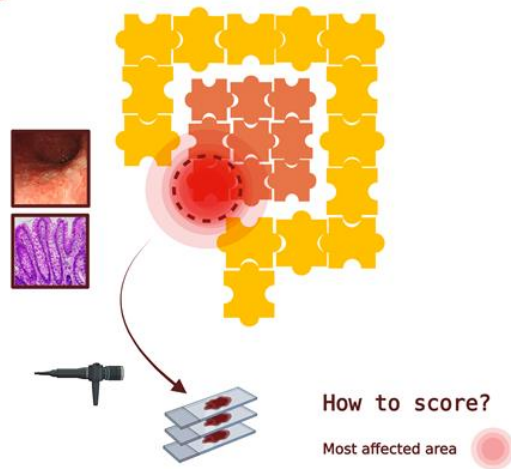
The Global Histological Activity Score [GHAS] records the severity at each ileal and colorectal site and documents disease extent [Supplementary Table 2].⁶⁸ The approach is to assess and score, at each site, the fragment in which each feature is the most abnormal. A final score between 0 and 16 serves as a guide to histological 'activity' and enables measurement of the improvement in mucosal state.^{26,68} However, GHAS has not been fully validated and the inclusion of granulomas in the score has been criticized.⁵⁵

Scoring for CD should enable assessment of both ileum and colorectum, but some CD scoring systems are specific for one anatomical site [e.g. ileum only, large bowel only, or even rectum only].^{6,21,25,64} Several other scoring systems, including GHAS and modifications of GHAS, are for separate assessment.^{24,25,68} GHAS, in particular, is applicable to ileum only, colon only, or both.⁶⁸ However, colonic GHAS [CGHAS] may be more reliable than ileal GHAS [IGHAS], and some authors observed higher interobserver consistency for CGHAS than for IGHAS.⁴⁴ Furthermore, faecal calprotectin [FC] and lactoferrin levels correlated well with CGHAS but not with IGHAS.⁴⁹

In a Cochrane review of 14 studies, one study evaluated the terminal ileum exclusively,⁶⁹ while nine assessed both terminal ileum and colon.^{10,46,65,70-75} Other scoring systems that may be applicable to terminal ileum biopsies in CD include the extent, chronicity, activity plus [ECAP] score⁷³ and Binder score.⁷⁶ In Naini and Cortina's scoring system, the ileum and colon are scored separately.²⁴ All these scoring systems include variables that are not necessarily indicative of active disease.

It seems appropriate to use the worst score for an item present across all segments. The most appropriate method for calculating a global colonic score, i.e. summing the segmental scores versus averaging the segmental scores, has not yet been agreed [Figure 1].⁶⁵

Ileal Biopsies



Colonic Biopsies

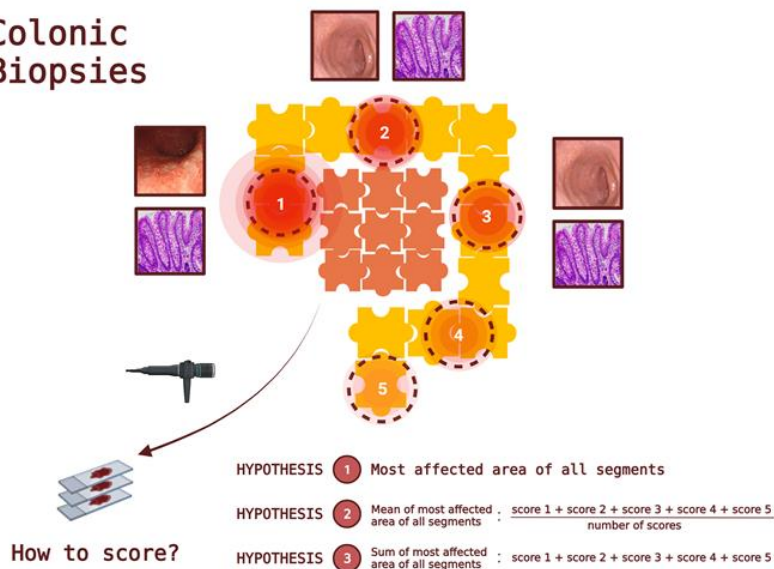


Figure 1. Ileal and colonic biopsies

APPLICABILITY OF ULCERATIVE COLITIS HISTOLOGY SCORES TO CROHN'S DISEASE

Statement 21. Histological scoring systems for ulcerative colitis [UC], including the Geboes Score, Roberts Histopathology Index [RHI], and Nancy Histological Index, can be used for scoring intestinal biopsies from Crohn's disease [CD] patients [EL-4].

Histological scoring systems that were originally developed for the evaluation of UC have been applied to CD intestinal mucosal biopsies.^{10,40,46,69-74,77-86} The Geboes score is the most common in this setting.^{22,40,46,69,70,72-74,77,78,86,87} The RHI^{10,46,72,73} and Nancy Histological Index^{10,73,79} are also used. Several studies applied more than one UC score.^{10,46,72,73} For example, two prospective studies of endoscopic and histological activity after treatment of CD used both the Geboes score and the RHI.^{46,72} At least three studies included a paediatric population with CD, with two of them using the Geboes score exclusively.^{69,87} Valid criticisms of using UC scores to assess CD are that UC scores are designed for the large bowel only and for the assessment of UC only.

Almradi *et al.* conducted a study aiming to standardize CD mucosal biopsy evaluation for clinical trials and concluded that both the Geboes score and the RHI are appropriate for assessing CD biopsies, but were uncertain about using the Nancy Histological Index.⁶⁵

Villanacci *et al.* studied four different UC scores (Geboes score, ECAP, Nancy Histological Index and RHI) in 12 adults with UC and 12 with CD in endoscopic remission. The studies were performed both before and after therapy and there was very good inter-rater variability.⁷³

CLINICAL PRACTICE

Statement 22. The Nancy Histological Index can be used for Crohn's disease [CD] biopsies in clinical practice [EL-5].

A recent ECCO position paper recommended the Nancy Histological Index or a similar approach to score UC histological inflammation in routine clinical practice.⁸⁸ However, a simple validated scheme

is not available for CD. The Nancy Histological Index may be the best option for clinical practice.

However, this index does not fully determine histological healing and normalization in CD.

DEFINITIONS OF HISTOLOGICAL REMISSION

Statement 23. The most stringent definition of histological remission in Crohn's disease [CD] is normalization of mucosal histology [EL-5].

Statement 24. Definitions of histological remission in Crohn's disease [CD] following treatment should include absence of erosion, ulceration, and epithelial damage; absence of intraepithelial neutrophils; and absence of inflammation [EL-3].

Statement 25. Absence of ulceration, erosions, and mucosal neutrophils is a good definition of histological remission and a realistic endpoint after induction therapy in Crohn's disease [CD] [EL-4].

The terms to describe histological endpoints are numerous and include histological inactivity, histological improvement, histological healing, histological mucosal healing, histological response, and histological remission. The available studies have a wide range of criteria for defining histological endpoints and have different cut-off points to distinguish between remission and non-remission. Constituent features and calculations of scores also vary between CD histology scoring schemes. Approaches to assessment may depend on ranges of scores, dichotomised scores, or continuous scores, or on the presence or absence of one or more histological features. Options include a binary score, a stepwise assessment, and complex scores.^{4,27,49,51,54,65,89}

A recent consensus paper stated that histological activity in CD should be defined by the presence of neutrophils in the mucosa, and that absence of mucosal neutrophils is an appropriate and realistic histological target following induction therapy.⁶⁵ The same consensus concluded that appropriate measures of activity in clinical trials should include histological disease activity, remission, and response.⁶⁵ However, no definition of histological remission in UC or CD is widely acceptable or validated.⁵⁵

ANCILLARY TESTS AND HISTOLOGY

Statement 26. Patients with elevated C-reactive protein [CRP], faecal calprotectin, and faecal lactoferrin are more likely to have active histological inflammation. Exact thresholds are not known. Therefore, none of these biomarkers can be used as a surrogate for histological activity [EL-3].

Many biomarkers may show a correlation with histological inflammation in IBD, including C-reactive protein [CRP]^{21,44,48}, FC^{44,48-50,70,86,90-93}, and faecal lactoferrin^{44,49,50}, among others [Supplementary Table 3].^{47,94-99} However, these studies used a variety of histological scores and criteria to determine histological remission or response. One study showed a correlation between FC and faecal lactoferrin concentration and colonic disease or ileocolonic disease but not ileal disease.⁴⁹

CONCLUSION

Histological remission may be a useful treatment target for CD, as it may add prognostic information over and above endoscopy. However, the most suitable histological scoring scheme for clinical trials, observational studies, or clinical practice. Specific CD scores are often complex or difficult to apply and their assessment is less straightforward and possibly less meaningful than in UC.

Currently, application of UC scores to CD mucosa, though not ideal, is probably the most appropriate choice. The Nancy Histological Index appears to be the best option for clinical practice. The best measure of histological activity in CD is the presence of mucosal neutrophils, ulceration, erosion, or combinations thereof. Different approaches are necessary for clinical practice, observational studies, and clinical trials.

Overall, there is a need for universal definitions. The definitions of histological inactivity and remission in CD could be derived from the assessment of one or more individual histological features or from the application of a histological scoring scheme. However, a simple scoring scheme for CD may facilitate global agreement on definitions of histological remission.

Conflict of Interest

ECCO has diligently maintained a disclosure policy of potential conflicts of interests. The conflict of interest declaration is based on a form used by the International Committee of Medical Journal Editors. The conflict of interest statement is not only stored at the ECCO Office and the editorial office of Journal of Crohn's and Colitis, but also open to public scrutiny on the ECCO website [<https://www.ecco-ibd.eu/about-ecco/ecco-disclosures.html>] providing a comprehensive overview of potential conflicts of interest of authors.

Disclaimer

ECCO Position Statement projects are based on an international consensus process. Any treatment decisions are a matter for the individual clinician and should not be based exclusively on the content of the ECCO Position Statement. The ECCO and/or any of its staff members and/or any consensus contributor may not be held liable for any information published in good faith in an ECCO Position Statement.

Author Contributions

This article is a joint expert consensus activity. Hence, all authors participated intellectually and practically in this work and take public responsibility for the content of the article, including conception, design, data interpretation, and writing. All authors and the ECCO Governing Board approved the final version for submission.

Accepted Manuscript

REFERENCES

1. Magro F., Gionchetti P., Eliakim R., Ardizzone S., Armuzzi A., Barreiro-de Acosta M., et al. Third European Evidence-based Consensus on Diagnosis and Management of Ulcerative Colitis. Part 1: Definitions, Diagnosis, Extra-intestinal Manifestations, Pregnancy, Cancer Surveillance, Surgery, and Ileo-anal Pouch Disorders. *J Crohns Colitis* 2017;**11**(6):649–70. Doi: 10.1093/ecco-jcc/jjx008.
2. Gionchetti P., Dignass A., Danese S., Magro Dias FJ., Rogler G., Lakatos PL., et al. 3rd European Evidence-based Consensus on the Diagnosis and Management of Crohn's Disease 2016: Part 2: Surgical Management and Special Situations. *J Crohn's Colitis* 2017;**11**(2):135–49. Doi: 10.1093/ecco-jcc/jjw169.
3. Narang V., Kaur R., Garg B., Mahajan R., Midha V., Sood N., et al. Association of endoscopic and histological remission with clinical course in patients of ulcerative colitis. *Intest Res* 2018;**16**(1):55. Doi: 10.5217/ir.2018.16.1.55.
4. Molander P., Sipponen T., Kemppainen H., Jussila A., Blomster T., Koskela R., et al. Achievement of deep remission during scheduled maintenance therapy with TNF α -blocking agents in IBD. *J Crohn's Colitis* 2013;**7**(9):730–5. Doi: 10.1016/j.crohns.2012.10.018.
5. Brennan GT., Melton SD., Spechler SJ., Feagins LA. Clinical Implications of Histologic Abnormalities in Ileocolonic Biopsies of Patients With Crohn's Disease in Remission. *J Clin Gastroenterol* 2017;**51**(1):43–8. Doi: 10.1097/MCG.0000000000000507.
6. Christensen B., Erlich J., Gibson PR., Turner JR., Hart J., Rubin DT. Histologic Healing Is More Strongly Associated with Clinical Outcomes in Ileal Crohn's Disease than Endoscopic Healing. *Clin Gastroenterol Hepatol* 2020;**18**(11):2518-2525.e1. Doi: 10.1016/j.cgh.2019.11.056.
7. Magro F., Langner C., Driessen A., Ensari A., Geboes K., Mantzaris GJ., et al. European consensus on the histopathology of inflammatory bowel disease. *J Crohns Colitis* 2013;**7**(10):827–51. Doi: 10.1016/j.crohns.2013.06.001.
8. Dejaco C., Oesterreicher C., Angelberger S., Püspök A., Birner P., Poetzi R., et al. Diagnosing Colitis: a Prospective Study on Essential Parameters for Reaching a Diagnosis. *Endoscopy* 2003;**35**(12):1004–8. Doi: 10.1055/s-2003-44593.
9. Annese V., Daperno M., Rutter MD., Amiot A., Bossuyt P., East J., et al. European evidence based consensus for endoscopy in inflammatory bowel disease. *J Crohn's Colitis*

10. Novak G., Stevens T., Van Viegen T., Bossuyt P., Štabuc B., Jeyarajah J., et al. Evaluation of optimal biopsy location for assessment of histological activity, transcriptomic and immunohistochemical analyses in patients with active Crohn's disease. *Aliment Pharmacol Ther* 2019;**49**(11):1401–9. Doi: 10.1111/apt.15250.
11. Maaser C., Sturm A., Vavricka SR., Kucharzik T., Fiorino G., Annese V., et al. ECCO Guideline / Consensus Paper ECCO-ESGAR Guideline for Diagnostic Assessment in IBD Part 1 : Initial diagnosis , monitoring of known IBD , detection of complications 2019:144–64. Doi: 10.1093/ecco-jcc/jjy113.
12. Dignass A., Van Assche G., Lindsay JO., Lémann M., Söderholm J., Colombel JF., et al. The second European evidence-based Consensus on the diagnosis and management of Crohn's disease: Current management. *J Crohn's Colitis* 2010;**4**(1):28–62. Doi: 10.1016/j.crohns.2009.12.002.
13. Rutgeerts P., Onette E., Vantrappen G., Geboes K., Broeckaert L., Talloen L. Crohn's Disease of the Stomach and Duodenum: A Clinical Study with Emphasis on the Value of Endoscopy and Endoscopic Biopsies. *Endoscopy* 1980;**12**(06):288–94. Doi: 10.1055/s-2007-1021762.
14. Wagtmans M. Crohn's disease of the upper gastrointestinal tract. *Neth J Med* 1997;**50**(2):S2–7. Doi: 10.1016/S0300-2977(96)00063-0.
15. Annunziata ML., Caviglia R., Papparella LG., Cicala M. Upper gastrointestinal involvement of Crohn's disease: a prospective study on the role of upper endoscopy in the diagnostic work-up. *Dig Dis Sci* 2012;**57**(6):1618–23. Doi: 10.1007/s10620-012-2072-0.
16. Castellaneta SP., Afzal NA., Greenberg M., Deere H., Davies S., Murch SH., et al. Diagnostic Role of Upper Gastrointestinal Endoscopy in Pediatric Inflammatory Bowel Disease. *J Pediatr Gastroenterol Nutr* 2004;**39**(3):257–61. Doi: 10.1097/00005176-200409000-00006.
17. Lang-Schwarz C., Agaimy A., Atreya R., Becker C., Danese S., Fléjou J-F., et al. Maximizing the diagnostic information from biopsies in chronic inflammatory bowel diseases: recommendations from the Erlangen International Consensus Conference on Inflammatory Bowel Diseases and presentation of the IBD-DCA score as a proposal for a new i. *Virchows Arch* 2021;**478**(3):581–94. Doi: 10.1007/s00428-020-02982-7.
18. Neri B., Mossa M., Scucchi L., Sena G., Palmieri G., Biancone L. Histological scores in

19. Agnholt J., Dahlerup JF., Buntzen S., Tøttrup A., Nielsen SL., Lundorf E. Response, relapse and mucosal immune regulation after infliximab treatment in fistulating Crohn's disease. *Aliment Pharmacol Ther* 2003;**17**(5):703–10. Doi: 10.1046/j.1365-2036.2003.01487.x.
20. Regueiro M., Palma-Diaz M., El-Hachem S., Kip KE., Schraut WH., Harrison J., et al. Correlation of Histologic and Endoscopic Scores for Evaluation of Crohn's Disease Recurrence After Ileal Resection and Infliximab Therapy. *Gastroenterology* 2010;**138**(5):S-358. Doi: 10.1016/S0016-5085(10)61651-4.
21. Gomes P., du Boulay C., Smith CL., Holdstock G. Relationship between disease activity indices and colonoscopic findings in patients with colonic inflammatory bowel disease. *Gut* 1986;**27**(1):92–5. Doi: 10.1136/gut.27.1.92.
22. Geboes K. A reproducible grading scale for histological assessment of inflammation in ulcerative colitis. *Gut* 2000;**47**(3):404–9. Doi: 10.1136/gut.47.3.404.
23. Mantzaris GJ., Christidou A., Sfakianakis M., Roussos A., Koilakou S., Petraki K., et al. Azathioprine Is Superior to Budesonide in Achieving and Maintaining Mucosal Healing and Histologic Remission in Steroid-Dependent Crohn's Disease. *Inflamm Bowel Dis* 2009;**15**(3):375–82. Doi: 10.1002/ibd.20777.
24. Naini B V., Cortina G. A histopathologic scoring system as a tool for standardized reporting of chronic (ileo)colitis and independent risk assessment for inflammatory bowel disease. *Hum Pathol* 2012;**43**(12):2187–96. Doi: 10.1016/j.humpath.2012.03.008.
25. Ward M., Webb JN. Rectal biopsy as a prognostic guide in Crohn's colitis. *J Clin Pathol* 1977;**30**(2):126–31. Doi: 10.1136/jcp.30.2.126.
26. D'Haens G., Van Deventer S., Van Hogezaand R., Chalmers D., Kothe C., Baert F., et al. Endoscopic and histological healing with infliximab anti-tumor necrosis factor antibodies in Crohn's disease: A European multicenter trial. *Gastroenterology* 1999;**116**(5):1029–34. Doi: 10.1016/S0016-5085(99)70005-3.
27. Yamamoto T., Nakahigashi M., Umegae S., Kitagawa T., Matsumoto K. Impact of Elemental Diet on Mucosal Inflammation in Patients with Active Crohn's Disease: Cytokine Production and Endoscopic and Histological Findings. *Inflamm Bowel Dis* 2005;**11**(6):580–8. Doi: 10.1097/01.MIB.0000161307.58327.96.

28. Novak G., Parker CE., Pai RK., MacDonald JK., Feagan BG., Sandborn WJ., et al. Histologic scoring indices for evaluation of disease activity in Crohn's disease. *Cochrane Database Syst Rev* 2017;**2017**(7). Doi: 10.1002/14651858.CD012351.pub2.
29. Laharie D., Reffet A., Belleannée G., Chabrun E., Subtil C., Razaire S., et al. Mucosal healing with methotrexate in Crohn's disease: a prospective comparative study with azathioprine and infliximab. *Aliment Pharmacol Ther* 2011;**33**(6):714–21. Doi: 10.1111/j.1365-2036.2010.04569.x.
30. Baert FJ., D'Haens GR., Peeters M., Hiele MI., Schaible TF., Shealy D., et al. Tumor necrosis factor α antibody (infliximab) therapy profoundly down-regulates the inflammation in Crohn's ileocolitis. *Gastroenterology* 1999;**116**(1):22–8. Doi: 10.1016/S0016-5085(99)70224-6.
31. Smith JP., Bingaman SI., Ruggiero F., Mauger DT., Mukherjee A., McGovern CO., et al. Therapy with the Opioid Antagonist Naltrexone Promotes Mucosal Healing in Active Crohn's Disease: A Randomized Placebo-Controlled Trial. *Dig Dis Sci* 2011;**56**(7):2088–97. Doi: 10.1007/s10620-011-1653-7.
32. Gupta A., Yu A., Peyrin-Biroulet L., Ananthakrishnan AN. Treat to Target: The Role of Histologic Healing in Inflammatory Bowel Diseases: A Systematic Review and Meta-analysis. *Clin Gastroenterol Hepatol* 2021;**19**(9):1800-1813.e4. Doi: 10.1016/j.cgh.2020.09.046.
33. VanDussen KL., Liu T-C., Li D., Towfic F., Modiano N., Winter R., et al. Genetic Variants Synthesize to Produce Paneth Cell Phenotypes That Define Subtypes of Crohn's Disease. *Gastroenterology* 2014;**146**(1):200–9. Doi: 10.1053/j.gastro.2013.09.048.
34. Hong SW., Yoon H., Shin CM., Park YS., Kim N., Lee DH., et al. Clinical significance of granulomas in Crohn's disease: A systematic review and meta-analysis. *J Gastroenterol Hepatol* 2020;**35**(3):364–73. Doi: 10.1111/jgh.14849.
35. Johnson CM., Hartman DJ., Ramos-Rivers C., Rao BB., Bhattacharya A., Regueiro M., et al. Epithelioid Granulomas Associate With Increased Severity and Progression of Crohn's Disease, Based on 6-Year Follow-Up. *Clin Gastroenterol Hepatol* 2018;**16**(6):900-907.e1. Doi: 10.1016/j.cgh.2017.12.034.
36. Molander P., Kempainen H., Ilus T., Sipponen T. Long-term deep remission during maintenance therapy with biological agents in inflammatory bowel diseases. *Scand J*

37. Baars JE., Nuij VJAA., Oldenburg B., Kuipers EJ., van der Woude CJ. Majority of patients with inflammatory bowel disease in clinical remission have mucosal inflammation. *Inflamm Bowel Dis* 2012;**18**(9):1634–40. Doi: 10.1002/ibd.21925.
38. Yoon H., Jangi S., Dulai PS., Boland BS., Jairath V., Feagan BG., et al. Histologic Remission Is Associated With Lower Risk of Treatment Failure in Patients With Crohn Disease in Endoscopic Remission. *Inflamm Bowel Dis* 2021;**27**(8):1277–84. Doi: 10.1093/ibd/izaa301.
39. Kucharski M., Karczewski J., Mańkowska-Wierzbicka D., Karmelita-Katulaska K., Kaczmarek E., Iwanik K., et al. Usefulness of Endoscopic Indices in Determination of Disease Activity in Patients with Crohn's Disease. *Gastroenterol Res Pract* 2016;**2016**:7896478. Doi: 10.1155/2016/7896478.
40. Noman M., Ferrante M., Bisschops R., De Hertogh G., Van den Broeck K., Rans K., et al. Vedolizumab Induces Long-term Mucosal Healing in Patients With Crohn's Disease and Ulcerative Colitis. *J Crohns Colitis* 2017;**11**(9):1085–9. Doi: 10.1093/ecco-jcc/jjx048.
41. Giugliano FP., Strisciuglio C., Martinelli M., Andreozzi M., Cenni S., Campione S., et al. Does Azathioprine induce endoscopic and histologic healing in pediatric inflammatory bowel disease? A prospective, observational study. *Dig Liver Dis* 2018;**50**(3):240–6. Doi: 10.1016/j.dld.2017.10.017.
42. Danese S., Sandborn WJ., Colombel J-F., Vermeire S., Glover SC., Rimola J., et al. Endoscopic, Radiologic, and Histologic Healing With Vedolizumab in Patients With Active Crohn's Disease. *Gastroenterology* 2019;**157**(4):1007-1018.e7. Doi: 10.1053/j.gastro.2019.06.038.
43. Gong W., Guo K., Zheng T., Fang M., Xie H., Li W., et al. Correlation between endoscopic and histological validated scoring indices in Crohn's disease. *Dig Liver Dis* 2019;**51**(6):812–7. Doi: 10.1016/j.dld.2019.01.010.
44. Li K., Friedman JR., Chan D., Pollack P., Yang F., Jacobstein D., et al. Effects of Ustekinumab on Histologic Disease Activity in Patients With Crohn's Disease. *Gastroenterology* 2019;**157**(4):1019-1031.e7. Doi: 10.1053/j.gastro.2019.06.037.
45. Tajra JB., Calegario JU., de Paula AP., Bachour D., Silveira D., Lozi M., et al. Correlation and concordance measures between clinical, endoscopic and histological scores activity in Crohn's disease under treatment. *Scand J Gastroenterol* 2019;**54**(4):441–5. Doi:

46. Löwenberg M., Vermeire S., Mostafavi N., Hoentjen F., Franchimont D., Bossuyt P., et al. Vedolizumab Induces Endoscopic and Histologic Remission in Patients With Crohn's Disease. *Gastroenterology* 2019;**157**(4):997-1006.e6. Doi: 10.1053/j.gastro.2019.05.067.
47. Geboes K., Rutgeerts P., Opdenakker G., Olson A., Patel K., Wagner CL., et al. Endoscopic and histologic evidence of persistent mucosal healing and correlation with clinical improvement following sustained infliximab treatment for Crohn's disease. *Curr Med Res Opin* 2005;**21**(11):1741–54. Doi: 10.1185/030079905X65457.
48. Berni Canani R., Terrin G., Rapacciuolo L., Miele E., Siani MC., Puzone C., et al. Faecal calprotectin as reliable non-invasive marker to assess the severity of mucosal inflammation in children with inflammatory bowel disease. *Dig Liver Dis* 2008;**40**(7):547–53. Doi: 10.1016/j.dld.2008.01.017.
49. Sipponen T., Kärkkäinen P., Savilahti E., Kolho K-L., Nuutinen H., Turunen U., et al. Correlation of faecal calprotectin and lactoferrin with an endoscopic score for Crohn's disease and histological findings. *Aliment Pharmacol Ther* 2008;**28**(10):1221–9. Doi: 10.1111/j.1365-2036.2008.03835.x.
50. Sipponen T., Savilahti E., Kärkkäinen P., Kolho K-L., Nuutinen H., Turunen U., et al. Fecal calprotectin, lactoferrin, and endoscopic disease activity in monitoring anti-TNF-alpha therapy for Crohn's disease. *Inflamm Bowel Dis* 2008;**14**(10):1392–8. Doi: 10.1002/ibd.20490.
51. Drews BH., Barth TFE., Hänle MM., Akinli AS., Mason RA., Muche R., et al. Comparison of sonographically measured bowel wall vascularity, histology, and disease activity in Crohn's disease. *Eur Radiol* 2009;**19**(6):1379–86. Doi: 10.1007/s00330-008-1290-5.
52. Algaba A., Linares PM., Fernández-Contreras ME., Ordoñez A., Trápaga J., Guerra I., et al. Relationship between levels of angiogenic and lymphangiogenic factors and the endoscopic, histological and clinical activity, and acute-phase reactants in patients with inflammatory bowel disease. *J Crohn's Colitis* 2013;**7**(11):e569–79. Doi: 10.1016/j.crohns.2013.04.005.
53. Durko L., Stasikowska-Kanicka OA., Wagrowska-Danilewicz M., Danilewicz M., Małeczka-Panas EI. An analysis of the correlation of clinical, endoscopic and histological classifications in Crohn's disease. *Prz Gastroenterol* 2013;**8**(6):377–82. Doi: 10.5114/pg.2013.39921.
54. Mojtahed A., Khanna R., Sandborn WJ., D'Haens GR., Feagan BG., Shackelton LM., et al.

Assessment of histologic disease activity in Crohn's disease: a systematic review. *Inflamm Bowel Dis* 2014;**20**(11):2092–103. Doi: 10.1097/MIB.0000000000000155.

55. Bryant RV., Winer S., SPL T., Riddell RH. Systematic review: Histological remission in inflammatory bowel disease. Is 'complete' remission the new treatment paradigm? An IOIBD initiative. *J Crohn's Colitis* 2014;**8**(12):1582–97. Doi: 10.1016/j.crohns.2014.08.011.
56. Feakins RM. Transmural Histology Scores in Stricturing Crohn's Disease: Seeking to Build Precision on Uncertain Foundations. *J Crohn's Colitis* 2020;**14**(6):721–3. Doi: 10.1093/ecco-jcc/jjaa008.
57. Mosli MH., Feagan BG., Zou G., Sandborn WJ., D'Haens G., Khanna R., et al. Development and validation of a histological index for UC. *Gut* 2017;**66**(1):50–8. Doi: 10.1136/gutjnl-2015-310393.
58. Pai RK., Jairath V. What is the role of histopathology in the evaluation of disease activity in Crohn's disease? *Best Pract Res Clin Gastroenterol* 2019;**38–39**:101601. Doi: 10.1016/j.bpg.2019.02.003.
59. Zezos P., Patsiaoura K., Nakos A., Mpoumponaris A., Vassiliadis T., Giouleme O., et al. Severe eosinophilic infiltration in colonic biopsies predicts patients with ulcerative colitis not responding to medical therapy. *Colorectal Dis* 2014;**16**(12):O420-30. Doi: 10.1111/codi.12725.
60. Turner KO., Sinkre RA., Neumann WL., Genta RM. Primary Colonic Eosinophilia and Eosinophilic Colitis in Adults. *Am J Surg Pathol* 2017;**41**(2):225–33. Doi: 10.1097/PAS.0000000000000760.
61. Morgenstern S., Brook E., Rinawi F., Shamir R., Assa A. Tissue and peripheral eosinophilia as predictors for disease outcome in children with ulcerative colitis. *Dig Liver Dis* 2017;**49**(2):170–4. Doi: 10.1016/j.dld.2016.11.007.
62. Best WR., Bectel JM., Singleton JW., Kern F. Development of a Crohn's disease activity index. National Cooperative Crohn's Disease Study. *Gastroenterology* 1976;**70**(3):439–44.
63. Colombel J-F., Sandborn WJ., Rutgeerts P., Enns R., Hanauer SB., Panaccione R., et al. Adalimumab for maintenance of clinical response and remission in patients with Crohn's disease: the CHARM trial. *Gastroenterology* 2007;**132**(1):52–65. Doi: 10.1053/j.gastro.2006.11.041.

64. Regueiro M., Schraut W., Baidoo L., Kip KE., Sepulveda AR., Pesci M., et al. Infliximab prevents Crohn's disease recurrence after ileal resection. *Gastroenterology* 2009;**136**(2):441-50.e1; quiz 716. Doi: 10.1053/j.gastro.2008.10.051.
65. Almradi A., Ma C., D'Haens GR., Sandborn WJ., Parker CE., Guizzetti L., et al. An expert consensus to standardise the assessment of histological disease activity in Crohn's disease clinical trials. *Aliment Pharmacol Ther* 2021;**53**(7):784–93. Doi: 10.1111/apt.16248.
66. Salem MS., Melmed GY. The Role of Histology in Determining Disease Activity, Treatment, and Prognosis: Are We There yet? *Gastrointest Endosc Clin N Am* 2019;**29**(3):437–46. Doi: 10.1016/j.giec.2019.02.010.
67. Reinisch W., Colombel J-F., D'Haens G., Sandborn WJ., Rutgeerts P., Geboes K., et al. Characterisation of Mucosal Healing with Adalimumab Treatment in Patients with Moderately to Severely Active Crohn's Disease: Results from the EXTEND Trial. *J Crohn's Colitis* 2016;jjw178. Doi: 10.1093/ecco-jcc/jjw178.
68. D'Haens GR., Geboes K., Peeters M., Baert F., Penninckx F., Rutgeerts P. Early lesions of recurrent Crohn's disease caused by infusion of intestinal contents in excluded ileum. *Gastroenterology* 1998;**114**(2):262–7.
69. Alipour M., Zaidi D., Valcheva R., Jovel J., Martínez I., Sergi C., et al. Mucosal Barrier Depletion and Loss of Bacterial Diversity are Primary Abnormalities in Paediatric Ulcerative Colitis. *J Crohn's Colitis* 2016;**10**(4):462–71. Doi: 10.1093/ecco-jcc/jjv223.
70. Zittan E., Kelly OB., Kirsch R., Milgrom R., Burns J., Nguyen GC., et al. Low Fecal Calprotectin Correlates with Histological Remission and Mucosal Healing in Ulcerative Colitis and Colonic Crohn's Disease. *Inflamm Bowel Dis* 2016;**22**(3):623–30. Doi: 10.1097/MIB.0000000000000652.
71. Allgayer H., Roisch U., Zehnter E., Ziegenhagen DJ., Dienes HP., Kruis W. Colonic Ornithine Decarboxylase in Inflammatory Bowel Disease: Ileorectal Activity Gradient, Guanosine Triphosphate Stimulation, and Association with Epithelial Regeneration but Not the Degree of Inflammation and Clinical Features. *Dig Dis Sci* 2007;**52**(1):25–30. Doi: 10.1007/s10620-006-9515-4.
72. Feagan BG., Sandborn WJ., Danese S., Wolf DC., Liu WJ., Hua SY., et al. Ozanimod induction therapy for patients with moderate to severe Crohn's disease: a single-arm, phase 2,

- prospective observer-blinded endpoint study. *Lancet Gastroenterol Hepatol* 2020;**5**(9):819–28. Doi: 10.1016/S2468-1253(20)30188-6.
73. Villanacci V., Antonelli E., Lanzarotto F., Bozzola A., Cadei M., Bassotti G. Usefulness of Different Pathological Scores to Assess Healing of the Mucosa in Inflammatory Bowel Diseases: A Real Life Study. *Sci Rep* 2017;**7**(1):6839. Doi: 10.1038/s41598-017-07338-x.
 74. Abreu-Delgado Y., Isidro RA., Torres EA., González A., Cruz ML., Isidro AA., et al. Serum vitamin D and colonic vitamin D receptor in inflammatory bowel disease. *World J Gastroenterol* 2016;**22**(13):3581–91. Doi: 10.3748/wjg.v22.i13.3581.
 75. Pai RK., Geboes K. Disease activity and mucosal healing in inflammatory bowel disease: a new role for histopathology? *Virchows Arch* 2018;**472**(1):99–110. Doi: 10.1007/s00428-017-2156-5.
 76. Binder V. A Comparison between Clinical State, Macroscopic and Microscopic Appearances of Rectal Mucosa, and Cytologic Picture of Mucosal Exudate in Ulcerative Colitis. *Scand J Gastroenterol* 1970;**5**(7):627–32. Doi: 10.1080/00365521.1970.12096647.
 77. Baars JE., Vogelaar L., Wolfhagen FHJ., Biermann K., Kuipers EJ., van der Woude CJ. A short course of corticosteroids prior to surveillance colonoscopy to decrease mucosal inflammation in inflammatory bowel disease patients: Results from a randomized controlled trial. *J Crohn's Colitis* 2010;**4**(6):661–8. Doi: 10.1016/j.crohns.2010.07.011.
 78. Lv C., Gu H., Zhao X., Huang L., Zhou S., Zhi F. Involvement of Activated Cdc42 Kinase1 in Colitis and Colorectal Neoplasms. *Med Sci Monit* 2016;**22**:4794–802. Doi: 10.12659/MSM.902274.
 79. Kirchgessner J., Svrcek M., Le Gall G., Landman C., Dray X., Bourrier A., et al. Nancy Index Scores of Chronic Inflammatory Bowel Disease Activity Associate With Development of Colorectal Neoplasia. *Clin Gastroenterol Hepatol* 2020;**18**(1):150-157.e1. Doi: 10.1016/j.cgh.2019.05.002.
 80. Lobatón T. Relationship between methylation and colonic inflammation in inflammatory bowel disease. *World J Gastroenterol* 2014;**20**(30):10591. Doi: 10.3748/wjg.v20.i30.10591.
 81. Roediger WE. Thiol methyltransferase activity in inflammatory bowel disease. *Gut* 2000;**47**(2):206–10. Doi: 10.1136/gut.47.2.206.

82. Ruthlein J., Ibe M., Burghardt W., Mossner J., Auer IO. Immunoglobulin G (IgG), IgG1, and IgG2 determinations from endoscopic biopsy specimens in control, Crohn's disease, and ulcerative colitis subjects. *Gut* 1992;**33**(4):507–12. Doi: 10.1136/gut.33.4.507.
83. Şimşek HD., Basyigit S., Aktas B., Vargol E., Şimşek GG., Küçükazman M., et al. Comparing the type and severity of inflammatory bowel disease in relation to IgG4 immunohistochemical staining. *Acta Gastroenterol Belg* n.d.;**79**(2):216–21.
84. Smedh K., Olaison G., Franzén L., Sjobahl R. Endoscopic and external bowel changes and histopathology in patients with Crohn's disease. *Br J Surg* 1995;**82**(2):191–4. Doi: 10.1002/bjs.1800820217.
85. Katsuta T., Lim C., Shimoda K., Shibuta K., Mitra P., Banner BF., et al. Interleukin-8 and SDF1-alpha mRNA expression in colonic biopsies from patients with inflammatory bowel disease. *Am J Gastroenterol* 2000;**95**(11):3157–64. Doi: 10.1111/j.1572-0241.2000.03289.x.
86. Mooiweer E., Severs M., Schipper MEI., Fidler HH., Siersema PD., Laheij RJF., et al. Low Fecal Calprotectin Predicts Sustained Clinical Remission in Inflammatory Bowel Disease Patients: A Plea for Deep Remission. *J Crohn's Colitis* 2015;**9**(1):50–5. Doi: 10.1093/ecco-jcc/jju003.
87. Sznurkowska K., Żawrocki A., Sznurkowski J., Iżycka-Świeszewska E., Landowski P., Szlagatys-Sidorkiewicz A., et al. Indoleamine 2,3-dioxygenase and regulatory t cells in intestinal mucosa in children with inflammatory bowel disease. *J Biol Regul Homeost Agents* n.d.;**31**(1):125–31.
88. Magro F., Doherty G., Peyrin-Biroulet L., Svrcek M., Borralho P., Walsh A., et al. ECCO Position Paper: Harmonization of the Approach to Ulcerative Colitis Histopathology. *J Crohns Colitis* 2020;**14**(11):1503–11. Doi: 10.1093/ecco-jcc/jjaa110.
89. Korelitz BI., Sommers SC. Response to Drug Therapy in Crohn's Disease. *J Clin Gastroenterol* 1984;**6**(2):123–8. Doi: 10.1097/00004836-198404000-00005.
90. D'Inca R., Dal Pont E., Di Leo V., Ferronato A., Fries W., Vettorato MG., et al. Calprotectin and lactoferrin in the assessment of intestinal inflammation and organic disease. *Int J Colorectal Dis* 2007;**22**(4):429–37. Doi: 10.1007/s00384-006-0159-9.
91. Kaiser T., Langhorst J., Wittkowski H., Becker K., Friedrich AW., Rueffer A., et al. Faecal S100A12 as a non-invasive marker distinguishing inflammatory bowel disease from irritable bowel syndrome. *Gut* 2007;**56**(12):1706–13. Doi: 10.1136/gut.2006.113431.

92. Boon GJ. Are faecal markers good indicators of mucosal healing in inflammatory bowel disease? *World J Gastroenterol* 2015;**21**(40):11469. Doi: 10.3748/wjg.v21.i40.11469.
93. Dolinšek J., Rižnik P., Sabath L., Mičetić-Turk D. Fecal calprotectin as a marker of the severity of mucosal inflammation in children with inflammatory bowel disease. *Wien Klin Wochenschr* 2016;**128**(7–8):253–9. Doi: 10.1007/s00508-015-0915-3.
94. Carty E., Nickols C., Feakins RM., Rampton DS. Thromboxane synthase immunohistochemistry in inflammatory bowel disease. *J Clin Pathol* 2002;**55**(5):367–70. Doi: 10.1136/jcp.55.5.367.
95. Vizoso FJ., González LO., Corte MD., Corte MG., Bongera M., Martínez A., et al. Collagenase-3 (MMP-13) expression by inflamed mucosa in inflammatory bowel disease. *Scand J Gastroenterol* 2006;**41**(9):1050–5. Doi: 10.1080/00365520600554667.
96. Sabatino A Di., Saarialho-Kere U., Buckley MG., Gordon JN., Biancheri P., Rovedatti L., et al. Stromelysin-1 and macrophage metalloelastase expression in the intestinal mucosa of Crohn's disease patients treated with infliximab. *Eur J Gastroenterol Hepatol* 2009;**21**(9):1049–55. Doi: 10.1097/MEG.0b013e3283293d0f.
97. de Bruyn M., Arijis I., De Hertogh G., Ferrante M., Van Assche G., Rutgeerts P., et al. Serum Neutrophil Gelatinase B-associated Lipocalin and Matrix Metalloproteinase-9 Complex as a Surrogate Marker for Mucosal Healing in Patients with Crohn's Disease. *J Crohn's Colitis* 2015;**9**(12):1079–87. Doi: 10.1093/ecco-jcc/jjv148.
98. Eder P., Lykowska-Szuber L., Iwanik K., Krela-Kazmierczak I., Stawczyk-Eder K., Majewski P., et al. The influence of anti-TNF therapy on CD31 and VEGF expression in colonic mucosa of Crohn's disease patients in relation to mucosal healing. *Folia Histochem Cytobiol* 2015. Doi: 10.5603/FHC.a2016.0008.
99. Wang J., Ortiz C., Fontenot L., Xie Y., Ho W., Mattai SA., et al. High circulating elafin levels are associated with Crohn's disease-associated intestinal strictures. *PLoS One* 2020;**15**(4):e0231796. Doi: 10.1371/journal.pone.0231796.

Figure Captions

Figure 1. Ileal and colonic biopsies

Accepted Manuscript