



HAL
open science

Gastrointestinal Behcet's-like Disease with Myelodysplastic Neoplasms with Trisomy 8: A French Case Series and Literature Review

Nadege Wesner, Louis Drevon, Alexis Guedon, Jean Baptiste Fraison, Benjamin Terrier, Salim Trad, Jean Emmanuel Kahn, Achille Aouba, Jerome Gillard, Matthieu Ponsoye, et al.

► **To cite this version:**

Nadege Wesner, Louis Drevon, Alexis Guedon, Jean Baptiste Fraison, Benjamin Terrier, et al.. Gastrointestinal Behcet's-like Disease with Myelodysplastic Neoplasms with Trisomy 8: A French Case Series and Literature Review. *Leukemia & lymphoma*, 2019, 60 (7), pp.1782–1788. 10.1080/10428194.2018.1542152 . hal-03704098

HAL Id: hal-03704098

<https://hal.sorbonne-universite.fr/hal-03704098v1>

Submitted on 24 Nov 2022

HAL is a multi-disciplinary open access archive for the deposit and dissemination of scientific research documents, whether they are published or not. The documents may come from teaching and research institutions in France or abroad, or from public or private research centers.

L'archive ouverte pluridisciplinaire **HAL**, est destinée au dépôt et à la diffusion de documents scientifiques de niveau recherche, publiés ou non, émanant des établissements d'enseignement et de recherche français ou étrangers, des laboratoires publics ou privés.

Behcet's disease associated with trisomy 8-positive myelodysplastic syndrome: French retrospective case-series and literature review.

Nadege Wesner^{1,2}, Louis Drevon^{1,2}, Alexis Guedon³, Jean Baptiste Fraison⁴, Benjamin Terrier⁵, Salim Trad⁵, Jean Emmanuel Kahn⁶, Achille Aouba⁷, Jerome Gillard⁸, Matthieu Ponsoye⁵, Thomas Hanslik⁵, Clement Gourguechon⁹, Eric Liozon¹⁰, Kamel Laribi¹¹, Julien Rossignol¹², Olivier Hermine¹², Philippe Seksik¹³, Lionel Adès², Fabrice Carrat³, Pierre Fenaux², Arsene Mekinian¹, Olivier Fain¹. On behalf GFM and MINHEMON (French Network of dysimmune disorders associated to hemopathies)

¹Department of Internal Medicine, Inflammation-Immunopathology-Biotherapy Department (DHU i2B), Assistance Publique - Hôpitaux de Paris, Hôpital Saint-Antoine, 184, rue du Faubourg Saint-Antoine, 75012 Paris, France UPMC University Paris 06, Paris, France

²Sorbonne Universités, INSERM U938, Centre de Recherche Saint-Antoine (CRSA), Paris, France

³Sorbonne Université, INSERM, Institut Pierre Louis d'Epidémiologie et de Santé Publique IPLESP, AP-HP, Hôpital Saint Antoine, F75012 Paris, France

⁴Department of Internal Medicine, Hôpital Sète, France

⁵Department of Internal Medicine, Assistance Publique - Hôpitaux de Paris, Hôpital Ambroise Paré, 9 avenue Charles de Gaulle, 92100 Boulogne Billancourt, France

⁶Department of Internal Medicine, Hôpital Foch, 40 rue Worth, 92150 Suresnes, France

⁷Department of Internal Medicine, CH Caen, Avenue de la côte de nacre, 14033 Caen, France

⁸Department of Rheumatology, CH Lons le Saunier, 55 rue du Docteur Jean Michel 39016 Lons le Saunier, France

⁹Department of Internal Medicine, CHU Amiens-Picardie, Chemin de Longpré, 80080 Amiens, France

¹⁰Department of Internal Medicine, CHU Limoges, 2 Avenue Martin Luther King, 87000 Limoges, France

¹¹Department of Hematology, Centre Hospitalier Le Mans, 72037 Le Mans, France

¹²Department of Hematology, Assistance Publique - Hôpitaux de Paris, Hôpital Necker Enfants Malades, 149 rue de Sèvres, 75015 Paris, France

¹³Department of Hepato-gastroenterology, Assistance Publique - Hôpitaux de Paris, Hôpital Saint-Antoine, 184, rue du Faubourg Saint-Antoine, 75012 Paris, France UPMC University Paris 06, Paris, France

Correspondance: Dr Arsène Mekinian, Service de médecine interne, hôpital Saint Antoine, 184, rue du Faubourg Saint-Antoine, 75012 Paris, France.

Tel: +33 (0) 1 / Fax: +33 (0) 1

E-mail: arsene.mekinian@aphp.fr

Key words: Behcet's disease; trisomy 8 positive myelodysplastic syndrome; outcome; treatment

Short title: Behcet's disease in myelodysplastic syndromes

Abstract word count: NNN Total word count: NNNN

Introduction

Behcet's disease (BD) is a systemic vasculitis characterized by recurrent mouth and genital ulcers, ocular, skin and joints involvements. The central nervous system, gastrointestinal tract and vessels are less frequently affected, but their involvement can lead to life-threatening complications (1). Myelodysplastic syndrome (MDS) is a clonal hematologic disorder, which prognosis is marked by the risk of transformation in myeloid acute leukemia. MDS may be associated with autoimmune and inflammatory manifestations (IADs) (2). We previously raised the possible link between Behcet's like syndrome and trisomy 8 cytogenetic abnormalities, but larger data about clinical phenotype, outcome and treatments are scarce. Case reports of Behcet's disease associated with MDS have been showed from Asian countries, characterized by the presence of particularly frequent intestinal involvement (3). Description of gastrointestinal features and outcome in the Behcet's syndrome related to MDS and the comparison with idiopathic Behcet's syndrome is lacking. Here, we report trisomy 8 positive-MDS/CMML associated with Behcet's disease, describe their features, compare to idiopathic Behcet's disease and to Crohn's disease, and analyse the impact of Behcet's disease on overall survival and acute myeloid leukemia progression.

Patients and methods

Data for patients with trisomy 8-positive MDS/CMML and Behcet's or pseudo-Behcet's syndrome were collected from Groupe français des myélodysplasies (GFM), Société Nationale Française de Médecine Interne (SNFMI) and MINHEMON. To be included, patients had to meet following criteria: (1) MDS or CMML (2016 OMS); (2) isolated or combined trisomy 8 karyotype; (3) Behcet's or pseudo Behcet's disease (according to the international Behcet's criteria) (4) time from MDS and autoimmune/inflammatory disease less than 5 years. The exclusion criteria were MDS secondary to previous immunosuppressive drugs and infectious-, drug- or neoplasm-related immune disorders. Behcet's disease diagnosis was considered when 3 or more criteria were fulfilled. Behcet's like disease was defined by the presence of at least 2 criteria and/or combination of gastrointestinal involvement and oral and/or genital aphthosis and/or thrombosis in the absence of other autoimmune/inflammatory disorders.

The following clinical features were collected at the baseline, during the follow-up and the last visit : non-infectious fever, skin abnormalities, arthritis, ocular manifestations, gastrointestinal features, neurological peripheral or central involvements, venous or arterial

thrombosis. Laboratory data included blood count, C-reactive protein and serum creatinine levels, hepatitis C virus and HIV serologies, immunological data (antineutrophil cytoplasmic and antinuclear antibodies, cryoglobulinemia, complement system) and HLA B51 status, if available. Endoscopical abnormalities were analyzed in the five following anatomical sections : jejunum, ileon, colon, rectum and anus. The presence of histopathological lesions was collected from the digestive biopsies at each segment : vasculitis, ulceration, inflammation, stenosis, bleeding, abscess, necrosis, perforation, fistula and granuloma. Response of the Behcet's disease was considered complete in the case of complete disappearance of all clinical signs, acute-phase reactants and partial with at least 50% improvement of clinical and biological signs.

The control groups included patients with idiopathic Behcet's disease (Cochin Hospital) (n=63), with inflammatory bowel disease (Saint Antoine Hospital) (n=100) and MDS associated to trisomy 8 without any systemic inflammatory or autoimmune features from the "GFM" prospective registry (n=103).

Literature search strategy

Two investigators (NW and AM) searched M via PubMed, Web of Science and the Cochrane Library for English-language articles published up to January 2018 by using the keywords "myelodysplastic syndrome; trisomy 8; chronic lymphocytic leukemia, Behçet's syndrome, vasculitis". All articles with sufficient data were included in the literature review. Among 36 available cases, 28 with sufficient data have been included in this review (4) (5) (6) (7) (8) (9) (10) (11) (12) (13) (14) (15) (16) (17) (18) (19) (20) (21) (22) (23) (24).

Statistical analysis

Data are expressed as medians (interquartile range [IQR]: 25 and 75 percentiles) for quantitative variables and numbers (percentages) for categorical variables. T Student or Mann Whitney tests were used to compare quantitative values and chi square or Fischer exact test for qualitative variables. The overall survival and survival free of progression to acute myeloid leukemia were estimated using Kaplan Meier curves and compared between patients with and without Behcet's disease or according to treatment with the log-rank test. All tests were two-tailed and a $p \leq 0.05$ was considered statistically significant. Statistical analyses involved GraphPad Prism v7.00 for Windows (GraphPad Software, La Jolla, CA USA) and R version 3.4.3 for Windows (R Foundation for Statistical Computing, Vienna Austria) using the survminer package.

Results

Behcet's disease features in trisomy 8-positives MDS

Our cases

Eleven patients with trisomy-8 positive MDS and Behcet's like disease have median age 75 years [65 -87] with male/female sex ratio at 0.8. Four of them (36%) were non-European, all from Sub-Saharan Africa. Two patients fulfilled the complete criteria for Behcet's disease with oral and genital aphthosis with specific skin manifestations (4 points), one presented oral and genital aphthosis with gastrointestinal involvement (3 points) and one oral aphthosis, digestive and specific skin manifestations (2 points) (**Table 1**). The remaining patients suffered from oral aphthosis with venous thrombosis and/or gastrointestinal manifestations. Oral and genital aphthosis were present in 10/11 cases (90%) and 4/11 (30%), respectively, with thrombosis in 1/10 (10%), without any ocular involvement. Gastrointestinal involvement was particularly frequent and present in 8/11 (73%) cases, as dysphagia (n = 7/10; 70%), diarrhea (n = 6/11; 55%), digestive hemorrhage (n = 7/10, 70%) or abdominal pain (n = 7/10, 70%). Median C-reactive protein levels were 38 mg/L [18 – 112].

MDS and Behcet's disease were usually diagnosed at the same time (7/11, 64%), one patient had symptoms of Behcet's disease before the diagnosis of MDS (1/11, 9%) and one after MDS (1/11, 9%). The underlying MDS/CMML subtypes were refractory anemia, unclassified MDS and MDS/myeloproliferative syndrome in one case each (9%), refractory anemia with excess blasts type-1, refractory anemia with excess blasts type-2, multilineage cytopenia dysplasia, CMML in 2 cases each (18%). Specific hematological treatment (first or second line therapy) was started in 9/11 cases (82%), and consisted in azacitidine (n=7), lenalidomide and hydroxycarbamide in one case each. Complete or partial hematological response have been achieved in 5 cases (45%).

In comparison to 63 patients with non-MDS related Behcet's disease, trisomy-8 positive MDS patients were older (75 years vs 48 years; $p = 0.0003$), and had significantly less pseudofolliculitis and ocular impairments (11% vs 62% and 0% vs 52%, respectively; $p = 0.0045$ and 0.0008). Gastrointestinal involvement was significantly more frequent in trisomy 8-positive MDS Behcets-like patients (60% vs 13%; $p = 0.0005$).

Our cases pooled with literature data

Literature review showed 28 cases of trisomy 8-positive MDS with Behcet's diseases, with median age 50 years [30 – 68] and male/female sex ratio 0.4 (**Table 1**). The pooled 39 cases from our cases and the literature case have median age at 59 years [36 – 75] and male/female sex ratio at 0.4. In comparison to 63 non-MDS related Behcet's disease, 39 MDS-related Behcet's disease cases were more frequently non-European (76% vs 29%; $p = 0.0005$), have less frequently pseudofolliculitis (31% vs 62%, $p = 0.05$), central neurological (0% vs 25%; $p = 0.049$) and ocular involvements (3% vs 52%, $p = 0.0001$). Gastrointestinal signs and endoscopic abnormalities were more frequent in MDS trisomy 8-positive Behcet's syndrome than non MDS-related idiopathic Behcet's disease (85% vs 13%, $p = 0.0001$).

MDS trisomy 8- positive Behcet's disease comparison to Crohn's disease patients

In comparison to 100 patients with Crohn's disease, Behcet's disease with trisomy 8-positive MDS ($n = 39$) were significantly older (72 years [53 – 78] vs 36 years [27 – 45]; $p = 0.0002$) (**Table 2**). Trisomy 8-positive MDS Behcet's cases have significantly more frequent oral aphthosis (97% vs 5%, $p < 0.0001$), skin features (50% vs 10%, $p = 0.0005$) and arthralgia's (63% vs 20%, $p = 0.03$). Endoscopic abnormalities in MDS trisomy-8 positive Behcet's patients were less frequent in comparison to Crohn's disease (85% vs 100%, $p = 0.0001$). The gastrointestinal lesions distribution was similar, except less frequent colic lesions in MDS-related Behcets disease (42% vs 55%, $p = 0.03$). Digestive stenosis was more frequent in Crohn disease (26% vs 0%, $p = 0,01$). Sixteen patients (16%) with Crohn disease suffered from digestive perforation, and 4 patients (4%) underwent specific surgery, whereas none in MDS-related Behcet's disease have digestive perforation with 3 surgery interventions.

Trisomy 8-positive MDS Behcet's disease treatment and outcome

Treatments for Behcet's disease have been started in 10/11 cases (91%), and consisted in steroids (9/10, 90%) with median dose 20 mg/day [13 – 48]. Combined immunosuppressive drugs have been used in 2 cases (anakinra and azathioprine). Only 2 patients have long term colchicine drug. Behcet's disease complete/partial response have been shown in 8/10 (80%) cases. Second-line therapy was needed for steroid dependence or relapse in 3 cases: methotrexate, thalidomide and anakinra allowing complete or partial response in all cases. Surgery and/or endoscopic treatment for gastrointestinal Behcet's impairment were need in 3 (27%) patients. In the 28 literature cases, first-line treatment has been initiated in 25/26 (96%) of cases and consisted in steroids (16/25, 64%) alone in 8 cases (38%) and combined with

ciclosporine in 3 cases (19%), salazopyrine in 2 cases (13%), colchicine, infliximab and thalidomide in one case each (7%). Five patients (18%) underwent surgical intervention for digestive perforation, severe hemorrhage and/or stenosis. Complete or partial –response to the first line therapy was noted in 12/19 cases. In four refractory cases treated by TNF α antagonists, 2/4 (50%) have partial/complete response of Behcet’s disease.

The median survival was similar in MDS patients with trisomy 8-positive Behcet’s disease and those without associated Behcet’s disease (= 47 months versus 34 months, log rank test = 0.61) (**Figure 1**). The acute myeloid leukemia-free survival was also similar in MDS patients with and without Behcet’s disease (log rank test= 0.29) (**Figure 2**). As expected, the hematological treatment significantly improved the overall survival (24 months in treated versus 6 months in untreated MDS (log rank < 0,001).

Discussion

Our work describes a cohort of patients with trisomy 8-MDS and associated Behcet’s or Behcet’s-like disease. We show that MDS/CMML associated Behcet’s disease have particular clinical phenotype, mainly represented by frequent gastrointestinal involvement, and less ocular and central neurological impairments. The presence of Behcet’s disease seems to not impair the overall survival and progression to acute myeloid leukemia in MDS/CMML patients. In comparison to Crohn’s disease, the gastrointestinal lesions distribution seems to be similar, but with less frequent digestive complications even in patients which have received less immunosuppressive therapy.

Several cases-reports from Asian groups previously raised the possible association of Behcet’s disease with underlying MDS/CMML, but no data compared the features with idiopathic Behcet’s disease. We show that MDS-related Behcet’s disease have rarely neurological and ocular involvement, whereas gastrointestinal involvement seems to be one of the major characteristics of these patients as compared to non-MDS Behcet’s disease. Any part of the digestive tract can be involved, from mouth to anus like in Crohn’s disease. Ileocaecal localization was the most represented (79%), with various non-specific histological features: ulcerations in 29/35 (83%), inflammation in 21/31 (68%) and vasculitis in 5/28 (18%) of patients. Granuloma is present in the same proportion in trisomy-8 MDS associated Behcet’s disease and Crohn’s disease. While diagnosis of Crohn’s disease is based on endoscopic and histological features, there is no specific features to distinguish for the gastrointestinal involvement related to the Behcet’s disease. Even the difference with Crohn

disease could be difficult to assess in some our cases, the presence of specific skin features and high prevalence of oral aphthosis could argue for the Behcet's disease in our patients. Similarly, even the gastrointestinal lesions distribution seems to be similar, the more frequent rate of digestive complications seems to argue for Behcet's disease rather than MDS-related Crohn's disease even though MDS-related patients received less immunosuppressive therapy.

We have previously shown the particular clinical phenotype-genotype association of patients with Behcet's disease and MDS/CMML. One could hypothesize that several genes could be over-expressed in the presence of trisomy 8. Defensin are important molecules in immune activation at the epithelial surfaces. In patients with constitutional trisomy 8 and Behcet's disease, increased gene copy numbers of the variable-number neutrophil defensin genes DEFA1A3 have been shown (25). Other reports suggested that trisomy 8 may lead to the development of intestinal ulcers by production of pro-inflammatory cytokines, like TNF- α , IL-1 and IL-6 (26) or by the production of reactive oxygen species.

Conflicting data are reported in concern the impact on the overall survival and the progression to acute myeloid leukemia in the presence of IADs. Previously, a little study raised the possible impact of vasculitis on the overall survival, but with mainly few cases of cryoglobulinemic vasculitis (27). Considering various subtypes of IADs, we previously show no difference in the overall survival in comparison to MDS/CMML without IADs. Similarly, in our case series of Behcet's disease, the overall survival and progression to acute leukemia remained similar in the presence or not of Behcet's disease, and only the response to hematological therapy reflect the survival increase.

In conclusion, we show that MDS/CMML can be associated with particular phenotype of Behcet's disease, with predominant gastrointestinal involvement which could be in some cases difficult to distinguish from Crohn's disease. This subset seems to be particularly associated with trisomy 8 karyotype, and further studies could be interesting to determine the increased gene expressing related to the development of this particular immune disorder.

Table 1. Characteristics of patients with Behçet's disease with and without trisomy 8- myelodysplastic syndrome/chronic myelomonocytic leukemia (our cases and pooled with literature data)

Characteristics	MDS/CMML related Behçet's disease N = 11	MDS/CMML related Behçet's disease N=39 (our cases and literature review)	Non –MDS related Behçet's disease N = 63
Age, years (median [IQR])	75 (65 – 87)*	59 (36 – 75)	48 (39 – 57)
Females (n ;%)	6/11 (55%)	24/39 (62%)	30/63 (47%)
Non-European (n ;%)	4/11 (36%)	29/38 (76%)**	18/63 (29%)
Age at diagnosis	72 (53 – 78)*	-	33 (27 – 40)
Oral aphtosis (n ;%)	9/10 (90%)	35/36 (97%)	62/63 (98%)
Genital aphtosis (n ;%)	3/10 (30%)*	21/32 (66%)	45/63 (71%)
Erythema nodosa (n ;%)	1/9 (11%)	7/27 (26%)	8/63 (13%)
Pseudofolliculitis (n ;%)	1/9 (11%)*	8/26 (31%)**	39/63 (62%)
Patergy test (n ;%)	0/4	9/18 (50%)**	8/63 (13%)
Arthralgia (n ;%)	5/10 (50%)	12/19 (63%)	46/63 (73%)
Central neurological impairment	0	0/12 (0%)**	16/63 (25%)
Peripheral neurological impairment (n ;%)	0	0/12 (0%)**	16/63 (25%)
Uveitis (n ;%)	0*	1/32 (3%)**	33/63 (52%)
Arterial thrombosis (n ;%)	0	0/10 (0%)	7/63 (11%)
Superficial venous thrombosis	0	0/14 (0%)	6/63 (9.5%)
Deep venous thrombosis (n ;%)	1/10 (10%)	4/14 (29%)	9/63 (14%)
Endoscopic abnormalities (n ;%)	6/10 (60%)*	29/34 (85%)**	8/63 (13%)
Death (n ;%)	7/10 (70%)	17/20 (85%)	-

*p<0.05 Our cases in comparison to non-MDS Behçet's disease

**p<0.05 Our cases and literature review pooled data to non-MDS Behçet's disease

Table 2. Characteristics of patients with Behcet's disease and trisomy 8-myelodysplastic syndrome/chronic myelomonocytic leukemia (MDS/CMML) comparing to patients with Crohn's disease

Characteristics	Behcet's disease and MDS/CMML N=11	MDS/CMML related Behcet's N=39 (our cases and literature review)	Crohn's disease N=100
Age, years (median [IQR])	75 (65 – 87)	59 (36 – 75)	36 (27 - 45)
Females (n ;%)	6/11 (55%)	24/39 (62%)	68/100 (68%)
Non-European (n ;%)	4/11 (36%)*	29/38 (76%)	69/94 (73%)
Age at diagnosis (median [IQR])	72 (53 – 78)*	-	36 (27 – 45)
Skin manifestations (n ;%)	3/10 (30%)	15/30 (50%)**	10/100 (10%)
Arthralgia (n ;%)	5/10 (50%)*	12/19 (63%)**	20/100 (20%)
Uveitis (n ;%)	0	1/32 (3%)	3/100 (3%)
Oral aphtosis (n ;%)	9/10 (90%)*	35/36 (97%)**	5/100 (5%)
Endoscopic abnormalities (n ;%)	6/10 (60%)*	29/34 (85%)**	100/100 (100%)
Jejunal lesions (n ;%)	0	0	4/100 (4%)
Ileal lesions (n ;%)	5/10 (50%)	26/33 (79%)	67/100 (67%)
Colic lesions (n ;%)	4/10 (40%)	13/31 (42%)**	55/100 (55%)
Sigmoid/rectum lesions (n ;%)	3/10 (30%)	8/28 (29%)	32/100 (32%)
Anus lesions (n ;%)	5/10 (50%)*	6/29 (21%)	17/100 (17%)
Stenosis (n ;%)	0*	0**	26/100 (26%)
Perforation (n ;%)	0	2/20 (10%)	16/100 (16%)
Granuloma (n ;%)	1/8 (13%)	2/11 (18%)	19/100 (19%)
Death (n ;%)	7/10 (70%)*	17/20 (85%)**	0/100 (0%)

*p<0.05 our cases in comparison to patients with Crohn's disease

**p<0.05 our cases and literature review pooled data to Crohn's disease

Figures

Figure 1. Overall survival in trisomy 8 MDS/CMML patients with and without Behçet's disease.

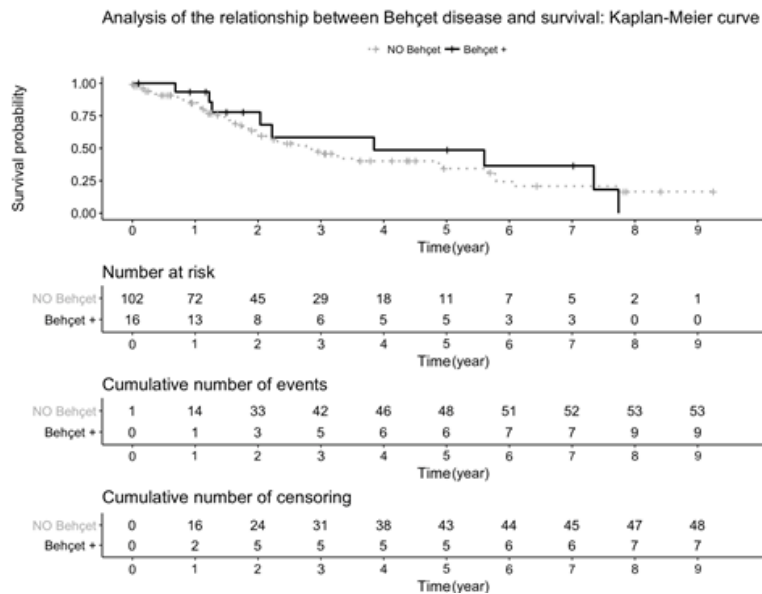
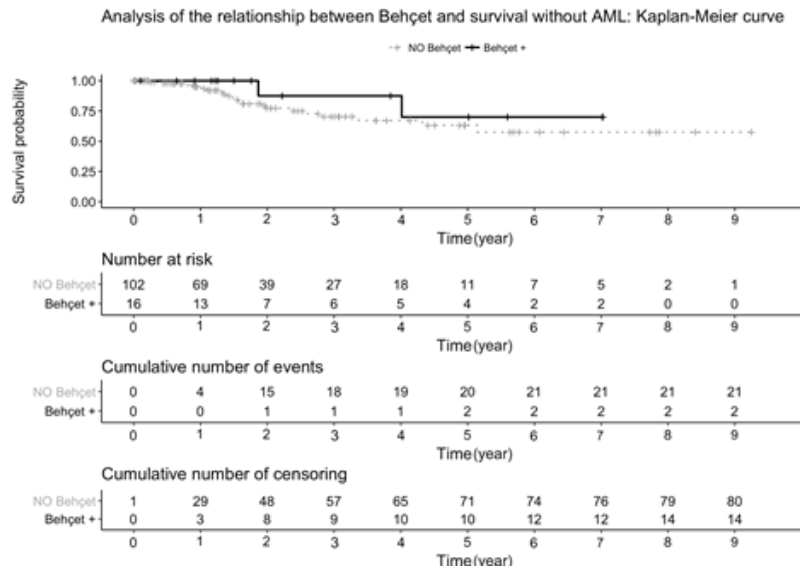


Figure 2. Progression to acute myeloid leukemia in trisomy 8 MDS/CMML patients with and without Behçet's disease.



References

1. International Team for the Revision of the International Criteria for Behçet's Disease (ITR-ICBD). The International Criteria for Behçet's Disease (ICBD): a collaborative study of 27 countries on the sensitivity and specificity of the new criteria. *J Eur Acad Dermatol Venereol JEADV*. 2014 Mar;28(3):338–47.
2. Mekinian A, Grignano E, Braun T, Decaux O, Liozon E, Costedoat-Chalumeau N, et al. Systemic inflammatory and autoimmune manifestations associated with myelodysplastic syndromes and chronic myelomonocytic leukaemia: a French multicentre retrospective study. *Rheumatol Oxf Engl*. 2016 Feb;55(2):291–300.
3. Ohno E, Ohtsuka E, Watanabe K, Kohno T, Takeoka K, Saburi Y, et al. Behçet's disease associated with myelodysplastic syndromes. A case report and a review of the literature. *Cancer*. 1997 Jan 15;79(2):262–8.
4. Kawano S, Hiraoka S, Okada H, Akita M, Iwamuro M, Yamamoto K. Clinical Features of Intestinal Behçet's Disease Associated with Myelodysplastic Syndrome and Trisomy 8. *Acta Med Okayama*. 2015;69(6):365–9.
5. Takizawa Y, Setoguchi K, Kobayashi T, Kuwata G. Severe gastrointestinal disease development coinciding with the progression of myelodysplastic syndrome after a long-term mild course of Behçet's disease. *Int J Rheum Dis*. 2017 Nov;20(11):1856–9.
6. Della Rossa A, Tavoni A, Tognetti A, Testi C, Bombardieri S. Behçet's disease with gastrointestinal involvement associated with myelodysplasia in a patient with congenital panhypopituitarism. *Clin Rheumatol*. 1998;17(6):515–7.
7. Chen Y, Shen Y, Ma H-F, Cai J-F, Hua Y-Q, Zou J, et al. Infliximab associated with life-threatening lung infection in a patient with Behçet disease with intestinal and hematopoietic system involvement: A case report. *Medicine (Baltimore)*. 2017 Dec;96(50):e9202.
8. Yano K, Eguchi K, Migita K, Takashima H, Tamura M, Izumino K, et al. Behçet's disease complicated with myelodysplastic syndrome: a report of two cases and review of the literature. *Clin Rheumatol*. 1996 Jan;15(1):91–3.
9. Endo M, Sekikawa A, Tsumura T, Maruo T, Osaki Y. A Case of Myelodysplastic Syndrome with Intestinal Behçet's Disease-Like Symptoms Treated by Prednisolone and Azacitidine. *Am J Case Rep*. 2015 Nov 21;16:827–31.
10. Kimura M, Tsuji Y, Iwai M, Inagaki M, Madian A, Yoshino T, et al. Usefulness of Adalimumab for Treating a Case of Intestinal Behçet's Disease With Trisomy 8 Myelodysplastic Syndrome. *Intest Res*. 2015 Apr;13(2):166–9.
11. Mantzourani MG, Chantziara K, Thanopoulou I, Variami H, Vaiopoulos G, Pangalis GA. Coexistence of Behçet's disease and chronic myelomonocyte leukemia with trisomy 8: a case report and review of the literature. *Clin Exp Rheumatol*. 2009 Apr;27(2 Suppl 53):S85-87.

12. Ohno E, Ohtsuka E, Watanabe K, Kohno T, Takeoka K, Saburi Y, et al. Behçet's disease associated with myelodysplastic syndromes. A case report and a review of the literature. *Cancer*. 1997 Jan 15;79(2):262–8.
13. Oh EJ, Yoon JS, Park YJ, Cho CS, Kim BK. Behçet's disease associated with myelodysplastic syndrome: a case report. *J Korean Med Sci*. 1999 Dec;14(6):685–7.
14. Fine LA, Hoffman LD, Hoffman MD. Aphthous ulcerations associated with trisomy 8-positive myelodysplastic syndrome. *J Am Acad Dermatol*. 2007 Aug;57(2 Suppl):S38-41.
15. Kawabata H, Sawaki T, Kawanami T, Shimoyama K, Karasawa H, Fukushima T, et al. Myelodysplastic syndrome complicated with inflammatory intestinal ulcers: significance of trisomy 8. *Intern Med Tokyo Jpn*. 2006;45(22):1309–14.
16. Thachil JV, Salim R, Field A, Moots R, Bolton-Maggs P. Myelodysplastic syndrome with trisomy 8 associated with Behçet syndrome: an immunologic link to a karyotypic abnormality. *Pediatr Blood Cancer*. 2008 Mar;50(3):649–51.
17. Koguchi-Yoshioka H, Inokuma D, Kanda M, Kondo M, Kikuchi K, Shimizu S. Behçet's disease-like symptoms associated with myelodysplastic syndrome with trisomy 8: a case report and review of the literature. *Acta Derm Venereol*. 2014 May;94(3):355–6.
18. Toyonaga T, Nakase H, Matsuura M, Minami N, Yamada S, Honzawa Y, et al. Refractoriness of intestinal Behçet's disease with myelodysplastic syndrome involving trisomy 8 to medical therapies - our case experience and review of the literature. *Digestion*. 2013;88(4):217–21.
19. Tanaka H, Shimizu N, Tougasaki E, Kawajiri C, Hashimoto S, Takeda Y, et al. Successful treatment by azacitidine therapy of intestinal Behçet's disease associated with myelodysplastic syndrome. *Int J Hematol*. 2013 Apr;97(4):520–4.
20. Chen H-C, Chiu Y-M. Large-vessel thrombosis in intestinal Behçet's disease complicated with myelodysplastic syndrome and trisomy 8. *World J Gastroenterol*. 2012 Mar 14;18(10):1137–40.
21. Shigemura T, Agematsu K, Yamazaki T, Sakashita K, Nakayama Y, Higuchi Y, et al. A case of Behçet's disease associated with myelodysplastic syndrome involving trisomy 8 and a gain-of-function mutation in SHP-2. *Rheumatol Oxf Engl*. 2011 Jul;50(7):1342–4.
22. Lin Y-C, Liang T-H, Chang H-N, Lin J-S, Lin H-Y. Behçet disease associated with myelodysplastic syndrome. *J Clin Rheumatol Pract Rep Rheum Musculoskelet Dis*. 2008 Jun;14(3):169–74.
23. Hasegawa H, Iwamasa K, Hatta N, Fujita S. Behçet's disease associated with myelodysplastic syndrome with elevated levels of inflammatory cytokines. *Mod Rheumatol*. 2003 Dec;13(4):350–5.
24. Adachi Y, Tsutsumi A, Murata H, Takemura H, Chino Y, Takahashi R, et al. Behçet's disease accompanied by myelodysplastic syndrome with trisomy 8: two case reports and a review of 15 Japanese cases. *Mod Rheumatol*. 2003 Mar;13(1):90–4.

25. Becker K, Fitzgerald O, Green AJ, Keogan M, Newbury-Ecob R, Greenhalgh L, et al. Constitutional trisomy 8 and Behçet syndrome. *Am J Med Genet A*. 2009 May;149A(5):982–6.
26. Kimura S, Kuroda J, Akaogi T, Hayashi H, Kobayashi Y, Kondo M. Trisomy 8 involved in myelodysplastic syndromes as a risk factor for intestinal ulcers and thrombosis-- Behçet's syndrome. *Leuk Lymphoma*. 2001 Jun;42(1–2):115–21.
27. de Hollanda A, Beucher A, Henrion D, Ghali A, Lavigne C, Lévesque H, et al. Systemic and immune manifestations in myelodysplasia: a multicenter retrospective study. *Arthritis Care Res*. 2011 Aug;63(8):1188–94.