



**HAL**  
open science

# Reversible Tumor Progression Induced by a Dexamethasone Course for Severe COVID-19 during Immune Checkpoint Inhibitor Treatment

Paul Gougis, Baptiste Abbar, Julie Benzimra, Aurore Vozy, Jean-Philippe Spano, Luca Campedel

► **To cite this version:**

Paul Gougis, Baptiste Abbar, Julie Benzimra, Aurore Vozy, Jean-Philippe Spano, et al.. Reversible Tumor Progression Induced by a Dexamethasone Course for Severe COVID-19 during Immune Checkpoint Inhibitor Treatment. *Diagnostics*, 2022, 12 (8), pp.1933. 10.3390/diagnostics12081933. hal-03888712

**HAL Id: hal-03888712**

**<https://hal.sorbonne-universite.fr/hal-03888712>**

Submitted on 8 Dec 2022

**HAL** is a multi-disciplinary open access archive for the deposit and dissemination of scientific research documents, whether they are published or not. The documents may come from teaching and research institutions in France or abroad, or from public or private research centers.


L'archive ouverte pluridisciplinaire **HAL**, est destinée au dépôt et à la diffusion de documents scientifiques de niveau recherche, publiés ou non, émanant des établissements d'enseignement et de recherche français ou étrangers, des laboratoires publics ou privés.



Distributed under a Creative Commons Attribution 4.0 International License

## Interesting Images

# Reversible Tumor Progression Induced by a Dexamethasone Course for Severe COVID-19 during Immune Checkpoint Inhibitor Treatment

Paul Gougis <sup>1,2,†</sup>, Baptiste Abbar <sup>1,†</sup>, Julie Benzimra <sup>3</sup>, Aurore Vozy <sup>1</sup>, Jean-Philippe Spano <sup>1</sup>  
and Luca Campedel <sup>4,\*</sup> 

<sup>1</sup> Sorbonne Université, INSERM, Institut Pierre Louis d'Epidémiologie et de Santé Publique (iPLESP), Assistance Publique-Hôpitaux de Paris (AP-HP), Pitié Salpêtrière Hospital, Department of Medical Oncology, Institut Universitaire de Cancérologie, CLIP<sup>2</sup> Galilée, 75013 Paris, France

<sup>2</sup> Residual Tumor & Response to Treatment Laboratory, RT2Lab, INSERM, U932 Immunity and Cancer, Institut Curie, 75005 Paris, France

<sup>3</sup> Sorbonne Université, Department of Radiology, Assistance Publique-Hôpitaux de Paris (AP-HP), Pitié Salpêtrière Hospital, 75004 Paris, France

<sup>4</sup> Service d'Oncologie Médicale, CHU Gabriel Montpied, Université Clermont Auvergne, 63000 Clermont-Ferrand, France

\* Correspondence: [lcampedel@chu-clermontferrand.fr](mailto:lcampedel@chu-clermontferrand.fr); Tel.: +33-473751635; Fax: +33-473751636

† These authors contributed equally to this work.



**Citation:** Gougis, P.; Abbar, B.; Benzimra, J.; Vozy, A.; Spano, J.-P.; Campedel, L. Reversible Tumor Progression Induced by a Dexamethasone Course for Severe COVID-19 during Immune Checkpoint Inhibitor Treatment. *Diagnostics* **2022**, *12*, 1933. <https://doi.org/10.3390/diagnostics12081933>

Academic Editors: Xavier Bosch and Javier Marco-Hernández

Received: 28 June 2022

Accepted: 7 August 2022

Published: 10 August 2022

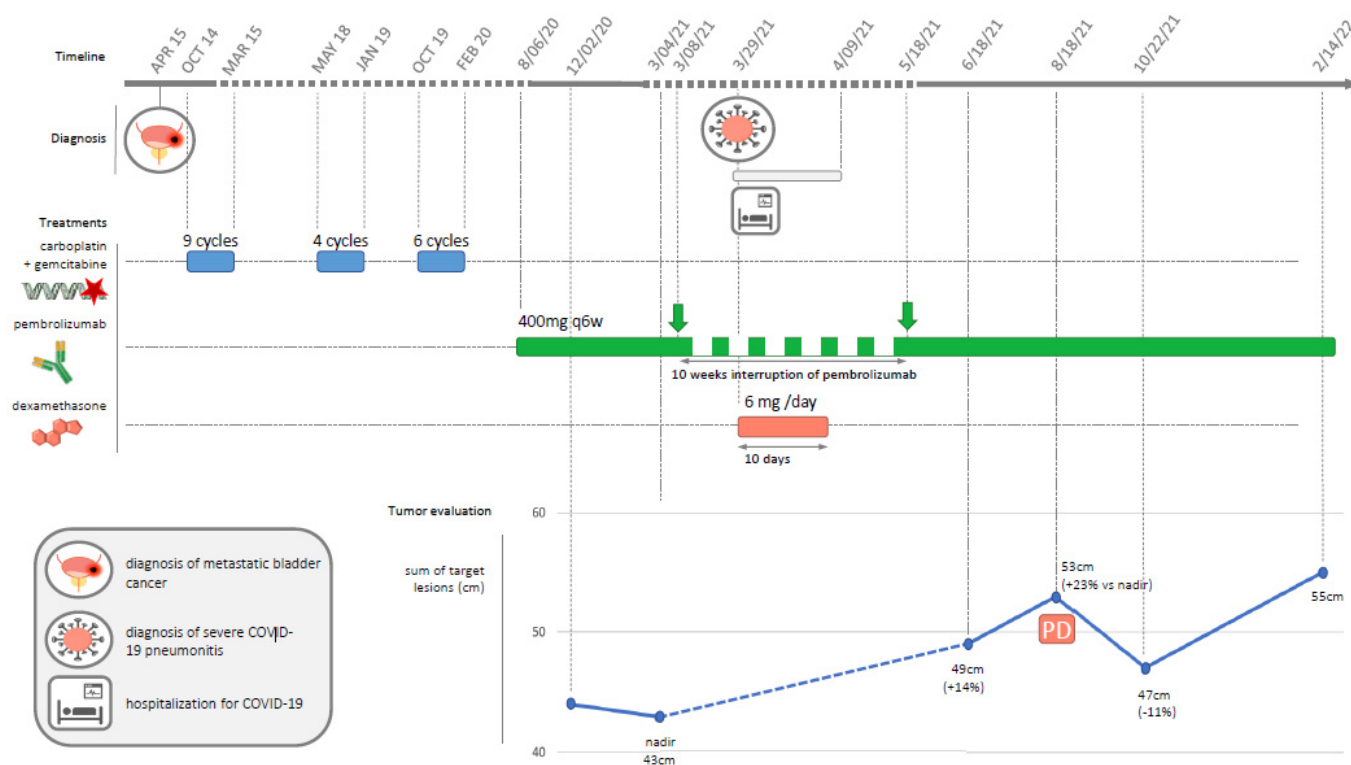
**Publisher's Note:** MDPI stays neutral with regard to jurisdictional claims in published maps and institutional affiliations.

**Abstract:** Immunotherapies and immune checkpoint inhibitors (ICI) represent the latest revolution in oncology. Several studies have reported an association between the use of corticosteroids and poorer outcomes for patients treated with ICIs. However, it has been never established whether corticoid-induced tumor progression under ICI treatment could be reversible. We report herein transient tumor progression induced by dexamethasone for a patient treated with pembrolizumab for metastatic bladder cancer. An 82-year-old man was treated with pembrolizumab as a second-line treatment for metastatic urothelial carcinoma with stable disease for 8 months as the best tumoral response. He experienced severe coronavirus disease 2019 (COVID-19) infection and was treated with high-dose dexamethasone for ten days according to the RECOVERY protocol. Following this episode, radiological CT-scan evaluation showed tumor progression. Pembrolizumab was maintained, and subsequent radiological evaluation showed tumor shrinkage. This case highlights that the antagonistic effect of glucocorticoids with ICI efficacy is transient and can be reverted when corticoids are withdrawn. Clinicians should be aware that tumor progression in the context of the intercurrent use of systemic corticosteroids can be temporary and should be interpreted with caution, and ICI continuation could be considered for some patients. **Insights:** The antagonistic effect of glucocorticoids with ICI efficacy is transient and can be reverted when corticoids are withdrawn. Tumor progression in the context of the intercurrent use of systemic corticosteroids can be temporary and should be interpreted with caution, and ICI continuation could be considered for some patients.

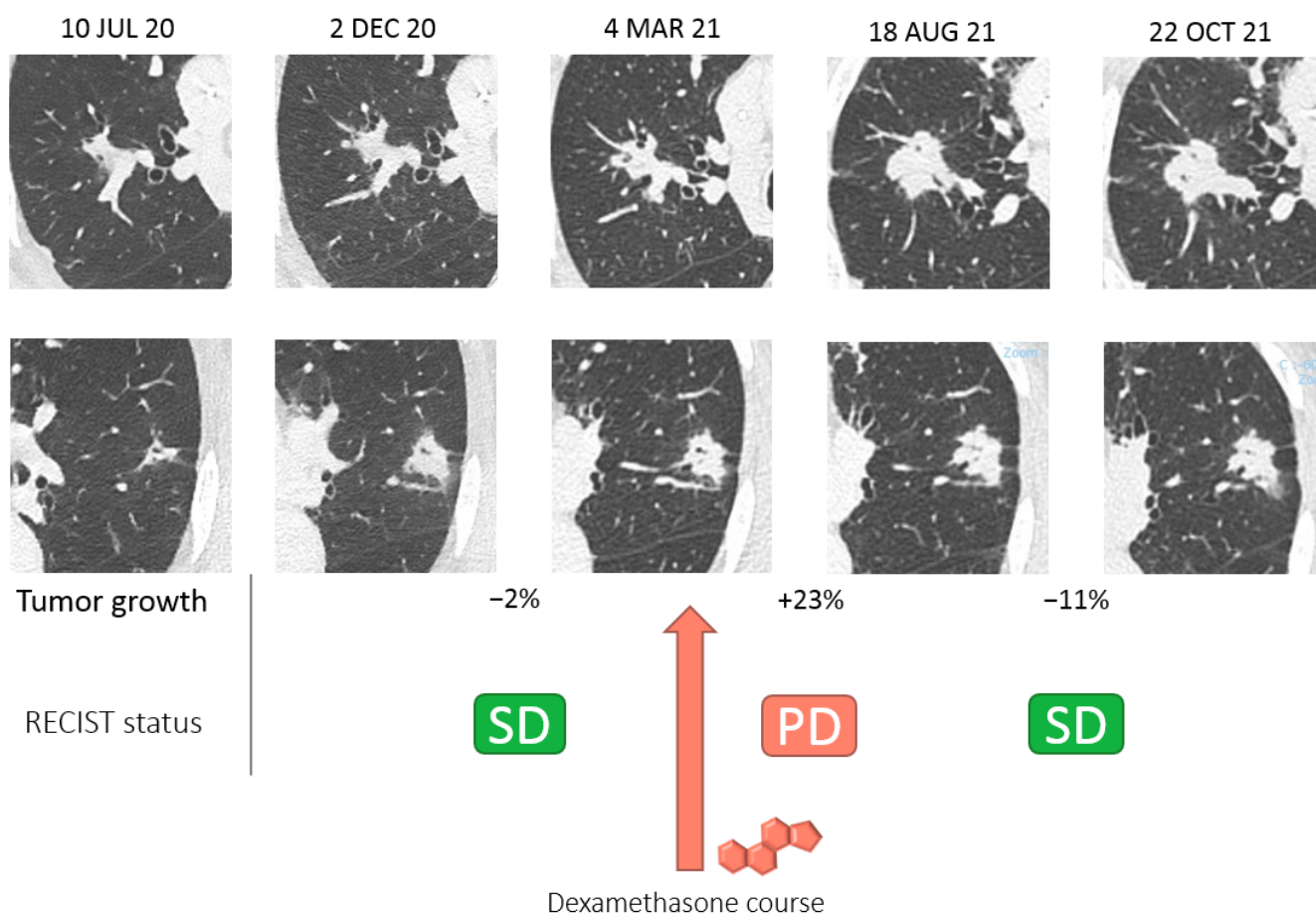
**Keywords:** immunotherapy; immune checkpoint inhibitors; COVID-19; pseudoprogression; corticosteroids



**Copyright:** © 2022 by the authors. Licensee MDPI, Basel, Switzerland. This article is an open access article distributed under the terms and conditions of the Creative Commons Attribution (CC BY) license (<https://creativecommons.org/licenses/by/4.0/>).



**Figure 1.** Timeline of patient history depicting cancer diagnosis, cancer treatments, and COVID-19 diagnosis and treatment. In April 2014, a 75-year-old man with a history of smoking (20 pack-years) presented with hematuria, which revealed an FGFR wild-type urothelial bladder carcinoma with lung metastases. The patient was also treated for hypertension and diabetes. He was treated with a combination of gemcitabine–carboplatin as a first-line treatment between October 2014 and March 2015 (n = 9 cycles). After a partial response (RECIST 1.1 criteria) was observed on CT-scan evaluation, he was monitored without treatment. He relapsed in May 2018 and was rechallenged with gemcitabine–carboplatin (n = 4 cycles) until January 2019, when he achieved another partial response. For the third relapse in October 2019, he was treated with six more cycles of gemcitabine–carboplatin until February 2020, with stable disease as the best response. Tumor progression was diagnosed in July 2020, and pembrolizumab at the dose of 400 mg (intravenous every 6 weeks) was initiated on 6 August 2020, according to local guidelines. The patient had stable disease as the initial best response. After eight months of stable disease with pembrolizumab, the patient experienced severe coronavirus disease 2019 (COVID-19) infection and was admitted to the intensive care unit on 29 March 2021. He was treated with oxygen (up to 12 L/min without noninvasive ventilation) and 6 mg of dexamethasone per day for ten days according to the RECOVERY protocol [1]. The clinical evolution was favorable, with oxygen withdrawal and hospital discharge on 9 April 2021. Pembrolizumab was resumed on 18 May 2021 after an interruption of ten weeks. Radiological CT-scan evaluation on 18 August 2021 showed RECIST tumor progression (Figure) with a target lesion sum of 53 mm compared to 43 mm (+23%) on nadir (4 March 2021). Pembrolizumab injections were maintained, and the following radiological evaluation on 22 October 2021 showed a decrease of 11% (sum of target lesion = 47 mm vs. 53 mm, stable disease according to RECIST criteria) compared to August 2021 (Figure).



**Figure 2.** Timeline of TDM scan evaluation of the two target lesions according to RECIST 1.1 criteria. Glucocorticoids (GC) are among the most potent anti-inflammatory and immunosuppressive agents. In severe COVID-19 infection, the host immune response is thought to play a key role in the pathophysiology of organ failure, and the use of dexamethasone to mitigate inflammatory organs has been shown to result in lower mortality [2,3]. Immune checkpoint inhibitors (ICI) such as pembrolizumab have been successfully developed for the treatment of various cancers and have been approved for several indications, including for bladder cancer. They potently restore exhausted T-cell functions and are activated at tumor contact [4]. Corticoids have multiple mechanisms and inhibit several lymphocyte activities, such as T cell differentiation, activation, and migration [5]. Therefore, there is a strong rationale for pharmacological antagonism between corticoids and ICI. GCs could impair the antitumoral activity of ICI, and this negative pharmacological interaction also explains their efficacy as a treatment for the immune-related adverse events induced by ICI [6]. Several retrospective studies have reported a negative impact of the use of corticoids on the outcomes of patients treated with ICI [7–10], and this association was further confirmed in a meta-analysis of 4045 cancer patients [11]. Based on these findings, the EMA recommends avoiding the use of systemic corticosteroids before starting pembrolizumab [12]. However, despite efforts made to limit confusion biases in these studies, the causality assessment of the negative impact of corticoids remains limited. In this case report, we demonstrate for the first time that the antitumoral effect of pembrolizumab can be temporarily antagonized by a strong course of GCs but that the antitumoral effect is later recovered and translated into tumor shrinkage and control. Of note, pembrolizumab cessation for 4 weeks compared to the classic scheme (10 weeks instead of 6 weeks) could not explain tumor progression when taking the long-lasting effects of a pembrolizumab concentration several times above the inhibitory concentration 50 and treatment half-life (3 weeks) into consideration [4]. Dexamethasone has a short half-life of fewer than three days, and no active concentration remains after two weeks.

In our case, however, we observed tumor progression between 40 and 100 days after dexamethasone cessation followed by tumor decrease. The direct antagonistic effect of GCs could not explain such a chronology. However, GCs have a pleiotropic impact on different T cell populations and precursors and can regulate T cell trafficking, alter TCR repertoire, or modify thymic homeostasis, which could explain the long-lasting and remnant antagonizing effects despite a short half-life [13]. Pseudoprogession could be an alternative explanation for transient tumor progression, and is not an exceptional event with urothelial cancer, with 1.5% to 17% of cases being treated with PD-1 inhibitors [14]. However, pseudoprogession arises exceptionally after three months (late pseudoprogession), and no cases have been reported after 6 months of treatment for urothelial cancer or other tumor types [15,16]. Classic pseudoprogession seems unlikely in this case, with one year of treatment before transient progession was observed. However, we could not discard the late pseudoprogession induced by GC cessation followed by transient inflammation that led to tumor progession followed by a decrease in tumor size. Consequently, tumor progession in the context of the intercurrent use of systemic corticosteroids should be interpreted with caution due to potential pharmacological antagonism, and ICI continuation should be considered for some patients. Tumor evaluation was carried out according to RECIST 1.1 criteria. COVID-19: coronavirus disease 2019; PD: progressive disease (RECIST 1.1 criteria). The tumor progessed after a course of dexamethasone and later experienced tumor shrinkage that did not meet partial response according to RECIST 1.1 criteria. PD: progressive disease; SD stable disease.

**Author Contributions:** Conceptualization, P.G., B.A. and L.C.; investigation, P.G., B.A., J.B. and L.C.; resources, P.G., B.A. and L.C.; data curation, P.G., B.A., J.B. and L.C.; writing—original draft preparation, P.G., B.A. and L.C.; writing—review and editing, P.G., B.A., J.B., A.V., J.-P.S. and L.C.; supervision, P.G., B.A., J.B., A.V., J.-P.S. and L.C.; project administration, P.G., B.A. and L.C. All authors have read and agreed to the published version of the manuscript.

**Funding:** This research received no external funding.

**Institutional Review Board Statement:** Not applicable.

**Informed Consent Statement:** Written informed consent has been obtained from the patient to publish this paper.

**Data Availability Statement:** Not applicable.

**Conflicts of Interest:** The authors declare no conflict of interest.

## References

1. The RECOVERY Collaborative Group. Dexamethasone in Hospitalized Patients with COVID-19. *N. Engl. J. Med.* **2021**, *384*, 693–704. [[CrossRef](#)] [[PubMed](#)]
2. Giles, A.J.; Hutchinson, M.-K.N.D.; Sonnemann, H.M.; Jung, J.; Fecci, P.E.; Ratnam, N.M.; Zhang, W.; Song, H.; Bailey, R.; Davis, D.; et al. Dexamethasone-Induced Immunosuppression: Mechanisms and Implications for Immunotherapy. *J. Immunother. Cancer* **2018**, *6*, 51. [[CrossRef](#)] [[PubMed](#)]
3. Alfarouk, K.O.; AlHoufie, S.T.S.; Ahmed, S.B.M.; Shabana, M.; Ahmed, A.; Alqahtani, S.S.; Alqahtani, A.S.; Alqahtani, A.M.; Ramadan, A.M.; Ahmed, M.E.; et al. Pathogenesis and Management of COVID-19. *J. Xenobiot.* **2021**, *11*, 77–93. [[CrossRef](#)] [[PubMed](#)]
4. Geraud, A.; Gougis, P.; Vozy, A.; Anquetil, C.; Allenbach, Y.; Romano, E.; Funck-Brentano, E.; Moslehi, J.J.; Johnson, D.B.; Salem, J.-E. Clinical Pharmacology and Interplay of Immune Checkpoint Agents: A Yin-Yang Balance. *Annu. Rev. Pharmacol. Toxicol.* **2021**, *61*, 85–112. [[CrossRef](#)] [[PubMed](#)]
5. Libert, C.; Dejager, L. How Steroids Steer T Cells. *Cell Rep.* **2014**, *7*, 938–939. [[CrossRef](#)] [[PubMed](#)]
6. Brahmer, J.R.; Lacchetti, C.; Schneider, B.J.; Atkins, M.B.; Brassil, K.J.; Caterino, J.M.; Chau, I.; Ernstoff, M.S.; Gardner, J.M.; Ginex, P.; et al. Management of Immune-Related Adverse Events in Patients Treated With Immune Checkpoint Inhibitor Therapy: American Society of Clinical Oncology Clinical Practice Guideline. *J. Clin. Oncol.* **2018**, *36*, 1714–1768. [[CrossRef](#)] [[PubMed](#)]
7. Scott, S.C.; Pennell, N.A. Early Use of Systemic Corticosteroids in Patients with Advanced NSCLC Treated with Nivolumab. *J. Thorac. Oncol.* **2018**, *13*, 1771–1775. [[CrossRef](#)] [[PubMed](#)]
8. Arbour, K.C.; Mezquita, L.; Long, N.; Rizvi, H.; Auclin, E.; Ni, A.; Martínez-Bernal, G.; Ferrara, R.; Lai, W.V.; Hendriks, L.E.L.; et al. Impact of Baseline Steroids on Efficacy of Programmed Cell Death-1 and Programmed Death-Ligand 1 Blockade in Patients with Non-Small-Cell Lung Cancer. *JCO* **2018**, *36*, 2872–2878. [[CrossRef](#)] [[PubMed](#)]

9. De Giglio, A.; Mezquita, L.; Auclin, E.; Blanc-Durand, F.; Riudavets, M.; Caramella, C.; Martinez, G.; Benitez, J.C.; Martín-Romano, P.; El-Amarti, L.; et al. Impact of Intercurrent Introduction of Steroids on Clinical Outcomes in Advanced Non-Small-Cell Lung Cancer (NSCLC) Patients under Immune-Checkpoint Inhibitors (ICI). *Cancers* **2020**, *12*, 2827. [[CrossRef](#)] [[PubMed](#)]
10. Buti, S.; Bersanelli, M.; Perrone, F.; Tiseo, M.; Tucci, M.; Adamo, V.; Stucci, L.S.; Russo, A.; Tanda, E.T.; Spagnolo, F.; et al. Effect of Concomitant Medications with Immune-Modulatory Properties on the Outcomes of Patients with Advanced Cancer Treated with Immune Checkpoint Inhibitors: Development and Validation of a Novel Prognostic Index. *Eur. J. Cancer* **2021**, *142*, 18–28. [[CrossRef](#)] [[PubMed](#)]
11. Petrelli, F.; Signorelli, D.; Ghidini, M.; Ghidini, A.; Pizzutilo, E.G.; Ruggieri, L.; Cabiddu, M.; Borgonovo, K.; Dognini, G.; Brighenti, M.; et al. Association of Steroids Use with Survival in Patients Treated with Immune Checkpoint Inhibitors: A Systematic Review and Meta-Analysis. *Cancers* **2020**, *12*, 546. [[CrossRef](#)] [[PubMed](#)]
12. EMA Keytruda—European Public Assessment Report. Available online: <https://www.ema.europa.eu/en/medicines/human/EPAR/keytruda> (accessed on 14 December 2021).
13. Taves, M.D.; Ashwell, J.D. Glucocorticoids in T Cell Development, Differentiation and Function. *Nat. Rev. Immunol.* **2021**, *21*, 233–243. [[CrossRef](#)] [[PubMed](#)]
14. Soria, F.; Beleni, A.I.; D’Andrea, D.; Resch, I.; Gust, K.M.; Gontero, P.; Shariat, S.F. Pseudoprogression and Hyperprogression during Immune Checkpoint Inhibitor Therapy for Urothelial and Kidney Cancer. *World J. Urol.* **2018**, *36*, 1703–1709. [[CrossRef](#)] [[PubMed](#)]
15. Kurra, V.; Sullivan, R.J.; Gainor, J.F.; Hodi, F.S.; Gandhi, L.; Sadow, C.A.; Harris, G.J.; Flaherty, K.; Lee, S. Pseudoprogression in Cancer Immunotherapy: Rates, Time Course and Patient Outcomes. *JCO* **2016**, *34*, 6580. [[CrossRef](#)]
16. Hodi, F.S.; Ballinger, M.; Lyons, B.; Soria, J.-C.; Nishino, M.; Tabernero, J.; Powles, T.; Smith, D.; Hoos, A.; McKenna, C.; et al. Immune-Modified Response Evaluation Criteria In Solid Tumors (ImRECIST): Refining Guidelines to Assess the Clinical Benefit of Cancer Immunotherapy. *J. Clin. Oncol.* **2018**, *36*, 850–858. [[CrossRef](#)] [[PubMed](#)]