



## Novel mutations in antiviral multiresistant HSV-2 genital lesion: A case report

Lucas Khellaf, Fabrice Bouscarat, Sonia Burrel, Nadhira Fidouh, Lorry Hachon, Margot Bucau, Sylvie Lariven, David Boutolleau, Véronique Joly, Jade Ghosn, et al.

### ► To cite this version:

Lucas Khellaf, Fabrice Bouscarat, Sonia Burrel, Nadhira Fidouh, Lorry Hachon, et al.. Novel mutations in antiviral multiresistant HSV-2 genital lesion: A case report. *Journal of Medical Virology*, 2022, 94 (12), pp.6122 - 6126. 10.1002/jmv.28070 . hal-03948876

**HAL Id: hal-03948876**

**<https://hal.sorbonne-universite.fr/hal-03948876>**



Submitted on 20 Jan 2023

**HAL** is a multi-disciplinary open access archive for the deposit and dissemination of scientific research documents, whether they are published or not. The documents may come from teaching and research institutions in France or abroad, or from public or private research centers.

L'archive ouverte pluridisciplinaire **HAL**, est destinée au dépôt et à la diffusion de documents scientifiques de niveau recherche, publiés ou non, émanant des établissements d'enseignement et de recherche français ou étrangers, des laboratoires publics ou privés.

Public Domain

# Novel mutations in antiviral multiresistant HSV-2 genital lesion: A case report

Lucas Khellaf<sup>1</sup> | Fabrice Bouscarat<sup>2</sup> | Sonia Burrel<sup>3</sup>  | Nadhira Fidouh<sup>4</sup> |  
Lorry Hachon<sup>5</sup> | Margot Bucau<sup>6</sup> | Sylvie Lariven<sup>1</sup> | David Boutolleau<sup>3</sup> |  
Véronique Joly<sup>1</sup> | Jade Ghosn<sup>1</sup> | Diane Le Pluart<sup>1</sup> | Michaël Thy<sup>1</sup> 

<sup>1</sup>Department of Infectious Diseases, Hôpital Bichat, Université de Paris, Paris, France

<sup>2</sup>Department of Dermatology, Hôpital Bichat, Université de Paris, Paris, France

<sup>3</sup>Department of Virology, Centre National de Référence Herpès virus, Hôpital Pitié-Salpêtrière, Sorbonne Université, INSERM U1136, Institut Pierre Louis d'épidémiologie et de santé publique (IPLESP), Paris, France

<sup>4</sup>Department of Virology, Hôpital Bichat, Université de Paris, Paris, France

<sup>5</sup>Department of Pharmacy, Hôpital Bichat, Université de Paris, Paris, France

<sup>6</sup>Department of Pathology, Hôpital Bichat, Université de Paris, Paris, France

## Correspondence

Michael Thy, Department of Infectious Diseases, Hôpital Bichat, Université de Paris, Paris, France.  
Email: [michael.thy@aphp.fr](mailto:michael.thy@aphp.fr)

## Abstract

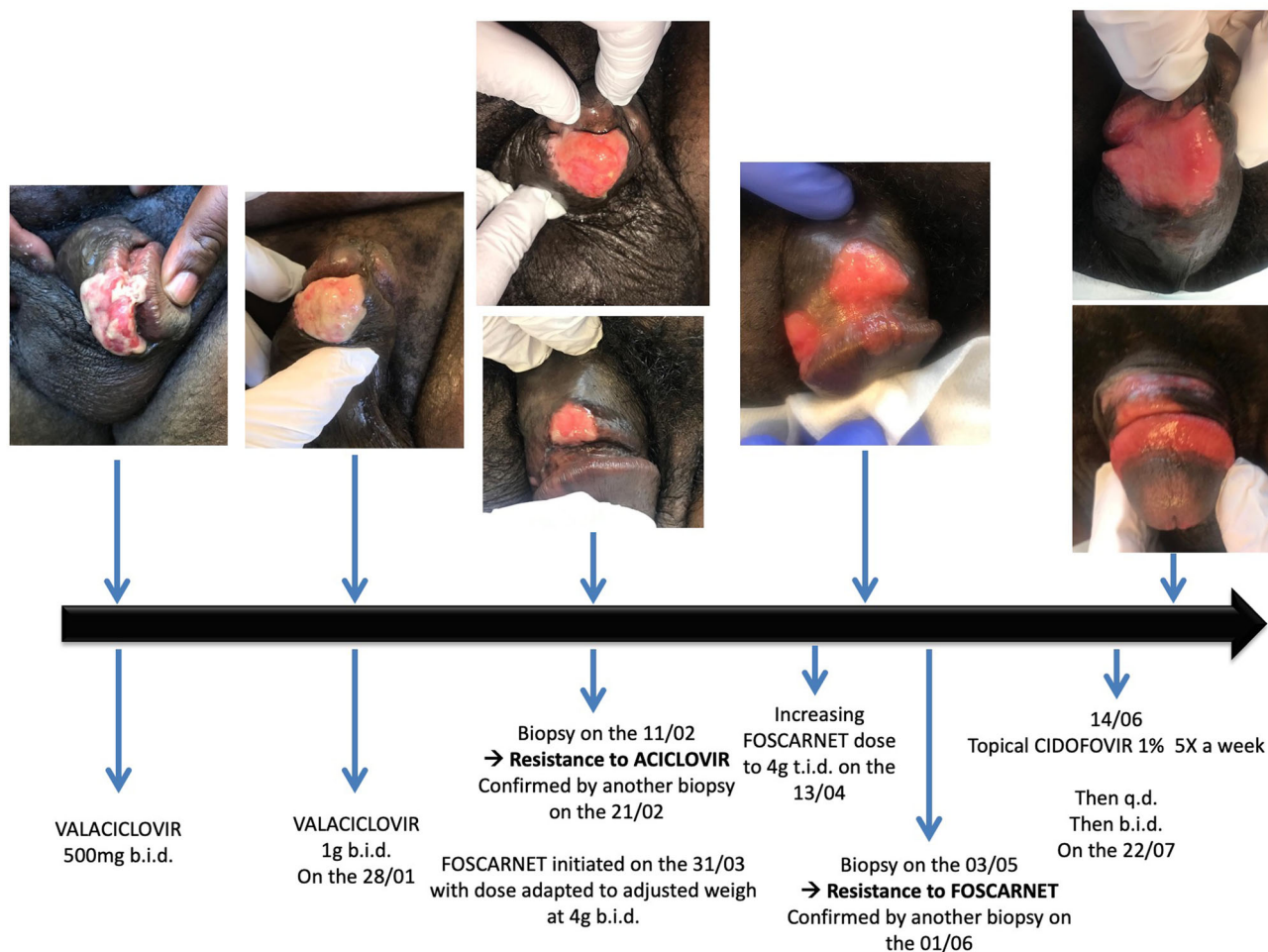
HSV-2 antiviral resistance mainly occurs in immunocompromised patients and especially in HIV-positive individuals receiving long-term antiviral treatment. Those situations can be challenging as few alternatives are available for HSV infection management. To describe clinical and virological significance of two novel potential HSV-2 resistance mutations after treating an obese patient with a pseudotumoral genital HSV-related lesion. Consecutive different antiviral treatments were used: valacyclovir (VACV) then foscarnet (FOS) then topical cidofovir (CDV) and finally imiquimod. Under VACV, genotypic resistance testing revealed a novel mutation within viral thymidine kinase (TK, gene UL23) not previously reported but probably accounting for antiviral resistance: W89G, similar to W88R mutation reported in HSV-1 TK, known to be associated with ACV resistance for HSV-1. Under FOS, while initial mutations were still present, a second genotypic resistance testing performed on persisting lesions showed a novel mutation within viral DNA polymerase (DNA pol, gene UL30): C625R. All three antivirals used in this case are small molecules and pharmacokinetics of VACV, FOS, and CDV have not been evaluated in animals and there are very few studies in human. As small molecules are poorly bound to proteins and distribution volume is increased in obese patients, there is risk of underdosage. This mechanism is suspected to be involved in emergence of resistance mutation and further data is needed to adapt, closely to patient profile, antiviral dosage. This report describes a chronic HSV-2 genital lesion, with resistance to current antivirals and novel mutations within viral TK and DNA pol which may confer antiviral resistance.

## KEYWORDS

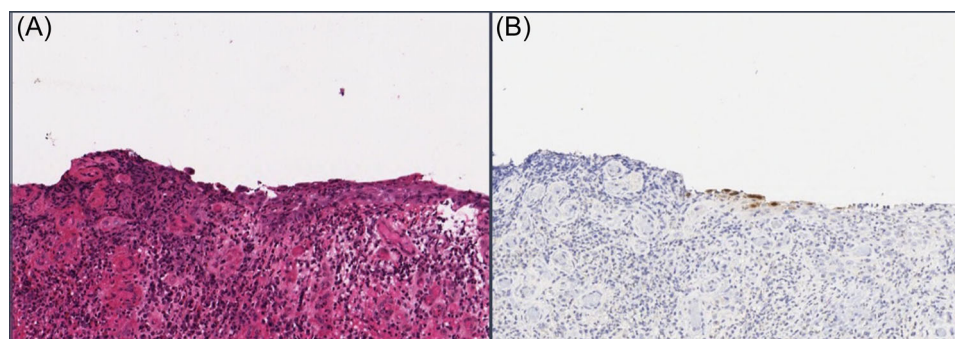
antiviral resistance, cidofovir, foscarnet, herpes simplex virus

A 49-year-old man presented with penis chronic lesion with central ulceration. He had a previous history of AIDS associated with pulmonary cryptococcoma (CD4 nadir in 2012:  $0/\text{mm}^3$ ), Ofuzi's eosinophilic folliculitis, obesity (BMI  $45 \text{ kg/m}^2$ ), and recurrent herpes simplex virus 2 (HSV-2) genital recurrences treated by oral valacyclovir (VACV) since 2012. In 2021, he developed a  $2 \times 1 \text{ cm}$  nodular ulcerative hypertrophic lesion on prepuce's inner surface. Medical history is displayed in Figure 1. He was treated with VACV 500 mg twice a day (BID) during 1 month and antiretroviral therapy (CD4 T-count  $430/\text{mm}^3$ ). Lesion worsened under treatment and VACV dose was doubled to reach  $2 \text{ mg/kg}$  per day. HSV polymerase chain reaction (PCR) on skin swab and immunolabeling performed on skin biopsy showed Malpighian cells positive for HSV-2 without dysplasia (Figure 2). Genotypic resistance testing was performed<sup>1</sup> revealing a mutation within viral thymidine kinase (TK, gene UL23) unpreviously reported but probably accounting for antiviral resistance: W89G. In the same sample we also identified the R628C mutation in viral DNA polymerase (DNA pol, gene UL30), however its role is uncertain as it has been described as a natural polymorphism or as potential associated resistance.<sup>2,3</sup> W89G mutation within TK

was never previously reported for HSV-2 but a similar mutation (W88R) has been associated with acyclovir (ACV) resistance in HSV-1 TK with phenotypic testing. In comparison, position 88 for HSV-1 TK is the homologous position 89 for HSV-2 TK. Moreover, this position is located within a highly conserved catalytic site of the TK (Figure 3).<sup>4</sup> Therefore, clinical resistance to VACV is suspected to be induced by W89G TK mutation rather than R628C DNA pol mutation. A second-line treatment by intravenous foscarnet (FOS) was initiated at weight-adjusted dosing due to obesity according to pharmacists' guidelines. The initial dose at  $80 \text{ mg/kg}$  was rapidly increased to  $120 \text{ mg/kg}$  per day regarding good tolerance and insufficient initial clinical response (i.e., persistent ulcerative lesion, see Figure 1). FOS was given for 1 month after a good but partial clinical response. After this delay, lesion tended to evolve into a  $3 \times 4 \text{ cm}$  chronic nodular scar with central ulceration (Figure 1). While initial mutations (W89G in TK and R628C in DNA pol) were still present, a second genotypic resistance testing performed on persisting lesion while under FOS-treatment showed the appearance of a novel mutation within DNA pol: C625R. ACV resistance was presumably linked to the W89G TK mutation, but we hypothesized



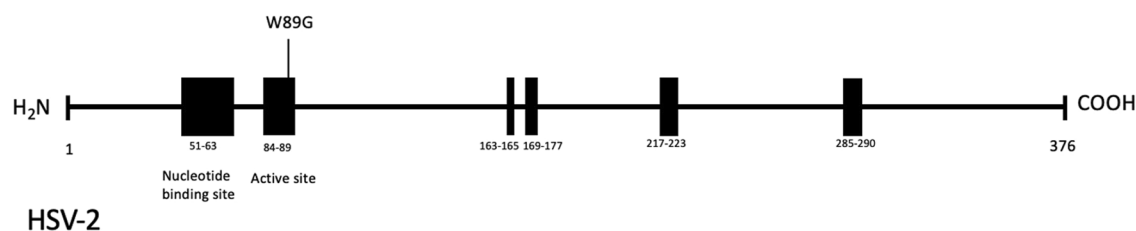
**FIGURE 1** Lesion evolution throughout each treatment from initial presentation in January 2021. b.i.d., twice a day; q.d., every day; t.i.d., three times a day; 5× a week, 5 times a week.



**FIGURE 2** Genital skin biopsy. (A) Saffron Eosin Hematein stain, magnification  $\times 100$ . The squamous mucosa of the glans is ulcerated, with lymphocytic and plasmocytic cellular infiltration. Normal epithelium is replaced by granulation tissue. Some squamous cells remain, without visible cytopathic effect. There are no architectural disorganization nor malignant epithelial cells. (B) Anti-HSV-2 immunohistochemistry, magnification  $\times 100$ . On the same ulcerated area, immunolabelling shows some HSV-positive squamous cells. HSV, herpes simplex virus.

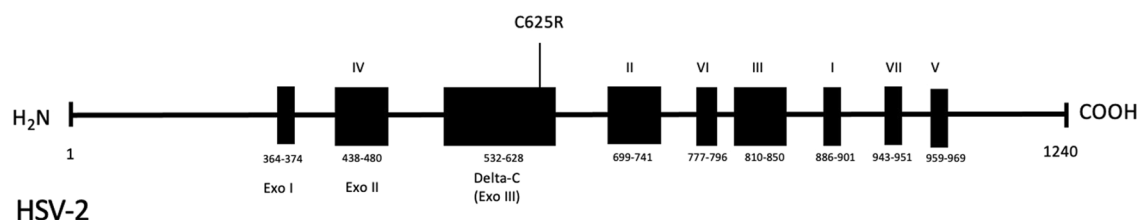
(A)

### Thymidine kinase (UL23 gene)



(B)

### DNA polymerase (UL30 gene)



**FIGURE 3** Mutations identified in both thymidine kinase (UL23 gene, panels A and B) and DNA polymerase (UL30 gene, panel C). (Panel A) Comparison between HSV-1 (HHV-1) and HSV-2 (HHV-2) coding sequence within thymidine-kinase active site. W88R mutation was previously associated with acyclovir resistance. Panel B (TK) and panel C (DNA Pol). Within DNA Pol, conserved regions among *Herpesviridae* genes are shown by the black boxes. Roman numbers (I to VII and Delta-C region) corresponding to each of these regions are indicated above the boxes. Each sequence with critical mutation is given and red letters mean substitutions.

that clinical resistance to FOS could be linked to the emergence of the C625R DNA Pol mutation. Unfortunately, no phenotypic assay could be performed. The association of the mutation localization, clinical nonresponse to antiviral treatment, and the appearance under selective pressure of FOS treatment gave the very high probability that this mutation (i.e., C625R DNA Pol) is associated with FOS resistance (also possibly associated with ACV resistance).

A third line of treatment using 5 days a week of topical cidofovir (CDV) 1% application (one application per day) was initiated with a good clinical response. After 2 months, chronic lesions were still present even though PCR on skin swab and immunolabeled viral

research on biopsy were negative for HSV-2. Without complete clinical improvement and the hypothesis of an aberrant skin reaction (described as "pseudotumoral"), topical CDV 1% was discontinued and switched to imiquimod 5% cream locally applied three times weekly. The evolution was good until new erosion areas appeared leading to the discontinuation of imiquimod with continuation of local cares only. After 1 month of treatment by imiquimod, a new clinical relapse appeared. HSV-2 PCR was again positive and genotypic resistance testing did not show mutations associated with antiviral resistance in absence of antiviral selection pressure (i.e., wild-type virus replication). Both mutations probably exist in minor variants and

**TABLE 1** Description of the reported mutations and novel mutations associated with drugs

Previously reported mutation	Novel reported mutation	Coding	Gene	Drug resistance
W88R in HSV-1	W89G in HSV-2	viral thymidine kinase	gene UL23	ACV/VACV
	R628C in HSV-2	viral DNA polymerase	gene UL30	possible ACV/VACV
	C625R in HSV-2	viral DNA polymerase	gene UL30	FOS

Abbreviations: ACV, Acyclovir; FOS: Foscarnet; VACV, Valacyclovir.

have probably been archived in sacral sensory ganglia (site of viral latency). Thereby, they may re-emerge if the antiviral pressure is applied again.

HSV-2 antiviral resistance mainly occurs in immunocompromised patients and especially in HIV-positive individuals (up to 7% of HIV-associated HSV-2 genital lesions) receiving long-term antiviral treatment. Those situations can be challenging as few alternatives are available for HSV infection management.<sup>5,6</sup> Standard therapy for the management of HSV infections includes ACV or its prodrug VACV. ACV is a guanosine analogue primophosphorylated by viral TK and then by cellular kinases into triphosphate form. When incorporated into viral DNA by DNA pol, it acts as a chain terminator and blocks viral DNA polymerization. Multiple resistance mutations accounting for HSV resistance to ACV has been reported to date.<sup>7</sup> However, the extensive database of natural polymorphisms and resistance mutations is not known to date. Mutation W89G has not been previously described, but a mutation at the residue 88 in HSV-1 TK (homologous position in HSV-2 TK) is known to confer ACV resistance in HSV-1.<sup>8</sup> In this case, W89G in HSV-2 TK is located in the highly conserved catalytic site of the viral enzyme<sup>4</sup> and could explain treatment failure. VACV underdosing during iterative antiviral treatments as well as immunosuppression due to HIV infection may have contributed to the emergence of antiviral resistance mutations. Second-line treatment for ACV-resistant genital herpetic lesions includes TK-phosphorylation-independent drugs such as FOS and CDV that remain active against ACV-resistant HSV due to TK alteration.<sup>9</sup> Indeed, FOS is a competitive pyrophosphate inhibitor directly blocking viral DNA pol. CDV is a phosphonyl nucleotide analogue (no further need of phosphorylation by viral TK to be active) that also hinders viral replication via the viral DNA pol.<sup>10</sup> Mutations within DNA pol may lead to cross-resistance to ACV and FOS, as previously described.<sup>11</sup> Mutation C625R within DNA pol is suspected to explain clinical resistance to FOS in this case. Phenotypic testing could not be performed, so we cannot demonstrate that mutation C625R is linked to a FOS phenotypic resistance profile. However, the association of (1) the location of mutations (Figure 3) in the highly conserved regions of TK (W89G) and DNA pol (C625R), (2) the appearance of mutations under ACV/FOS treatment, and (3) clinical failure of antiviral treatment could likely explain the selection of these mutations and the clinical resistance profile. We summarized the reported mutations and novel mutations associated with drugs in Table 1. We could not conclude to CDV-related cross-resistance, as for the first time since disease onset, we did not find any viral replication.

ACV, FOS, and CDV pharmacokinetic properties have not extensively been evaluated in animals' studies and there are very few studies in human. As small molecules and poorly bound to proteins, distribution volume increase in obese patients leading to potential underdosing.<sup>12</sup> This mechanism is suspected to be involved in the emergence of antiviral resistance mutations and further data is needed to adapt, closely to patient profile, antiviral dosage.

Hypertrophic genital herpes is a rare HSV-2 clinical presentation, almost exclusively described among immunocompromised patient, and especially within HIV individuals. Local immunotherapy by imiquimod 5%, after exclusion of malignancy, has been proposed for chronic hypertrophic herpes lesions and for pseudotumoral ACV and FOS resistant herpetic lesions.<sup>12–15</sup> Imiquimod is a Toll-like receptor-7 agonist, with indirect antiviral activity, that enhances local inflammatory reaction through Th1 profile cytokine including interferon- $\alpha$ , IL-12, and tumor necrosis factor- $\alpha$ .<sup>16</sup> Only two randomized trials studied imiquimod 5% local treatment in recurrent herpetic lesions<sup>17,18</sup> with contradictory results on efficacy and tolerance. In a double-blind Phase 2 randomized trial, Schacker et al.<sup>18</sup> observed some pharmacological response with imiquimod but it did not reduce genital herpes reactivations. Further data from clinical trials are needed to establish imiquimod treatment sequence, dose, duration, and combination with other treatment.

## 2 | CONCLUSION

In conclusion, this report describes a chronic HSV-2 genital lesion, with resistance to current antivirals and novel mutations within viral TK and DNA pol which may confer antiviral resistance.

## AUTHOR CONTRIBUTIONS

Lucas Khellaf and Michaël Thy collected the data and drafted the manuscript. Sonia Burrel, David Boutolleau, and Nadhira Fidouh performed virological analysis and contributed to interpretation. Lucas Khellaf and Michaël Thy, Fabrice Bouscarat, Sonia Burrel, Lorry Hachon, Margot Bucan, Sylvie Lariven, David Boutolleau, Véronique Joly, Jade Ghosn, and Diane Le Pluart contributed to the patient's care and interpretation and also critically revised the manuscript.

## CONFLICT OF INTEREST

The authors declare no conflict of interest.



## DATA AVAILABILITY STATEMENT

All data generated or analyzed during this study are included in this article or its supplementary material files. Further inquiries can be directed to the corresponding author.

## ORCID

Sonia Burrel  <http://orcid.org/0000-0002-7783-2601>

Michaël Thy  <http://orcid.org/0000-0001-9366-505X>

## REFERENCES

- Burrel S, Deback C, Agut H, Boutolleau D. Genotypic characterization of UL23 thymidine kinase and UL30 DNA polymerase of clinical isolates of herpes simplex virus: natural polymorphism and mutations associated with resistance to antivirals. *Antimicrob Agents Chemother*. 2010;54(11):4833-4842. doi:10.1128/AAC.00669-10
- Bohn-Wippert K, Schmidt S, Runtze A, Zell R, Sauerbrei A. Resistance testing of clinical herpes simplex virus type 2 isolates collected over 4 decades. *IJMM*. 2015;305(7):644-651. doi:10.1016/j.ijmm.2015.08.014
- Chibo D, Druce J, Sasadeusz J, Birch C. Molecular analysis of clinical isolates of acyclovir resistant herpes simplex virus. *Antiviral Res*. 2004;61(2):83-91. doi:10.1016/j.antiviral.2003.08.018
- Korovina AN, Gus'kova AA, Skoblov MY, et al. Mutations in the DNA polymerase and thymidine kinase genes of herpes simplex virus clinical isolates resistant to antiherpetic drugs. *Mol Biol*. 2010;44(3):431-438. doi:10.1134/S0026893310030118
- Topalis D, Gillemot S, Snoeck R, Andrei G. Thymidine kinase and protein kinase in drug-resistant herpesviruses: heads of a Lernaean Hydra. *Drug Resist Updat*. 2018;37:1-16. doi:10.1016/j.drug.2018.01.003
- Piret J, Boivin G. Antiviral resistance in herpes simplex virus and varicella-zoster virus infections: diagnosis and management. *Curr Opin Infect Dis*. 2016;29(6):654-662. doi:10.1097/QCO.0000000000000288
- Jiang YC, Feng H, Lin YC, Guo XR. New strategies against drug resistance to herpes simplex virus. *Int J Oral Sci*. 2016;8(1):1-6. doi:10.1038/ijos.2016.3
- Labrunie T, Ducastelle S, Domenech C, Ader F, Morfin F, Frobert E. UL23, UL30, and UL5 characterization of HSV1 clinical strains isolated from hematology department patients. *Antiviral Res*. 2019;168:114-120. doi:10.1016/j.antiviral.2019.05.012
- Vere Hodge RA, Field HJ. Antiviral agents for herpes simplex virus. *Adv Pharmacol*. 2013;67:1-38. doi:10.1016/B978-0-12-405880-4.00001-9
- Whitley R, Baines J. Clinical management of herpes simplex virus infections: past, present, and future. *F1000Res*. 2018;7:F1000 Faculty Rev-1726. doi:10.12688/f1000research.16157.1
- Bestman-Smith J, Boivin G. Drug resistance patterns of recombinant herpes simplex virus DNA polymerase mutants generated with a set of overlapping cosmids and plasmids. *J Virol*. 2003;77(14):7820-7829. doi:10.1128/jvi.77.14.7820-7829.2003
- Barroso Dos Reis HL, Tosato Boldrini NA, da Silva Campos LC, et al. Hypertrophic genital herpes in an HIV-infected female patient: imiquimod as an alternative treatment. *Int J Infect Dis*. 2020;95:153-156. doi:10.1016/j.ijid.2020.04.025
- Sbidian E, Battistella M, Legoff J, et al. Recalcitrant pseudotumoral anogenital herpes simplex virus type 2 in HIV-infected patients: evidence for predominant B-lymphoplasmocytic infiltration and immunomodulators as effective therapeutic strategy. *Clin Infect Dis*. 2013;57(11):1648-1655. doi:10.1093/cid/cit592
- Hirokawa D, Woldow A, Lee SN, Samie F. Treatment of recalcitrant herpes simplex virus with topical imiquimod. *Cutis*. 2011;88(6):276-277.
- Lascaux AS, Caumes E, Deback C, et al. Successful treatment of aciclovir and foscarnet resistant Herpes simplex virus lesions with topical imiquimod in patients infected with human immunodeficiency virus type 1. *J Med Virol*. 2012;84(2):194-197. doi:10.1002/jmv.23188
- Tandon S, Singh J, Sinha S, Sharma DP. Recalcitrant hypertrophic herpes genitalis in HIV-infected patient successfully treated with topical imiquimod. *Dermatol Ther*. 2017;30(3):e12479. doi:10.1111/dth.12479
- Bernstein DI, Spruance SL, Arora SS, Schroeder JL, Meng TC. Evaluation of imiquimod 5% cream to modify the natural history of herpes labialis: a pilot study. *Clin Infect Dis*. 2005;41(6):808-814. doi:10.1086/432802
- Schacker TW, Conant M, Thoming C, Stanczak T, Wang Z, Smith M. Imiquimod 5-percent cream does not alter the natural history of recurrent herpes genitalis: a phase II, randomized, double-blind, placebo-controlled study. *Antimicrob Agents Chemother*. 2002;46(10):3243-3248. doi:10.1128/AAC.46.10.3243-3248.2002

**How to cite this article:** Khellaf L, Bouscarat F, Burrel S, et al. Novel mutations in antiviral multiresistant HSV-2 genital lesion: a case report. *J Med Virol*. 2022;94:6122-6126. doi:10.1002/jmv.28070