



**HAL**  
open science

## Toxic-metabolic encephalopathy in adults: Critical discussion and pragmatical diagnostic approach

L Le Guennec, C Marois, S Demeret, E F M Wijdicks, Nicolas Weiss

### ► To cite this version:

L Le Guennec, C Marois, S Demeret, E F M Wijdicks, Nicolas Weiss. Toxic-metabolic encephalopathy in adults: Critical discussion and pragmatical diagnostic approach. *Revue Neurologique*, 2022, 178, pp.93 - 104. 10.1016/j.neurol.2021.11.007 . hal-03980706

**HAL Id: hal-03980706**

**<https://hal.sorbonne-universite.fr/hal-03980706>**

Submitted on 22 Jul 2024

**HAL** is a multi-disciplinary open access archive for the deposit and dissemination of scientific research documents, whether they are published or not. The documents may come from teaching and research institutions in France or abroad, or from public or private research centers.

L'archive ouverte pluridisciplinaire **HAL**, est destinée au dépôt et à la diffusion de documents scientifiques de niveau recherche, publiés ou non, émanant des établissements d'enseignement et de recherche français ou étrangers, des laboratoires publics ou privés.



Distributed under a Creative Commons Attribution - NonCommercial 4.0 International License

## **Toxic-metabolic encephalopathy in adults: critical discussion and pragmatical diagnostic approach.**

Loic Le Guennec<sup>1, †</sup>, Clémence Marois<sup>1, †</sup>, Sophie Demeret<sup>1</sup>, Eelco F. M. Wijdicks<sup>2</sup>

Nicolas Weiss<sup>3</sup>

### Affiliations :

<sup>1</sup> Sorbonne Université, AP-HP.Sorbonne Université, Hôpital de la Pitié-Salpêtrière, département de neurologie, unité de Médecine Intensive Réanimation à orientation neurologique, Paris, France & Groupe de Recherche Clinique en REanimation et Soins intensifs du Patient en Insuffisance Respiratoire aiguE (GRC-RESPIRE) Sorbonne Université

<sup>2</sup> Mayo Clinic, Department of Neurology, 200 First Street SW, Rochester, MN 55905, USA

<sup>3</sup> Sorbonne Université, AP-HP.Sorbonne Université, Hôpital de la Pitié-Salpêtrière, département de neurologie, unité de Médecine Intensive Réanimation à orientation neurologique, Paris, France & Brain Liver Pitié-Salpêtrière (BLIPS) Study Group, INSERM UMR\_S 938, Centre de recherche Saint-Antoine, Maladies métaboliques, biliaires et fibro-inflammatoire du foie, Institute of Cardiometabolism and Nutrition (ICAN), Paris, France & Groupe de Recherche Clinique en REanimation et Soins intensifs du Patient en Insuffisance Respiratoire aiguE (GRC-RESPIRE) Sorbonne Université  
Sorbonne Université, AP-HP.Sorbonne Université, Hôpital de la Pitié-Salpêtrière, département de neurologie, unité de Médecine Intensive Réanimation à orientation neurologique, Paris, France & Brain Liver Pitié-Salpêtrière (BLIPS) Study Group, INSERM UMR\_S 938, Centre de recherche Saint-Antoine, Maladies métaboliques, biliaires et fibro-inflammatoire du foie, Institute of Cardiometabolism and Nutrition (ICAN), Paris, France & Groupe de Recherche Clinique en REanimation et Soins intensifs du Patient en Insuffisance Respiratoire aiguE (GRC-RESPIRE) Sorbonne Université

†L.L.G. and C.M. contributed equally to this work.

### **Corresponding author:**

Eelco F. M. Wijdicks, [wijde@mayo.edu](mailto:wijde@mayo.edu)

Mayo Clinic, Department of Neurology, 200 First Street SW, Rochester, MN 55905, USA

**Abstract:**

Toxic-metabolic encephalopathy (TME) results from an acute cerebral dysfunction due to different metabolic disturbances including medications or illicit-drugs. It can lead to altered consciousness, going from delirium to coma, which may require intensive care and invasive mechanical ventilation. Even if it is a life-threatening condition, TME might have an excellent prognosis if its etiology is rapidly identified and treated adequately. This review summarizes the main etiologies, their differential diagnosis, and diagnostic strategy and management of TME with a critical discussion on the definition of TME.

**Keywords:** toxic-metabolic encephalopathy, metabolic encephalopathy, ICU, inborn error of metabolism, disorders of consciousness, coma, delirium, encephalopathy, blood-brain barrier.

**Abbreviations**

CSF: cerebrospinal fluid

CT: computerized tomography

EEG: electroencephalogram

cEEG: continuous electroencephalogram

FLAIR: fluid-attenuated inversion recovery

HE: hepatic encephalopathy

ICU: intensive care unit

IEM: inborn error of metabolism

MELAS: mitochondrial encephalopathy with lactic acidosis and stroke-like episodes

MERRF: myoclonic epilepsy with ragged red fibers

TME: toxic-metabolic encephalopathy

## **Introduction**

Among the many causes of altered consciousness, toxic-metabolic encephalopathy (TME) is probably the most common evoked diagnosis. However, whereas specific causes are well defined, the definition of TME is complex and a generally accepted definition is still lacking. Metabolic encephalopathy, and the term toxic frequently added, is nowadays however a commonly used term in medicine. We should keep in mind that its delineation is blurred and its existence as a nosological entity can be questioned. Indeed, whereas metabolic encephalopathy has initially been proposed as the cerebral consequences of one major organ dysfunction, it has progressively been applied to all hemispheric neurological symptoms without any focal sign [1]. This probably explains some concurrence between a purely symptomatic description of neurological status compared to a more pathophysiological description that could be, imperfectly, expressed by toxic-metabolic encephalopathy [2]. One must nevertheless keep in mind the fact that while the pathophysiology of some metabolic encephalopathies is relatively well understood, the pathophysiology of most of others remains largely unknown. The absence of a precise nosological description has probably hindered pathophysiological studies in the past.

Despite these shortcomings, in the common acceptance of TME, the term refers to a potentially reversible pathological process within the brain, arising from an extracerebral origin, secondary to different metabolic disturbances including the effect of medications/drugs and their withdrawal.

The clinical presentation of TME is nonspecific and implies altered consciousness, without, in general, any focal and/or asymmetrical neurological signs. Abnormal movements such as asterixis or myoclonus can be found. This life-threatening condition could account for 15% of all causes of coma in the intensive care unit

(ICU), with the limitations that have been raised previously [3][4]. Thus, an accurate diagnostic approach is critical for proper management.

This review will successively discuss the following points:

- (1) How is TME most commonly defined and what are the main causes?
- (2) What are the clinical presentations of TME?
- (3) What are the main differential diagnoses to rule out prior to evoking TME?
- (4) What etiological workup should be performed?
- (5) How should TME be managed and what is the possible outcome?
- (6) Some perspectives

## **1. How is TME most commonly defined and what are the main causes?**

### *1.1 Commonly accepted definition and pathophysiology*

According to the recent nomenclature updated by an expert consensus, the term *acute encephalopathy* should be defined as a rapidly developing brain process which is expressed clinically as delirium or coma and may have additional features, such as seizures or extrapyramidal signs [2] (Supplemental Table 1). Thus, despite its initial limitation to only cerebral consequences of organ dysfunction, TME could be defined as a developing brain process secondary to a metabolic disturbance but is often described as multifactorial in origin [5][1][6]. This metabolic disturbance can be either innate, very rare, or acquired, most frequently, and is secondary to an organ failure, to altered homeostasis, the deficit or the accumulation of some endogenous or exogenous substances, including medications, illicit drugs or any neurotoxic substance.

This process could be responsible for compromised cellular functioning of neurons but probably also astrocytes, and for long-lasting compromised signal transmission

between different brain regions. Moreover, some brain areas such as the frontal regions could be particularly susceptible to metabolic disturbance [7].

Some circumstances associate multiple homeostasis disturbances, for instance as in hepatic encephalopathy (HE), where neurological symptoms can be secondary to hyperammonemia and systemic and cerebral inflammation, as well as intracerebral accumulation of bile acids and medications [8]. The implication of increased permeability of the blood-brain barrier (BBB) and the expression of specific transporters – ATP binding cassette transporter or efflux pumps – on it has been proposed [9][10] and could explain differences in the severity of the neurological signs despite very similar triggering events. Indeed, patients with previous cerebral alterations – elderly patients, patients with prior neurological diseases or patients without prior neurological diseases but with altered BBB permeability like cirrhotic patients for example – are more prone to develop encephalopathy: [11][12][13][14]. For instance, 20% of patients with liver cirrhosis display hepatic encephalopathy (HE) at diagnosis, and approximately 70% will develop HE during the disease course [8]. Increased permeability of the BBB has been recently shown in this condition [10][15] as as have the accumulation of efflux pump substrates in the cerebrospinal fluid (CSF). Most of the patients with encephalopathy in ICU have many medications due to their intensive care condition, sedatives, antimicrobial agents for nosocomial infection, or due to the cause of their admission to ICU [16][17]. Therefore, they might be more vulnerable to metabolic disturbance. Some polymorphisms of P-glycoprotein (P-gp) have been found to be associated with an increased risk of ICU delirium [18]. The number of prescribed medications could thus constitute a risk factor mainly through possible drug competition on BBB efflux pumps [19][10][20]. One illustrative example is the concomitant use of over-the-counter loperamide with another P-gp

substrate, frequently verapamil, to deliberately induce neurological toxic effects by loperamide, a “peripheral” opioid. Indeed, when taken concomitantly with verapamil that will be effluxed by P-gp, loperamide will accumulate inside the brain as attested by cerebral scintigraphy and positron emission tomography [19] and lead to alteration of consciousness.

### *1.2 Main causes of TME*

Some etiologies of TME, such as anoxic-ischemic encephalopathy and hypercapnic encephalopathy, are easily recognized by physicians as they often occur in an obvious context of organ dysfunction: heart failure or cardiac arrest and respiratory failure, respectively. Hepatic encephalopathy or uremic encephalopathy are frequently associated with other causes of TME due to the patient’s condition, especially septic-associated encephalopathy. Some toxic etiologies, for instance carbon monoxide poisoning, are more difficult to evoke if not in their common medical scenarios, particularly if the victim was alone at home without other victims. Illicit drug abuse is another example. Table 1 summarizes the main causes of acquired TME. Among TMEs due to deficiencies, hypoglycemia and Gayet-Wernicke’s encephalopathy should be rapidly ruled out since these life-threatening conditions require rapid supplementation to preclude definitive neurological sequelae. Gayet-Wernicke’s encephalopathy is observed after exhaustion of thiamine (vitamin B1) reserves mainly in patients with chronic alcohol consumption [21]. Nowadays, it can also be encountered following obesity surgery, with poor or insufficient postoperative supplementation or following certain chemotherapies, which may interfere with thiamine absorption. Anecdotally, among rare causes of TME, endocrinological etiologies such as hypothyroidism or adrenal insufficiency can be cited, although the



cerebral hypometabolism observed in these conditions is simply the expression of a global body hypometabolism. Among TMEs secondary to the accumulation of a substance, either an endogenous or an exogenous substance, hyperammonemia and drug-induced encephalopathy should be promptly evoked as well [6][22]. A list of drugs and medication commonly associated with TME is shown in Table 2. It should be noticed that some drugs are able to induce hyperammonemia as well. In the ICU, medications responsible for encephalopathy are usually analgesics, antiepileptic medications and antimicrobial drugs, but neuroleptics, antidepressants, and immunosuppressive agents can also be responsible [23]. Another mechanism of encephalopathy, which is neither due to a deficiency nor an accumulation of a substance, we can cite rapid osmolar shift, responsible for osmotic demyelination. Usually, this entity is attributed to an overly rapid correction of hyponatremia [24]. The implication of this osmotic shift in cirrhotic patients with hyponatremia has been proposed to be implicated or associated with HE [25][26]. In a patient with a history of alcoholism or illicit drug abuse, acute alcoholic or another drug withdrawal must be evoked. Some specific causes such as vasculitis or specific TME, e.g. *Chasing the Dragon* in heroin users [27], could be looked for.

Finally, encephalopathy can be an acute manifestation of an inborn error of metabolism (IEM). IEMs are rare conditions mainly diagnosed in childhood, but those can occur in adulthood with an acute presentation and few or no symptoms beforehand [28]. IEMs involve brain functioning via three main mechanisms: *i*) intoxication with an endogenous substance due to its rapid accumulation; *ii*) an energy deficit due to deficiency in energetic metabolism processes; *iii*) cellular organelle dysfunction leading to a synthesis deficit regarding a crucial molecule or catabolism abnormalities, particularly in enzymes involved in the degradation of

complex molecules [29][30][28]. Table 3 summarizes IEMs, with their diagnostic investigations. Even though these diseases are rare, specific experience is needed for both diagnosis and management. In most developed countries, dedicated networks exist and it is helpful to identify the local contact upstream (see in France: <http://www.filiere-g2m.fr> or <http://www.sfeim.org>).

Due to its heterogeneous non-specific clinical presentation with symptom fluctuations, onset of encephalopathy requires an appropriate neurological examination and an accurate diagnostic approach, essential for tailored patient management.

## **2. What are the clinical presentations of TME?**

Although not specific, subacute delirium with myoclonus in the absence of focal neurological sign should suggest TME [31].

### *2.1 Delirium*

The term *delirium* (Supplemental Table 1) is defined by a change from baseline, with disturbance in attention, awareness, and cognition (memory deficit, disorientation, language, visuospatial or perception disturbance) over a short period of time, with a trend to fluctuation in severity over time. To fulfilled *delirium* definition, these disturbances should not be explained by a pre-existing neurological disorder [2] [32].

The inability to pay attention is a subtle sign that appears precociously and should constitute a red flag. Altered awareness ranges from drowsiness to deep coma, and can be assessed using the Glasgow Coma Scale or the FOUR score (full outline of unresponsiveness) [33] [34]. It can lead to the loss of airway reflexes with a risk of airway obstruction, aspiration pneumonia or bradypnea, which may require ICU

admission and mechanical invasive ventilation. In the ICU, delirium can be scored using the Confusion Assessment Method for the ICU (CAM-ICU)[35]. This scale can be used even in mechanically ventilated patients and is a validated tool to assess delirium.

## *2.2 Sleep disorders*

Reversal of circadian rhythm, insomnia, hypersomnia, and rapid eye movement sleep behavior disorder can be observed in TME, sometimes independently from delirium, and should be sought.

## *2.3 Myoclonus and asterixis*

*Myoclonus*, a movement disorder characterized by brief and involuntary muscular jerks, is common in TME. Frequently visible in the upper limbs or on the face, it can sometimes be observed over the whole body. TME can also be revealed by *asterixis*, a sudden postural fall which is called negative myoclonus [36][37]. It is characterized by irregular and sustained intermittent muscle relaxation (distal negative myoclonus), and revealed classically in the upper limbs by the Barré test. It is quite common for these myoclonus to be misinterpreted as epileptic activity, both clinically and at EEG, and treated as such, thereby worsening TME and associated consciousness disorders [38].

## *2.4 Cranial nerve palsy*

Even though a differential diagnosis should be ruled out first prior to evoking TME in the diagnostic approach of a cranial nerve palsy, this presentation is possible. It is an expression of brain stem dysfunction, with cranial nerve signs (oculomotor

disturbances, nystagmus, or changes in pupil size), pathological brain stem reflexes, and bulbar syndrome [39].

### *2.5 Extrapyrarnidal signs and movement disorders*

According to the TME etiology, extrapyramidal signs can be observed as well as other movement disorders [39]. These symptoms are classically observed during the accumulation of certain substances, such as excess copper during Wilson's disease or in manganese intoxication [40][41]. Extrapyrarnidal signs can also be observed in overt HE [42]. These are typically reversible after liver transplantation and have been associated with the accumulation of manganese ([43]). However, these symptoms are rarely seen in other causes of TME.

The diversity of clinical manifestations might be explained by the heterogeneity of brain regions involved depending on the related TME etiology.

### **3.What are the main differential diagnoses to rule out prior to evoking TME?**

Table 4 summarizes the main differential diagnoses that should at least be discussed, clinical symptoms to look for and associated complementary examinations. Briefly, if a neurological localization sign is observed or if an acute coma occurs, the first urgent diagnosis to rule out is a vascular cause or a space occupying process, by brain imaging [44]. Note that post-traumatic brain injury is not considered as a TME. Bacterial meningitis has to be ruled out in a patient with fever and associated meningism [45]. Skin purpuric lesions, which in this context must lead to suspect an invasive meningococcal disease, should be sought. Similarly, fever associated with a focal neurological sign or seizures should raise the hypothesis of an ongoing brain infectious process (viral encephalitis, rhombencephalitis, brain

abscess or septic embolism from an endocarditis). Posterior reversible encephalopathy syndrome can also mimic a TME (see for review [46]). Immune-mediated encephalitis can be evoked in a patient with alteration of consciousness, focal neurologic signs, movement disorders and seizures (see for review [47]). However, it should be recalled that apart from very common biochemical or immunological tests, most of the biological work-up requires several weeks to obtain definitive results. The consequence is that the diagnosis of TME is generally retained before some results are known, based on the clinical context and minimal negative etiological work-up.

#### **4. Which etiological work-up should be performed?**

##### *4.1 First-line etiological work-up*

This first-line etiological work-up has as objectives to confirm TME, to determine its etiology and to rule out differential diagnoses (Table 4). Whereas EEG can confirm TME, brain imaging will mainly rule out differential diagnoses. Blood sampling will bring clues in favor of TME but will inconsistently enable definitive confirmation of TME.

##### Blood sampling

Capillary glucose level must be determined whenever there is an acute neurological symptom. Confirmation on a blood sample is required, but a low capillary glucose level should be treated rapidly by glucose administration. Blood chemistry with sodium and calcium levels and other blood tests – urea, creatinine, liver enzymes and prothrombin time – enables evoking the most common causes of TME: electrolyte disorder, kidney or liver failure. Blood gases can show evidence of

hypercarbia associated with respiratory failure [5]. Depending on the context, other tests including vitamin B1 assay before any supplementation, search for illicit-drugs or medications – especially, opioids, benzodiazepines, neuroleptics, amphetamines, and cannabinoids – in urine and blood samples, as well as blood tests for thyroid hormones, cortisol, vitamin B9, B12, C or PP can be ordered [48]. It can be helpful to store blood and urine samples, drawn before any supplementation, for further unplanned analyses.

In the absence of any definite diagnosis in the hours after symptom onset, ammonemia should be determined without delay and without waiting for the results of all tests. Indeed, even when the context is not suggestive of acute liver failure or chronic liver disease, hyperammonemia is an important finding since it could reveal hepatic encephalopathy associated with an undiagnosed liver disease, or with a porto-systemic shunt without liver disease; drug-associated hyperammonemia (sodium valproate, 5-fluorouracil or asparaginase for the most frequent ones) [49] is another possibility, or more rarely an undiagnosed IEM, especially urea cycle defect [28][50][30]. Some miscellaneous causes of hyperammonemia are also possible [51][52]. In the specific context of liver disease, neurological symptoms suggestive of HE with a normal ammonia level should prompt search for a differential diagnosis such as aseptic or drug-associated encephalopathy. For example, using metabolomics our group recently showed that about 60% of cirrhotic patients presenting with encephalopathy had significant levels of antimicrobial agents in their CSF [53]. On the other hand, ammonia levels above 150  $\mu\text{mol/l}$ , but the cut-off is still discussed, would be suggestive of IEM that can be associated with atypical liver presentation. It should however be recalled that some technical issues persist with ammonia assays [54].

## Brain imaging

TME diagnosis is based on history taking and physical examination, however, if there is a doubt or an atypical presentation, brain imaging may be needed to rule out major differential diagnoses and to exclude brain lesions (Table 2). If brain imaging is performed, magnetic resonance imaging should be preferred to computed tomography (CT) as it is more sensitive [55]. However, if unavailable, or cumbersome to perform as in the ICU, a CT-scan should at least be performed if no positive diagnosis has already been established. In most cases, brain imaging is normal in TME. Nevertheless, unfrequently, it can show either diffuse or focal edema or specific lesions as in Gayet-Wernicke's encephalopathy or metronidazole-associated TME. For instance, bilateral T2 and FLAIR hyperintensity of the dentate nucleus, the cerebellar peduncles and the inferior colliculus associated with olivary hypertrophy is evocative of a metronidazole-induced encephalopathy [56]. Similarly, T2 and FLAIR hyperintensity of the splenium of the corpus callosum have been described in patients treated with carbamazepine [57].

Magnetic resonance spectroscopy can also help the investigation. For instance, a classical spectroscopic profile of hepatic encephalopathy shows an increased peak of glutamine/glutamate and a decreased peak of choline and myoinositol [58].

## Electroencephalogram (EEG)

EEG is a primary tool for the positive diagnosis as it can detect and monitor TME in the ICU and because of its availability at bedside, its non-invasiveness, and its excellent temporal resolution. In case of TME, it will typically show the presence of slow background activity with fluctuating triphasic waves, maximal over anterior

regions, and an inconstant reactivity to stimulations (Fig. 1). However, an unreactive EEG pattern must raise the possibility of a differential diagnosis, such as status epilepticus or severe hypoxic ischemic encephalopathy. The degree of EEG disturbance correlates fairly well with the level of consciousness, and allows to graduate TME severity [59][60][61]. More specific patterns can sometimes be found such as unreactive pseudo periodic triphasic waves in cefepime-induced encephalopathy, an increase in frequency of the posterior dominant rhythm in hyperthyroidism, or frontal intermittent rhythmic delta activity in hyperglycemia or hyponatremia [62][63]. Several drugs including baclofen, barbiturates or propofol can also cause burst-suppression on EEG.

EEG can also detect interictal patterns, non-convulsive seizures or electrical status epilepticus that represent frequent differential diagnoses and possible complications of TME [38][64] (Fig. 2). More recently, several studies demonstrated the value of continuous electroencephalographic monitoring (cEEG) in the ICU. cEEG provides continuous monitoring of brain function and is recommended to identify non-convulsive seizures in patients with an altered mental status without known acute brain injury. cEEG may also provide some prognostic elements in hypoxemic ischemic encephalopathy [65] [66] [67] [68] [69] [70]. The place of cEEG in TME has however to be clarified in the future even though most neuro-ICUs use regularly it in this condition.

### Lumbar puncture

Lumbar puncture is normal in TME or IEM, outside specific techniques not routinely available [10] and may be performed mainly to rule out a differential diagnosis, especially in the case of altered consciousness with fever suggesting



meningoencephalitis. Quiet recently, two studies proposed that the concentrations of drugs or the level of neurofilaments in the CSF could be prognostic in TME [71] [72]. This has however to be confirmed.

#### *4.2 If the first-line etiological work-up doesn't lead to a diagnosis*

The most important points are probably to review all the tests that have been performed, and sometimes redo the doubtful ones, and go back to the medical history. Indeed, having a detailed history of symptom onset, of personal and familial history will enable to orient the second-line etiological work-up.

If an IEM is suspected, additional explorations – thoraco-abdominopelvic CT scan, ophthalmologic examination – should be proposed to identify frequently associated non-symptomatic lesions in other organs, or in the spine or the peripheral or central nervous system. Spine magnetic resonance imaging, electroneuromyography and audiogram are sometimes needed. In some case, histological analysis is performed on a muscle or brain biopsy [73] [74].

Evidence of neurosensorial impairment (deafness, blindness), diabetes mellitus, family history in association with TME and myoclonus will lead to evoke mitochondrial encephalopathy and will need genetic testing for MELAS and MERF and muscular biopsy. An acute encephalopathy onset in a context of fasting, high protein intake, pregnancy, previous episodes of altered consciousness, unexplained rhabdomyolysis or metabolic acidosis will lead to evoke an IEM. If so, an expert center should be rapidly contacted, and preventive measures urgently taken. Specific dosages or genetic analysis (one or many specific genomic regions with next generation

sequencing, or whole exome sequencing) are needed but are guided by the expert's advice [75].

Broader diffusion of metabolomic techniques, liquid chromatography coupled to mass spectroscopy, now also enables posteriori identification of thousands of toxic substances based on hair analyses [76].

## **5. How should TME be managed and what is the possible outcome?**

Management of TME includes symptomatic management including neuroprotective measures and etiological management. Whatever the etiology of TME, management consists in avoiding fever, controlling mean arterial blood pressure, glucose and sodium levels, avoiding hypercarbia but also severe hypocarbia that has been associated with cerebral ischemia. Several studies recently suggested that hyperoxia could be deleterious, thus systemic oxygen administration should probably be avoided and oxygen delivered only if oxygen level is low [77]. In the ICU, some simple environmental measures are frequently added and recommended: quiet ambiance with low intensity lights and night switch off, ear plugs and eye masks, displaying clocks in each room [78]. If psychomotor agitation is present, haloperidol and dexmedetomidine are the preferred drugs [79]. In case of a non-rapidly reversible comatose state, mechanical ventilation can be mandatory. Seizure management have no specificities in TME outside the frequent pitfall of misdiagnosing myoclonus or triphasic waves as seizures or epileptic activity [38]. Some authors prefer to avoid antiepileptic drugs that can be responsible for TME in this condition and suggest avoiding sodium valproate in patients with previously altered brains.

The etiological management of TME is of major importance. Electrolyte disorders must be corrected, glucose be given in case of hypoglycemia, B1 supplementation prescribed in Gayet-Wernicke's encephalopathy, invasive or non-invasive mechanical ventilation be started in case of hypercapnic encephalopathy, the cause of sepsis be identified and antimicrobial agents be given. If encephalopathy onset is secondary to medications, simplifying the prescription is of major importance. Depending on the associated causes of TME and the possible complex interaction between the different drugs on efflux pumps, stopping every non-indispensable molecule is an easy practical advice. If one specific compound is clearly suspected, cefepime for example, its replacement by another equivalent drugs is indicated. Whereas in the case of TME associated for example to lithium or phenytoin intoxication, renal replacement therapy can be discussed [80], some others associated with toxic alcohol, methotrexate or ifosfamide specific antidotes can be proposed [81] [82] [83]. IEM treatment should be done in collaboration with the local expert center. In the first hours, it is important to avoid further degradation by applying a preventive strategy. In case of urea cycle defects, protein restriction during the first 24 hours should be done only in association with the administration of glucose and lipids in order to prevent endogenous protein catabolism [28]. Whatever the etiology of TME, any precipitant factor should be treated; infection being probably the most frequent one.

Very few data on outcome of TME are available. The large range of etiologies preclude definitive answers. However, due to the theoretical reversible nature of TME, it appears, by experience, that the prognosis of TME is good. This is an important point especially for intensivists and has two major implications. First, patients with suspected TME should be admitted in the ICU and second it is important to give the

patients with TME some time to improve before discussing care withdrawal or withholding. In some circumstances, where the disturbance has lasted for a long time and management has been delayed, definitive neurological sequelae can be present. This reinforces the need for early recognition and early management/treatment [84].

## **6. Perspectives**

We previously discussed shortcomings of the term toxic-metabolic encephalopathy. Thus, how to deal with it? Quiet recently, it has been shown that the use of the term encephalopathy or delirium in original articles in Pubmed were largely dependent on the specialty of the authors [2]. Whereas internists, neurologists mainly use encephalopathy; anesthesiologists, intensivists, psychiatrics, and geriatrics use delirium. Furthermore, the authors showed that the corresponding published literature is highly segregated. A panel of experts using a modified Delphi method proposed the definition presented in **Supplemental Table 1** for encephalopathy and delirium and discarded the use of some other terms. Should a similar approach be applied to TME? Indeed, the imperfect shape precludes for more detailed studies on epidemiology, pharmacology, pharmacoepidemiology or pathophysiology. Only such an approach could improve our knowledge and provide strong evidence for better management.

## **7. Conclusion**

TME is a frequently encountered condition in the emergency room, the ICU and/or in patients with chronic diseases. Even if most cases are reversible and have good outcome, delayed diagnosis and management can be associated with worse

outcome and neurological sequelae. This reinforces the need for an urgent diagnosis and management. Clinically, the presentation is unspecific with altered consciousness, without focal signs classically, and can be associated to asterixis or myoclonus. Apart the medical history and the context, EEG is of major importance to make a positive diagnostic of TME whereas brain imaging is mainly important to rule out differential diagnosis. In the absence of any definite diagnosis, ammonia should be measured. Past medical history of sensory disturbance, neuropathy, epilepsy in childhood, consanguineous marriage in the family or an unknown neurological disease in patient's relative can raise the possibility of an IEM. TME management encompasses symptomatic measures aimed to avoid neurological worsening and the treatment of the cause of TME. Some technical evolution, metabolomics or improved brain imaging, will probably provide a more rapid diagnosis of TME in a near future [22] [53] [85] [86].

## **Acknowledgements**

*Nicolas Weiss would like to thank the Fondation pour le Recherche Médicale for their support (FRM (EQU202003010517)) for research activities.*

EQU202003010517).

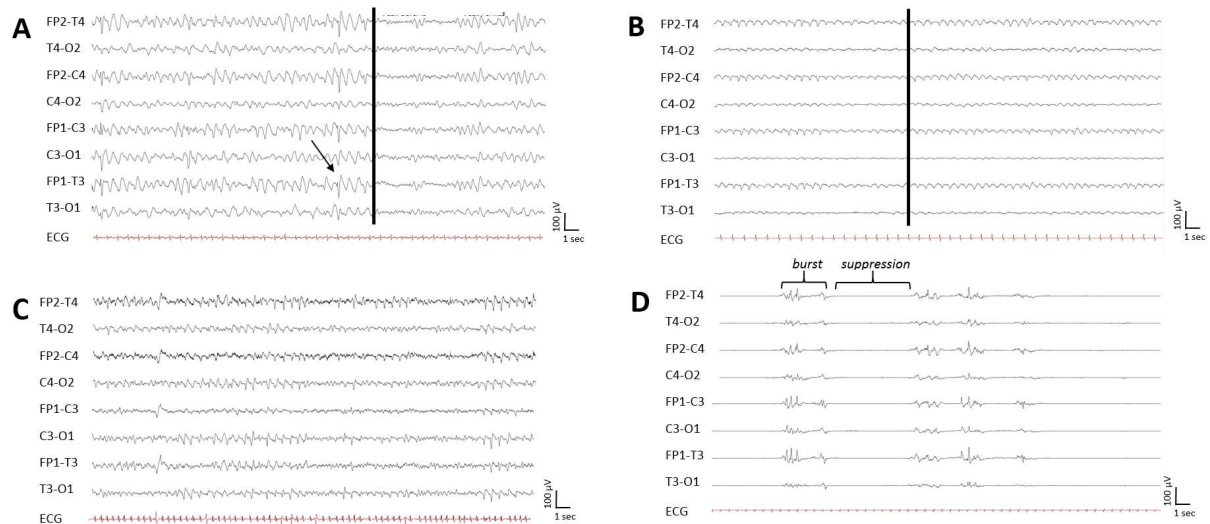
Funding sources:

*Nicolas Weiss would like to thank the Fondation pour le Recherche Médicale for their support (FRM (EQU202003010517)) for research activities.*

Nicolas Weiss declares having perceived consultant fees from MedDay Pharmaceuticals and Owkin.

## Legends

**Figure 1:** Various representative EEG patterns of TME.



EEGs are in bipolar montage

A: hepatic encephalopathy pattern, with slow activity (2-3Hz) and fluctuating triphasic waves (shown by the arrow), maximal over anterior regions, with reactivity to stimulation (shown by the vertical line)

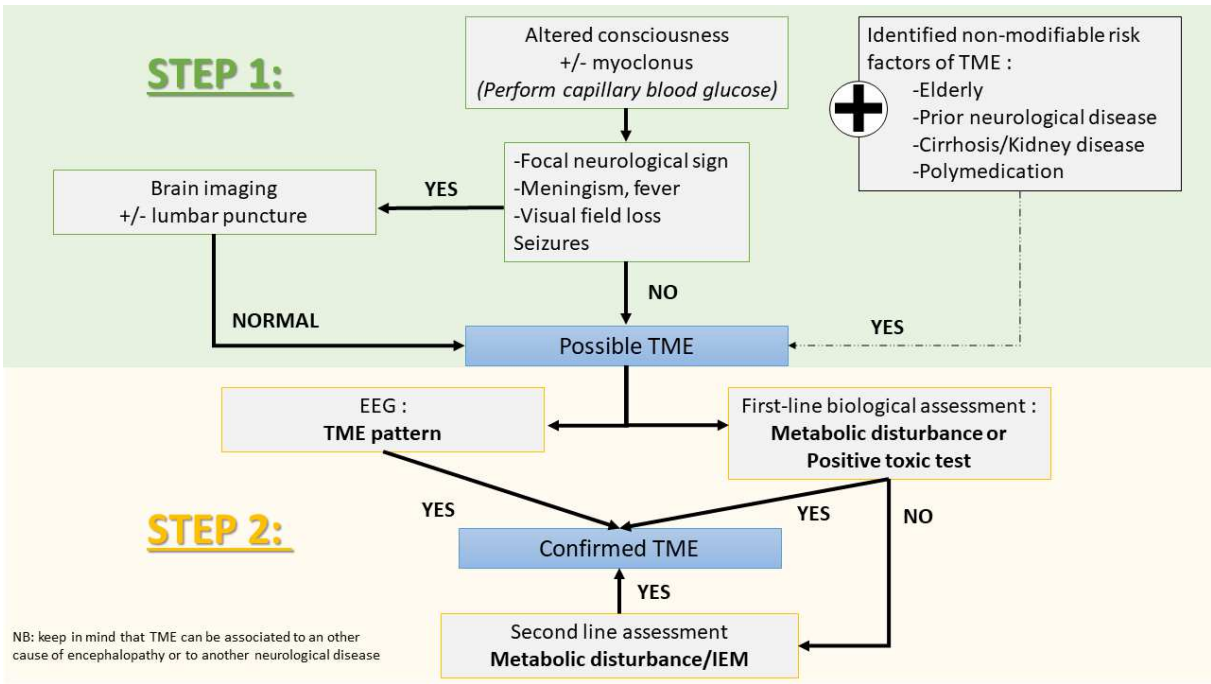
B: more severe hepatic encephalopathy pattern, with a continuous slow background activity, with no reactivity to stimulation (shown by the vertical line)

C: pseudo-periodic discharges with triphasic morphology, over the frontocentral area, in cefepime-induced encephalopathy

D: burst-suppression pattern: alternating episodes of isoelectric EEG and bursting slow waves, induced by thiopental

*Abbreviations: EEG: electroencephalography; TME: toxic-metabolic encephalopathy*

**Figure 2: Diagnostic algorithm for suspected toxic-metabolic encephalopathy**



Abbreviations: EEG: electroencephalography; TME: toxic-metabolic encephalopathy; IEM: inborn error of metabolism

**Table 1: Main causes of acquired TME.**

Metabolic encephalopathy	
Hepatic encephalopathy	Acute or chronic liver failure Portosystemic shunt
Hypercapnic encephalopathy	End-stage COPD Acute respiratory failure Diaphragmatic dysfunction
Uremic encephalopathy	Kidney failure
Electrolyte disturbances	Hyper/hyponatremia Hyper/hypocalcemia
Endocrine disorders	Hyper/hypoglycemia Hyper/hypothyroidism Hyper/hypocortisolism
Deficiency-related encephalopathy	Thiamin (vitamin B1) deficiency: Gayet-Wernicke's encephalopathy Niacin (vitamin B3 or PP) deficiency: pellagrous encephalopathy Pyridoxine (vitamin B6) deficiency Folate (vitamin B9) deficiency Cyanocobalamin (vitamin B12) deficiency Ascorbic acid (vitamin C) deficiency: scurvy Vitamin E deficiency (cerebellum)
Septic-associated encephalopathy	Sepsis, septic shock Acute pancreatitis, ARDS
Anoxic-ischemic encephalopathy	Cardiac arrest Shock
Toxic encephalopathy	
Drug-induced encephalopathy	see Table 3
Alcohol abuse	
Illicit drug abuse	Methamphetamine, heroin, cocaine, synthetic cathinones
Other toxic encephalopathy	Heavy metal (lead, manganese, mercury) Environmental agents (methanol, ethylene glycol, carbon monoxide) Organophosphate
Withdrawal syndrome	Alcohol Benzodiazepine ...

Abbreviation: ARDS, Acute Respiratory Distress Syndrome; COPD, Chronic obstructive Pulmonary Disease



**Table 2: Main drugs that could lead to toxic metabolic encephalopathy.**

Antiepileptics	Benzodiazepines Valproic acid* Barbiturates* Phenytoin Gabapentin Lacosamide Carbamazepine#
Psychiatric	Tricyclic antidepressants Selective serotonin reuptake inhibitors Neuroleptics Lithium
Oncologic	Methotrexate* L-asparaginase* 5-fluoro-uracil* Ifosfamide
Immunosuppressants	Calcineurin inhibitors Tacrolimus
Antimicrobial agents	Betalactams (including carbapenems, cefepime) Fluoroquinolone Metronidazole# Linezolid  Foscavir, aciclovir Interferon alpha  Fluconazole
Miscellaneous	Dopamine agonists Levodopa Opioids Proton pump inhibitors Baclofen Loperamide

\*can be associated with hyperammonemia; if associated with a P-gp inhibitor such as verapamil or proton pumps inhibitor  
#brain magnetic resonance imaging can be abnormal

**Table 3: Categories of inborn errors of metabolism in adults, with their main diagnostic investigations.**

<b>Intoxication by an endogenous substance</b>	
<b>Amino acid disorders</b>	Amino acids chromatography in blood and urine, homocysteine assay
<i>homocystinuria, leucinosi</i>	
<b>Organic acidurias</b>	Organic acids chromatography in blood and urine, acylcarnitine profile
<i>Isovaleric acidemia, methylmalonic acidemia (cobalamin disorders), methylmalonic acidemia (methylmalonyl-CoA mutase), methylmalonic acidemia (methylmalonyl-CoA mutase)</i>	
<b>Urea cycle defects</b>	Ammonemia, amino acids chromatography, urine orotic acid
<i>OTC, CPS, ASA</i>	
<b>Metal storage disorders</b>	Serum copper, ceruloplasmin, iron, ferritin, transferrin assay, hepatic biopsy, genetic testing
<i>Wilson disease, hemochromatosis, neurodegeneration with brain iron accumulation</i>	
<b>Porphyrias</b>	5-aminolevulinic acid, urinary porphobilinogen assay
<b>Energy deficiency</b>	
<b>Mitochondrial disorders</b>	Lactate/ pyruvate in blood and CSF, stress test, ENMG, muscle biopsy, genomic sequencing, molecular analyses, extra-neurological evaluations
<i>MERRF, MELAS, POLG, Leigh, Kearns-Sayre</i>	
<b>Glycogen storage diseases</b>	Hepatic/muscle biopsy, lactate level, genetic testing
<b>Disorders of fatty acid oxidation</b>	Organic acids chromatography, acylcarnitine profile
<i>Carnitine uptake defect/carnitine transport defect</i>	
<b>Deficiency of complex molecules synthesis or catabolism</b>	
<b>Peroxisomal disorders</b>	Phytanic acid, pristanic acid assay, serum very-long-chain fatty acid
<i>Refsum disease</i>	
<b>Lysosomal storage diseases</b>	Enzyme assay, genomic sequencing
<i>Gaucher disease, Fabry disease</i>	
<b>Congenital disorders of glycosylation</b>	Carbohydrate deficient transferrin and protein-linked glycan analysis, genomic sequencing

Abbreviations: CPS, carbamyl phosphate synthetase; MERRF: myoclonic epilepsy with ragged red fibers; MELAS: Mitochondrial Encephalomyopathy, Lactic Acidosis and Stroke-Like Episodes, OTC, ornithine transcarbamylase; CSF: cerebrospinal fluid ENMG: electroneuromyogram.

**Table 4: Differential diagnosis of TME, with clinical manifestations and complementary examinations.**

<b>Differential diagnosis</b>	<b>Clinical manifestations</b>	<b>Complementary examinations</b>
- <b>Infectious meningoencephalitis</b>	Fever Headache Meningismus Subacute onset Skin purpuric lesion	Lumbar puncture Brain imaging
<b>Autoimmune encephalitis</b>	Neuropsychiatric manifestations Seizures Movement disorders Autonomic dysfunction	Brain imaging Lumbar puncture Blood/CSF antibodies - neuronal cell-surface - synaptic receptors EEG
<b>Posterior reversible encephalopathy syndrome</b>	Headaches High blood pressure Elevated plasmatic creatinine	Brain imaging EEG
<b>Convulsive or non-convulsive status epilepticus</b>	Generalized or unilateral Myoclonus Seizures	EEG / cEEG
<b>Psychiatric or cognitive disorders</b>	Normal neurological examination	Psychiatric evaluation
<b>Cerebrovascular disease</b> - Ischemic stroke - Intracerebral hemorrhage - Subarachnoid hemorrhage - Cerebral venous thrombosis - Sub/extra-dural hematoma	Neurological focal sign Sudden onset Headache Possible intracranial Hypertension syndrome	Brain imaging
<b>Space occupying brain lesion</b> - Tumor - Abscess - Inflammatory lesion / ADEM	Neurological localization sign Chronic or subacute onset Intracranial hypertension syndrome	Brain imaging ± Lumbar puncture ± Brain biopsy

Abbreviations: ADEM: acute disseminated encephalomyelitis; CSF: cerebrospinal fluid; EEG: electroencephalogram; cEEG: continuous EEG.

## References

- [1] E. F. M. Wijdsicks, « Metabolic Encephalopathy: Behind the Name », *Neurocrit. Care*, vol. 29, n° 3, p. 385-387, déc. 2018, doi: 10.1007/s12028-017-0497-1.
- [2] A. J. C. Slooter *et al.*, « Updated nomenclature of delirium and acute encephalopathy: statement of ten Societies », *Intensive Care Med.*, vol. 46, n° 5, p. 1020-1022, 2020, doi: 10.1007/s00134-019-05907-4.
- [3] N. Weiss *et al.*, « Causes of coma and their evolution in the medical intensive care unit », *J. Neurol.*, vol. 259, n° 7, p. 1474-1477, juill. 2012, doi: 10.1007/s00415-011-6388-z.
- [4] M. W. B. Horsting, M. D. Franken, J. Meulenbelt, W. A. van Klei, et D. W. de Lange, « The etiology and outcome of non-traumatic coma in critical care: a systematic review », *BMC Anesthesiol.*, vol. 15, p. 65, avr. 2015, doi: 10.1186/s12871-015-0041-9.
- [5] Posner JB, Saper CB, Schiff N, Plum F., « Plum and Posner's diagnosis of stupor and coma. 4 edition Oxford; New York: Oxford University Press;2007 »,
- [6] C. Marois *et al.*, « [Metabolic encephalopathies] », *Rev. Med. Interne*, vol. 40, n° 2, p. 88-97, févr. 2019, doi: 10.1016/j.revmed.2018.11.006.
- [7] A. T. Meira, K. F. Alves, T. O. P. Rezende, A. O. Schelp, et L. E. Betting, « Source Analysis of Triphasic Waves Using Quantitative Neuroimaging », *J. Clin. Neurophysiol. Off. Publ. Am. Electroencephalogr. Soc.*, vol. Publish Ahead of Print, déc. 2020, doi: 10.1097/WNP.0000000000000804.
- [8] N. Weiss, R. Jalan, et D. Thabut, « Understanding hepatic encephalopathy », *Intensive Care Med.*, vol. 44, n° 2, p. 231-234, févr. 2018, doi: 10.1007/s00134-017-4845-6.
- [9] N. Weiss, F. Miller, S. Cazaubon, et P.-O. Couraud, « The blood-brain barrier in brain homeostasis and neurological diseases », *Biochim. Biophys. Acta*, vol. 1788, n° 4, p. 842-857, avr. 2009, doi: 10.1016/j.bbamem.2008.10.022.
- [10] N. Weiss *et al.*, « Cerebrospinal fluid metabolomics highlights dysregulation of energy metabolism in overt hepatic encephalopathy », *J. Hepatol.*, vol. 65, n° 6, p. 1120-1130, déc. 2016, doi: 10.1016/j.jhep.2016.07.046.
- [11] J. Witlox, L. S. M. Eurelings, J. F. M. de Jonghe, K. J. Kalisvaart, P. Eikelenboom, et W. A. van Gool, « Delirium in elderly patients and the risk of postdischarge mortality, institutionalization, and dementia: a meta-analysis », *JAMA*, vol. 304, n° 4, p. 443-451, juill. 2010, doi: 10.1001/jama.2010.1013.
- [12] B. T. Pun *et al.*, « Caring for Critically Ill Patients with the ABCDEF Bundle: Results of the ICU Liberation Collaborative in Over 15,000 Adults », *Crit. Care Med.*, vol. 47, n° 1, p. 3-14, janv. 2019, doi: 10.1097/CCM.00000000000003482.
- [13] J. Barr *et al.*, « Clinical practice guidelines for the management of pain, agitation, and delirium in adult patients in the intensive care unit », *Crit. Care Med.*, vol. 41, n° 1, p. 263-306, janv. 2013, doi: 10.1097/CCM.0b013e3182783b72.
- [14] P. P. Pandharipande, T. D. Girard, et E. W. Ely, « Long-term cognitive impairment after critical illness », *N. Engl. J. Med.*, vol. 370, n° 2, p. 185-186, janv. 2014, doi: 10.1056/NEJMc1313886.
- [15] N. Weiss *et al.*, « Modification in CSF specific gravity in acutely decompensated cirrhosis and acute on chronic liver failure independent of encephalopathy, evidences for an early blood-CSF barrier dysfunction in cirrhosis », *Metab. Brain Dis.*, vol. 32, n° 2, p. 369-376, avr. 2017, doi: 10.1007/s11011-016-9916-9.
- [16] M. Smith et G. Meyfroidt, « Critical illness: the brain is always in the line of fire », *Intensive Care Med.*, vol. 43, n° 6, p. 870-873, juin 2017, doi: 10.1007/s00134-017-4791-3.

- [17] R. D. Stevens et P. J. Pronovost, « The spectrum of encephalopathy in critical illness », *Semin. Neurol.*, vol. 26, n° 4, p. 440-451, sept. 2006, doi: 10.1055/s-2006-948325.
- [18] Y. Skrobik, C. Leger, M. Cossette, V. Michaud, et J. Turgeon, « Factors predisposing to coma and delirium: fentanyl and midazolam exposure; CYP3A5, ABCB1, and ABCG2 genetic polymorphisms; and inflammatory factors », *Crit. Care Med.*, vol. 41, n° 4, p. 999-1008, avr. 2013, doi: 10.1097/CCM.0b013e318275d014.
- [19] T. Wanek *et al.*, « Factors Governing P-Glycoprotein-Mediated Drug-Drug Interactions at the Blood-Brain Barrier Measured with Positron Emission Tomography », *Mol. Pharm.*, vol. 12, n° 9, p. 3214-3225, sept. 2015, doi: 10.1021/acs.molpharmaceut.5b00168.
- [20] J. Assaraf, N. Weiss, et D. Thabut, « Proton Pump Inhibitor Administration Triggers Encephalopathy in Cirrhotic Patients by Modulating Blood-Brain Barrier Drug Transport », *Gastroenterology*, vol. 152, n° 8, p. 2077, juin 2017, doi: 10.1053/j.gastro.2016.10.049.
- [21] G. Sechi et A. Serra, « Wernicke's encephalopathy: new clinical settings and recent advances in diagnosis and management », *Lancet Neurol.*, vol. 6, n° 5, p. 442-455, mai 2007, doi: 10.1016/S1474-4422(07)70104-7.
- [22] N. Weiss, C. Junot, M. Rudler, et D. Thabut, « Hepatic vs. drug-induced encephalopathy in cirrhotic patients? », *Liver Int. Off. J. Int. Assoc. Study Liver*, vol. 36, n° 8, p. 1233-1234, août 2016, doi: 10.1111/liv.13061.
- [23] E. F. Wijdicks, « Neurotoxicity of immunosuppressive drugs », *Liver Transplant. Off. Publ. Am. Assoc. Study Liver Dis. Int. Liver Transplant. Soc.*, vol. 7, n° 11, p. 937-942, nov. 2001, doi: 10.1053/jlts.2001.27475.
- [24] T. D. Singh, J. E. Fugate, et A. A. Rabinstein, « Central pontine and extrapontine myelinolysis: a systematic review », *Eur. J. Neurol.*, vol. 21, n° 12, p. 1443-1450, déc. 2014, doi: 10.1111/ene.12571.
- [25] J. Córdoba, J. Gottstein, et A. T. Blei, « Chronic hyponatremia exacerbates ammonia-induced brain edema in rats after portacaval anastomosis », *J. Hepatol.*, vol. 29, n° 4, p. 589-594, oct. 1998, doi: 10.1016/s0168-8278(98)80154-2.
- [26] J. Córdoba, R. García-Martinez, et M. Simón-Talero, « Hyponatremic and hepatic encephalopathies: similarities, differences and coexistence », *Metab. Brain Dis.*, vol. 25, n° 1, p. 73-80, mars 2010, doi: 10.1007/s11011-010-9172-3.
- [27] B. Zante, E. M. Hammel, A. Lauber, et J. C. Schefold, « "Chasing the dragon" on the intensive care unit », *Anaesthesiol. Intensive Ther.*, vol. 50, n° 3, p. 243, 2018, doi: 10.5603/AIT.a2018.0014.
- [28] N. Weiss *et al.*, « Peak hyperammonemia and atypical acute liver failure: The eruption of an urea cycle disorder during hyperemesis gravidarum », *J. Hepatol.*, sept. 2017, doi: 10.1016/j.jhep.2017.09.009.
- [29] F. Sedel, « [Inborn errors of metabolism in adult neurology] », *Rev. Neurol. (Paris)*, vol. 169 Suppl 1, p. S63-69, févr. 2013, doi: 10.1016/S0035-3787(13)70062-6.
- [30] J. Häberle *et al.*, « Suggested guidelines for the diagnosis and management of urea cycle disorders », *Orphanet J. Rare Dis.*, vol. 7, p. 32, mai 2012, doi: 10.1186/1750-1172-7-32.
- [31] E. F. M. Wijdicks, « Why you may need a neurologist to see a comatose patient in the ICU », *Crit. Care Lond. Engl.*, vol. 20, n° 1, p. 193, juin 2016, doi: 10.1186/s13054-016-1372-8.
- [32] D. A. Regier, E. A. Kuhl, et D. J. Kupfer, « The DSM-5: Classification and criteria changes », *World Psychiatry Off. J. World Psychiatr. Assoc. WPA*, vol. 12, n° 2, p. 92-98, juin 2013, doi: 10.1002/wps.20050.

- [33] E. F. M. Wijdicks, A. A. Rabinstein, W. R. Bamlet, et J. N. Mandrekar, « FOUR score and Glasgow Coma Scale in predicting outcome of comatose patients: a pooled analysis », *Neurology*, vol. 77, n° 1, p. 84-85, juill. 2011, doi: 10.1212/WNL.0b013e318220ac06.
- [34] S. Mouri *et al.*, « FOUR score, a reliable score for assessing overt hepatic encephalopathy in cirrhotic patients », *Neurocrit. Care*, vol. 22, n° 2, p. 251-257, avr. 2015, doi: 10.1007/s12028-014-0078-5.
- [35] E. W. Ely *et al.*, « Delirium in mechanically ventilated patients: validity and reliability of the confusion assessment method for the intensive care unit (CAM-ICU) », *JAMA*, vol. 286, n° 21, p. 2703-2710, déc. 2001, doi: 10.1001/jama.286.21.2703.
- [36] G. Pal, M. M. Lin, et R. Laureno, « Asterixis: a study of 103 patients », *Metab. Brain Dis.*, vol. 29, n° 3, p. 813-824, sept. 2014, doi: 10.1007/s11011-014-9514-7.
- [37] V. Krishnan, L. Y. Leung, et L. R. Caplan, « A neurologist's approach to delirium: diagnosis and management of toxic metabolic encephalopathies », *Eur. J. Intern. Med.*, vol. 25, n° 2, p. 112-116, févr. 2014, doi: 10.1016/j.ejim.2013.11.010.
- [38] M. Rudler, C. Marois, N. Weiss, D. Thabut, V. Navarro, et Brain-Liver Pitié-Salpêtrière Study Group (BLIPS), « Status epilepticus in patients with cirrhosis: How to avoid misdiagnosis in patients with hepatic encephalopathy », *Seizure*, vol. 45, p. 192-197, févr. 2017, doi: 10.1016/j.seizure.2016.12.011.
- [39] I. I. Berisavac *et al.*, « How to recognize and treat metabolic encephalopathy in Neurology intensive care unit », *Neurol. India*, vol. 65, n° 1, p. 123, janv. 2017, doi: 10.4103/0028-3886.198192.
- [40] C. Mulligan et J. M. Bronstein, « Wilson Disease: An Overview and Approach to Management », *Neurol. Clin.*, vol. 38, n° 2, p. 417-432, mai 2020, doi: 10.1016/j.ncl.2020.01.005.
- [41] M. R. Dobbs, « Toxic encephalopathy », *Semin. Neurol.*, vol. 31, n° 2, p. 184-193, avr. 2011, doi: 10.1055/s-0031-1277989.
- [42] American Association for the Study of Liver Diseases et European Association for the Study of the Liver, « Hepatic encephalopathy in chronic liver disease: 2014 practice guideline by the European Association for the Study of the Liver and the American Association for the Study of Liver Diseases », *J. Hepatol.*, vol. 61, n° 3, p. 642-659, sept. 2014, doi: 10.1016/j.jhep.2014.05.042.
- [43] K. Weissenborn, C. Ehrenheim, A. Hori, S. Kubicka, et M. P. Manns, « Pallidal lesions in patients with liver cirrhosis: clinical and MRI evaluation », *Metab. Brain Dis.*, vol. 10, n° 3, p. 219-231, sept. 1995, doi: 10.1007/BF02081027.
- [44] J. A. Edlow, A. Rabinstein, S. J. Traub, et E. F. M. Wijdicks, « Diagnosis of reversible causes of coma », *Lancet Lond. Engl.*, vol. 384, n° 9959, p. 2064-2076, déc. 2014, doi: 10.1016/S0140-6736(13)62184-4.
- [45] A. R. Tunkel *et al.*, « 2017 Infectious Diseases Society of America's Clinical Practice Guidelines for Healthcare-Associated Ventriculitis and Meningitis », *Clin. Infect. Dis. Off. Publ. Infect. Dis. Soc. Am.*, vol. 64, n° 6, p. e34-e65, mars 2017, doi: 10.1093/cid/ciw861.
- [46] J. E. Fugate et A. A. Rabinstein, « Posterior reversible encephalopathy syndrome: clinical and radiological manifestations, pathophysiology, and outstanding questions », *Lancet Neurol.*, vol. 14, n° 9, p. 914-925, sept. 2015, doi: 10.1016/S1474-4422(15)00111-8.
- [47] F. Graus *et al.*, « A clinical approach to diagnosis of autoimmune encephalitis », *Lancet Neurol.*, vol. 15, n° 4, p. 391-404, avr. 2016, doi: 10.1016/S1474-4422(15)00401-9.

- [48] F. Plum et J. B. Posner, « [The diagnosis of stupor and coma] », *Brain Nerve Shinkei Kenkyu No Shinpo*, vol. 67, n° 3, p. 344-345, mars 2015.
- [49] A. Sakusic *et al.*, « Features of Adult Hyperammonemia Not Due to Liver Failure in the ICU », *Crit. Care Med.*, vol. 46, n° 9, p. e897-e903, sept. 2018, doi: 10.1097/CCM.0000000000003278.
- [50] M. Mallet, N. Weiss, D. Thabut, et M. Rudler, « Why and when to measure ammonia in cirrhosis? », *Clin. Res. Hepatol. Gastroenterol.*, vol. 42, n° 6, p. 505-511, déc. 2018, doi: 10.1016/j.clinre.2018.01.004.
- [51] C. Legouy *et al.*, « Ureaplasma parvum causes hyperammonemia presenting as refractory status epilepticus after kidney transplant », *J. Crit. Care*, vol. 57, p. 79-83, juin 2020, doi: 10.1016/j.jcrc.2020.02.003.
- [52] N. Weiss *et al.*, « A urinary cause of coma », *J. Neurol.*, vol. 258, n° 5, p. 941-943, mai 2011, doi: 10.1007/s00415-010-5850-7.
- [53] N. Weiss *et al.*, « Cerebrospinal fluid metabolomics highlights dysregulation of energy metabolism in overt hepatic encephalopathy », *J. Hepatol.*, vol. 65, n° 6, p. 1120-1130, déc. 2016, doi: 10.1016/j.jhep.2016.07.046.
- [54] F. Imbert-Bismut *et al.*, « Transportation and handling of blood samples prior to ammonia measurement in the real life of a large university hospital », *Clin. Chim. Acta Int. J. Clin. Chem.*, vol. 510, p. 522-530, nov. 2020, doi: 10.1016/j.cca.2020.07.048.
- [55] A. M. de Oliveira *et al.*, « Imaging Patterns of Toxic and Metabolic Brain Disorders », *Radiogr. Rev. Publ. Radiol. Soc. N. Am. Inc*, vol. 39, n° 6, p. 1672-1695, oct. 2019, doi: 10.1148/rg.2019190016.
- [56] D. Farmakiotis et B. Zeluff, « IMAGES IN CLINICAL MEDICINE. Metronidazole-Associated Encephalopathy », *N. Engl. J. Med.*, vol. 374, n° 15, p. 1465, avr. 2016, doi: 10.1056/NEJMicm1505174.
- [57] H. Mori *et al.*, « Reversible splenial lesion in the corpus callosum following rapid withdrawal of carbamazepine after neurosurgical decompression for trigeminal neuralgia », *J. Clin. Neurosci. Off. J. Neurosurg. Soc. Australas.*, vol. 19, n° 8, p. 1182-1184, août 2012, doi: 10.1016/j.jocn.2011.09.017.
- [58] B. Hermann, M. Rudler, D. Galanaud, D. Thabut, et N. Weiss, « Magnetic resonance spectroscopy: A surrogate marker of hepatic encephalopathy? », *J. Hepatol.*, vol. 71, n° 5, p. 1055-1057, nov. 2019, doi: 10.1016/j.jhep.2019.07.008.
- [59] B. G. Parsons-Smith, W. H. Summerskill, A. M. Dawson, et S. Sherlock, « The electroencephalograph in liver disease », *Lancet Lond. Engl.*, vol. 273, n° 7001, p. 867-871, nov. 1957, doi: 10.1016/s0140-6736(57)90005-3.
- [60] P. Amodio *et al.*, « Electroencephalographic analysis for the assessment of hepatic encephalopathy: comparison of non-parametric and parametric spectral estimation techniques », *Neurophysiol. Clin. Clin. Neurophysiol.*, vol. 39, n° 2, p. 107-115, avr. 2009, doi: 10.1016/j.neucli.2009.02.002.
- [61] P. Marchetti *et al.*, « Electroencephalography in patients with cirrhosis », *Gastroenterology*, vol. 141, n° 5, p. 1680-1689.e1-2, nov. 2011, doi: 10.1053/j.gastro.2011.06.085.
- [62] R. Faigle, R. Sutter, et P. W. Kaplan, « The electroencephalography of encephalopathy in patients with endocrine and metabolic disorders », *J. Clin. Neurophysiol. Off. Publ. Am. Electroencephalogr. Soc.*, vol. 30, n° 5, oct. 2013, doi: 10.1097/WNP.0b013e3182a73db9.
- [63] H.-T. Li *et al.*, « Clinical, Electroencephalographic Features and Prognostic Factors of Cefepime-Induced Neurotoxicity: A Retrospective Study », *Neurocrit. Care*, vol. 31, n° 2, p. 329-337, oct. 2019, doi: 10.1007/s12028-019-00682-y.

- [64] J. D. Triplett, N. D. Lawn, J. Chan, et J. W. Dunne, « Cephalosporin-related neurotoxicity: Metabolic encephalopathy or non-convulsive status epilepticus? », *J. Clin. Neurosci. Off. J. Neurosurg. Soc. Australas.*, vol. 67, p. 163-166, sept. 2019, doi: 10.1016/j.jocn.2019.05.035.
- [65] C. R. Newey, P. George, A. Sarwal, N. So, et S. Hantus, « Electro-Radiological Observations of Grade III/IV Hepatic Encephalopathy Patients with Seizures », *Neurocrit. Care*, vol. 28, n° 1, p. 97-103, févr. 2018, doi: 10.1007/s12028-017-0435-2.
- [66] J. Claassen *et al.*, « Recommendations on the use of EEG monitoring in critically ill patients: consensus statement from the neurointensive care section of the ESICM », *Intensive Care Med.*, vol. 39, n° 8, p. 1337-1351, août 2013, doi: 10.1007/s00134-013-2938-4.
- [67] S. T. Herman *et al.*, « Consensus Statement on Continuous EEG in Critically Ill Adults and Children, Part I: Indications », *J. Clin. Neurophysiol. Off. Publ. Am. Electroencephalogr. Soc.*, vol. 32, n° 2, p. 87-95, avr. 2015, doi: 10.1097/WNP.000000000000166.
- [68] D. M. W. Hilkmann, W. N. K. A. van Mook, W. H. Mess, et V. H. J. M. van Kranen-Mastenbroek, « The Use of Continuous EEG Monitoring in Intensive Care Units in The Netherlands: A National Survey », *Neurocrit. Care*, vol. 29, n° 2, p. 195-202, oct. 2018, doi: 10.1007/s12028-018-0525-9.
- [69] G. B. Young et G. S. Doig, « Continuous EEG monitoring in comatose intensive care patients: epileptiform activity in etiologically distinct groups », *Neurocrit. Care*, vol. 2, n° 1, p. 5-10, 2005, doi: 10.1385/NCC:2:1:005.
- [70] N. Wiwattanadittakul *et al.*, « The utility of EEG monitoring in neonates with hyperammonemia due to inborn errors of metabolism », *Mol. Genet. Metab.*, vol. 125, n° 3, p. 235-240, nov. 2018, doi: 10.1016/j.ymgme.2018.08.011.
- [71] L. E. Payne *et al.*, « Cefepime-induced neurotoxicity: a systematic review », *Crit. Care Lond. Engl.*, vol. 21, n° 1, p. 276, nov. 2017, doi: 10.1186/s13054-017-1856-1.
- [72] J. Ehler *et al.*, « The prognostic value of neurofilament levels in patients with sepsis-associated encephalopathy - A prospective, pilot observational study », *PloS One*, vol. 14, n° 1, p. e0211184, 2019, doi: 10.1371/journal.pone.0211184.
- [73] B. Mathon *et al.*, « Neurological diseases of unknown etiology: Brain-biopsy diagnostic yields and safety », *Eur. J. Intern. Med.*, vol. 80, p. 78-85, oct. 2020, doi: 10.1016/j.ejim.2020.05.029.
- [74] B. Mathon, M. Pineton de Chambrun, F. Bielle, A. Amelot, et A. Le Joncour, « Encephalitis of Unknown Etiology? Not Until the Results of a Brain Biopsy! », *Clin. Infect. Dis. Off. Publ. Infect. Dis. Soc. Am.*, vol. 72, n° 9, p. e432, mai 2021, doi: 10.1093/cid/ciaa1093.
- [75] M. Tarailo-Graovac *et al.*, « Exome Sequencing and the Management of Neurometabolic Disorders », *N. Engl. J. Med.*, vol. 374, n° 23, p. 2246-2255, juin 2016, doi: 10.1056/NEJMoa1515792.
- [76] A. Roux, D. Lison, C. Junot, et J.-F. Heilier, « Applications of liquid chromatography coupled to mass spectrometry-based metabolomics in clinical chemistry and toxicology: A review », *Clin. Biochem.*, vol. 44, n° 1, p. 119-135, janv. 2011, doi: 10.1016/j.clinbiochem.2010.08.016.
- [77] Y. Jouan *et al.*, « Effects of mean arterial pressure on arousal in sedated ventilated patients with septic shock: a SEPSISPAM post hoc exploratory study », *Ann. Intensive Care*, vol. 9, n° 1, p. 54, mai 2019, doi: 10.1186/s13613-019-0528-5.
- [78] W. D. Schweickert *et al.*, « Early physical and occupational therapy in mechanically ventilated, critically ill patients: a randomised controlled trial », *Lancet Lond. Engl.*, vol. 373, n° 9678, p. 1874-1882, mai 2009, doi: 10.1016/S0140-6736(09)60658-9.



- [79] T. D. Girard *et al.*, « Haloperidol and Ziprasidone for Treatment of Delirium in Critical Illness », *N. Engl. J. Med.*, vol. 379, n° 26, p. 2506-2516, déc. 2018, doi: 10.1056/NEJMoa1808217.
- [80] V. Lavergne *et al.*, « The EXTRIP (EXtracorporeal TReatments In Poisoning) workgroup: guideline methodology », *Clin. Toxicol. Phila. Pa*, vol. 50, n° 5, p. 403-413, juin 2012, doi: 10.3109/15563650.2012.683436.
- [81] K. McMartin, D. Jacobsen, et K. E. Hovda, « Antidotes for poisoning by alcohols that form toxic metabolites », *Br. J. Clin. Pharmacol.*, vol. 81, n° 3, p. 505-515, mars 2016, doi: 10.1111/bcp.12824.
- [82] S. C. Howard, J. McCormick, C.-H. Pui, R. K. Buddington, et R. D. Harvey, « Preventing and Managing Toxicities of High-Dose Methotrexate », *The Oncologist*, vol. 21, n° 12, p. 1471-1482, déc. 2016, doi: 10.1634/theoncologist.2015-0164.
- [83] A. Küpfer, C. Aeschlimann, B. Wermuth, et T. Cerny, « Prophylaxis and reversal of ifosfamide encephalopathy with methylene-blue », *Lancet Lond. Engl.*, vol. 343, n° 8900, p. 763-764, mars 1994, doi: 10.1016/s0140-6736(94)91839-2.
- [84] J. A. Frontera, « Metabolic encephalopathies in the critical care unit », *Contin. Minneap. Minn*, vol. 18, n° 3, p. 611-639, juin 2012, doi: 10.1212/01.CON.0000415431.07019.c2.
- [85] O. Braissant, V. Rackayová, K. Pierzchala, J. Grosse, V. A. McLin, et C. Cudalbu, « Longitudinal neurometabolic changes in the hippocampus of a rat model of chronic hepatic encephalopathy », *J. Hepatol.*, vol. 71, n° 3, p. 505-515, sept. 2019, doi: 10.1016/j.jhep.2019.05.022.
- [86] M. J. Owen *et al.*, « Rapid Sequencing-Based Diagnosis of Thiamine Metabolism Dysfunction Syndrome », *N. Engl. J. Med.*, vol. 384, n° 22, p. 2159-2161, juin 2021, doi: 10.1056/NEJMc2100365.