



**HAL**  
open science

## **Botulism mimicking Miller Fisher syndrome: Clinical and pathophysiological discussion of a case**

Charlotte Calligaris, Clémence Marois, Karine Viala, Thierry Gendre, Alain Créange, Sophie Demeret, Benjamin Rohaut

► **To cite this version:**

Charlotte Calligaris, Clémence Marois, Karine Viala, Thierry Gendre, Alain Créange, et al.. Botulism mimicking Miller Fisher syndrome: Clinical and pathophysiological discussion of a case. 2023. hal-04002934

**HAL Id: hal-04002934**

**<https://hal.sorbonne-universite.fr/hal-04002934v1>**

Preprint submitted on 23 Feb 2023

**HAL** is a multi-disciplinary open access archive for the deposit and dissemination of scientific research documents, whether they are published or not. The documents may come from teaching and research institutions in France or abroad, or from public or private research centers.

L'archive ouverte pluridisciplinaire **HAL**, est destinée au dépôt et à la diffusion de documents scientifiques de niveau recherche, publiés ou non, émanant des établissements d'enseignement et de recherche français ou étrangers, des laboratoires publics ou privés.

# Botulism mimicking Miller Fisher syndrome: Clinical and pathophysiological discussion of a case

**Charlotte Calligaris<sup>1,\*</sup>, Clémence Marois<sup>1,\*</sup>, Karine Viala<sup>2</sup>, Thierry Gendre<sup>3</sup>, Alain Créange<sup>3</sup>, Sophie Demeret<sup>1</sup>, Benjamin Rohaut<sup>1,4,5</sup>**

\*These authors contributed equally to this work

<sup>1</sup> AP-HP, Groupe Hospitalier Universitaire APHP-Sorbonne Université, site Pitié-Salpêtrière, Department of Neurology, Neuro-ICU, Paris, France

<sup>2</sup> AP-HP, Groupe Hospitalier Universitaire APHP-Sorbonne Université, site Pitié-Salpêtrière, Department of Neurophysiology, Paris, France

<sup>3</sup> AP-HP, Hôpital Henri-Mondor, Department of Neurology, Créteil, France

<sup>4</sup> Sorbonne Université, Paris, France

<sup>5</sup> Brain institute - ICM, Sorbonne Université, Inserm U1127, CNRS UMR 7225, F-75013, Paris, France

An 81-year-old woman was admitted to the stroke unit for acute diplopia. She had no history of neurologic or cardiovascular disease. Physical examination showed a left mydriasis, a ptosis and a slight abduction of the left eye. Brain MRI ruled out ischemic stroke.

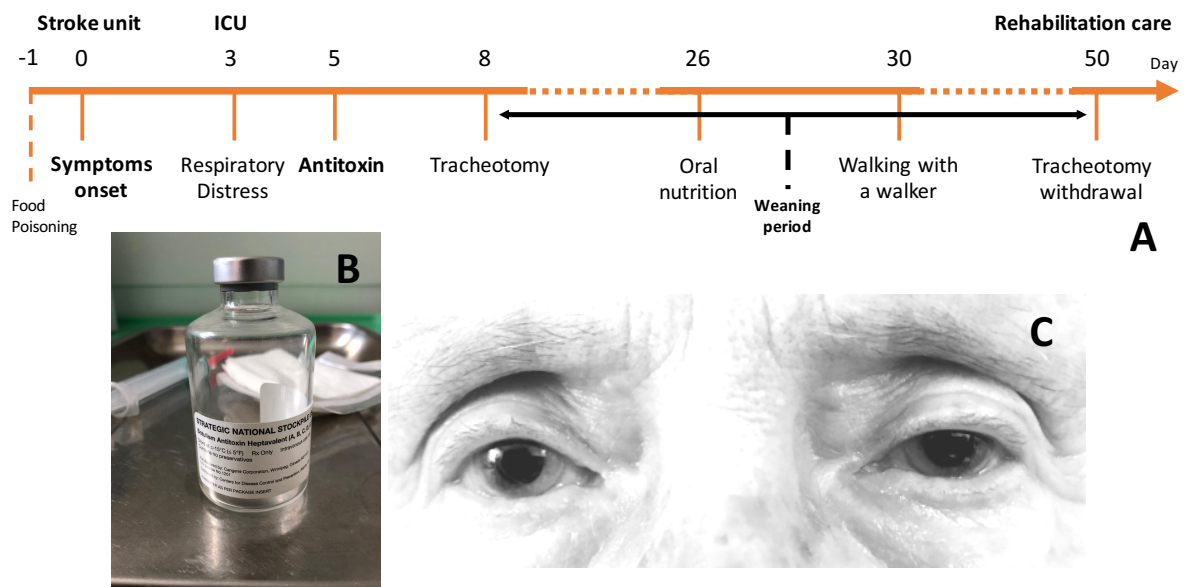
On day 2 after first symptoms, facial diplegia with complete bilateral ptosis, ophthalmoplegia, bilateral mydriasis, dysphonia and soft palate paresis appeared. There were no motor or sensory deficit or ataxia, nor areflexia. Cerebrospinal fluid exam showed a white-cell count  $<1/\text{mm}^3$  and 0.49g/L of proteins. Electrophysiological study was unremarkable.

At day 3, respiratory distress leads the patient to intensive care unit for mechanical ventilation. Gradual worsening continued with tetraparesia and dysautonomia (blood pressure lability, digestive disorder, dry eye and mouth syndrome). Electrophysiological study on day 4 showed a 60% decrease of the compound muscle

action potentials in the upper limbs. Sensory and motor conduction velocities were preserved. Low frequency repetitive stimulation was normal. Results were compatible with an acute motor axonal neuropathy. Intravenous immunoglobulin therapy was initiated.

At day 5, botulinum toxin type A was positive in the serum and in a canned soup eaten 24 hours before symptoms onset. Heptavalent antitoxin was administered.

Clinical condition improved gradually in a month (figure 1). 3 months later, the patient was at home with only a persisting dry mouth.



**Figure 1. Foodborne botulism in an 81-year-old patient.**

- A. Time line from symptoms onset to rehabilitation care.
- B. Botulism antitoxin heptavalent. Administer by slow intravenous infusion after dilution 1 :10 in normal saline at the dose of 0,5mL/min until 2mL/min if well-tolerated (for adult).
- C. Bilateral mydriasis with ptosis and ophthalmoplegia.

Botulism is a rare and potentially lethal neuromuscular disorder that shares clinical features with Miller Fisher syndrome. Bigaut and al, recently reported a similar case and discussed clinical and molecular mimicry between both diseases<sup>1</sup>.

Botulism is caused by botulinum toxin produced by *Clostridium botulinum*, an anaerobic gram-positive bacillus. After ingestion, toxin reaches the presynaptic nerve terminal, binding to its membrane and internalizing by the way of gangliosides and synaptic vesicles proteins<sup>2</sup>. After translocation, it interferes and cleaves SNARE proteins involving in exocytosis machinery, leading to the inhibition of the acetylcholine's release, to muscle contraction impairment and autonomic nerve dysfunction. Nerve conduction studies show a presynaptic neuromuscular blockade. However, decremental response to low frequency repetitive stimulation can be missing. High frequency repetitive stimulation > 20Hz is required looking for an incremental response or facilitation which is more frequent<sup>3</sup>. Toxin detection in the serum, stool or suspected food source confirms the diagnosis.

Supportive care in an intensive care unit and rapid administration of antitoxin are the keys to successful therapy. Heptavalent antitoxin derived from equine plasma is currently used. Neutralizing free-circulation toxin, it prevents symptom progression without reversing paralysis nor speeding recovery. Therefore, the earlier the administration the better<sup>4</sup>, but clinical benefit of late administration persists if symptoms worsen. In France, antitoxin is part of national products reserve which could be necessary for management of health alerts. It is available after specific administrative process of nominative temporary authorization of use (ATUn) which may lead to a delay after receiving product. Patients receiving antitoxin should be monitored for hypersensitivity reactions and adverse events, but usually treatment is well tolerated. Current antitoxin purification methods have lowered the risk of anaphylaxis, less than 1-2%<sup>5</sup>.

Early recognition of botulism is primordial for patient prognosis. Oriented nerves conduction studies can help for diagnosis but should not delay treatment initiation.

Antitoxin should be administered upon clinical suspicion as soon as possible, even if diagnosis confirmation could not be performed.

## References

1. Bigaut K, Kremer L, Hacquard A, Collongues N, De Seze J. Miller Fisher syndrome mimicking botulism: Clinical and pathophysiological discussion of a case. *Revue Neurologique* 2019;175(6):403–5.
2. Verderio C, Rossetto O, Grumelli C, Frassoni C, Montecucco C, Matteoli M. Entering neurons: botulinum toxins and synaptic vesicle recycling. *EMBO Rep* 2006;7(10):995–9.
3. Kongsangdao S, Samintarapanya K, Rasmeechan S, Sithinamsuwan P, Tanprawate S. Electrophysiological diagnosis and patterns of response to treatment of botulism with neuromuscular respiratory failure. *Muscle Nerve* 2009;40(2):271–8.
4. O'Horo JC, Harper EP, El Rafei A, et al. Efficacy of Antitoxin Therapy in Treating Patients With Foodborne Botulism: A Systematic Review and Meta-analysis of Cases, 1923–2016. *Clinical Infectious Diseases* 2018;66(suppl\_1):S43–56.
5. Yu PA, Lin NH, Mahon BE, et al. Safety and Improved Clinical Outcomes in Patients Treated With New Equine-Derived Heptavalent Botulinum Antitoxin. *Clinical Infectious Diseases* 2018;66(suppl\_1):S57–64.

## ACKNOWLEDGMENTS

The authors thank Dr Pierre Jaquet (Pitié Salpêtrière Neuro-ICU), Dr Nicolas Weiss (Pitié-Salpêtrière Neuro-ICU), Dr Christelle Mazuet (CNR Bactéries anaérobies et Botulisme Institut Pasteur, Paris) and Dr Florence Morel (Laboratoire de Bactériologie-Hygiène, AP-HP, Groupe Hospitalier Universitaire APHP-Sorbonne Université, site Pitié-Salpêtrière, Paris) for their help in the management of this patient.