



**HAL**  
open science

## Mismatch Repair Deficiency and Lynch Syndrome Among Adult Patients With Glioma

Patrick R Benusiglio, Fikret Elder, Mehdi Touat, Alexandre Perrier, Marc Sanson, Chrystelle Colas, Lea Guerrini-Rousseau, Duy Thanh Tran, Nesrine Trabelsi, Catherine Carpentier, et al.

► **To cite this version:**

Patrick R Benusiglio, Fikret Elder, Mehdi Touat, Alexandre Perrier, Marc Sanson, et al.. Mismatch Repair Deficiency and Lynch Syndrome Among Adult Patients With Glioma. *JCO precision oncology*, 2023, 7, 10.1200/PO.22.00525 . hal-04115776

**HAL Id: hal-04115776**

**<https://hal.sorbonne-universite.fr/hal-04115776>**

Submitted on 2 Jun 2023

**HAL** is a multi-disciplinary open access archive for the deposit and dissemination of scientific research documents, whether they are published or not. The documents may come from teaching and research institutions in France or abroad, or from public or private research centers.

L'archive ouverte pluridisciplinaire **HAL**, est destinée au dépôt et à la diffusion de documents scientifiques de niveau recherche, publiés ou non, émanant des établissements d'enseignement et de recherche français ou étrangers, des laboratoires publics ou privés.

## **Mismatch repair deficiency and Lynch syndrome among 1225 adult patients with glioma.**

Patrick R Benusiglio MD PhD <sup>1,2\*</sup>, Fikret Elder MD <sup>1</sup>, Mehdi Touat MD PhD <sup>2,3,4</sup>, Alexandre Perrier MD <sup>1,2</sup>, Marc Sanson MD PhD <sup>3,4</sup>, Chrystelle Colas MD PhD <sup>5,6</sup>, Lea Guerrini-Rousseau MD <sup>7,8</sup>, Duy Thanh Tran MD <sup>9,10</sup>, Nesrine Trabelsi PhD <sup>4</sup>, Catherine Carpentier PhD <sup>4</sup>, Yannick Marie PhD <sup>4</sup>, Clovis Adam MD <sup>11</sup>, Michèle Bernier MD <sup>12</sup>, Dominique Cazals-Hatem <sup>13</sup>, Karima Mokhtari MD <sup>4,9</sup>, Suzanne Tran MD <sup>4,9</sup>, Bertrand Mathon MD PhD <sup>14</sup>, Laurent Capelle MD <sup>14</sup>, Marion Dhooge MD <sup>15</sup>, Ahmed Idbaih MD PhD <sup>3</sup>, Agusti Alentorn MD MD <sup>3,4</sup>, Caroline Houillier MD <sup>3</sup>, Caroline Dehais MD <sup>3</sup>, Khe Hoang-Xuan MD PhD <sup>3,4</sup>, Stefania Cuzzubbo MD PhD <sup>16</sup>, Antoine Carpentier MD PhD <sup>16</sup>, Alex Duval MD PhD <sup>2</sup>, Florence Coulet PharmD PhD <sup>1,2</sup>, and Franck Bielle MD PhD <sup>4,9</sup>.

1. Département de Génétique Médicale et Institut Universitaire de Cancérologie, Hôpital Pitié-Salpêtrière, AP-HP, Sorbonne Université, 47-83 Boulevard de l'Hôpital, F-75013 Paris, France.

2. Sorbonne Université, INSERM, Unité Mixte de Recherche Scientifique 938 et SIRIC CURAMUS, Centre de Recherche Saint-Antoine (CRSA), Equipe Instabilité des Microsatellites et Cancer, Equipe labellisée par la Ligue Nationale contre le Cancer, 184 rue du Faubourg Saint-Antoine, F-75012 Paris, France.

3. Service de Neurologie 2 Mazarin, Hôpital Pitié-Salpêtrière, AP-HP, Sorbonne Université, 47-83 Boulevard de l'Hôpital, F-75013 Paris, France.

4. Sorbonne Université, Institut du Cerveau - Paris Brain Institute - ICM, Inserm, CNRS, SIRIC CURAMUS, Onconeurothèque, AP-HP 47-83 Boulevard de l'Hôpital, F-75013, Paris, France

5. Département de Génétique, Institut Curie, F-75005 Paris, France

6. INSERM U830, U 830 Unité de génétique et biologie des cancers, Institut Curie et Université de Paris, F-75005, Paris, France

7. Département de Cancérologie de l'Enfant et de l'Adolescent, Gustave Roussy, Université Paris-Saclay, Villejuif, France

8. Molecular Predictors and New Targets in Oncology, INSERM U981 Team "Genomics and Oncogenesis of pediatric Brain Tumors", Gustave Roussy, Université Paris-Saclay, Villejuif, France.

9. Service de Neuropathologie Raymond Escourolle, Hôpital Pitié-Salpêtrière, AP-HP, Sorbonne Université. 47-83 Boulevard de l'Hôpital, F-75013 Paris, France.

10. Department of Pathology, VietDuc university hospital, Hoan Kiem, Hanoi, Vietnam.

11. Service d'anatomopathologie, CHU de Bicêtre, AP-HP, 78 rue du Général-Leclerc, 94275 Le Kremlin-Bicêtre, France.

12. Département d'Anatomie et Cytologie Pathologiques, Hôpital Foch, 92151 Suresnes, France.

13. Département d'Anatomie Pathologique, Hôpital Beaujon, AP-HP, Université de Paris, 92110 Clichy, France.

14. Service de Neurochirurgie, Hôpital Pitié-Salpêtrière, AP-HP, Sorbonne Université, 47-83 Boulevard de l'Hôpital, F-75013 Paris, France.

15. Gastroentérologie et Oncologie Digestive, Hôpital Cochin, AP-HP, Université Paris Cité, F-75014 Paris, France.

16. Service de Neurologie, Hôpital Saint-Louis, AP-HP, Université Paris Cité, F-75010 Paris, France.

\*Corresponding author : [patrick.benusiglio@aphp.fr](mailto:patrick.benusiglio@aphp.fr), [patrick.benusiglio@cantab.net](mailto:patrick.benusiglio@cantab.net) , twitter @PBenusiglio

## Abstract

**Introduction:** The Lynch syndrome (LS)-glioma association is poorly documented. As for Mismatch Repair-deficiency (MMRd) in glioma, a hallmark of LS-associated tumors, there are only limited data available. We determined MMRd and LS prevalence in a large series of unselected gliomas, and explored the associated characteristics. Both have major implications in terms of treatment, screening and prevention.

**Methods:** Somatic next generation sequencing was performed on 1225 treatment-naïve adult gliomas referred between 2017 and 06.2022. For gliomas with  $\geq 1$  MMR pathogenic variant (PV), MMR immunohistochemistry (IHC) was done. Gliomas with  $\geq 1$  PV and protein expression loss were considered MMRd. Eligible patients had germline testing. To further explore MMRd specifically in glioblastomas, IDH-wild type (wt), we performed IHC, and complementary sequencing when indicated, in a series of tumors diagnosed over the 2007-2021 period.

**Results:** Nine gliomas were MMRd (9/1225, 0.73%). Age at glioma diagnosis was  $< 50$  for all but one case. Eight were glioblastomas, IDH-wt, and one was an astrocytoma, IDH-mutant. *ATRX* (n=5) and *TP53* (n=8) PV were common. There were no *TERT* promoter PV or *EGFR* amplification. LS prevalence was 5/1225 (0.41%). One 77-year old patient was a known LS case. Four cases had a novel LS diagnosis, with germline PV in *MSH2* (n=3) and *MLH1* (n=1). One additional patient had *PMS2*-associated CMMRD. Germline testing was negative in three MSH6-deficient tumors. In the second series of glioblastomas, IDH-wt, MMRd prevalence was 12.5% in the  $<40$ -year age group, 2.6% in the 40-49 year group, and 1.6% the  $\geq 50$  year group .

**Conclusion:** Screening for MMRd and LS should be systematic in glioblastomas, IDH-wt diagnosed under the age of 50.

## **Context Summary**

### **Key objective**

To determine the frequency of mismatch repair deficiency (MMRd) and Lynch Syndrome (LS) in a large series of unselected adult glioma patients, and to describe the associated histological, molecular and clinical characteristics.

### **Knowledge Generated**

Of 1225 gliomas, nine were MMRd (0.73%) with a mean age at diagnosis of 35. Eight MMRd gliomas were glioblastomas, IDH-wild type (wt), and one was an astrocytoma, IDH-mutant. Among these MMRd gliomas, we identified five LS (5/1225, 0.41%), four of them novel diagnoses. Another patient had Constitutional Mismatch Repair Deficiency. All cases with a hereditary cancer syndrome had glioblastoma, IDH-wt. We estimated age-based MMRd prevalence specifically in glioblastoma, IDH-wt. It was 12.5% in the under-40 year age group, and 2.6% in the 40-50 age group.

### **Relevance**

Our study will guide practice regarding MMRd and LS screening in gliomas. We would recommend screening in all glioblastomas, IDH-wt diagnosed under the age of 50.

## Introduction

The Lynch syndrome (LS) - glioma association is poorly documented. An excess of gliomas was reported as far back as 1996 in the Dutch Hereditary Non-Polyposis Colorectal Cancer registry, although some early-onset cases likely had Constitutional Mismatch Repair Deficiency (CMMRD), i.e. they carried bi-allelic germline mismatch repair (MMR) pathogenic variants (PV), and not one <sup>1</sup>. In the Prospective LS Database, cumulative brain tumor incidence was 0%-7.7% by age 75 depending on gene and gender, the risk being highest in male *MSH2* PV carriers <sup>2</sup>. There are limited data regarding the overall LS prevalence among unselected gliomas. In a pan-cancer study, there were three LS cases among 923 patients with a variety of central nervous system tumors <sup>3</sup>. The exact number of gliomas was not specified.

LS-associated tumors are characterized by MMR deficiency (MMRd). In a series of 740 brain tumors, Korean researchers identified MMRd in thirteen, eleven of which were treatment-naïve (11/740, 1.5%) <sup>4</sup>. The most common type was glioblastoma, IDH-wildtype (wt).

Of note, not all MMRd tumors are associated with LS, regardless of site, as the phenotype can be caused by purely somatic genetic events in the MMR genes.

The WHO classification of central nervous system tumors distinguishes three main histomolecular types of adult diffuse glioma: glioblastoma, IDH-wt, astrocytoma IDH-mutant, and oligodendroglioma IDH-mutant and 1p/19q codeleted <sup>5,6</sup>. A primary MMR deficient IDH-mutant astrocytoma entity associated with LS and CMMRD has been reported in children, adolescents and young adults <sup>7</sup>. However, more generally, MMRd and LS according to glioma type and age at diagnosis are poorly described, and there are few recommendations regarding screening.

LS and MMRd are therefore rare in glioma. However, both are of major importance considering their implications in terms of screening, prevention and treatment. LS identification allows for personalized cancer screening and risk-reduction, in the index case and in relatives who subsequently turn out to carry the PV. As for MMRd, it is associated with resistance to temozolomide, the most commonly used drug in neuro-oncology, while possibly predicting response to immunotherapy <sup>8</sup>.

Unlike colorectal and endometrial cancer, there are no clear guidelines regarding universal or criteria-based screening for MMRd and LS in gliomas. We have been performing routine somatic next generation sequencing (NGS) of gliomas since 2017, and complementary immunohistochemistry (IHC) whenever  $\geq 1$  MMR PV is present. The combination of somatic PV and negative IHC (loss of protein expression) defines MMRd. In this study, we report the prevalence of MMRd in 1225 treatment-naïve gliomas, along with the outcomes of downstream germline testing. Our objective was to determine the frequency of MMRd and LS among a large series of unselected adult glioma patients, and to describe the associated histological, molecular and clinical characteristics.

## **Methods**

### *Patient selection*

We studied all treatment-naïve adult gliomas diagnosed by or referred to (second opinion) neuropathologists at Pitié-Salpêtrière Hospital, AP-HP, Sorbonne Université, Paris between January 2017 and June 2022, and analyzed by a custom next-generation sequencing panel.

### *Somatic next generation sequencing (NGS)*

The capture-based panel of 1 Mb included the most frequent glioma genetic alterations (*IDH1/2*, *TP53*, *ATRX*, *TERT* promoter, *H3F3A*, *HIST1H3B*, *BRAF*, *FGFR1*, *EGFR*, *NF1*, *PIK3CA*) and the MMR coding and exon-intron boundaries sequences. Seventy-five bp paired-end sequencing was performed on NextSeq 500 (Illumina). MMR gene variants were classified pathogenic if they were annotated as such in ClinVar (missense, splicing site variants) or if they led to a truncated or absent protein (nonsense, frameshift, and start sites variants). Variants of unknown significance were not considered. We used MSIsensor2 to evaluate microsatellite instability (MSI) based on NGS data. MSIsensor2 was used at the default setting with the recommended cutoff value of  $\geq 20\%$  <sup>9</sup>. MSI status was also assessed with pentaplex polymerase chain reaction (PCR), and the following five quasimonomorphic mononucleotide repeats: BAT26, BAT25, NR21, NR24 and NR27.

### *IHC*

Four micrometres-thick formalin-fixed paraffin-embedded tissue sections were deparaffinized and immunolabeled by a fully automatic Ventana benchmark Ultra System (Roche, Basel, Switzerland), using a streptavidin-peroxidase complex with diaminobenzidine as the chromogen and the following primary antibodies: ATRX (Mouse Monoclonal, clone BSB-108, Diagnostics, 1/100), IDH1 R132H (mouse monoclonal, clone QM002, Diagnostics, 1/100), p53 (mouse monoclonal, clone DO-7, 1/100), MLH1 (mouse monoclonal, clone M1, Roche Ventana, prediluted), MSH2 (mouse monoclonal, clone G219-1129, Roche Ventana, prediluted), MSH6 (rabbit monoclonal, clone SP93, Roche Ventana, prediluted), PMS2 (mouse monoclonal, clone A16-4, Roche Ventana, prediluted). An IDH1 R132H and p53 immunostaining positive control was added to each slide. MMRd controls with protein expression loss were also added to each slide.



Gliomas with  $\geq 1$  MMR PV and matching protein expression loss on IHC were considered MMRd. Patients with an MMRd glioma were referred to Oncogenetics for genetic counseling and germline analysis.

#### *Germline testing*

MMR coding sequences were enriched by capture and sequenced via a multigene panel<sup>10</sup>. Libraries were prepared according to the Kapa sample preparation protocol (Kapa Biosystems®). They were pooled and captured using the SeqCap EZ Choice Library (Roche/NimbleGen, Madison, WI) according to the manufacturer's protocol and sequenced using an Illumina Platform (Illumina, San Diego, CA). PV and copy number variations were confirmed by Sanger sequencing and MLPA, respectively.

All MMRd glioma patients had signed a consent form for germline testing, and agreed to the possibility of further research on hereditary cancer syndromes (HCS). They, or their next of kin, were also informed of this study with a possibility to opt out. French law waives ethics committee approval for retrospective non-interventional studies, as long as subjects are informed in writing.

#### *MMRd in glioblastoma, IDH-wt according to age*

Most MMRd and all LS-associated gliomas turned out to be glioblastomas, IDH-wt (see Results). All but one patients were under 50 years at diagnosis, all but three under 40. This type is rare in young adults, but becomes more common as people get older, with a median age at diagnosis of 64<sup>5</sup>. These observations suggested that early-onset glioblastoma, IDH-wt was a red flag for MMRd and LS, and required validation. We therefore further explored MMRd specifically in glioblastoma, IDH-wt by carrying out MMR IHC in an series of 257 treatment-naïve tumors diagnosed over a longer period (2007- 2021), and complementary NGS when protein expression was lost. All glioblastomas,

IDH-wt diagnosed under the age of 40 were analyzed, along with a random subset of tumors diagnosed at later ages.

### *Statistical analysis*

Discrete variables were compared by the Fisher test. Continuous variables were analysed by the Mann-Whitney and Kruskal Wallis tests, for comparisons between two and more than two groups, respectively. Tests were performed with StatView 5.0 software.

## **Results**

### *Glioma series description*

We included 1225 gliomas (figure 1). There were 708 males and 517 females. The median age at diagnosis was 50 (range 17-92). Main tumor types were: glioblastoma, IDH-wildtype (n=559, 46%); astrocytoma, IDH-mutant (n=228, 19%); oligodendroglioma, IDH-mutant and 1p/19q codeleted (n=150, 12%); diffuse astrocytoma, IDH-wildtype not elsewhere classified (n=38, 3%); diffuse midline glioma, H3K27-altered (n=16, 1%) and diffuse hemispheric glioma, G34-mutant (n=9, 1%). Mean age at diagnosis significantly differed between tumor types ( $p < 10^{-4}$ ). It was for example 59 for glioblastoma, IDH-wildtype (range 18–87), 38 for astrocytoma, IDH-mutant (range 19–77) and 47 for oligodendroglioma, IDH-mutant and 1p/19q codeleted (range 24–80).

### *MMRd glioma characteristics*

$\geq 1$  somatic MMR PV was found in 9/1225 gliomas (0.73%) (figure 2 and table 1). Mean age at diagnosis was 35 (range 19-77), and all but one had a diagnosis under the age of 50. The genes involved were *MSH2* (n=4), *MSH6* (n=3), *MLH1* (n=1), *PMS2* (n=1) (table 1). IHC was concordant in all tumors, as protein expression loss matched the PV. These gliomas were thus considered MMRd. Expression was also lost in the *PMS2*-associated glioma normal tissue, suggesting CMMRD.

Eight tumors were glioblastomas, IDH-wt, two of them of the giant cell subtype (figure 3), representing 1.4% of glioblastomas, IDH-wt (8/559, 1.4%). Median age at diagnosis was significantly lower than for MMR-proficient tumors of this type (28 vs. 59,  $p=0.0016$ ). *ATRX* PV were present in four glioblastomas, IDH-wt, and were associated with protein expression loss in three of them. Seven tumors also had somatic *TP53* PV, with IHC positivity in six. Oncogenic driver variants involved the PI3K/AKT/mTOR ( $n=5$ ), and the Mitogen Activated Protein Kinase pathways ( $n=3$ ). The normally common glioblastoma, IDH-wildtype genetic alterations, i.e. *TERT* promoter PV and *EGFR* amplification, were not observed. These molecular features, along with other genetic alterations, are detailed in Figure 1.

The remaining MMRd glioma was an astrocytoma, IDH-mutant, grade 4. It had been diagnosed in a nineteen year-old female. Age corresponds to the first percentile of age distribution in astrocytomas, IDH-mutant. The tumor was characterized by somatic *ATRX* and *TP53* PV, with *ATRX* protein expression loss and *TP53* positivity, which are common in this histological type.

Five MMRd gliomas were classified MSI by MSIsensor2 (5/9, 56%), but none using pentaplex PCR.

### *LS diagnoses*

The overall LS prevalence was 5/1225 (0.41%). A 77-year old patient with an *MSH2* MMRd glioma turned out to be a known LS case with a past medical history of colorectal cancer. Eight patients (out of 9 with an MMRd glioma) were therefore referred for germline testing (figure 1). Five had a new HCS diagnosis: LS (n=4) and CMMRD (n=1) (table 1). None had a personal history of cancer. Three carried a monoallelic PV in *MSH2*, one in *MLH1*. The CMMRD case, a 19 year-old male, was compound heterozygote for *PMS2* PV.

Mean age at glioma diagnosis in the novel LS cases was 31 (range 22-47), all had glioblastoma, IDH-wt. None had a first-degree relative with a LS-associated cancer history. However, all cases had one second-degree relative with a cancer history compatible with LS: colorectal (2), urinary tract and pancreatic cancer at the ages of 63, 58, 75 and 50, respectively. We do not know however whether these relatives carried the MMR PV.

MMRd in the novel LS cases was attributable to two MMR genetic events, either two PV (germline and somatic), or one germline PV associated with loss of heterozygosity (table 1). The large germline deletion in *MSH2* had been missed by somatic NGS (table 1, patient 2), but the associated somatic frameshift variant had been detected. Similarly, somatic NGS had not identified the *PMS2* exon 8 deletion on the CMMRD patient (table 1, patient 6), only subsequently identified in the germline.

Germline testing was negative for the three cases with *MSH6*-associated glioma. Two somatic *MSH6* PV were observed in one, while the other had LOH for the first variant. In the third case, an

*MSH6* variant of unknown significance was seen in the tumor alongside the PV, although we do not know whether this was the second hit.

#### *MMRd in glioblastoma, IDH-wt according to age*

To further explore the hypothesis that early-onset glioblastoma, IDH-wt was suggestive of MMRd and LS, we performed MMR IHC on 257 glioblastomas, IDH-wt, enriched for early-onset tumors and diagnosed over the 2007-2021 period. These 257 did not include the nine MMRd gliomas previously identified, and reported throughout this manuscript. Expression loss was observed in three additional tumors (3/257, 1.2%), with ages at diagnosis of 19, 32 and 56 years. These three cases had been diagnosed before 2017, and therefore had not been included in the initial unselected 1225-glioma series. We subsequently confirmed MMRd by NGS. The 56 year-old case was a known LS patient. Germline testing information is not available for the remaining two.

In these complementary IHC-NGS analyses, we included all glioblastomas, IDH-wt diagnosed under the age of 40. Two under-40 MMRd cases were thus identified, in addition to the six that were part of the first unselected 1225-case series, out of a total of 64 (table 2). The estimated MMRd prevalence in glioblastoma, IDH-wt diagnosed under the age of 40, was therefore 12.5% (8/64). A random selection of tumors diagnosed at later ages was also studied. The estimated MMRd prevalence was 2.6% (2/76) in the 40-49 year group, and 1.6% (2/126) the  $\geq 50$  year group (table 2).

#### **Discussion**

This is one of the largest studies to date on MMRd and LS in gliomas. We first analyzed somatic NGS results for gliomas referred between 2017 and June 2022. For tumors with  $\geq 1$  MMR PV, we performed IHC to confirm MMRd, and germline testing when indicated. 9/1225 gliomas were MMRd (0.73%) Of these, five patients had LS (0.41% of the total). There was also one CMMRD.

Eight out of nine MMRd gliomas were glioblastomas, IDH-wt. Two were of the giant cell subtype. As for molecular characteristics, *TP53* PV were seen in most glioblastomas, IDH-wild type, and *ATRX* PV in half. There were neither *TERT* promoter PV nor *EGFR* amplification. The latter two observations are surprising, considering that *TERT* PV and *EGFR* amplification are found in 80% and 40% of these tumors, respectively <sup>6</sup>. All five LS cases and the CMMRD patient had glioblastoma, IDH-wt. The remaining MMRd glioma was an astrocytoma, IDH-mutant, in a 19 year-old woman, with associated *ATRX* and *TP53* PV. This observation is consistent with previous reports that MMRd astrocytoma, IDH-mutant, is a disease of children, adolescents and very young adults <sup>7</sup>.

Microsatellite instability was only detected in five MMRd gliomas using MSISensor2, but in none using pentaplex testing. Currently MSI detection methods perform poorly in glioma, and novel, sensitive methods are therefore needed.

Among the MMRd gliomas, we identified five LS (0.41% of the total), four of them novel, and one CMMRD. Novel LS cases were young (age range 22-47) and had no previous cancer history. Family history was of limited utility, as there were no 1<sup>st</sup>-degree relatives with a history of LS-associated cancer. There were however cancers with a possible link to LS in 2<sup>nd</sup>-degree relatives. Genetic susceptibility to glioma is a topic of growing interest. Yap *et al.* recently identified MMR germline PV in 10/2377 patients with brain tumors (0.4%) <sup>11</sup>, a prevalence similar to the LS prevalence observed here.

Most MMRd gliomas in our study were glioblastomas, IDH-wt. However, MMRd was rare overall in this type (8/559, 1.4%). Patients' characteristics suggested that young age at diagnosis was the best predictor of MMRd and LS. To validate these observations, we estimated age-based prevalence of MMRd specifically for the glioblastoma, IDH-wt type, by performing MMR IHC on a series of tumors diagnosed over a longer period, and somatic NGS when indicated. It was 12.5% in patients aged under 40, 2.6% in the 40-49 year group, and 1.6% in older cases. The only two over-50 cases were known LS patients, with past medical histories of associated cancers.

We would advocate systematic screening for MMRd and LS using somatic sequencing and/or IHC in all patients with glioblastoma, IDH-wt diagnosed under the age of 50, followed by germline testing when indicated. In older patients, screening might be justified in the presence of previous medical and family history of LS-associated cancers. Importantly, none of the following characteristics seem predictive of MMRd: giant cell histology, ATRX expression loss, P53 overexpression.

As for astrocytoma, IDH-mutant, we would suggest screening for cases diagnosed before the age of 25. Further studies including more adolescents and young adults with gliomas, IDH-mutant are needed to better determine a screening age threshold. A specific methylation class is described for primary MMR deficient IDH-mutant astrocytoma<sup>7</sup>. Methylome-based classification might therefore guide MMRd screening in these tumors.

In this study, IHC was concordant with somatic NGS, as reported previously<sup>12</sup>.

MMRd exploration and LS screening have not been standard practice so far, although things are changing rapidly. For example, only twelve gliomas were tested by MMR IHC at a world-class cancer genetics center over a 20-year period<sup>13</sup>. The NCCN guidelines consider LS screening in gliomas in

general without recommending it <sup>14</sup>. A universal approach would however seem resource and time-consuming for a very low detection rate.

We acknowledge the following limitations. We did routine somatic NGS in all cases diagnosed under the age of 70. However, it was not systematic in older patients with glioblastoma, IDH-wt (the most common type in this age category), as age or comorbidities would sometimes have precluded systemic treatment or inclusion in precision oncology trials. As a result, the median age at diagnosis of glioblastoma IDH-wt in our cohort is lower than what is reported in the literature, 59 versus 64 years <sup>6</sup>. In this context, we might have missed MMRd and LS cases among older patients. Another limitation pertains to somatic NGS itself. We cannot be certain to have identified all MMR PV. Indeed, NGS only had suboptimal sensitivity to identify large deletions, as illustrated by the germline *MSH2* and *PMS2* deletions that were only detected in the germline.

MMRd not only suggests LS. It also has therapeutic implications, as it decreases sensitivity to temozolomide, the drug used routinely in glioma patients, while possibly predicting response to immunotherapy <sup>15,16</sup>. Those immediate consequences warrant fast MMRd screening whenever indicated.

We expect that our study will improve awareness of MMRd and LS in glioma among the different specialties involved in the care of neuro-oncology patients. More than ever, in an era of multidisciplinary management and precision medicine, the involvement of all is paramount.

## **Funding**

FB is funded by INCA-DGOS-Inserm\_12560 SiRIC CURAMUS which is financed by the French National Cancer Institute, the French Ministry of Solidarity and Health and the National Institute for



Science and Medical Research (INSERM). FB has received a high-risk/high-gain grant from the French National Cancer Institute to support the development of therapies for MMRd gliomas

### **Conflicts of Interest**

Patrick R Benusiglio has received honoraria from the following pharmaceutical companies: AstraZeneca, MSD, and BMS.

### **Data availability statement**

Data are available upon reasonable request, pending a data transfer agreement between Assistance Publique – Hôpitaux de Paris and the applicant's institution.

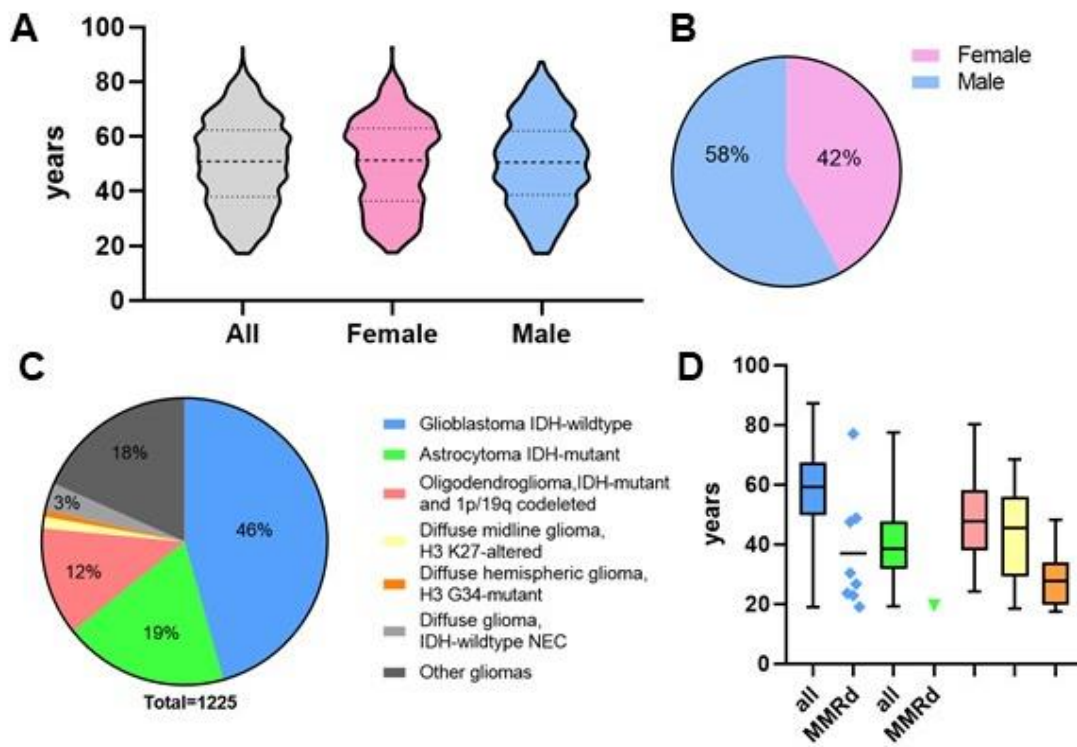
## References

1. Vasen HFA, Sanders EA, Taal BG, et al. The risk of brain tumours in hereditary non-polyposis colorectal cancer (HNPCC). *Int J Cancer*. 1996;65(4):422-425. doi:10.1002/(SICI)1097-0215(19960208)65:4<422::AID-IJC4>3.0.CO;2-Z
2. Dominguez-Valentin M, Sampson JR, Seppälä TT, et al. Cancer risks by gene, age, and gender in 6350 carriers of pathogenic mismatch repair variants: findings from the Prospective Lynch Syndrome Database. *Genet Med*. 2020;22(1):15-25. doi:10.1038/s41436-019-0596-9
3. Latham A, Srinivasan P, Kemel Y, et al. Microsatellite Instability Is Associated With the Presence of Lynch Syndrome Pan-Cancer. *J Clin Oncol*. 2019;37(4):286-295. doi:10.1200/JCO.18.00283
4. Kim H, Lim KY, Park JW, et al. Sporadic and Lynch syndrome-associated mismatch repair-deficient brain tumors. *Lab Invest*. 2022;102(2):160-171. doi:10.1038/s41374-021-00694-3
5. Louis DN, Perry A, Reifenberger G, et al. The 2016 World Health Organization Classification of Tumors of the Central Nervous System: a summary. *Acta Neuropathol (Berl)*. 2016;131(6):803-820. doi:10.1007/s00401-016-1545-1
6. Perez A, Huse JT. The Evolving Classification of Diffuse Gliomas: World Health Organization Updates for 2021. *Curr Neurol Neurosci Rep*. 2021;21(12):67. doi:10.1007/s11910-021-01153-8
7. Suwala AK, Stichel D, Schrimpf D, et al. Primary mismatch repair deficient IDH-mutant astrocytoma (PMMRDIA) is a distinct type with a poor prognosis. *Acta Neuropathol (Berl)*. 2021;141(1):85-100. doi:10.1007/s00401-020-02243-6
8. Prost D, Bielle F, Ligon KL, Touat M. Mutational burden and immune recognition of gliomas. *Curr Opin Oncol*. 2021;33(6):626. doi:10.1097/CCO.0000000000000787
9. Niu B, Ye K, Zhang Q, et al. MSIsensor: microsatellite instability detection using paired tumor-normal sequence data. *Bioinformatics*. 2014;30(7):1015-1016. doi:10.1093/bioinformatics/btt755
10. Dhooge M, Baert-Desurmont S, Corsini C, et al. National recommendations of the French Genetics and Cancer Group - Unicancer on the modalities of multi-genes panel analyses in hereditary predispositions to tumors of the digestive tract. *Eur J Med Genet*. 2020;63(12):104080. doi:10.1016/j.ejmg.2020.104080
11. Yap TA, Ashok A, Stoll J, et al. Prevalence of Germline Findings Among Tumors From Cancer Types Lacking Hereditary Testing Guidelines. *JAMA Netw Open*. 2022;5(5):e2213070. doi:10.1001/jamanetworkopen.2022.13070
12. McCord M, Steffens A, Javier R, Kam KL, McCortney K, Horbinski C. The efficacy of DNA mismatch repair enzyme immunohistochemistry as a screening test for hypermutated gliomas. *Acta Neuropathol Commun*. 2020;8(1):15. doi:10.1186/s40478-020-0892-2
13. Evans DG, Lalloo F, Ryan NA, et al. Advances in genetic technologies result in improved diagnosis of mismatch repair deficiency in colorectal and endometrial cancers. *J Med Genet*. 2022;59(4):328-334. doi:10.1136/jmedgenet-2020-107542

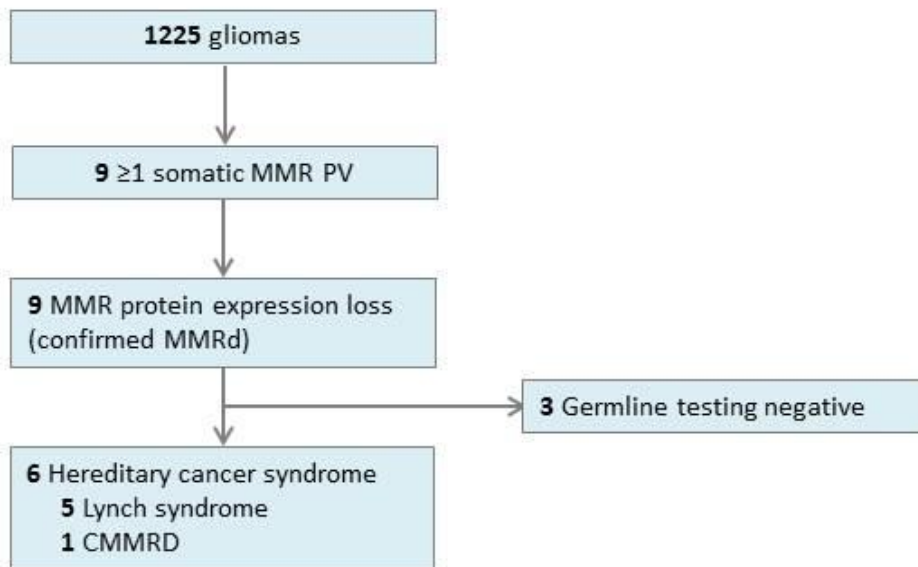
14. National Comprehensive Cancer Network. Genetic/Familial High-Risk Assessment: Colorectal (Version 1.2022). Accessed July 19, 2022.  
[https://www.nccn.org/professionals/physician\\_gls/pdf/genetics\\_colon.pdf](https://www.nccn.org/professionals/physician_gls/pdf/genetics_colon.pdf)
15. Bouffet E, Larouche V, Campbell BB, et al. Immune Checkpoint Inhibition for Hypermutant Glioblastoma Multiforme Resulting From Germline Biallelic Mismatch Repair Deficiency. *J Clin Oncol*. 2016;34(19):2206-2211. doi:10.1200/JCO.2016.66.6552
16. Touat M, Li YY, Boynton AN, et al. Mechanisms and therapeutic implications of hypermutation in gliomas. *Nature*. 2020;580(7804):517-523. doi:10.1038/s41586-020-2209-9

**Figure 1. Age distribution and pathological and molecular features of 1225 gliomas analyzed by NGS.**

A. Age distribution. B. Sex ratio. C. Pathological and molecular features. D. Age distribution according to type.



**Figure 2.** Study flowchart. MMR, mismatch-repair; CMMRD, constitutional MMR deficiency; PV, pathogenic variant.

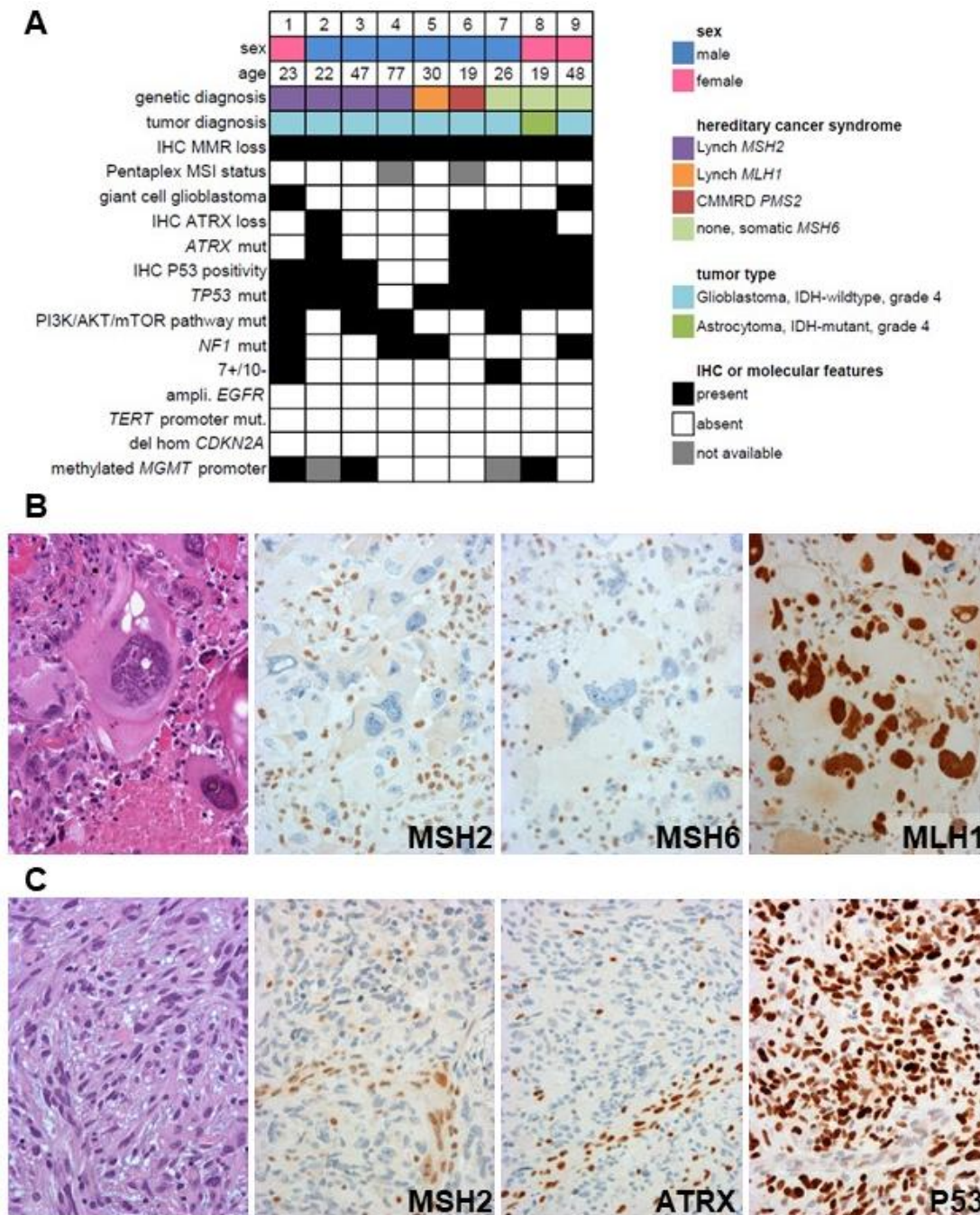


**Table 1.** MMR-deficient gliomas. Somatic, IHC and germline results with tumor and patient characteristics. CMMRD, constitutional mismatch repair deficiency. HCS, hereditary cancer syndrome. LOH, loss of heterozygosity. LS, Lynch syndrome. Wt, wild-type. <sup>§</sup>Missed in the tumor by somatic NGS (large deletion). <sup>#</sup>Patient with known Lynch syndrome prior to the glioma diagnosis. Variant description was based on HGVS guidelines using human genome GRCh37 and reference sequences *MSH2* (NM\_000251.3), *MLH1* (NM\_000249.4), *MSH6* (NM\_000179.3), *PMS2* (NM\_000535.7).

Sex	Age	IDH	Somatic MMR PV LOH, if observed	IHC, expression loss	Germline result	HCS	
1	F	23	wt	<i>MSH2</i> c.970C>T; p.(Gln324*) <i>MSH2</i> c.772C>T; p.(Gln258*)	MSH2/MSH6	<i>MSH2</i> c.970C>T; p.(Gln324*)	LS
2	M	22	wt	<i>MSH2</i> c.1861C>T; p.(Arg621*)	MSH2/MSH6	<i>MSH2</i> exons 9-10 deletion <sup>§</sup>	LS
3	M	47	wt	<i>MSH2</i> c.1221_1222del; p.(Tyr 408Serfs*8) LOH	MSH2/MSH6	<i>MSH2</i> c.1221_1222del; p.(Tyr 408Serfs*8)	LS
4 <sup>#</sup>	M	77	wt	<i>MSH2</i> c.1528C>T; p.(Gln510*)	MSH2/MSH6	<i>MSH2</i> c.1528C>T; p.(Gln510*)	LS
5	M	30	wt	<i>MLH1</i> c.949del; p.(Leu317Cysfs*50) LOH	MLH1/PMS2	<i>MLH1</i> c.949del; p.(Leu317Cysfs*50)	LS
6	M	19	wt	<i>PMS2</i> c.2T>C; p.Met1?	PMS2	<i>PMS2</i> c.2T>C; p.Met1? <i>PMS2</i> exon 8 deletion <sup>§</sup>	CMMRD
7	M	26	wt	<i>MSH6</i> c.377C>A; p.(Ser126*) LOH	MSH6	-	-
8	F	19	mutant	<i>MSH6</i> c.3103C>T; p.(Arg1035*)	MSH6	-	-
9	F	48	wt	<i>MSH6</i> c.829G>T; p.(Glu277*) <i>MSH6</i> c.3261del; p.(Phe1088Serfs*2)	MSH6	-	-

**Figure 3. Pathological and molecular features of the MMRd tumors identified among 1225 unselected gliomas.**

A. Features, by case. B. MMRd glioblastoma, IDH-wt of the giant cell subtype (case 1). MSH2 and MSH6 expression is lost in tumor cells but maintained in smaller immune cells. MLH1 expression is maintained in all cells. C. MMRd glioblastoma, IDH-wt grade 4 with fusiform astrocytic tumor cells (case 2). Expression of MSH2 and ATRX is lost in tumor cells and maintained in vascular wall cells. P53 is highly expressed in tumor cells in accordance with the somatic *TP53* missense pathogenic variant.



**Figure 3**

**Table 2.** Complementary analyses: Mismatch repair deficiency (MMRd) specifically in 266 glioblastoma IDH-wildtype by age category. Number and proportion of tumors tested and testing results. .

<b>Age category (years)</b>	<b>18-39</b>	<b>40-49</b>	<b>≥50</b>
IDH-wt glioblastoma (total n)	64	211	1430
Tested for MMRd (n)	64	76	126
Tested for MMRd (%)	100%	36%	9%
MMRd (n)	8	2	2
MMRd (% of tested)	12.5%	2.6%	1.6%