



HAL
open science

Cholangioscopy for biliary diseases

Aymeric Becq, Adil Soualy, Marine Camus

► **To cite this version:**

Aymeric Becq, Adil Soualy, Marine Camus. Cholangioscopy for biliary diseases. *Current Opinion in Gastroenterology*, 2023, 39 (2), pp.67-74. 10.1097/MOG.0000000000000907 . hal-04117126

HAL Id: hal-04117126

<https://hal.sorbonne-universite.fr/hal-04117126v1>

Submitted on 5 Jun 2023

HAL is a multi-disciplinary open access archive for the deposit and dissemination of scientific research documents, whether they are published or not. The documents may come from teaching and research institutions in France or abroad, or from public or private research centers.

L'archive ouverte pluridisciplinaire **HAL**, est destinée au dépôt et à la diffusion de documents scientifiques de niveau recherche, publiés ou non, émanant des établissements d'enseignement et de recherche français ou étrangers, des laboratoires publics ou privés.



Cholangioscopy for biliary diseases

Aymeric Becq^a, Adil Soualy^b and Marine Camus^c

Purpose of review

Cholangioscopy is a mini-invasive endoscopic procedure, which consists in a direct intraductal visualization of the biliary tract. The purpose of this review is to summarize the technique, the clinical applications, as well as future perspectives of cholangioscopy.

Recent findings

Numerous technologic advances during the last decades have allowed for an improved utility and functionality, leading to a broader use of this procedure, for diagnostic or therapeutic purposes, in the setting of biliary diseases. Novel tools and emerging indications have been developed and more are yet to come.

Summary

Cholangioscopy can be performed by peroral, percutaneous transhepatic or intra-operative transcystic or transcholedochal access. Clinical applications of cholangioscopy are multiple, ranging from visual impression and optical guided biopsies of indeterminate biliary strictures to the management of difficult stones, guidance before biliary stenting and retrieval of migrated ductal stents. Multiple devices such as lithotripsy probes, biopsy forceps, snares and baskets have been developed to help achieve these procedures successfully.

Cholangioscopy has improved the way biliary diseases can be visualized and treated. New technology, accessories, and applications are expected in the future.

Keywords

benign biliary stricture, biliary stones, cholangioscopy, endoscopic retrograde cholangiopancreatography, malignant biliary stricture

INTRODUCTION

Cholangioscopy or choledochoscopy is an endoscopic procedure, which consists in a direct intraductal visualization of the biliary tract. It was first developed during the 1970s. Improvements made over the years have allowed for a broader use of this procedure, for diagnostic or therapeutic purposes, in the setting of biliary diseases [1]. This technique is set to be increasingly utilized in the future, as demand is rising and most interventional endoscopists are getting accustomed to its use and indications demand.

Applications are multiple, ranging from visual impression and optical guided biopsies of indeterminate biliary strictures (as recommended by the European Society of Gastrointestinal Endoscopy [ESGE]) to difficult stone management, guidance before biliary stenting and retrieval of migrated ductal stents [2,3].

In clinical practice, a prospective multicenter study, published in 2022 including 369 patients showed that this procedure is performed for diagnostic and therapeutic purposes in the same proportion, with a success rate of 97.6%. Adverse events, mostly of mild or moderate severity, occur in 10% of cases,

which is comparable to standard endoscopic retrograde cholangiopancreatography (ERCP) [4].

In this review, we will focus on the technical aspects of this procedure, its indications in the setting of biliary diseases, as well as its most recent innovations.

TECHNIQUES

Cholangioscopy can be performed by peroral (POCS), percutaneous transhepatic (PTCS) or intra-operative transcystic or transcholedochal access with various devices [2] (Fig. 1 and Table 1).

^aParis-Est Créteil University, Gastroenterology Department, Henri Mondor Hospital, Créteil, ^bGastroenterology Department, Avicenne Hospital, Bobigny and ^cSorbonne Université, INSERM, Centre de Recherche Saint-Antoine (CRSA), & Assistance Publique-Hôpitaux de Paris (AP-HP), Endoscopy Unit, Saint Antoine Hospital, Paris, France

Correspondence to Marine Camus, MD, PhD, Pr, Endoscopy Unit, Saint Antoine Hospital, 184 rue du faubourg St Antoine, 75012 Paris, France. Tel: +33 1 49 28 27 10; e-mail: marine.camus@aphp.fr

Curr Opin Gastroenterol 2023, 39:67–74

DOI:10.1097/MOG.0000000000000907

KEY POINTS

- Cholangioscopy or choledochoscopy is an endoscopic procedure, which consists in a direct intraductal visualization of the biliary tract.
- Cholangioscopy can be performed by peroral (mainly), percutaneous transhepatic or intra-operative transcystic or transcholedochal access.
- The development of digital single-operator cholangioscopy using a single-use cholangioscope has changed and improved utility and functionality of cholangioscopy these last 10 years.
- Applications are multiple: indeterminate biliary strictures, difficult stone management, guidance before biliary stenting and retrieval of migrated ductal stents.
- In case of indeterminate biliary strictures, cholangioscopy with guided biopsy during the first endoscopic retrograde cholangiopancreatography may reduce the need to perform multiple procedures.

Regarding POCS, the most frequent modality (indirect POCS), a cholangioscope is advanced over a guidewire through the working channel of a duodenoscope, into the common bile duct ('mother-baby' endoscope system). This is performed during an ERCP and requires prior biliary cannulation, sphincterotomy and a fluoroscopy guided cholangiogram so as to ensure proper positioning within the biliary tracts, before the cholangioscope can be advanced. A cholangioscope can also be advanced into the bile ducts through an extra-anatomical stent (lumen apposing stent, hepaticogastric stent) [5,6]. Digital single-operator cholangioscopy using a SpyGlass® cholangioscope (Boston Scientific, Boston, USA) is the most frequently performed POCS [7].

POCS can also be performed as direct POCS without the use of a duodenoscope. In this case, an ultra-slim endoscope is directly advanced into the bile duct. The main disadvantage is a large outer diameter (5.0–5.9 mm), which may complicate insertion and advancement in small bile ducts [2]. However, a new multiband ultra-slim endoscope seems to yield a high technical success rate [8].

Regarding PTCS, shorter endoscopes with better maneuverability are used (such as CHF-CB30; Olympus Medical Systems, Tokyo, Japan), allowing access to areas that are less easily attainable perorally. These procedures are useful in case of complicated anatomy (i.e. surgically altered anatomy), when POCS is not doable. This is considered second line procedure as it is more invasive, time-consuming and risky (bile leak) compared to POCS [2].

POCS should be performed in a dedicated endoscopy unit, by experienced endoscopists and nurses, knowledgeable on the manipulation of this specific equipment. The patient is under general anesthesia. It is a low risk procedure. However, given the higher risk of cholangitis compared to standard ERCP, prophylactic antibiotics are mandatory [2].

The single-operator POCS cholangioscope has a 1.2-mm working channel through which a variety of accessories can be advanced into the biliary tract under direct visualization: biopsy forceps for tissue sampling, retrieval snare or baskets for stone fragment or foreign body extraction, electrohydraulic or laser lithotripsy probes for stone fragmentation [9].

INDICATIONS

Difficult bile duct stones removal

In 10–15% of the cases, the removal of bile duct stones is not possible using basic ERCP techniques

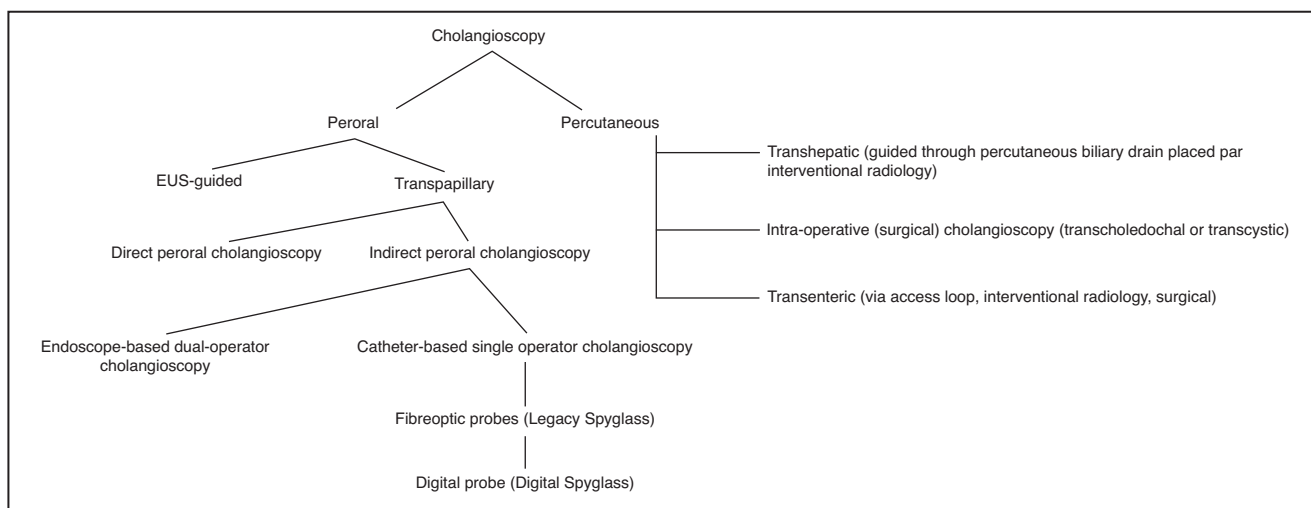


FIGURE 1. Different access routes for cholangioscopy.

Table 1. Different types of peroral cholangioscopes

	Peroral – dual-operator	Peroral – single-operator	Direct peroral choledochoscopy
Endoscopes (fiberoptic or digital-based imaging systems)	SpyGlass Legacy 2007 (Boston Scientific Corporation, Natick, MA, USA) (Fireoptic) SpyGlass Direct Visualisation 2015 (Boston Scientific Corporation, Natick, MA, USA) (Digital) SpyGlass Direct Visualisation II 2018 (Boston Scientific Corporation, Natick, MA, USA) (Digital)	Mother-baby (fiberoptic) Short-access-mother-baby (Karl Storz, Tuttlingen, Germany) (Fiberoptic) Videocholangioscope (CHF-B290; Olympus Medical Systems, Tokyo, Japan) (Digital)	Using variety of ultra-thin endoscopes (fiberoptic or digital)
Outer diameter (mm)	3.3–3.6	2.8–3.4	5.0 – 5.9
Accessory working channel diameter (mm)	1.2	0.8 – 1.5	2.0
Tip deflections	4-way (up-down, left-right)	2-way (up-down)	4-way (up-down, left-right)

(endoscopic sphincterotomy, large-balloon dilation, basket or balloon extraction). These are called difficult biliary stones [10]. Multiple factors can contribute to a difficult extraction, such as stone characteristics (size > 15 mm, number of stones, odd shaped stones), location (intrahepatic duct, cystic duct) and patient-related factors (old age, anticoagulation). ESGE guidelines suggest the use of cholangioscopy-assisted intraluminal lithotripsy for difficult bile duct stones, after sphincterotomy has failed, combined with endoscopic papillary large-balloon dilation [11^{***}].

POCS lithotripsy is a highly effective treatment with shorter and fewer necessary procedures to obtain ductal clearance [12–15] (Fig. 2). Adverse

event rates are similar compared to conventional ERCP, including pancreatitis (2%) cholangitis (4%) and perforation (1%) [16]. However, POCS is less costly compared to repeat ERCs, and is noninferior and less invasive compared to laparoscopic common bile duct exploration [17,18].

Intraluminal lithotripsy can be done by means of two distinct techniques: electrohydraulic and laser lithotripsy. Electrohydraulic lithotripsy uses a specific probe producing high-frequency hydraulic pressure waves when a charge is applied, causing fragmentation of the stone. Laser lithotripsy uses a different probe focusing a laser light on the surface of the stone to induce wave-mediated fragmentation. Both techniques can be repeated until

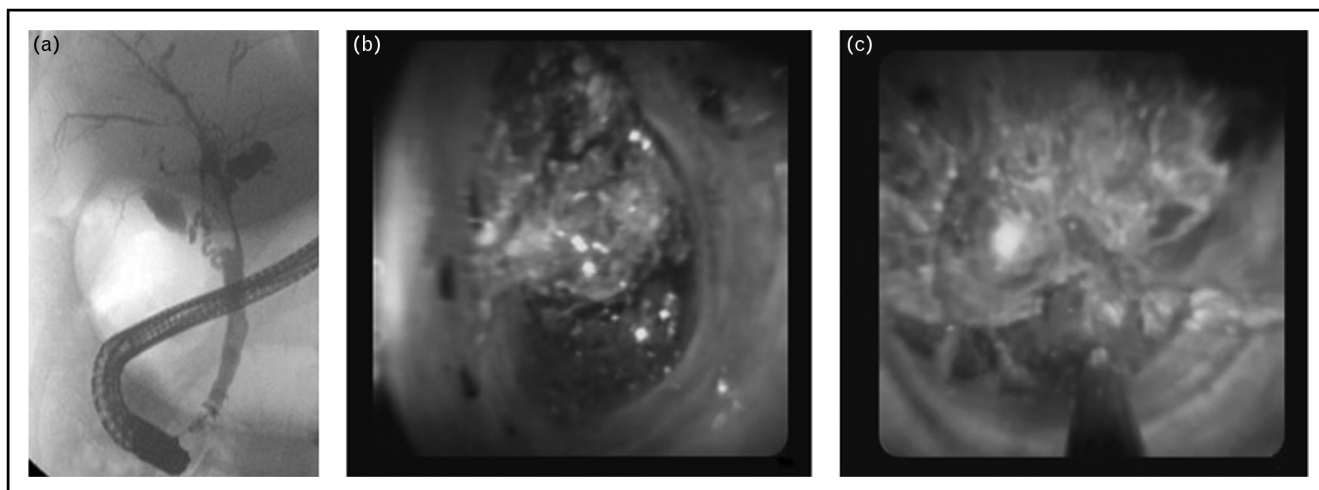


FIGURE 2. Example of a difficult stone extraction treated by cholangioscopy. (a) Endoscopic retrograde cholangiopancreatography (ERCP) showing large bile duct stone. (b, c) Digital cholangioscopic imaging of the stone, treated by lithotripsy under cholangioscopy guidance.

fragmentation is complete. Continuous saline irrigation is required to maintain proper visualization and avoid bile-duct wall damage. At the end of the procedure, stones fragments are extracted using the conventional techniques (i.e. balloon catheters). The rates of total bile duct clearance seem equivalent in retrospective studies (96.7% for electrohydraulic and 99% for laser lithotripsy) and a single session is required in 77.4% of cases [19]. However, recent data including two meta-analyses suggest that laser lithotripsy had a higher complete ductal clearance rate than electrohydraulic lithotripsy (95.1% vs. 88.4%), with a shorter mean procedure time (49.9 vs. 73.9 min) [15,20]. Also, it was reported that the adverse event rate was significantly higher with electrohydraulic lithotripsy (13.8% vs. 9.6%) [21]. Electrohydraulic probes have a short life duration and need to be replaced proportionally to the power used during lithotripsy, contrary to laser light probes, which are more expensive and available in only a few endoscopy units. These studies did not explore the mean number of probes used and their economic impact. Cost-effectiveness studies are warranted. Currently, there are no data supporting the superiority of one method over the other and guidelines suggest that the choice of lithotripsy technique should depend on local availability and expertise only [11[■],22].

Mirizzi syndrome is an extrinsic compression of the common bile duct due to impacted stone(s) in cystic duct. Conventional ERCP techniques are often unable to achieve stone extraction, which may result in laparoscopic management with significant morbidity. Cholangioscopy-assisted intraluminal lithotripsy is an efficient technique for cystic duct stone clearance, so as to achieve bile duct decompression [23].

Bile duct stones removal in patients with surgically altered anatomy is challenging. The main limitation is failure/difficulty to reach the papilla. In patients with a Billroth II or Roux-en-Y reconstruction, a long and/or sharp angled afferent limb, increases the difficulty in reaching the papilla [24]. ERCP and enteroscopy assisted ERCP fail in 15% of cases in this setting.

Two techniques have been described to overcome these drawbacks: percutaneous transhepatic (PTCS) and endoscopic ultrasound (EUS)-guided biliary drainage. Percutaneous transhepatic biliary drainage is a well described second line procedure, after ERCP has failed. However, antegrade extraction of bile duct stones can be difficult, especially in case of large or multiple stones. PTCS allows for an antegrade electrohydraulic or laser intraluminal lithotripsy. Stone fragments are then pushed in the duodenum after papillary dilation [25,26]. The

procedure cannot be done in a single session because prior dilatation of the percutaneous tract is necessary to allow passage of the cholangioscope. Cholangioscopy should not be done immediately after the percutaneous tract has been created. The external biliary drain is removed a few days after duct clearance is confirmed.

EUS-guided biliary drainage consists in creating an hepaticogastrostomy between the left intra-hepatic ducts (which need to be dilated) and the stomach. A metal stent is placed and POCS lithotripsy can then be performed through the stent [27]. In gastric bypass with Roux-en-Y reconstruction patients, EUS guided gastro-gastrostomy between the stomach pouch and the excluded stomach, with lumen apposing metal stent placement, allows the advancement of a duodenoscope into the duodenum, similar to conventional ERCP. Stone fragmentation and extraction can then be performed via the POCS technique, which represents a dramatic improvement in the prognosis.

Indeterminate biliary stricture and biliary tract neoplasia

Biliary strictures which remain unclassified (i.e. benign vs. malignant) after cross-sectional imaging and ERCP-based tissue sampling are defined as indeterminate biliary strictures. Diagnosis of malignant biliary strictures is very challenging. Cytologic or tissue samples obtained during ERCP by brushing, biopsies, or both are limited by a poor sensitivity, of roughly 50%. Cholangioscopy provides direct visualization of strictures and allows for targeted biopsies, which may help to diagnose or rule out malignancy in case of indeterminate strictures [28,29] (Figs. 3 and 4). When available, direct visual assessment and guided biopsies via cholangioscopy during the first ERCP may reduce the need to perform multiple procedures [30]. However, POCS is not the preferred procedure in case of distal biliary strictures, due to inherent technical difficulties.

In a systematic review, including 13 original articles (876 patients) the diagnostic yield of digital/video cholangioscopes for the diagnosis of indeterminate biliary stricture was evaluated. The overall pooled sensitivity and specificity were 88% (95% confidence interval [CI] 83–91) and 95% (95% CI 89–98), respectively. Subgroup analysis showed that visual impression provided significantly higher sensitivity (93% (95% CI 88–96) vs. 82% (95% CI 76–87); $P=0.007$), but lower specificity 86% (95% CI 75–92) vs. 98 (95% CI 95–99); $P<0.001$) than the tissue diagnosis from cholangioscopy-guided biopsies [31[■]]. Thus, decision of surgical management

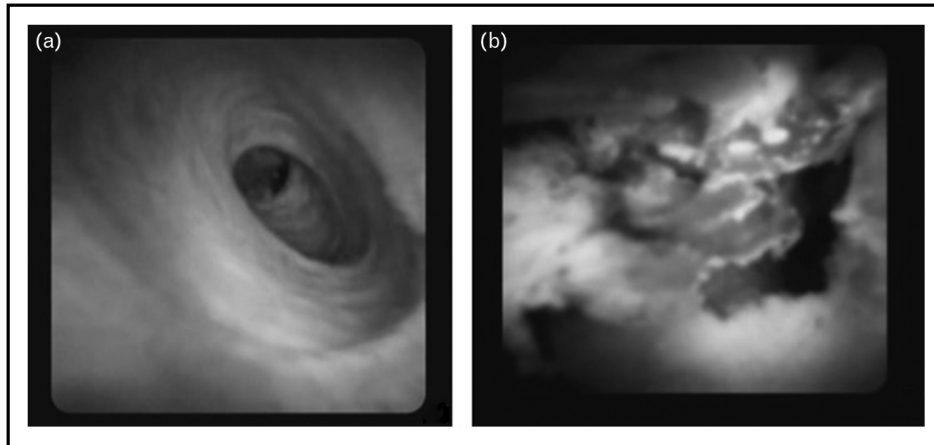


FIGURE 3. Example of peroral digital single operator cholangioscopic imaging. (a) Digital cholangioscopic imaging of normal bile duct. (b) Digital cholangioscopic imaging of a common bile stricture, biopsied with SpyBite™ biopsy forceps, confirmed to be cholangiocarcinoma (CCA).

could take into consideration the endoscopist's visual opinion on an indeterminate biliary stricture. Tumor vessels, papillary projection, nodular or polypoid mass, and infiltrative lesions are highly suggestive of neoplastic/malignant biliary disease [32,33*,34,35]. Image enhancement during cholangioscopy may increase the diagnostic sensitivity of visual impression of malignant biliary strictures [36]. However, the interpretation of indeterminate biliary stricture is difficult, with well known inter-observer variation [37]. Cytology of aspiration fluid from the irrigation performed during cholangioscopy and cholangioscopy guided biopsies significantly improves the sensitivity for detecting malignancy [38]. Future development of AI tools may optimize the macroscopic characterization of biliary strictures [39–41].

Although cholangioscopy is very useful in cases of indeterminate biliary stricture, the accuracy of cholangioscopy biopsies to identify the extension of biliary tract cancer into the biliary tract was considered insufficient in two retrospective studies of 23 patients and 54 patients [42,43].

Finally, cholangioscopy allows an early diagnosis of premalignant lesions (i.e. biliary papillomatosis) of the bile duct, thus enabling early treatment [44,45] and dramatic improvement of the prognosis of these rare diseases.

Migrated foreign bodies

Cholangioscopy can be useful for the retrieval of foreign bodies, which have migrated in the biliary tract. In case of migrated stents, this is often used as

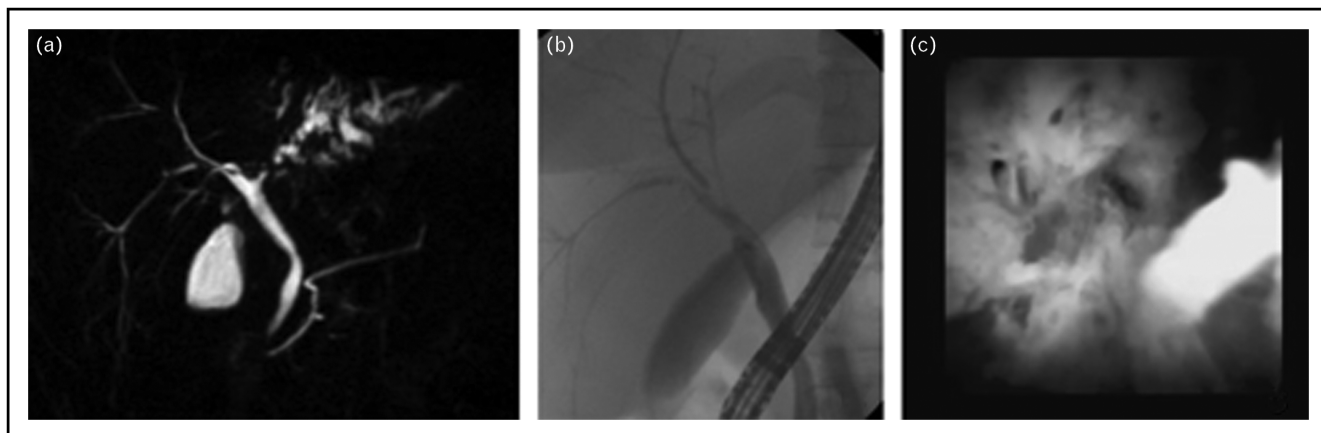


FIGURE 4. Example of an indeterminate biliary stricture evaluated by cholangioscopy corresponding to IgG4 stricture. (a) Magnetic resonance cholangiopancreatography (3D biliary reconstruction) demonstrating common left intrahepatic duct (LHD) stricture without mass. (b) Endoscopic retrograde cholangiopancreatography (ERCP) showing LHD stricture (no LHD opacification). (c) Digital cholangioscopic imaging of the LHD stricture, biopsied with SpyBite™ biopsy forceps.

a last resort technique, when endoscopic retrieval or radiologic interventions have failed [46]. Dedicated accessories such as retrieval baskets and snares, or forceps, which can be advanced through the cholangioscope operating channel, have been shown to be effective in this setting [46,47]. Thin balloons can also be advanced into a plastic stent, after a guidewire has been placed under cholangioscopic guidance within the stent. These balloons are then inflated so as to retrieve the stent by strong traction [48]. Cholangioscopy with electrohydraulic lithotripsy (EHL) has also been successfully used for stone-impacted intra-biliary stent [49,50]. Other foreign bodies such as postcholecystectomy migrated clip and pealed guidewire can also be retrieved [51].

Complex biliary drainage

Cholangioscopy can also be used for guidance in the setting of complex biliary strictures or anatomy. Malignant hilar strictures are a well known challenge. Cholangioscopy guided advancement of guidewires through strictures to help achieve optimal biliary drainage has been described and is commonly used in expert centers, sometimes as a first line procedure [52,53]. The ultra-slim cholangioscope has also been successfully used to guide drainage in patient with difficult stones [54]. In cases of severe post liver transplantation anastomotic biliary strictures, cholangioscopy can also help guide a wire through the stricture [55]. Finally, in patients with acute cholecystitis, endoscopic transpapillary gallbladder drainage seems to be better achieved if guided by cholangioscopy [56].

Primary sclerosing cholangitis

Patients with primary sclerosing cholangitis (PSC) are at a high risk of developing cholestatic liver injury and biliary cancer. Prompt and accurate differentiation between benign and malignant strictures is crucial. A few case or case series suggest an interest of POCS: visual evaluation and optical guided biopsies of indeterminate biliary strictures to rule out malignancy, electrohydraulic lithotripsy of impacted stones [57,58]. POCS seems effective and safe for the endoscopic management of PSC patients and should be considered for complex PCS cases.

Biliary anastomotic stricture post liver transplantation

Cholangioscopy for biliary anastomotic strictures in the setting of liver transplantation has been described as useful in up to 78.9% of patients [59]. In case of very tight strictures, cholangioscopy can

help pass the guidewire across the stricture under direct visualization [59,60]. Repeated biopsies of the anastomosis under direct vision using biopsy forceps, until a passage for the guidewire is made, has also been described in difficult cases [61]. High-frequency needle-knife electrotomy guided by percutaneous transhepatic cholangioscopy has also been successful [62]. Finally, cholangioscopy guided corticosteroid injection following balloon dilation of anastomotic strictures could help patients remain stent-free [63].

Pregnancy and pediatrics

The prevalence of choledocholithiasis during pregnancy is between 1% and 5% [64[■]]. ESGE guidelines suggest that ERCP during pregnancy is a safe and effective technique [64[■]]. However, radiation exposure must be kept to a minimal. Extraction of difficult bile duct stones can be challenging without fluoroscopy. ERCP without radiation has also been proposed, using various techniques such as POCS [64[■]]. A retrospective study including 10 patients showed successful stone extraction using laser lithotripsy, balloon extraction and retrieval basket in 100% of cases with no complication [65].

Biliary stones and strictures can also be encountered in children. Cholangioscopy has been evaluated in a retrospective study including 36 procedures. Radiation exposure was thus avoided. Adverse events were less prevalent in patients who underwent cholangioscopy compared to those who underwent ERCP [66].

INNOVATIONS

Two types of innovations can be distinguished. The first one encompasses technological advances such as the development of new multibending cholangioscopes to facilitate bile duct cannulation, technical improvements of forceps jaws for better sampling, novel enhanced imaging systems and video display techniques (i.e. 3D), artificial intelligence for automated neoplasia detection [2,67–70]. The second one comprises uncommon procedures performed with the use of a cholangioscope. For instance, cases of bile duct reconstruction by rendezvous technique using endoscopic and percutaneous cholangioscopy or treatment of refractory benign biliary stricture using cholangioscopy-guided thulium laser stricturoplasty have been achieved [71–73].

CONCLUSION

Cholangioscopy is an endoscopic procedure which allows direct intraductal visualization of the biliary

tract. Cholangioscopy has emerged as a major tool for indeterminate biliary stricture evaluation and treatment of difficult biliary stones, with adverse event rates comparable to standard endoscopic retrograde cholangioscopy. Cholangioscopy has improved the way biliary diseases can be visualized and treated. New technology, accessories, and applications are expected in the future.

Acknowledgements

None.

Financial support and sponsorship

None.

Conflicts of interest

There are no conflicts of interest.

REFERENCES AND RECOMMENDED READING

Papers of particular interest, published within the annual period of review, have been highlighted as:

- of special interest
- of outstanding interest

1. Subhash A, Buxbaum JL, Tabibian JH. Peroral cholangioscopy: update on the state-of-the-art. *World J Gastrointest Endosc* 2022; 14:63–76.
 2. Lee T, Teng TZJ, Shelat VG. Choledochoscopy: an update. *World J Gastrointest Endosc* 2021; 13:571–592.
 3. Pouw RE, Barret M, Biermann K, *et al.* Endoscopic tissue sampling. Part 1. ■ Upper gastrointestinal and hepatopancreatobiliary tracts. European Society of Gastrointestinal Endoscopy (ESGE) Guideline. *Endoscopy* 2021; 53:1174–1188.
- This reference is mandatory to know. There are the ESGE (European Society of Gastrointestinal Endoscopy) guidelines. This reference includes the good practices for the indeterminate bile duct stricture sampling including the role of cholangioscopy.
4. Fugazza A, Gabbiadini R, Tringali A, *et al.* Digital single-operator cholangioscopy in diagnostic and therapeutic bilio-pancreatic diseases: A prospective, multicenter study. *Dig Liver Dis* 2022; 54:1243–1249.
 5. Yoo HW, Moon JH, Lee YN, *et al.* Feasibility of cholangioscopy using multi-bending ultra-slim endoscope through a lumen-apposing metal stent for choledochoduodenostomy. *Dig Dis Sci* 2022; doi: 10.1007/s10620-022-07531-7. [Online ahead of print]
 6. Fugazza A, Gabbiadini R, Sollai M, *et al.* EUS-guided hepaticogastrotomy and antegrade direct peroral cholangioscopy: an effective alternative to overcome the distance (with video). *Endosc Ultrasound* 2021; DOI: 10.4103/EUS-D-21-00087.
 7. Tsuyuguchi T. Pancreato-hepatobiliary endoscopy: cholangioscopy. *Dig Endosc* 2022; 34(Suppl 2):107–110.
 8. Lee YN, Moon JH, Lee TH, *et al.* Efficacy and safety of direct peroral cholangioscopy using a new multi-bending ultra-slim endoscope for the management of biliary diseases. *J Hepatobiliary Pancreat Sci* 2022; 29:1292–1299.
 9. Subhash A, Abadir A, Iskander JM, *et al.* Applications, limitations, and expansion of cholangioscopy in clinical practice. *Gastroenterol Hepatol* 2021; 17:110–120.
 10. Lee YS, Jeon TJ, Paik WH, *et al.* National survey regarding the management of difficult bile duct stones in South Korea. *Gut Liver* 2022; DOI: 10.5009/gnl220117.
 11. Manes G, Paspatis G, Aabakken L, *et al.* Endoscopic management of common bile duct stones: European Society of Gastrointestinal Endoscopy (ESGE) guideline. *Endoscopy* 2019; 51:472–491.
- This reference is mandatory to know. There are the ESGE (European Society of Gastrointestinal Endoscopy) guidelines. This reference includes the good practices for the treatment of bile duct stones including the role of cholangioscopy.
12. Alexandrino G, Lopes L, Fernandes J, *et al.* Factors influencing performance of cholangioscopy-guided lithotripsy including available different technologies: a prospective multicenter study with 94 patients. *Dig Dis Sci* 2022; 67:4195–4203.
 13. Facciorusso A, Gkolfakis P, Ramai D, *et al.* Endoscopic treatment of large bile duct stones: a systematic review and network meta-analysis. *Clin Gastroenterol Hepatol* 2023; 21:33–44.

14. Goenka MK, Shah BB, Rodge GA, *et al.* Efficacy and safety of cholangioscopy guided laser lithotripsy for difficult bile duct stones - A prospective study from a tertiary care centre in Eastern India. *Arab J Gastroenterol* 2021; 22:111–114.
 15. McCarty TR, Gulati R, Rustagi T. Efficacy and safety of peroral cholangioscopy with intraductal lithotripsy for difficult biliary stones: a systematic review and meta-analysis. *Endoscopy* 2021; 53:110–122.
 16. Tronccone E, Mossa M, De Vico P, *et al.* Difficult biliary stones: a comprehensive review of new and old lithotripsy techniques. *Med Kaunas Lith* 2022; 58:120.
 17. Alrajhi S, Barkun A, Adam V, *et al.* Early cholangioscopy-assisted electrohydraulic lithotripsy in difficult biliary stones is cost-effective. *Ther Adv Gastroenterol* 2021; 14:17562848211031388.
 18. Li G, Pang Q, Zhai H, *et al.* SpyGlass-guided laser lithotripsy versus laparoscopic common bile duct exploration for large common bile duct stones: a noninferiority trial. *Surg Endosc* 2021; 35:3723–3731.
 19. Oh CH, Dong SH. Recent advances in the management of difficult bile-duct stones: a focus on single-operator cholangioscopy-guided lithotripsy. *Korean J Intern Med* 2021; 36:235–246.
 20. Brewer Gutierrez OI, Bekkali NLH, Rajman I, *et al.* Efficacy and safety of digital single-operator cholangioscopy for difficult biliary stones. *Clin Gastroenterol Hepatol* 2018; 16:918–926; e1.
 21. Veld JV, van Huijgevoort NCM, Boermeester MA, *et al.* A systematic review of advanced endoscopy-assisted lithotripsy for retained biliary tract stones: laser, electrohydraulic or extracorporeal shock wave. *Endoscopy* 2018; 50:896–909.
 22. ASGE Standards of Practice Committee. Buxbaum JL, Abbas Fehmi SM, *et al.* ASGE guideline on the role of endoscopy in the evaluation and management of choledocholithiasis. *Gastrointest Endosc* 2019; 89:1075–1105; e15.
 23. Kawai H, Sato T, Natsui M, *et al.* Mirizzi syndrome type iv successfully treated with peroral single-operator cholangioscopy-guided electrohydraulic lithotripsy: a case report with literature review. *Intern Med Tokyo Jpn* 2022; 61:3513–3519.
 24. Tringali A, Costa D, Fugazza A, *et al.* Endoscopic management of difficult common bile duct stones: where are we now? A comprehensive review. *World J Gastroenterol* 2021; 27:7597–7611.
 25. Chon HK, Choi KH, Seo SH, *et al.* Efficacy and safety of percutaneous transhepatic cholangioscopy with the spyglass DS direct visualization system in patients with surgically altered anatomy: a pilot study. *Gut Liver* 2022; 16:111–117.
 26. Neuhaus H, Beyna T. Percutaneous single-operator video cholangioscopy using a novel short disposable endoscope: first clinical case with treatment of a complex biliary stone and inaccessible papilla after Roux-en-Y reconstructive surgery. *VideoGIE Off Video J Am Soc Gastrointest Endosc* 2021; 6:27–29.
 27. Yonamine K, Koshita S, Kanno Y, *et al.* Endoscopic ultrasound (EUS)-guided antegrade intervention for a hepaticojejunostomy anastomosis obstruction under peroral cholangioscopy via an EUS-guided hepaticogastrotomy route. *Endoscopy* 2022; 54:E788–E789.
 28. Angsuwatcharakon P, Kulpacharapong S, Moon JH, *et al.* Consensus guidelines on the role of cholangioscopy to diagnose indeterminate biliary stricture. *HPB* 2022; 24:17–29.
 29. Weigand K, Küchle M, Zuber-Jerger I, *et al.* Diagnostic accuracy and therapeutic efficacy of digital single-operator cholangioscopy for biliary lesions and stenosis. *Digestion* 2021; 102:776–782.
 30. Gerges C, Beyna T, Tang RSY, *et al.* Digital single-operator peroral cholangioscopy-guided biopsy sampling versus ERCP-guided brushing for indeterminate biliary strictures: a prospective, randomized, multicenter trial (with video). *Gastrointest Endosc* 2020; 91:1105–1113.
 31. Kulpacharapong S, Pittayanon R, Kerr SJ, *et al.* Diagnostic performance of ■ digital and video cholangioscopes in patients with suspected malignant biliary strictures: a systematic review and meta-analysis. *Surg Endosc* 2022; 36:2827–2841.
- Systematic review about the diagnostic yield of digital/video cholangioscopes for the diagnosis of indeterminate biliary stricture.
32. El Bacha H, Harizi R, Laugier R, *et al.* Identification of endoscopic predictors of biliary malignancy during digital cholangioscopy. *Dig Endosc* 2022; 34:1224–1233.
 33. Kahaleh M, Gaidhane M, Shahid HM, *et al.* Digital single-operator cholangioscopy interobserver study using a new classification: the Mendoza Classification (with video). *Gastrointest Endosc* 2022; 95:319–326.
- Study has evaluated the interobserver agreement of cholangioscopy.
34. Sethi A, Tyberg A, Slivka A, *et al.* Digital single-operator cholangioscopy (DSOC) improves interobserver agreement (IOA) and accuracy for evaluation of indeterminate biliary strictures: the Monaco Classification. *J Clin Gastroenterol* 2022; 56:e94–e97.
 35. Robles-Medrandra C, Oleas R, Sánchez-Carriel M, *et al.* Vascularity can distinguish neoplastic from nonneoplastic bile duct lesions during digital single-operator cholangioscopy. *Gastrointest Endosc* 2021; 93:935–941.
 36. Shin IS, Moon JH, Lee YN, *et al.* Efficacy of narrow-band imaging during peroral cholangioscopy for predicting malignancy of indeterminate biliary strictures (with videos). *Gastrointest Endosc* 2022; 96:512–521.

37. Stassen PMC, Goodchild G, de Jonge PJF, *et al.* Diagnostic accuracy and interobserver agreement of digital single-operator cholangioscopy for indeterminate biliary strictures. *Gastrointest Endosc* 2021; 94:1059–1068.
 38. Munot K, Rajman I, Khan V, *et al.* Aspiration fluid cytology during single operator cholangioscopy with targeted biopsy to improves the diagnostic yield in indeterminate biliary strictures. *Diagn Cytopathol* 2021; 49:768–772.
 39. Ribeiro T, Saraiva MM, Afonso J, *et al.* Automatic identification of papillary projections in indeterminate biliary strictures using digital single-operator cholangioscopy. *Clin Transl Gastroenterol* 2021; 12:e00418.
 40. Saraiva MM, Ribeiro T, Ferreira JPS, *et al.* Artificial intelligence for automatic diagnosis of biliary stricture malignancy status in single-operator cholangioscopy: a pilot study. *Gastrointest Endosc* 2022; 95:339–348.
 41. Pereira P, Mascarenhas M, Ribeiro T, *et al.* Automatic detection of tumor vessels in indeterminate biliary strictures in digital single-operator cholangioscopy. *Endosc Int Open* 2022; 10:E262–E268.
 42. Onoyama T, Hamamoto W, Sakamoto Y, *et al.* Peroral cholangioscopy-guided forceps mapping biopsy for evaluation of the lateral extension of biliary tract cancer. *J Clin Med* 2021; 10:597.
 43. Takeda T, Sasaki T, Mie T, *et al.* Comparison of tube-assisted mapping biopsy with digital single-operator peroral cholangioscopy for preoperative evaluation of biliary tract cancer. *Clin Endosc* 2022; 55:549–557.
 44. Becq A, Camus M, Pietri O, *et al.* Direct cholangioscopy for diagnosis and treatment guidance of suspected biliary papillomatosis with malignant transformation. *Endoscopy* 2020; 52:E3–E4.
 45. Junquera Alonso E, Vargas González C, Terroba Alonso M, *et al.* Diagnosis of biliary papillomatosis with a Spyglass® cholangioscope. *Rev Espanola Enfermedades Dig Organo Of Soc Espanola Patol Dig* 2022; 114:439–440.
 46. Weaver MJ, Kushnir VM. Endoscopic retrieval of a proximally migrated biliary stent using extracorporeal shockwave lithotripsy, electrohydraulic lithotripsy, and cholangioscopy with minisnare. *VideoGIE Off Video J Am Soc Gastrointest Endosc* 2021; 6:231–233.
 47. Bills G, Brown J, Gabr M. Cholangioscopy-guided removal of a proximally migrated biliary stent using a modified standard polypectomy snare. *VideoGIE Off Video J Am Soc Gastrointest Endosc* 2021; 6:316–318.
 48. Fujimori N, Yasumori S, Oono T. Successful endoscopic retrieval of an embedded biliary stent using an intra-stent balloon inflation technique assisted by direct per-oral cholangioscopy. *Dig Endosc* 2021; 33:e97–e99.
 49. Matsumi A, Matsumoto K, Yamazaki T, *et al.* Successful removal of an uncovered metallic stent using peroral direct cholangioscopy and the stent-in-stent technique. *Endoscopy* 2022; 54:E860–E861.
 50. Loosen SH, Kunstein A, Vom Dahl S, *et al.* Digital single-operator cholangioscopy with EHL as salvage therapy of an internalized and stone-impacted biliary stent 13 years after implantation. *Endosc Int Open* 2022; 10: E269–E272.
 51. Aaron E, Palamuthusingam P. Postcholecystectomy clip migration—a unique method of retrieval. *J Surg Case Rep* 2022; 2022:rjab640.
 52. Bokemeyer A, Gross D, Brückner M, *et al.* Digital single-operator cholangioscopy: a useful tool for selective guidewire placements across complex biliary strictures. *Surg Endosc* 2019; 33:731–737.
 53. Keane MG, Ghandour B, Bejjani M, *et al.* Cholangioscopy-guided double-guidewire technique for complex malignant hilar obstruction. *VideoGIE Off Video J Am Soc Gastrointest Endosc* 2022; 7:36–37.
 54. Park JK, Moon JH, Lee YN, *et al.* Feasibility study of endoscopic biliary drainage under direct peroral cholangioscopy by using an ultra-slim upper endoscope (with videos). *Endosc Int Open* 2021; 9:E1447–E1452.
 55. Trivedi PS, Pshak TJ. Cholangioscopy-assisted crossing of severe biliary-enteric anastomotic stricture following failure of standard fluoroscopic techniques. *Cardiovasc Intervent Radiol* 2021; 44:992–995.
 56. Yoshida M, Naitoh I, Hayashi K, *et al.* Four-step classification of endoscopic transpapillary gallbladder drainage and the practical efficacy of cholangioscopic assistance. *Gut Liver* 2021; 15:476–485.
 57. Tejaswi S, Olson KA, Loehfelm TW. Cholangioscopy in primary sclerosing cholangitis: a case series of dominant strictures and cholangiocarcinoma. *VideoGIE Off Video J Am Soc Gastrointest Endosc* 2021; 6:277–281.
 58. Bokemeyer A, Lenze F, Stoica V, *et al.* Digital single-operator video cholangioscopy improves endoscopic management in patients with primary sclerosing cholangitis—a retrospective observational study. *World J Gastroenterol* 2022; 28:2201–2213.
 59. Yu J-F, Zhang D-L, Wang Y-B, *et al.* Digital single-operator cholangioscopy for biliary stricture after cadaveric liver transplantation. *World J Gastrointest Oncol* 2022; 14:1037–1049.
 60. Funari MP, Hirsch BS, Franzini TP, *et al.* Role of cholangioscopy and therapeutic options in complex anastomotic strictures after liver transplantation. *Endoscopy* 2022; 54:E581–E582.
 61. Martínez-Moreno B, Martínez-Sempere J, Ruiz Gómez F, *et al.* Usefulness of intraductal cholangioscopy biopsy forceps in critical strictures of the biliary anastomosis after liver transplantation. *Endoscopy* 2022; DOI: 10.1055/a-1838-4154.
 62. Tao H, Wang P, Sun B, *et al.* One-step percutaneous transhepatic cholangioscopy combined with high-frequency needle-knife electrocromy in biliary strictures after liver transplantation. *Surg Laparosc Endosc Percutan Tech* 2021; 31:787–793.
 63. Franzini T, Sagae VMT, Guedes HG, *et al.* Cholangioscopy-guided steroid injection for refractory post liver transplant anastomotic strictures: a rescue case series. *Ther Adv Gastrointest Endosc* 2019; 12: 2631774519867786.
 64. Testoni PA, Mariani A, Aabakken L, *et al.* Papillary cannulation and sphincterotomy techniques at ERCP: European Society of Gastrointestinal Endoscopy (ESGE) Clinical Guideline. *Endoscopy* 2016; 48:657–683.
- This reference is mandatory to know, ESGE guidelines.
65. Dalal A, Patil G, Kamat N, *et al.* Utility of the novel SpyGlass™ DS II system and laser lithotripsy for choledocholithiasis in pregnancy. *GE Port J Gastroenterol* 2022; 29:172–177.
 66. Barakat MT, Berquist WE, Gugig R. Cholangioscopy in children and adolescents: utilization, outcomes, and safety. *J Pediatr Gastroenterol Nutr* 2022; 75:196–201.
 67. Wirsing L, Linzenbold W, Jaeger SU, *et al.* A new tool for bile duct tissue sampling: ex vivo clinical evaluation of intraductal cryobiopsy for cholangioscopy. *Endosc Int Open* 2022; 10:E809–E814.
 68. Low DJ, Hong Z, Lee JH. Artificial intelligence implementation in pancreaticobiliary endoscopy. *Expert Rev Gastroenterol Hepatol* 2022; 16:493–498.
 69. Koiwai A, Hirota M, Satoh K. Observations on the presence of bile using red dichromatic imaging 3 in peroral cholangioscopy. *Dig Endosc* 2022; 34:649.
 70. Ahmad OF, Stassen P, Webster GJ. Artificial intelligence in biliopancreatic endoscopy: is there any role? *Best Pract Res Clin Gastroenterol* 2021; 52-53:101724.
 71. Ratone J-P, Caillol F, Marx M, *et al.* A novel case of biliary common bile duct reconstruction by the rendezvous technique using endoscopic cholangioscopy and percutaneous cholangioscopy. *Endoscopy* 2022; 54:E950–E951.
 72. Leonor PA, Miley A, Al-Shahrani A, *et al.* Endoscopic treatment of a refractory benign biliary stricture using cholangioscopy-guided thulium laser stricturoplasty. *VideoGIE Off Video J Am Soc Gastrointest Endosc* 2022; 7:256–258.
 73. Kharbat M, Durmush D, Lodh SP, *et al.* Bile duct reconstruction with single-operator cholangioscopy and percutaneous radiological rendezvous procedure. *Endoscopy* 2021; 53:E67–E68.