



HAL
open science

Pulmonary cystic echinococcosis in a child

Elora Peulier-Maitre, Erik Hervieux, Jeanne Bigot, Chiara Sileo, Sophie Denamur, Harriet Corvol

► **To cite this version:**

Elora Peulier-Maitre, Erik Hervieux, Jeanne Bigot, Chiara Sileo, Sophie Denamur, et al.. Pulmonary cystic echinococcosis in a child. *Pediatric Pulmonology*, 2023, 10.1002/ppul.26579 . hal-04154987

HAL Id: hal-04154987


<https://hal.sorbonne-universite.fr/hal-04154987v1>

Submitted on 7 Jul 2023

HAL is a multi-disciplinary open access archive for the deposit and dissemination of scientific research documents, whether they are published or not. The documents may come from teaching and research institutions in France or abroad, or from public or private research centers.

L'archive ouverte pluridisciplinaire **HAL**, est destinée au dépôt et à la diffusion de documents scientifiques de niveau recherche, publiés ou non, émanant des établissements d'enseignement et de recherche français ou étrangers, des laboratoires publics ou privés.

Pulmonary cystic echinococcosis in a child

Elora Peulier-Maitre MD¹ | Erik Hervieux MD² | Jeanne Bigot PharmD, PhD^{3,4} |
Chiara Sileo MD⁵ | Sophie Denamur MD^{1,4} | Harriet Corvol MD, PhD^{1,4} 

¹Sorbonne Université, Assistance Publique-Hôpitaux de Paris (AP-HP), Hôpital Trousseau, Service de Pneumologie Pédiatrique, Paris, France

²Sorbonne Université, AP-HP, Hôpital Trousseau, Service de Chirurgie Viscérale Pédiatrique et Néonatale, Paris, France

³Sorbonne Université, AP-HP, Hôpital Saint-Antoine, Service de Parasitologie-Mycologie, Paris, France

⁴Sorbonne Université, Inserm U938, Centre de Recherche Saint-Antoine (CRSA), Paris, France

⁵Sorbonne Université, AP-HP, Hôpital Trousseau, Service de Radiologie Pédiatrique, Paris, France

Correspondence

Harriet Corvol, MD, PhD, Sorbonne Université, Assistance Publique-Hôpitaux de Paris (AP-HP), Hôpital Trousseau, Service de Pneumologie Pédiatrique, 26 Ave du Dr Netter, 75012 Paris, France.
Email: harriet.corvol@aphp.fr

Funding information

None

Abstract

This case report describes the presentation, diagnosis, and treatment of a 13-year-old boy with pulmonary cystic echinococcosis. The patient presented with low-volume hemoptysis, and lung imaging revealed a large cystic mass, as well as smaller pseudo-nodular lesions, suggesting a large intrathoracic hydatid cyst and ruptured cysts. The diagnosis was confirmed by a positive echinococcosis Western Blot assay, despite equivocal serology. The treatment consisted of surgical removal of the large cyst using thoracoscopy, along with a two-week course of albendazole and praziquantel, followed by albendazole alone for two years. Analysis of the cyst membrane revealed an *Echinococcus granulosus* protoscolex. The patient had a successful recovery.

KEYWORDS

hydatid cyst, lung, pediatric, protoscolex, surgery

To the Editor,

A 13-year-old boy with no notable medical history presented at the Pediatric University Hospital Armand Trousseau (Paris, France) after experiencing low-volume hemoptysis. His parents were of Moroccan descent, and his last trip to Morocco occurred 18 months before the onset of symptoms. The chest CT revealed a mass in the lower lobe of the right lung with a cystic component and fluid density (dimensions: 53 × 58 mm in axial; 67 mm in height), as well as two smaller pseudo-nodular lesions (one also located in the right lower lobe and the other one in the left lower lobe) (Figure 1A,B,C). The biggest lesion was consistent with an intrathoracic hydatid cyst, while the smaller ones were suggestive of ruptured cysts. The hydatid serology was equivocal, but the echinococcosis Western Blot assay was positive. There was no hypereosinophilia

at diagnosis, and the staging assessment detected no lesions in the abdominal or brain.

While the assessment was still in progress, the patient expressed chest pain and subsequently expectorated a clear fluid mixed with whitish debris, suggestive of hydatid cyst membranes. The rupture of the right intrathoracic cyst was confirmed by imaging. Dual therapy with albendazole and praziquantel was started. The patient underwent a semi-emergency surgical thoracoscopic removal of the cyst. The cyst membrane was quickly visualized (Figure 2A). Pleural cavity was protected by irrigation of a 10% hypertonic saline solution during the surgery. The cyst was aspirated (Figure 2B), followed by a cystectomy (Figure 2C,D) and capitonnage of the residual cavity. The homolateral-associated collapsed cyst, identified on imaging, could not be visualized during

This is an open access article under the terms of the Creative Commons Attribution-NonCommercial-NoDerivs License, which permits use and distribution in any medium, provided the original work is properly cited, the use is non-commercial and no modifications or adaptations are made.

© 2023 The Authors. *Pediatric Pulmonology* published by Wiley Periodicals LLC.

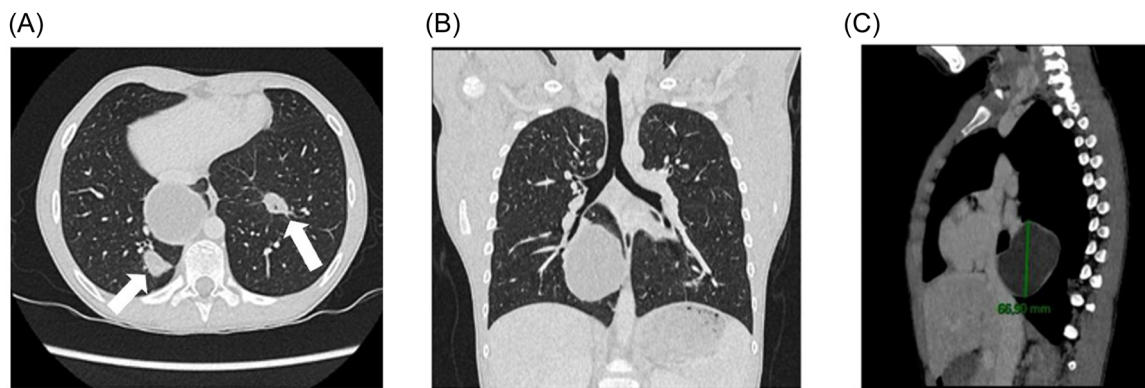


FIGURE 1 The chest Computed Tomography ([A] parenchymal axial section, [B] parenchymal coronal section, [C] mediastinal sagittal section) revealed a large mass in the lower lobe of the right lung with a cystic component and fluid density and two smaller pseudo-nodular lesions (one the right lower lobe and the other one in the left lower lobe underlined in [A] by the white arrows). [Color figure can be viewed at wileyonlinelibrary.com]

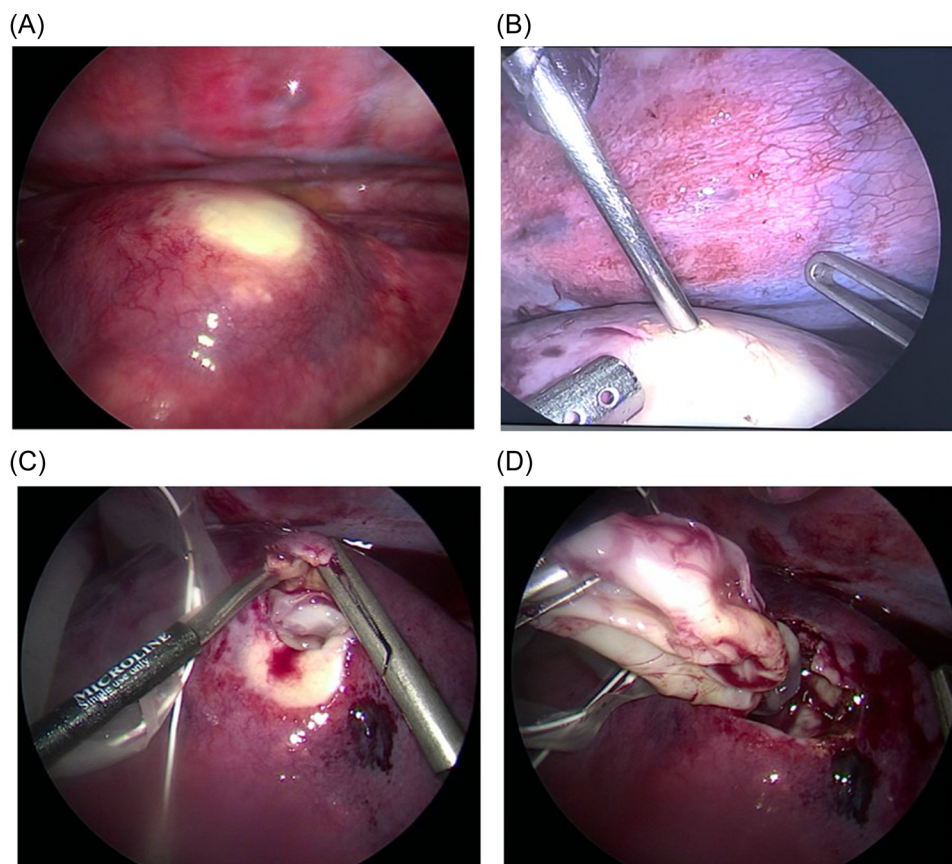


FIGURE 2 Thoracoscopy allowed for visualization of the cyst membrane (A), followed by cyst aspiration (B) and excision (C and D). [Color figure can be viewed at wileyonlinelibrary.com]

thoracoscopy. Chest tube was removed at postoperative Day 2, residual fluid and air effusion spontaneously resolved, and the patient was transferred from intensive care unit to conventional medical unit at postoperative Day 5. Adjacent therapy by albendazole and praziquantel was given for 2 weeks, followed by

albendazole alone for an expected duration of 2 years. Right after the surgery, the eosinophil count increased to 0.690 G/L, and further normalized within 2 weeks. The hydatid serology turned positive and the analysis of the cyst membrane (Figure 3A) revealed an *Echinococcus granulosus protoscolex* (Figure 3B).

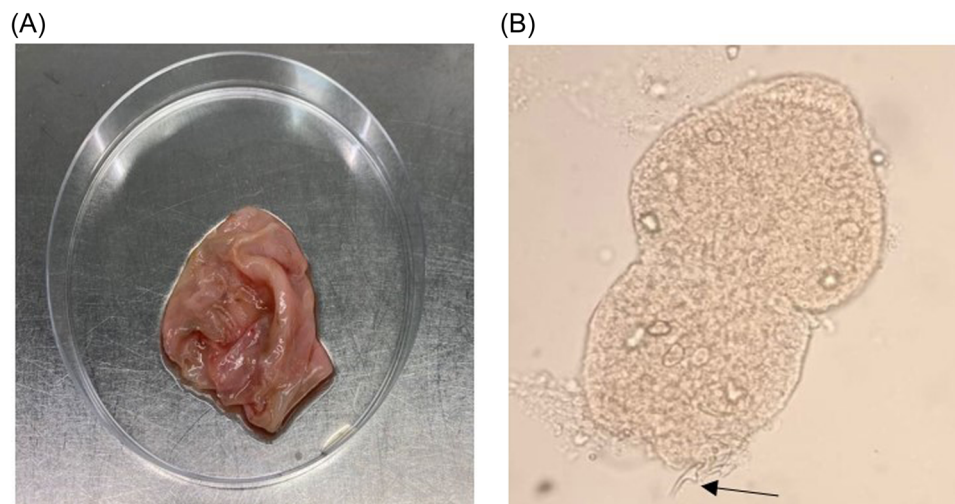


FIGURE 3 Visualization of the ruptured cyst membrane after surgical removal (A) and microscopic identification of an *Echinococcus granulosus* protoscolex in the cystic liquid (at 400× magnification, the black arrow indicates the presence of a hook [B]). [Color figure can be viewed at wileyonlinelibrary.com]

E. granulosus, the cestode parasite responsible for causing cystic echinococcosis (CE), is predominantly found in deprived and rural areas worldwide where individuals live in close proximity to dogs. Various genotypes of this pathogen have been described.¹ Humans are incidental intermediate hosts. After ingestion, eggs pass through the intestinal mucosa and enter the portal venous system, ultimately reaching the target organ where they develop into larvae. The lungs are the second most prevalent site of hydatid disease, following the liver.² Multiple protoscolex develop on the cyst inner surface. Protoscolex, which measures about 120 μm, contains invaginated scolex bearing suckers and hooks of the future adult cestode. They eventually differentiate into secondary cysts when a cyst ruptures.³

The diagnosis of pulmonary CE in children is based on a combination of history, imaging, and serology. Although there is limited data regarding therapeutic management, standard treatments typically involve both surgery and pharmacology.⁴ Surgical intervention is the mainstay of treatment for pulmonary CE and aims to achieve several objectives, including parasite removal, prevention of bronchial dissemination, and treatment of lung disease. The preferred surgical method for pulmonary CE is complete excision, utilizing parenchymal-preserving techniques such as cystectomy.³ To prevent recurrence after surgery, patients should receive albendazole (10–15 mg/kg/day) for a minimum of 6 months. In certain cases, pharmacological treatment alone may be proposed.^{2,5}

In conclusion, this case underscores the need for a multi-disciplinary approach involving surgery and pharmacological treatment in the management of pediatric pulmonary CE.

AUTHOR CONTRIBUTIONS

Elora Peulier-Maitre: Conceptualization; writing—original draft; writing—review and editing; investigation; methodology; validation. **Erik Hervieux:** Investigation; methodology; writing—review

and editing; validation; conceptualization. **Jeanne Bigot:** Conceptualization; investigation; methodology; validation; writing—review and editing. **Chiara Sileo:** Conceptualization; investigation; writing—review and editing; validation; methodology. **Sophie Denamur:** Conceptualization; investigation; methodology; validation; writing—review and editing. **Harriet Corvol:** Conceptualization; investigation; writing—original draft; writing—review and editing; validation; methodology; supervision.

CONFLICT OF INTEREST STATEMENT

The authors declare no conflict of interest.

DATA AVAILABILITY STATEMENT

The data that support the findings of this study are available from the corresponding author upon reasonable request.

ETHICS STATEMENT

Ethics board approval was not needed due to local policy. Written informed consent was obtained from the child's parents for publication of this case and any accompanying images.

ORCID

Harriet Corvol  <http://orcid.org/0000-0002-7026-7523>

REFERENCES

- Alvarez Rojas CA, Romig T, Lightowlers MW. *Echinococcus granulosus* sensu lato genotypes infecting humans: review of current knowledge. *Int J Parasitol.* 2014;44(1):9–18.
- Kocaman OH, Günendi T, Dere O, Dörterler ME, Boleken ME. Pulmonary hydatid cyst in children: a single-institution experience. *Cureus juill.* 2022;14(7):e26670.
- Goussard P, Eber E, Mfingwana L, et al. Paediatric pulmonary echinococcosis: a neglected disease. *Paediatr Respir Rev.* 2022;43:11–23.

4. Rawat S, Kumar R, Raja J, Singh RS, Thingnam SKS. Pulmonary hydatid cyst: review of literature. *J Family Med Prim Care*. 2019; 88(9):2774-2778.
5. Sheves A, Fuxman Y, Gazer B, et al. Treatment of cystic echinococcosis in children: asingle center experience. *Pediatr Infect Dis J*. 2023; 42(3):175-179.

How to cite this article: Peulier-Maitre E, Hervieux E, Bigot J, Sileo C, Denamur S, Corvol H. Pulmonary cystic echinococcosis in a child. *Pediatr Pulmonol*. 2023;1-4. doi:[10.1002/ppul.26579](https://doi.org/10.1002/ppul.26579)