



HAL
open science

Radiotherapy for newly diagnosed primary central nervous system lymphoma: role and perspective

Alice Thomas, Caroline Houillier, Delphine Antoni, Khe Hoang Xuan, Carole Soussain, Julian Jacob, Loic Feuvret

► To cite this version:

Alice Thomas, Caroline Houillier, Delphine Antoni, Khe Hoang Xuan, Carole Soussain, et al.. Radiotherapy for newly diagnosed primary central nervous system lymphoma: role and perspective. Reports of Practical Oncology & Radiotherapy, 2023, 28 (2), pp.271-285. 10.5603/RPOR.a2023.0028 . hal-04268581

HAL Id: hal-04268581

<https://hal.sorbonne-universite.fr/hal-04268581>

Submitted on 2 Nov 2023

HAL is a multi-disciplinary open access archive for the deposit and dissemination of scientific research documents, whether they are published or not. The documents may come from teaching and research institutions in France or abroad, or from public or private research centers.

L'archive ouverte pluridisciplinaire **HAL**, est destinée au dépôt et à la diffusion de documents scientifiques de niveau recherche, publiés ou non, émanant des établissements d'enseignement et de recherche français ou étrangers, des laboratoires publics ou privés.



Radiotherapy for newly diagnosed primary central nervous system lymphoma: role and perspective

Alice Thomas^{1,4}, Caroline Houillier², Delphine Antoni¹, Khe Hoang-Xuan², Carole Soussain³,
Julian Jacob⁴, Loïc Feuvret^{4,5}

¹Department of Radiation Oncology, Institut de Cancérologie Strasbourg Europe (ICANS), Strasbourg, France

²Sorbonne Université, Inserm, CNRS, UMR S 1127, Institut du Cerveau et de la Moelle épinière, ICM, AP-HP, Hôpitaux Universitaires La Pitié Salpêtrière — Charles Foix, Service de Neurologie 2-Mazarin, Paris, France

³Department of Hematology, Institut Curie site de Saint-Cloud, France, and INSERM U932 Institut Curie, PSL Research University, Paris, France

⁴Department of Radiation Oncology, Hôpitaux Universitaires La Pitié Salpêtrière — Charles Foix, APHP, Paris, France

⁵Department of Radiation Oncology, Hospices Civils de Lyon, Lyon, France

ABSTRACT

Whole brain radiotherapy (WBRT) has long been a key treatment of newly diagnosed primary central nervous system lymphoma (PCNSL). In the 1990s, the addition of high dose Methotrexate-based induction chemotherapy (HD MTX-based CT) has enabled a drastic improvement in PCNSL patients outcome. However, combined treatment has led to radiation-induced delayed neurotoxicity, especially in older patients. Alternative treatment strategies have been assessed to improve the efficacy and neurotoxicity ratio. Nowadays, in the elderly patients WBRT is widely omitted or deferred, and in younger patients WBRT is challenged by high dose chemotherapy with autologous stem cell transplant (HCT-ASCT) for consolidation treatment after HD MTX-based CT. In this setting, this review is addressed to clinicians with the aim to summarize the role of WBRT in the treatment of newly diagnosed PCNSL and its perspectives.

Key words: radiotherapy; lymphoma; central nervous system; chemotherapy; neurotoxicity

Rep Pract Oncol Radiother 2023;28(2):271–285

Introduction

Primary central nervous system lymphoma (PCNSL) is a rare aggressive non-Hodgkin's lymphoma confined to the brain, spine, eyes and leptomeninges. Historically, the treatment of newly diagnosed PCNSL was based on whole brain radiotherapy (WBRT) alone, and while objective responses occurred in the large majority of cases, durable responses were rare and outcomes poor [1].

In the 1990s, the introduction of high dose intravenous methotrexate-based chemotherapy (HD MTX-based CT) prior to WBRT significantly in-

creased median overall survival (OS) [2]. Consensus supported by several non-randomized clinical trials has long been a multimodal regimen (HD MTX-based CT followed by a WBRT as consolidation treatment) which resulted in median overall survival (OS) of 30 to 50 months [2–4]. However, it has exposed the patients to a substantial risk of radiation-induced neurotoxicity when administered at standard doses (≥ 40 Gy), especially in older patients [5, 6]. Widely accepted uses of cerebral irradiation in PCNSL treatment are exclusive therapy when chemotherapy (CT) is contraindicated and an optional salvage therapy in relapsing patients after first line

Address for correspondence: Dr Loïc Feuvret, MD, Department of Radiation Oncology, APHP, Hôpitaux Universitaires La Pitié Salpêtrière — Charles Foix, F-75013, Paris, France; e-mail: loic.feuvret@gmail.com

This article is available in open access under Creative Common Attribution-Non-Commercial-No Derivatives 4.0 International (CC BY-NC-ND 4.0) license, allowing to download articles and share them with others as long as they credit the authors and the publisher, but without permission to change them in any way or use them commercially

treatment. Major controversy exists in the setting of consolidation radiotherapy (RT) after induction HD MTX-based CT, where clinical benefit is counterbalanced by neurotoxicity risk [7]. An illustration of this ongoing controversy is the recently published clinical case in the “gray zone” section of the international journal of radiation oncology-biology-physics [8]. Here, we will review several alternative strategies that have been investigated in order to optimize treatment efficacy and tolerance and discuss the perspectives of radiation therapy in the management of newly diagnosed PCNSL.

Materials and methods

Search terms were generated by defining population/participants, intervention, comparison, outcome and study design (popularly abbreviated PICOS) [9]. Eligibility criteria were review articles or prospective or retrospective studies analyzing RT in newly diagnosed PCNSL. The exclusion criteria were as follows: case report, articles not written in English or French. References were retrieved from the database MEDLINE via PubMed. The following terms were used: “Primary central nervous system lymphoma” AND “radiotherapy”. The titles and abstracts of articles retrieved using the search strategy were screened to identify articles that potentially met the inclusion criteria. We did not define a starting date and stopped searching on October 19, 2021. The titles and abstracts of the articles retrieved through the search strategy were independently reviewed by two reviewers to identify articles likely to meet the inclusion criteria described above. By checking the references of these articles, other articles were considered eligible for our review.

Where applicable, the weight of the articles (high, intermediate or low) was determined according to the classification of the recommendations for clinical practice guidelines [10].

Overview of the indication and implementation of cerebral irradiation in the treatment of PCNSL

Historical evolution of cranial irradiation as a treatment of PCNSL

Before 1990, the treatment of PCNSL was based on WBRT and corticosteroids. The radiation doses

were heterogeneous and radiation portals used ranged from local field to whole brain. Although it succeeded in most cases in achieving remission, relapses occurred rapidly and survival was poor. Radiation doses of 20–55 Gy (median dose 40 Gy) were reported to produce median OS of 24 months [11] and 42 months [12]. The RTOG 8315 phase II study — the only prospective trial investigating RT alone in PCNSL — evaluated the benefit of a dose escalation strategy, including 41 patients treated with a WBRT to 40 Gy and a 20 Gy boost to tumor. Although complete or almost complete response (disappearance of the tumoral lesion on the post treatment brain scanner, 4 months after the start of RT) was observed in 81% of patients, median OS was limited to 11.6 months, and 5-year OS was below 5%. In patients older than 60 years, survival was even lower with a median OS of 7.6 months. Moreover, despite the 20 Gy boost to the original tumor site, it remained the predominant site of failure [1].

De Angelis et al. showed that systemic MTX-based CT followed by a cranial irradiation (40 Gy WBRT plus a 14 Gy boost) and high dose (HD) Cytarabine allowed a prolonged time to recurrence when compared to systemic MTX-based CT alone (41 months vs. 10 months, $p = 0.003$) and a trend to prolonged survival (42.5 months versus 21.7 months, $p = 0.22$) [2]. Subsequent clinical trials have also suggested that preirradiation CT produces prolonged disease-free and overall survival [3, 4]. A combined treatment with systemic MTX-based CT followed by WBRT has consequently been considered the standard of care [2–4]. However, a randomized phase III clinical trial comparing survival rates of patients treated with the combined treatment compared with patients treated with WBRT alone is lacking.

WBRT field limits

Optic nerves and retinas are histologically considered part of the CNS, and 11.5 to 15% of relapses occur in the ocular globes [13, 14]. Rare cases of optic nerves relapses have been reported in PCNSL patients without any initial ocular involvement [15]. Although a controlled clinical trial regarding the question of ocular irradiation in the treatment of PCNSL is lacking, these observations suggest an inclusion of the posterior part of the orbits and optic nerves in WBRT fields.

Regarding cervical limits, treatment field design for WBRT historically involves 2 parallel opposed fields with the inferior field edge set at C1 or C2 with at least 2 cm of flash posteriorly and superiorly [16]. More recently, guidelines have recommended the inferior limit of the WBRT clinical target volume (CTV) at the skull-C1 junction with 3 to 5 mm margins to delineate the planning target volume (PTV) [17].

Table S1 (Supplementary File) describes the implementation of ocular irradiation and cervical limits applied in the largest and most recent randomized trials involving PCNSL patients treated with a WBRT, and the published guidelines regarding these limits of WBRT fields in patients with newly diagnosed PCNSL.

Radiation-induced neurotoxicity

The drawback of the combined treatment is an increased risk of delayed neurotoxicity, especially in patients older than 60 years old [5, 6]. A retrospective review included 183 patients treated for a PCNSL, among whom 129 patients were treated with WBRT (doses ranging from 36 to 59.4 Gy) and 152 patients with HD MTX-based regimens (111 patients were treated with a combined treatment consisting of HD MTX-based CT followed by WBRT). The cumulative incidence of neurotoxicity was 25% at 2 years and 30% at 5 years. Neurotoxicity was defined as neurologic deterioration following treatment for PCNSL that was not caused by tumor recurrence or another identifiable cause. Univariate analysis found age (≥ 60 years), sex (female), presence of mental status abnormalities (cognitive, psychiatric) at PCNSL diagnosis and WBRT to be statistically significant risk factors for the development of neurotoxicity. In the multivariate analysis, only WBRT remained a significant risk factor of neurotoxicity [6].

Radiation-induced cerebral neurotoxicity is known to depend on the total dose of irradiation, dose per fraction, volume of irradiated brain tissue, associated systemic treatments (medications), age and patient's background (genetic, vascular). Radiation-induced neurotoxicity described after WBRT is clinically defined as a progressive subcortical dementia: psychomotor slowing, executive and memory dysfunction, behavioral changes, gait ataxia, and incontinence. Symptoms are irreversible and, at present, no treatment has shown effi-

cacy at resolving them. Imaging findings show diffuse white matter disease and cortical-subcortical atrophy. Available autopsy data show white matter damage with gliosis, thickening of small vessels, and demyelination [18]. This clinical, radiological and histological description corresponds to radiation-induced leukoencephalopathy [19]. Several independent experiments provided preliminary evidence that Amifostine might play a role in the prevention of radiation-induced neurotoxicity [20]. A randomized controlled trial showed that Memantine significantly delayed time to cognitive decline and reduced the rate of decline in memory, executive function, and processing speed in patients with brain metastases receiving WBRT [21]. A phase III randomized controlled trial in adult brain tumor survivors ≥ 6 months after partial or whole-brain irradiation showed that a treatment with Donepezil resulted in modest improvements in several cognitive functions [22]. However, no pharmacological intervention has shown robust evidence of efficiency in the prevention or management of radiation-induced leukoencephalopathy. Therefore, the role of WBRT at 40 to 50 Gy doses as consolidation treatment of newly diagnosed PCNSL is currently controversial because, although it is efficient, delayed neurotoxicity limits its acceptance as a standard of care. Alternative treatment strategies have been assessed to improve the therapeutic ratio.

Table 1 summarizes the characteristics and survival outcomes of various schemes of consolidation treatment given after immuno- and chemotherapies.

Table 2 summarizes the characteristics and treatment-induced toxicities of various schemes of consolidation treatment given after immuno- and chemotherapies.

Alternative strategies to WBRT as consolidation in first line treatment of PCNSL

Removing or deferring WBRT

In 2000, an unrandomized study compared the outcome and neurotoxicity of older patients (> 60 years old) treated either with HD MTX-based CT alone (22 patients) or with the same HD MTX-based CT and a 45 Gy WBRT (12 patients). Median OS was similar with or without the addi-

Table 1. Characteristics and survival outcomes of various schemes of consolidation treatments given after immuno-chemotherapies

Consolidation treatment	Reference	Number of patients	Weight of article	Description of the irradiation	PFS	OS
None	Thiel et al., 2010 [24]	n = 164	High		Median: 11.9 months	Median: 37.1 months
	Ekenel et al., 2008 [27]	n = 122	Intermediate		Median: 15 months	Median: 39 months
WBRT	Houillier et al., 2019 [29]	n = 66	High	WBRT 40 Gy (2 Gy/fr)	2-year PFS: 58%	2-year OS: 75%
	Ferreri et al., 2017 [30]	n = 59	High	WBRT 36 Gy (1.8 Gy/fr) ± boost 9 Gy (1.8 Gy/fr)	2-year PFS: 76%	2-year OS: 82%
	Ghesquieres et al., 2012 [62]	n = 53	Intermediate	WBRT 26 Gy (2 Gy/fr) + boost 28 Gy (2 Gy/fr) OR WBRT 40 Gy (2 Gy/fr)	2-year PFS: 67%	2-year OS: 82%
	Morris et al., 2013 [32]	n = 52	High	If CR: WBRT 23.4 Gy (1.8 Gy/fr) if not: WBRT 45 Gy (1.8 Gy/fr)	Median: 40 months	Median: 80 months
	Lesueur et al., 2019 [63]	n = 27	Intermediate	If CR: WBRT 23.4 Gy (1.8 Gy/fr)	2-year PFS: 65%	2-year OS: 90.5%
	Thiel et al., 2010 [24]	n = 154	High	WBRT 45 Gy (1.5 Gy/fr)	Median: 18.3	Median: 32.4
	Mishima et al., 2020 [44]	n = 62	High	WBRT 30 Gy ± boost 10 Gy	2-year PFS: 60.6%	2-year OS: 86.8%
WBRT + TMZ	Mishima et al., 2020 [44]	n = 60	High		2-year PFS: 49.9%	2-year OS: 71.4%
HCT-ASCT	Houillier et al., 2019 [29]	n = 66	High		2-year PFS: 70%	2-year OS: 66%
	Ferreri et al., 2017 [30]	n = 59	High		2-year PFS: 75%	2-year OS: 77%
	Abrey et al., 2003 [64]	n = 14	Intermediate		Median: 9.3 months	Median: not reached (median follow-up: 28 months)
	Yoon et al., 2011 [65]	n = 11	Intermediate		Median: 15 months	2-year OS: 88.9%
	Illerhaus et al., 2008 [66]	n = 13	Intermediate		3-year PFS: 77%	3-year OS: 77%
	Omuro et al., 2015 [67]	n = 32	Intermediate		2-year PFS: 81%	2-year OS: 81%
	Montemurro et al., 2007 [68]	n = 16	Intermediate		2-year PFS: 56%	2-year OS: 61%
	Young et al., 2020 [69]	n = 48	Intermediate		2-year PFS: 95.2%	2-year OS: 95.2%
	Schorb et al., 2017 [70]	n = 52	Intermediate		2-year PFS: 80%	2-year OS: 80%
DeFilipp et al., 2017 [71]	n = 41	Intermediate		2-year PFS: 92%	2-year OS: 95%	

MTX — methotrexate; PFS — progression free survival; OS — overall survival; CR — complete response; WBRT — whole brain radiotherapy; HCT-ASCT — high dose chemotherapy with autologous stem cell transplantation; NT — neurotoxicity; NA — not assessed; TMZ — temozolomide; fr — fraction

tion of RT (32 vs. 33 months, respectively), and late neurotoxicity was significantly more common

in patients who received WBRT ($p < 0.001$) [23]. More recently, a phase III non-inferiority study

Table 2. Characteristics and treatment-induced toxicities of various schemes of consolidation treatments given after immuno-chemotherapies

Consolidation treatment	Reference	Number of patients	Weight of article	Description of the irradiation	Toxicity
None	Thiel et al., 2010 [24]	n = 164	High		Treatment related NT in patients with CR: 9/34
	Ekenel et al., 2008 [27]	n = 122	Intermediate		Incidence of NT at 2 years = 4% Incidence of NT at 5 years = 7%
WBRT	Houillier et al., 2019 [29]	n = 66	High	WBRT 40 Gy (2 Gy/fr)	1/53 toxic deaths ≥ 50% of patients had a decline in their test score after WBRT
	Ferreri et al., 2017 [30]	n = 59	High	WBRT 36 Gy (1.8 Gy/fr) ± boost 9 Gy (1.8 Gy/fr)	0/55 toxic deaths Significant impairment in attention and executive functions after WBRT
	Ghesquieres et al., 2012 [62]	n = 53	Intermediate	WBRT 26 Gy (2 Gy/fr) + boost 28 Gy (2 Gy/fr) OR WBRT 40 Gy (2 Gy/fr)	NA
	Morris et al., 2013 [32]	n = 52	High	If CR: WBRT 23.4 Gy (1.8 Gy/fr) if not: WBRT 45 Gy (1.8 Gy/fr)	No cognitive impairment after WBRT
	Lesueur et al., 2019 [63]	n = 27	Intermediate	If CR: WBRT 23.4 Gy (1.8 Gy/fr)	No cognitive impairment after WBRT
	Thiel et al., 2010 [24]	n = 154	High	WBRT 45 Gy (1.5 Gy/fr)	Treatment related NT in patients with CR: 22/45
	Mishima et al., 2020 [44]	n = 62	High	WBRT 30 Gy ± boost 10 Gy	NA
WBRT + TMZ	Mishima et al., 2020 [44]	n = 60	High		NA
HCT-ASCT	Houillier et al., 2019 [29]	n = 66	High		5/44 toxic deaths TMT-A and TMT-B: stable scores after HCT-ASCT
	Ferreri et al., 2017 [30]	n = 59	High		2/58 toxic deaths Attention, executive functions, QoL: significant improvement after HCT-ASCT
	Abrey et al., 2003 [64]	n = 14	Intermediate		No cognitive impairment after HCT-ASCT
	Yoon et al., 2011 [65]	n = 11	Intermediate		0/11 toxic death
	Illerhaus et al., 2008 [66]	n = 13	Intermediate		No severe NT after HCT-ASCT (median follow up: 25 months)
	Omuro et al., 2015 [67]	n = 32	Intermediate		3/32 toxic deaths No cognitive impairment after HCT-ASCT
	Montemurro et al., 2007 [68]	n = 16	Intermediate		NA
	Young et al., 2020 [69]	n = 48	Intermediate		1/27 toxic death
	Schorb et al., 2017 [70]	n = 52	Intermediate		NA
DeFilipp et al., 2017 [71]	n = 41	Intermediate		NA	

MTX — methotrexate; PFS — progression free survival; OS — overall survival; CR — complete response; WBRT — whole brain radiotherapy; HCT-ASCT — high dose chemotherapy with autologous stem cell transplantation; NT — neurotoxicity; NA — not assessed; TMZ — temozolomide; fr — fraction

compared the survival of patients with newly diagnosed PCNSL (55 to 69 years old, median age 63 years) treated with a MTX-based CT regimen or with the same CT regimen followed by WBRT. Five hundred and fifty-one patients were treated per protocol, and WBRT was delivered at a total dose of 45 Gy (30×1.5 Gy). Two-year PFS was higher in the WBRT group than in the group treated with CT alone (43.5% vs. 30.7%, respectively), and there was no significant difference in OS between the two groups [24]. However, the trial failed to meet its non-inferiority end-point, and the methods of this study have been criticized since only 58% of the included patients received the intended treatment. The analysis of quality of life 2 years after the treatment was studied using EORTC-QLQ-C30, EORTC-QLQ-BN20 and MMSE questionnaires. Thirty-seven patients (no WBRT arm) and 33 patients (WBRT arm) were eligible for the analysis of quality of life. Subjective cognitive functioning, global health status and MMSE scores were significantly reduced in the WBRT arm as compared to patients treated with CT alone. Fatigue, appetite loss and hair loss were significantly more intense in the WBRT arm [25]. Several retrospective studies found similar results: a lack of significant impact on OS, despite a possibly lower PFS, of removing or deferring WBRT [26, 27]. A multicentric study retrospectively investigated a response-adjusted approach in PCNSL patients younger than 60 years, deferring WBRT in chemosensitive patients. All patients were treated with induction MTX-based CT, then patients achieving CR received five additional CT cycles and no further treatment (31 patients) while patients with a partial response (PR) or stable disease (SD) were treated with WBRT (9 patients) or high dose chemotherapy with autologous hematopoietic stem cell transplantation (HCT-ASCT) (2 patients). After a median follow-up of 108 months, PFS was disappointing in both the intent-to-treat population and in patients achieving CR after induction CT, thought to have the best chance of achieving prolonged remission (median PFS of 12 months and 22 months, respectively). Therefore, an indication of consolidation treatment is suggested, even in patients achieving CR after induction CT. In the intent-to-treat population, median OS was 63 months which is comparable with survival results in patients treated with MTX-based CT and immediate WBRT. This suggests that salvage

treatment with WBRT or HCT-ASCT in PCNSL patients with PR or SD after induction CT is effective [26] neurotoxicity risks are lower in young (< 60 years). A retrospective study analyzed 122 patients who achieved a CR after initial MTX-based CT. Patients received either no consolidation treatment, or HD Cytarabine alone, or WBRT plus HD Cytarabine, or WBRT alone. There was no difference in OS among patients who received a consolidation treatment. In univariate analysis, PFS was longer in patients who received WBRT plus HD Cytarabine when compared with other groups ($p = 0.03$). However, patients who underwent WBRT plus HD cytarabine were younger (median age: 51 years old) and multivariate analysis did not find a significant effect of the consolidation treatment on PFS nor on OS [27]. A meta-analysis compared the quality-adjusted life expectancy (defined with a Markov state transition model consisting of a number of health states including CR with no neurotoxicity, CR with mild neurotoxicity, CR with severe neurotoxicity, relapse and death) in patients treated with the combined modality therapy (MTX-based CT followed by consolidation WBRT) or with MTX-based CT alone [28]. In patients < 60 years old, there was a benefit of 0.62 quality-adjusted life years (or 7.4 quality-adjusted months) with the combined modality therapy as compared to CT alone. Because of the increased risk of radiation-induced neurotoxicity after the combined modality therapy in patients older than 60 years, quality-adjusted life expectancy was similar in patients treated with the combined modality therapy or with MTX-based CT alone.

In conclusion, it remains unclear whether consolidation WBRT can be safely omitted for younger patients (< 60 years) who reach CR after induction CT.

Replacement of WBRT by HCT-ASCT

PRECIS and IELSG32 trials are two recent phase II randomized studies that aimed to determine the efficacy and toxicity of WBRT or HCT-ASCT as consolidation treatment after induction MTX-based CT in newly diagnosed PCNSL patients ≤ 60 (29) or ≤ 70 years old [30]. Apart from the upper age limit, the PRECIS and IELSG trial differed by several aspects: (i) WBRT delivered 40 Gy (2 Gy/fraction) in the PRECIS trial while a dose of 36 Gy (1.8 Gy/fraction) plus a 9 Gy boost

on the remaining enhancing site in case of PR after induction CT was delivered in the IELSG32 trial; (ii) induction CT, although HD MTX-based in both trials, were not completely similar: R-MBVP (rituximab, MTX 3 g/m², VP16, BCNU, prednisone) followed by R-AraC (rituximab, cytarabine) in the PRECIS trial and MTX 3.5 g/m², cytarabine ± rituximab ± thiotepa in the IELSG32 trial; (iii) randomization between WBRT or HCT-ASCT was done at the time of registration in the PRECIS trial and after response assessment following the induction CT in the IELSG32 trial.

In both trials, 2-year PFS was the primary endpoint.

WBRT and HCT-ASCT were both effective consolidation treatments, and met the predetermined threshold in both trials. In the PRECIS trial, an exploratory comparison of the 2-year survival rates found significantly higher 2-year PFS rates in the HCT-ASCT arm compared to the WBRT arm (87% vs. 63%, respectively), whereas the 2-year OS rates were not significantly different. In the IELSG32 trial, there were no significant differences in 2-year PFS nor in 2-year OS between WBRT and HCT-ASCT (2-year PFS: 80% vs. 69%, 2-year OS: 85% vs. 71%, respectively).

In both trials, the proportion of toxic deaths was higher in the HCT-ASCT arm compared to the WBRT arm (11.4% vs. 1.8% in the PRECIS trial, 3.5% vs. 0% in the IELSG32 trial).

Both trials studied prospectively the impact of treatment on cognitive functions, by estimating the delta value between scores of neuropsychological tests done after treatment and during follow up (after 2 years of follow-up in the IELSG32 trial and after 6, 12, 18, 24 and 36 months of follow up in the PRECIS trial). In the IELSG32 trial, results showed a significant improvement in attention and executive functions [Trail Making Test A (TMT-A), Trail Making Test B (TMT-B), Trail Making Test B–A (TMT-B-A), Phonemic Verbal Fluency (PVF)] and visuoconstructive abilities (Rey Complex Figure Copy Test) in patients treated with HCT-ASCT. In the PRECIS trial, results of monthly variations in the mean scores of neuropsychological tests showed a significant difference between groups in global cognitive function [Mattis Dementia Rating Scale (MDRS)] and executive functions (TMT-A and TMT-B) in favor of HCT-ASCT.

In the absence of phase III trial, the current trend is to favor HCT-ASCT over WBRT at “standard dose” due to the risk of radiation-induced neurotoxicity. However, if the patient is not fit for HCT-ASCT, WBRT remains an alternative consolidation treatment (Fig. 1).

WBRT with reduced dose

The C5R protocol was the first which proposed to decrease the dose of WBRT as consolidation treatment of newly diagnosed PCNSL. It consisted in HD MTX-based CT followed by a WBRT delivering 20 Gy in 2 Gy fractions. However, an additional 30 Gy in 2 Gy fractions boost on the site of the primary tumor before CT was planned. Among the 25 patients included in the study, 18 patients completed the induction CT and received the consolidation cerebral RT as planned by the C5R protocol. Of note, 5 of these patients received a 50 Gy in 2 Gy fractions WBRT because of multiple tumor lesions. All 18 patients who completed the treatment achieved CR or PR. With a median follow-up of 32 months, only 2 of these 18 patients relapsed (respectively, 25 and 96 months after the initial treatment) [3].

Since then, several trials have been conducted to study the feasibility of prescribing lower doses of WBRT in patients who reached CR to induction CT.

In 2002, a multicentric prospective study included 25 patients < 60 years old who reached CR after induction CT. Fifteen patients were treated with a WBRT delivering 45 Gy in 1.8 Gy fractions and 10 received a reduced dose WBRT (30.6 Gy in 1.8 Gy fractions). OS was significantly lower in patients receiving the reduced dose (3-year OS: 92% versus 60% for patients receiving 45 or 30.6 Gy, respectively; $p = 0.04$) and a trend for a higher risk of relapse was observed in patients receiving the reduced dose (3-year risk of relapse: 25% vs. 79% for patients receiving 45 or 30.6 Gy, respectively; $p = 0.06$) [31].

More recently, Memorial Sloan-Kettering Cancer Center (MSKCC) conducted a phase II study including 52 patients, with a median age of 60 years (30 to 79 years). Patients received induction CT (five to seven cycles of R-MPV), then patients who achieved a CR received a reduced dose of WBRT (rdWBRT) (23.4 Gy, 1.8 Gy/fraction) while those with a PR or SD received a standard dose (45 Gy,

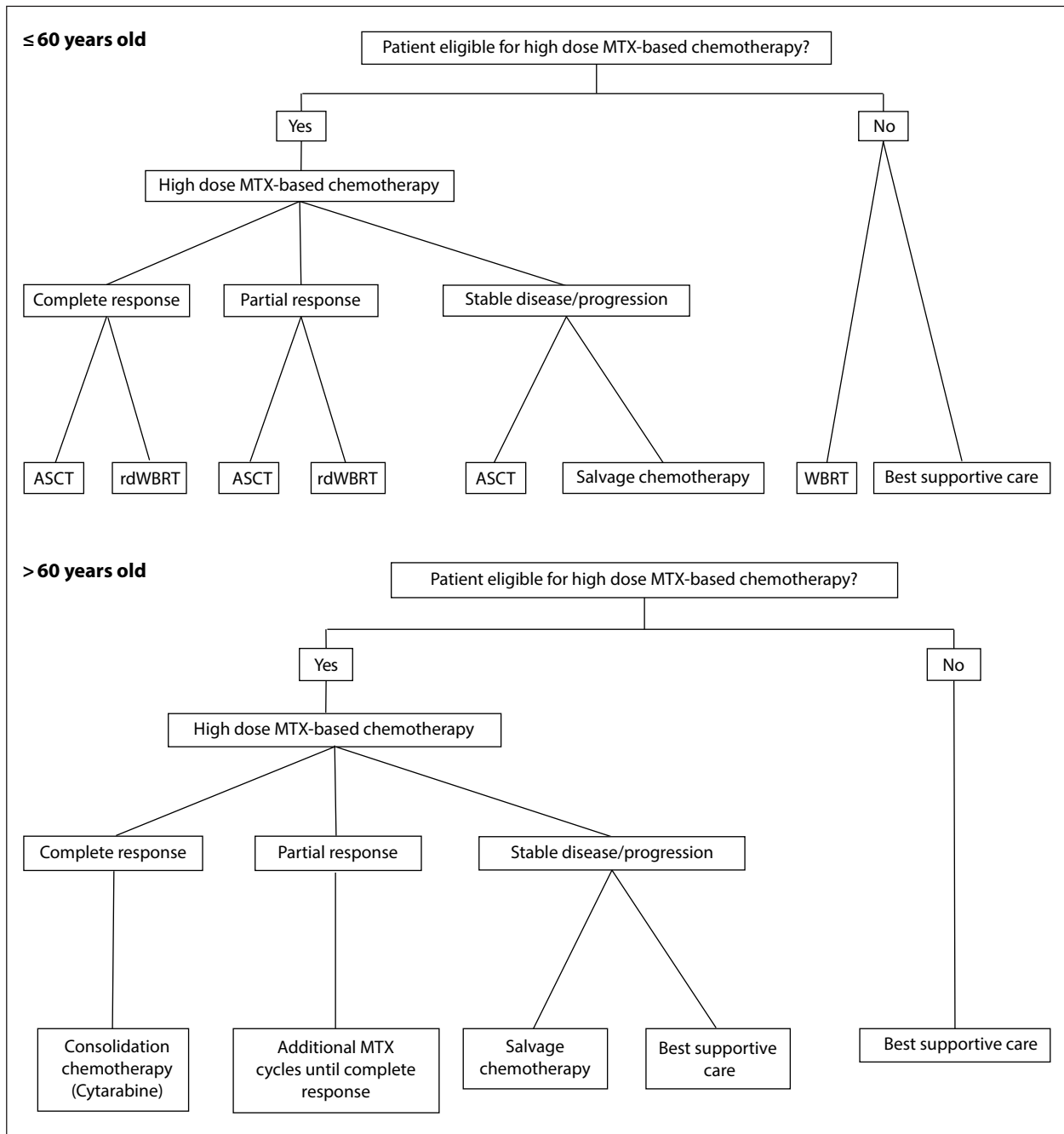


Figure 1. Current recommendations of the different treatment schedules admitted as consolidation of first line treatment of primary central nervous system lymphoma (PCNSL), according to the age and response to induction radiotherapy [34, 35, 74]. ASCT — autologous stem cell transplant; rdWBRT — reduced dose of whole brain radiotherapy; WBRT — whole brain radiotherapy; MTX — methotrexate

1.8 Gy/fraction). After RT, all patients received two consolidation HD cytarabine cycles. In patients treated with rdWBRT (31 patients), 2-year PFS was 77% and 2-year OS was 90%. Among the 12 patients who received rdWBRT and were progression free and completed neuropsychological evaluation at 2 years (median age, 58 years, including

three patients older than 60 years), there was no evidence of significant cognitive decline during the follow-up period, except for motor speed [32]. Cognitive functions of patients achieving long-term remission following rdWBRT (23.4 Gy, 1.8 Gy/fraction) or HCT-ASCT was recently reported: there was a decline in attention/executive

functions and memory after 3 years in both groups, and no significant differences in terms of cognitive performance or quality of life (QoL) [33].

Treating patients achieving CR after induction CT with a rdWBRT was therefore considered effective, and current guidelines recommend this approach [34] or offer it as an option [35] (Fig. 1).

These results prompt up the RTOG to set up a randomized trial (NCT01399372) comparing the efficacy of a CT-only, MSKCC regimen (see above) or the same CT regimen with rdWBRT (23.4 Gy in 1.8 Gy fractions) prior to cytarabine as first line treatment of PCNSL. A secondary objective is to determine the treatment-related neurotoxicity rates in each arm.

Preliminary results were recently published: 91 newly diagnosed patients were randomized, median age was 59 years in the CT arm and 66 years in the CT + rdWBRT arm. After a median follow-up

of 55 months, median PFS was 25 months in the CT arm and not reached in the CT + rdWBRT arm ($p = 0.015$). The 2-year PFS was 54% in the CT arm and 78% in the CT + rdWBRT arm. Median OS was not reached in either arm. The rate of clinically-defined moderate to severe neuro-toxicity was 11.4% in the CT arm and 14% in the CT + rdWBRT arm ($p=0.75$). The study therefore met its primary endpoint, demonstrating that the addition of rdWBRT to R-MPV-A improves PFS in newly diagnosed PCNSL. Neurotoxicity rates at time of analysis were not increased, but more follow-up is needed [36]. Further neuropsychological assessments and neuroimaging analyses are ongoing to characterize cognitive decline and compare it to other consolidation treatments.

Table 3 summarizes irradiation doses and volumes applied in the largest and most recent randomized trials and current guidelines of irradiation

Table 3. Doses and volumes applied in the largest and most recent randomized trials, and current guidelines of irradiation doses and volumes in whole brain radiotherapy (WBRT) as consolidation treatment of newly diagnosed primary central nervous system lymphoma (PCNSL)

	Complete response	Partial response
PRECIS trial [29]		WBRT 40 Gy 2 Gy/fr
IELSG32 trial [30]	WBRT 36 Gy 1.8 Gy/fr	WBRT 36 Gy 1.8 Gy/fr + Boost to 45 Gy 1.8 Gy/fr
French recommendations from the LOC network, 2014–2015 [72]	WBRT [23–30] Gy [1.8–2] Gy/fraction	WBRT 40 Gy [1.8–2] Gy/fraction
ILROG guidelines, 2015 [34]	WBRT 24 Gy 2 Gy/fraction	WBRT [36–45] Gy 1.5–1.8 Gy/fraction
Guidelines for the diagnosis and management of primary central nervous system diffuse large B-cell lymphoma, 2018 [35]	WBRT 36 Gy 1.8 Gy/fraction	WBRT 36 Gy 1.8 Gy/fraction + Boost to 45 Gy 1.8 Gy/fraction
NCCN guidelines Version 3.2020 Central Nervous System Cancers [73]	WBRT 23.4 Gy 1.8 Gy/fraction	WBRT [30–36] Gy + Boost to 45 Gy [1.8–2] Gy/fraction

ILROG — International Lymphoma Radiation Oncology Group; NCCN — National Comprehensive Cancer Network; WBRT — whole brain radiotherapy

doses and volumes in consolidation treatment of newly diagnosed PCNSL.

Radiosensitization of WBRT with concomitant temozolomide

Temozolomide (TMZ) is an oral alkylating agent that has shown anti-tumor activity in PCNSL in single arm studies [37–39].

A phase III trial showed a significant improvement in survival of glioblastoma patients treated with surgical resection followed by adjuvant RT plus TMZ given concomitantly with and after RT as compared to the same regimen without TMZ [40]. TMZ is known to be more active in glioblastoma patients who have a methylation of the MGMT promoter [41]. A proportion of patients with PCNSL also exhibit methylation of the MGMT promoter, which suggests a role for TMZ in this disease: a retrospective study explored the efficiency of TMZ monotherapy in the treatment of PCNSL in 17 elderly patients with severe comorbidities (3 of whom had a methylation of the MGMT promoter). The CR rate was 47% and median OS was 21 months (42). A phase II trial investigated the treatment of PCNSL with HD MTX, TMZ, and rituximab, followed by hyperfractionated WBRT and subsequent TMZ. Compared with historical controls from RTOG 93-10, 2-year OS and PFS were significantly improved ($p = 0.006$ and 0.03 , respectively) [43]. Based on these results, a phase III trial was recently done to examine whether the benefit of TMZ concomitant and adjuvant to RT can be found in PCNSL patients. The study randomized 122 patients with newly diagnosed PCNSL, after a HD-MTX CT regimen (MTX; 3.5 g/m^2 at day 1, 15, 29), between the control arm (WBRT, $30 \text{ Gy} \pm 10 \text{ Gy}$ boost) and the experimental arm (WBRT \pm boost with concomitant and adjuvant TMZ). Two-year PFS was 60.6% in the control arm and 49.9% in the experimental arm, and 2-year OS was 86.6% in the control arm and 71.4% in the experimental arm. Thus, this study failed to demonstrate the benefit of the addition of TMZ to WBRT [44].

A phase II trial (NCT03495960) is ongoing on elderly patients (≥ 70 years old) ineligible for HD MTX, to assess the efficacy of concomitant WBRT, TMZ and rituximab as induction therapy, followed by TMZ as maintenance treatment.

Reduction of irradiation target volume

Among patients with 1 to 3 brain metastases, the use of a focal stereotactic radiotherapy (SRS) alone resulted in less cognitive deterioration at 3 months than SRS combined with WBRT [45]. Thus, the current approach is to favor partial irradiation in patients with brain metastases. In patients with PCNSL, studies were conducted to assess whether the irradiation target volume could be safely reduced to partial-brain radiotherapy (PBRT), in order to reduce the radiation-induced neurotoxicity.

Iwabuchi et al. retrospectively analyzed the outcome of 16 PCNSL patients treated with PBRT (54 Gy , 2 Gy/fraction , focused on the initial enhancing lesion plus 4 cm margins) following a HD-MTX based CT regimen (MTX 3.5 g/m^2 alone in 9 patients, MTX 3.5 g/m^2 + rituximab in 6 patients, MTX 3.5 g/m^2 + rituximab + procarbazine + vincristine in 1 patient) [46]. The 3-year OS and PFS were, respectively, 68% and 36%. The in-field and outfield recurrence rates at 3 years were 27% and 21%, respectively. Late symptomatic neurotoxicity was encountered in 3 of the 16 (19%) patients, all of whom were ≥ 58 years old.

A prospective observational cohort study showed significantly improved survival rates in PCNSL patients treated with HD MTX-based CT followed by Gamma Knife single fraction radiosurgery compared to patients treated with HD MTX-based CT alone. Seventy-three patients received HD MTX-based CT alone and 55 patients received CT followed by Gamma Knife single fraction radiosurgery. There were no significant differences in patient demographics and histology was a large diffuse B-cell lymphoma in all patients. Gamma Knife single fraction radiosurgery doses were ranging from 11 Gy to 16 Gy (median: 11 Gy) to the 50% isodose line. Median OS was 47.6 months in patients who received HD MTX-based CT followed by Gamma Knife single fraction radiosurgery versus 26.8 months in patients who received HD MTX-based CT alone ($p = 0.0034$) [47].

A study of the pattern of relapse in PCNSL after partial brain irradiation showed that the cumulative in-field and out-field recurrence rates at 5 years were 57% and 49%, respectively, and that the out-field recurrence rate was 22% for patients treated with safety margins $\geq 4 \text{ cm}$ and 83%

for those treated with safety margins < 4 cm ($p = 0.0079$) [48]. A study of the pattern of relapse in PCNSL after first line CT alone (without cerebral irradiation) showed that 46% of relapses occurred in the initial tumoral site, 40% distant from the initial tumoral site and 14% in both [13]. Autopsy studies revealed that most PCNSL extensively infiltrate the brain, even far from radiologically detected sites [19].

In that respect, partial irradiation in PCNSL patients appears counter-intuitive regarding the infiltrative nature of the disease, and the efficiency of this approach has not been convincingly demonstrated. WBRT thus remains the standard RT approach. In case a partial irradiation was performed, safety margins should be ≥ 4 cm.

Conformal avoidance of the hippocampus during WBRT is known to be associated with preservation of memory and QOL as compared with historical series [49]. In this study, included patients had brain metastases outside a 5 mm margin around either hippocampus, and bilateral hippocampal contours were expanded by 5 mm to generate the hippocampal avoidance regions. Detailed data are still lacking regarding the possibility of sparing the hippocampal region in PCNSL patients. A study considered 36 patients with 57 PCNSL lesions (defined as T1 weighted contrast enhancement after HD MTX-based CT), and found 18 out of 57 lesions (31.6%) localized less than 5 mm from the hippocampus region and seven of them (12%) involving the hippocampus [50]. This high rate of PCNSL lesions near the hippocampus region does not encourage conformal avoidance of the hippocampus during WBRT in this indication.

Before the introduction of combined modality treatment with HD MTX-based CT prior to cerebral irradiation, it was generally agreed that a boost to the tumor bed should be employed [12, 51–55]. However, in the RTOG 8315 prospective trial patients treated with 40 Gy WBRT and a 20 Gy boost to tumor bed had a low median survival of 11.6 months. Although the poor prognosis may have been related to age (median age: 66 years), the 60 Gy irradiated tumor bed was the predominant site of failure which does not encourage a dose-escalation strategy to increase PCNSL local control [1]. A retrospective analysis of 50 studies published between 1980 and 1995 regarding

the therapeutic management of PCNSL in a total of 1180 immunocompetent patients did not find, in patients treated with RT alone, tumor bed dose to be an independent prognostic factor [56].

Some retrospective series suggest an additional boost to rdWBRT may be valuable in case of a PR after induction CT [57–59], although the efficiency of this strategy has never been demonstrated.

Current recommendations of irradiation volumes are visible in Table 3.

No data support the prescription of craniospinal RT in patients with PCNSL involving the cerebrospinal fluid. Indeed, craniospinal RT provides considerable toxicity (neurologic, haematologic, digestive) and may compromise a subsequent CT due to bone marrow toxicity.

Hyperfractionation

Hyperfractionation is defined as a dose per fraction < 1.8 Gy. It allows normal tissues to repair sublethal radiation damage, and should therefore theoretically minimize deleterious effects on normal brain structures and reduce the risk of leukoencephalopathy.

In the prospective RTOG 93-10 trial, after a HD MTX-based CT, 16 patients in CR received a hyperfractionated WBRT (36 Gy, 1.2 Gy/fraction) and 27 patients in CR received a normofractionated WBRT (45 Gy, 1.8 Gy/fraction). Severe (grade 3, 4 or 5) neurotoxicity was observed in 23% of patients treated with hyperfractionated RT compared with only 3.7% of those treated with normofractionated WBRT. There was no significant difference in MMSE scores at 8 months between the 2 groups, nor in time to decrease of MMSE score below 24, used as a measure of dementia [14]. A secondary analysis found, by 4 years, 2/16 (13%) grade 5 encephalopathies in patients treated with hyperfractionated RT and 0/27 (0%) in patients treated with normofractionated RT [60].

A phase II study investigated the treatment of PCNSL patients < 65 years old with HD MTX-based CT and HCT-ASCT followed by hyperfractionated WBRT (45 Gy, 1 Gy/fraction, 2 fractions/day). After a median follow-up of 63 months, five of 30 patients (16.7%) developed leukoencephalopathy [61].

These data suggest that hyperfractionated was not effective in preventing from radiation-induced neurotoxicity.

Conclusion

The risk of radiation-induced neurotoxicity in older (> 60 years old) newly diagnosed PCNSL patients treated with WBRT at doses > 40 Gy is important. Hence, this procedure is no longer recommended. In younger patients (≤ 60 years old) the risk of radiation-induced neurotoxicity is lower, although it remains present. Hence, in younger patients, WBRT at doses > 40 Gy can be regarded as a consolidation treatment in the same way as HCT-ASCT after a case-by-case discussion (HCT-ASCT is favored for fit patients while WBRT remains preferential for unfit patients).

Recently, a randomized clinical trial comparing newly diagnosed PCNSL patients treated with CT only and with CT + rdWBRT (23.4 Gy in 1.8 Gy fractions) showed a significant benefit of the addition of the rdWBRT consolidation treatment on local control (PFS) but not on OS. The use of rdWBRT has shown encouraging results in terms of neurotoxicity.

A dose-escalation strategy with the addition of a boost to the original tumor site has failed to demonstrate efficiency on local control or on survival. Autopsy and pattern of relapse reports lead to consider PCNSL as a very infiltrative disease throughout the brain. For that reason, partial brain irradiation and hippocampal avoidance approaches do not seem to be adapted to the treatment of PCNSL. Due to its considerable toxicity, there is no place for craniospinal RT in the treatment of patients with a PCNSL involving the cerebrospinal fluid. Hyperfractionation has failed to show efficiency in the prevention of radiation-induced neurotoxicity. Perspectives in the treatment of PCNSL patients are: (i) the use of targeted therapies or anti-PD1 immunotherapies in association with HD MTX-based induction CT. LOC-R01 (NCT04446962) is currently running to study the feasibility and efficiency of Lenalidomide or Ibrutinib to a HD MTX-based CT. (ii) The evaluation of the use of neuroprotective therapies (as Memantine) which have shown efficiency on cognitive decline in patients receiving WBRT for the treatment of brain metastases. (iii) A better evaluation of the response to treatment thanks to imaging examinations (multimodal MRI, TEP TDM) enabling a better distinction between tumoral and radiation-in-

duced white matter abnormalities, both resulting in flair-weighted hypersignal.

Prospective clinical trials and consensual guidelines are needed in the treatment of PCNSL. The efficiency of therapeutic approaches must be studied with regard to treatment-induced neurotoxicity and quality of life.

Conflicts of interest

None declared.

Funding

This publication was prepared without any external source of funding.

Ethical permission

Ethical approval was not necessary for the preparation of this article.

References

1. Nelson DF, Martz KL, Bonner H, et al. Non-Hodgkin's lymphoma of the brain: can high dose, large volume radiation therapy improve survival? Report on a prospective trial by the Radiation Therapy Oncology Group (RTOG): RTOG 8315. *Int J Radiat Oncol Biol Phys.* 1992; 23(1): 9–17, doi: [10.1016/0360-3016\(92\)90538-s](https://doi.org/10.1016/0360-3016(92)90538-s), indexed in Pubmed: [1572835](https://pubmed.ncbi.nlm.nih.gov/1572835/).
2. DeAngelis LM, Yahalom J, Thaler HT, et al. Combined modality therapy for primary CNS lymphoma. *J Clin Oncol.* 1992; 10(4): 635–643, doi: [10.1200/JCO.1992.10.4.635](https://doi.org/10.1200/JCO.1992.10.4.635), indexed in Pubmed: [1548527](https://pubmed.ncbi.nlm.nih.gov/1548527/).
3. Blay JY, Bouhour D, Carrie C, et al. The C5R protocol: a regimen of high-dose chemotherapy and radiotherapy in primary cerebral non-Hodgkin's lymphoma of patients with no known cause of immunosuppression. *Blood.* 1995; 86(8): 2922–2929, indexed in Pubmed: [7579384](https://pubmed.ncbi.nlm.nih.gov/7579384/).
4. Glass J, Gruber ML, Cher L, et al. Preirradiation methotrexate chemotherapy of primary central nervous system lymphoma: long-term outcome. *J Neurosurg.* 1994; 81(2): 188–195, doi: [10.3171/jns.1994.81.2.0188](https://doi.org/10.3171/jns.1994.81.2.0188), indexed in Pubmed: [8027800](https://pubmed.ncbi.nlm.nih.gov/8027800/).
5. Abrey LE, DeAngelis LM, Yahalom J. Long-term survival in primary CNS lymphoma. *J Clin Oncol.* 1998; 16(3): 859–863, doi: [10.1200/JCO.1998.16.3.859](https://doi.org/10.1200/JCO.1998.16.3.859), indexed in Pubmed: [9508166](https://pubmed.ncbi.nlm.nih.gov/9508166/).
6. Omuro AMP, Ben-Porat LS, Panageas KS, et al. Delayed neurotoxicity in primary central nervous system lymphoma. *Arch Neurol.* 2005; 62(10): 1595–1600, doi: [10.1001/archneur.62.10.1595](https://doi.org/10.1001/archneur.62.10.1595), indexed in Pubmed: [16216945](https://pubmed.ncbi.nlm.nih.gov/16216945/).
7. Citterio G, Ferreri AJ, Reni M. Current uses of radiation therapy in patients with primary CNS lymphoma. *Expert Rev Anticancer Ther.* 2013; 13(11): 1327–1337, doi: [10.1586/14737140.2013.851007](https://doi.org/10.1586/14737140.2013.851007), indexed in Pubmed: [24152125](https://pubmed.ncbi.nlm.nih.gov/24152125/).
8. Dabaja B, Milgrom S, Parikh R, et al. The Challenges of Applying Radiation in Primary Central Nervous System Lymphoma. *Int J Radiat Oncol Biol Phys.* 2020; 107(3):

- 398–400, doi: [10.1016/j.ijrobp.2020.02.466](https://doi.org/10.1016/j.ijrobp.2020.02.466), indexed in Pubmed: [32531380](https://pubmed.ncbi.nlm.nih.gov/32531380/).
9. Methley AM, Campbell S, Chew-Graham C, et al. PICO, PICOS and SPIDER: a comparison study of specificity and sensitivity in three search tools for qualitative systematic reviews. *BMC Health Serv Res.* 2014; 14: 579, doi: [10.1186/s12913-014-0579-0](https://doi.org/10.1186/s12913-014-0579-0), indexed in Pubmed: [25413154](https://pubmed.ncbi.nlm.nih.gov/25413154/).
 10. American Academy of Pediatrics Steering Committee on Quality Improvement and Management. Classifying recommendations for clinical practice guidelines. *Pediatrics.* 2004; 114(3): 874–877, doi: [10.1542/peds.2004-1260](https://doi.org/10.1542/peds.2004-1260), indexed in Pubmed: [15342869](https://pubmed.ncbi.nlm.nih.gov/15342869/).
 11. Letendre L, Banks PM, Reese DF, et al. Primary lymphoma of the central nervous system. *Cancer.* 1982; 49(5): 939–943, doi: [10.1002/1097-0142\(19820301\)49:5<939::aid-cn-cr2820490518>3.0.co;2-1](https://doi.org/10.1002/1097-0142(19820301)49:5<939::aid-cn-cr2820490518>3.0.co;2-1), indexed in Pubmed: [7059928](https://pubmed.ncbi.nlm.nih.gov/7059928/).
 12. Littman P, Wang CC. Reticulum cell sarcoma of the brain. A review of the literature and a study of 19 cases. *Cancer.* 1975; 35(5): 1412–1420, doi: [10.1002/1097-0142\(197505\)35:5<1412::aid-cn-cr2820350526>3.0.co;2-t](https://doi.org/10.1002/1097-0142(197505)35:5<1412::aid-cn-cr2820350526>3.0.co;2-t), indexed in Pubmed: [1091348](https://pubmed.ncbi.nlm.nih.gov/1091348/).
 13. Tabouret E, Houillier C, Martin-Duverneuil N, et al. Patterns of response and relapse in primary CNS lymphomas after first-line chemotherapy: imaging analysis of the ANOCEF-GOELAMS prospective randomized trial. *Neuro Oncol.* 2017; 19(3): 422–429, doi: [10.1093/neuonc/now238](https://doi.org/10.1093/neuonc/now238), indexed in Pubmed: [27994065](https://pubmed.ncbi.nlm.nih.gov/27994065/).
 14. DeAngelis LM, Seiferheld W, Schold SC, et al. Radiation Therapy Oncology Group Study 93-10. Combination chemotherapy and radiotherapy for primary central nervous system lymphoma: Radiation Therapy Oncology Group Study 93-10. *J Clin Oncol.* 2002; 20(24): 4643–4648, doi: [10.1200/JCO.2002.11.013](https://doi.org/10.1200/JCO.2002.11.013), indexed in Pubmed: [12488408](https://pubmed.ncbi.nlm.nih.gov/12488408/).
 15. Ahle G, Touitou V, Cassoux N, et al. Optic Nerve Infiltration in Primary Central Nervous System Lymphoma. *JAMA Neurol.* 2017; 74(11): 1368–1373, doi: [10.1001/jamaneurol.2017.2545](https://doi.org/10.1001/jamaneurol.2017.2545), indexed in Pubmed: [28973119](https://pubmed.ncbi.nlm.nih.gov/28973119/).
 16. Lee NY, Riaz N, Lu JJ. Target Volume Delineation for Conformal and Intensity-Modulated Radiation Therapy. Springer 2014: 524.
 17. Latorzeff I, Antoni D, Gaudaire-Josset S, et al. Radiothérapie des métastases cérébrales. *Cancer/Radiothérapie.* 2016; 20: S80–S87, doi: [10.1016/j.canrad.2016.07.041](https://doi.org/10.1016/j.canrad.2016.07.041).
 18. Vigliani MC, Duyckaerts C, Hauw JJ, et al. Dementia following treatment of brain tumors with radiotherapy administered alone or in combination with nitrosourea-based chemotherapy: a clinical and pathological study. *J Neurooncol.* 1999; 41(2): 137–149, doi: [10.1023/a:1006183730847](https://doi.org/10.1023/a:1006183730847), indexed in Pubmed: [10222434](https://pubmed.ncbi.nlm.nih.gov/10222434/).
 19. Lai R, Rosenblum MK, DeAngelis LM. Primary CNS lymphoma: a whole-brain disease? *Neurology.* 2002; 59(10): 1557–1562, doi: [10.1212/01.wnl.0000034256.20173.ea](https://doi.org/10.1212/01.wnl.0000034256.20173.ea), indexed in Pubmed: [12451197](https://pubmed.ncbi.nlm.nih.gov/12451197/).
 20. Nieder C, Andratschke NH, Wiedenmann N, et al. Prevention of radiation-induced central nervous system toxicity: a role for amifostine? *Anticancer Res.* 2004; 24(6): 3803–3809, indexed in Pubmed: [15736415](https://pubmed.ncbi.nlm.nih.gov/15736415/).
 21. Brown PD, Pugh S, Laack NN, et al. Radiation Therapy Oncology Group (RTOG). Memantine for the prevention of cognitive dysfunction in patients receiving whole-brain radiotherapy: a randomized, double-blind, placebo-controlled trial. *Neuro Oncol.* 2013; 15(10): 1429–1437, doi: [10.1093/neuonc/not114](https://doi.org/10.1093/neuonc/not114), indexed in Pubmed: [23956241](https://pubmed.ncbi.nlm.nih.gov/23956241/).
 22. Rapp SR, Case LD, Peiffer A, et al. Donepezil for Irradiated Brain Tumor Survivors: A Phase III Randomized Placebo-Controlled Clinical Trial. *J Clin Oncol.* 2015; 33(15): 1653–1659, doi: [10.1200/JCO.2014.58.4508](https://doi.org/10.1200/JCO.2014.58.4508), indexed in Pubmed: [25897156](https://pubmed.ncbi.nlm.nih.gov/25897156/).
 23. Abrey LE, Yahalom J, DeAngelis LM. Treatment for primary CNS lymphoma: the next step. *J Clin Oncol.* 2000; 18(17): 3144–3150, doi: [10.1200/JCO.2000.18.17.3144](https://doi.org/10.1200/JCO.2000.18.17.3144), indexed in Pubmed: [10963643](https://pubmed.ncbi.nlm.nih.gov/10963643/).
 24. Seidel S, Margold M, Kowalski T, et al. German Primary Central Nervous System Lymphoma Study Group, German Primary Central Nervous System Lymphoma Study Group (G-PCNSL-SG). Carboxypeptidase G2 rescue in a 79 year-old patient with cranial lymphoma after high-dose methotrexate induced acute renal failure. *Leuk Lymphoma.* 1999; 35(5-6): 631–635, doi: [10.1080/10428199909169631](https://doi.org/10.1080/10428199909169631), indexed in Pubmed: [10609804](https://pubmed.ncbi.nlm.nih.gov/10609804/).
 25. Herrlinger U, Schäfer N, Fimmers R, et al. Early whole brain radiotherapy in primary CNS lymphoma: negative impact on quality of life in the randomized G-PCNSL-SG1 trial. *J Cancer Res Clin Oncol.* 2017; 143(9): 1815–1821, doi: [10.1007/s00432-017-2423-5](https://doi.org/10.1007/s00432-017-2423-5), indexed in Pubmed: [28434043](https://pubmed.ncbi.nlm.nih.gov/28434043/).
 26. Omuro A, Taillandier L, Chinot O, et al. ANOCEF Group (French Neuro-Oncology Association). Primary CNS lymphoma in patients younger than 60: can whole-brain radiotherapy be deferred? *J Neurooncol.* 2011; 104(1): 323–330, doi: [10.1007/s11060-010-0497-x](https://doi.org/10.1007/s11060-010-0497-x), indexed in Pubmed: [21170569](https://pubmed.ncbi.nlm.nih.gov/21170569/).
 27. Ekenel M, Iwamoto FM, Ben-Porat LS, et al. Primary central nervous system lymphoma: the role of consolidation treatment after a complete response to high-dose methotrexate-based chemotherapy. *Cancer.* 2008; 113(5): 1025–1031, doi: [10.1002/cncr.23670](https://doi.org/10.1002/cncr.23670), indexed in Pubmed: [18618509](https://pubmed.ncbi.nlm.nih.gov/18618509/).
 28. Prica A, Chan K, Cheung MC. Combined modality therapy versus chemotherapy alone as an induction regimen for primary central nervous system lymphoma: a decision analysis. *Br J Haematol.* 2012; 158(5): 600–607, doi: [10.1111/j.1365-2141.2012.09208.x](https://doi.org/10.1111/j.1365-2141.2012.09208.x), indexed in Pubmed: [22734565](https://pubmed.ncbi.nlm.nih.gov/22734565/).
 29. Houillier C, Dureau S, Taillandier L, et al. LOC Network for CNS Lymphoma, Intergroupe GOELAMS-ANOCEF and the LOC Network for CNS Lymphoma. Recurrent mutations of MYD88 and TBL1XR1 in primary central nervous system lymphomas. *Clin Cancer Res.* 2012; 18(19): 5203–5211, doi: [10.1158/1078-0432.CCR-12-0845](https://doi.org/10.1158/1078-0432.CCR-12-0845), indexed in Pubmed: [22837180](https://pubmed.ncbi.nlm.nih.gov/22837180/).
 30. Ferreri AJM, Cwynarski K, Pulczynski E, et al. International Extranodal Lymphoma Study Group (IELSG), International Extranodal Lymphoma Study Group (IELSG). Chemoimmunotherapy with methotrexate, cytarabine, thiopeta, and rituximab (MATRix regimen) in patients with primary CNS lymphoma: results of the first randomisation of the International Extranodal Lymphoma Study Group-32 (IELSG32) phase 2 trial. *Lancet Haematol.* 2016; 3(5): e217–e227, doi: [10.1016/S2352-3026\(16\)00036-3](https://doi.org/10.1016/S2352-3026(16)00036-3), indexed in Pubmed: [27132696](https://pubmed.ncbi.nlm.nih.gov/27132696/).
 31. Bessell EM, López-Guillermo A, Villá S, et al. Importance of radiotherapy in the outcome of patients with primary CNS

- lymphoma: an analysis of the CHOD/BVAM regimen followed by two different radiotherapy treatments. *J Clin Oncol.* 2002; 20(1): 231–236, doi: [10.1200/JCO.2002.20.1.231](https://doi.org/10.1200/JCO.2002.20.1.231), indexed in Pubmed: [11773174](https://pubmed.ncbi.nlm.nih.gov/11773174/).
32. Morris PG, Correa DD, Yahalom J, et al. Rituximab, methotrexate, procarbazine, and vincristine followed by consolidation reduced-dose whole-brain radiotherapy and cytarabine in newly diagnosed primary CNS lymphoma: final results and long-term outcome. *J Clin Oncol.* 2013; 31(31): 3971–3979, doi: [10.1200/JCO.2013.50.4910](https://doi.org/10.1200/JCO.2013.50.4910), indexed in Pubmed: [24101038](https://pubmed.ncbi.nlm.nih.gov/24101038/).
 33. Correa DD, Braun E, Kryza-Lacombe M, et al. Longitudinal cognitive assessment in patients with primary CNS lymphoma treated with induction chemotherapy followed by reduced-dose whole-brain radiotherapy or autologous stem cell transplantation. *J Neurooncol.* 2019; 144(3): 553–562, doi: [10.1007/s11060-019-03257-1](https://doi.org/10.1007/s11060-019-03257-1), indexed in Pubmed: [31377920](https://pubmed.ncbi.nlm.nih.gov/31377920/).
 34. Yahalom J, Illidge T, Specht L, et al. International Lymphoma Radiation Oncology Group. Modern radiation therapy for extranodal lymphomas: field and dose guidelines from the International Lymphoma Radiation Oncology Group. *Int J Radiat Oncol Biol Phys.* 2015; 92(1): 11–31, doi: [10.1016/j.ijrobp.2015.01.009](https://doi.org/10.1016/j.ijrobp.2015.01.009), indexed in Pubmed: [25863750](https://pubmed.ncbi.nlm.nih.gov/25863750/).
 35. Fox CP, Phillips EH, Smith J, et al. British Society for Haematology. Guidelines for the diagnosis and management of primary central nervous system diffuse large B-cell lymphoma. *Br J Haematol.* 2019; 184(3): 348–363, doi: [10.1111/bjh.15661](https://doi.org/10.1111/bjh.15661), indexed in Pubmed: [30467845](https://pubmed.ncbi.nlm.nih.gov/30467845/).
 36. Omuro A, DeAngelis L, Karrison T, et al. Randomized phase II study of rituximab, methotrexate (MTX), procarbazine, vincristine, and cytarabine (R-MPV-A) with and without low-dose whole-brain radiotherapy (LD-WBRT) for newly diagnosed primary CNS lymphoma (PCNSL). *J Clin Oncol.* 2020; 38(15_suppl): 2501–2501, doi: [10.1200/jco.2020.38.15_suppl.2501](https://doi.org/10.1200/jco.2020.38.15_suppl.2501).
 37. Herrlinger U, Küker W, Platten M, et al. First-line therapy with temozolomide induces regression of primary CNS lymphoma. *Neurology.* 2002; 58(10): 1573–1574, doi: [10.1212/wnl.58.10.1573](https://doi.org/10.1212/wnl.58.10.1573), indexed in Pubmed: [12034807](https://pubmed.ncbi.nlm.nih.gov/12034807/).
 38. Omuro AMP, Taillandier L, Chinot O, et al. Temozolomide and methotrexate for primary central nervous system lymphoma in the elderly. *J Neurooncol.* 2007; 85(2): 207–211, doi: [10.1007/s11060-007-9397-0](https://doi.org/10.1007/s11060-007-9397-0), indexed in Pubmed: [17896079](https://pubmed.ncbi.nlm.nih.gov/17896079/).
 39. Reni M, Mason W, Zaja F, et al. Salvage chemotherapy with temozolomide in primary CNS lymphomas: preliminary results of a phase II trial. *Eur J Cancer.* 2004; 40(11): 1682–1688, doi: [10.1016/j.ejca.2004.03.008](https://doi.org/10.1016/j.ejca.2004.03.008), indexed in Pubmed: [15251157](https://pubmed.ncbi.nlm.nih.gov/15251157/).
 40. Stupp R, Mason WP, van den Bent MJ, et al. European Organisation for Research and Treatment of Cancer Brain Tumor and Radiotherapy Groups, National Cancer Institute of Canada Clinical Trials Group. Radiotherapy plus concomitant and adjuvant temozolomide for glioblastoma. *N Engl J Med.* 2005; 352(10): 987–996, doi: [10.1056/NEJMoa043330](https://doi.org/10.1056/NEJMoa043330), indexed in Pubmed: [15758009](https://pubmed.ncbi.nlm.nih.gov/15758009/).
 41. Hegi ME, Diserens AC, Gorlia T, et al. MGMT gene silencing and benefit from temozolomide in glioblastoma. *N Engl J Med.* 2005; 352(10): 997–1003, doi: [10.1056/NEJMoa043331](https://doi.org/10.1056/NEJMoa043331), indexed in Pubmed: [15758010](https://pubmed.ncbi.nlm.nih.gov/15758010/).
 42. Kurzweily D, Glas M, Roth P, et al. Primary CNS lymphoma in the elderly: temozolomide therapy and MGMT status. *J Neurooncol.* 2010; 97(3): 389–392, doi: [10.1007/s11060-009-0032-0](https://doi.org/10.1007/s11060-009-0032-0), indexed in Pubmed: [19841864](https://pubmed.ncbi.nlm.nih.gov/19841864/).
 43. Glass J, Won M, Schultz CJ, et al. Phase I and II Study of Induction Chemotherapy With Methotrexate, Rituximab, and Temozolomide, Followed By Whole-Brain Radiotherapy and Postirradiation Temozolomide for Primary CNS Lymphoma: NRG Oncology RTOG 0227. *J Clin Oncol.* 2016; 34(14): 1620–1625, doi: [10.1200/JCO.2015.64.8634](https://doi.org/10.1200/JCO.2015.64.8634), indexed in Pubmed: [27022122](https://pubmed.ncbi.nlm.nih.gov/27022122/).
 44. Yamasaki F, Fudaba H, Asano K, et al. International Extranodal Lymphoma Study Group (IELSG). High-dose methotrexate with or without whole brain radiotherapy for primary CNS lymphoma (G-PCNSL-SG-1): a phase 3, randomised, non-inferiority trial. *Lancet Oncol.* 2010; 11(11): 1036–1047, doi: [10.1016/S1470-2045\(10\)70229-1](https://doi.org/10.1016/S1470-2045(10)70229-1), indexed in Pubmed: [20970380](https://pubmed.ncbi.nlm.nih.gov/20970380/).
 45. Brown PD, Jaeckle K, Ballman KV, et al. Effect of Radiosurgery Alone vs Radiosurgery With Whole Brain Radiation Therapy on Cognitive Function in Patients With 1 to 3 Brain Metastases: A Randomized Clinical Trial. *JAMA.* 2016; 316(4): 401–409, doi: [10.1001/jama.2016.9839](https://doi.org/10.1001/jama.2016.9839), indexed in Pubmed: [27458945](https://pubmed.ncbi.nlm.nih.gov/27458945/).
 46. Iwabuchi M, Shibamoto Y, Sugie C, et al. Partial-brain radiotherapy for primary central nervous system lymphoma: multi-institutional experience. *J Radiat Res.* 2016; 57(2): 164–168, doi: [10.1093/jrr/rrv085](https://doi.org/10.1093/jrr/rrv085), indexed in Pubmed: [26661856](https://pubmed.ncbi.nlm.nih.gov/26661856/).
 47. Alvarez-Pinzon AM, Wolf AL, Swedberg H, et al. Primary Central Nervous System Lymphoma (PCNSL): Analysis of Treatment by Gamma Knife Radiosurgery and Chemotherapy in a Prospective, Observational Study. *Cureus.* 2016; 8(7): e697, doi: [10.7759/cureus.697](https://doi.org/10.7759/cureus.697), indexed in Pubmed: [27570717](https://pubmed.ncbi.nlm.nih.gov/27570717/).
 48. Shibamoto Y, Hayabuchi N, Hiratsuka Ji, et al. Is whole-brain irradiation necessary for primary central nervous system lymphoma? Patterns of recurrence after partial-brain irradiation. *Cancer.* 2003; 97(1): 128–133, doi: [10.1002/cncr.11035](https://doi.org/10.1002/cncr.11035), indexed in Pubmed: [12491514](https://pubmed.ncbi.nlm.nih.gov/12491514/).
 49. Gondi V, Pugh SL, Tome WA, et al. Preservation of memory with conformal avoidance of the hippocampal neural stem-cell compartment during whole-brain radiotherapy for brain metastases (RTOG 0933): a phase II multi-institutional trial. *J Clin Oncol.* 2014; 32(34): 3810–3816, doi: [10.1200/JCO.2014.57.2909](https://doi.org/10.1200/JCO.2014.57.2909), indexed in Pubmed: [25349290](https://pubmed.ncbi.nlm.nih.gov/25349290/).
 50. Zinicola T, Chiesa S, Bartoli FB, et al. P05.86 Hippocampal sparing in primary central nervous system lymphoma. Is it routinely possible? *Neuro-Oncology.* 2018; 20(suppl_3): iii323–iii323, doi: [10.1093/neuonc/nyy139.412](https://doi.org/10.1093/neuonc/nyy139.412).
 51. Ashby MA, Bowen D, Bleeheh NM, et al. Primary lymphoma of the central nervous system: experience at Addenbrooke's Hospital, Cambridge. *Clin Radiol.* 1988; 39(2): 173–181, doi: [10.1016/s0009-9260\(88\)80019-9](https://doi.org/10.1016/s0009-9260(88)80019-9), indexed in Pubmed: [3356097](https://pubmed.ncbi.nlm.nih.gov/3356097/).
 52. Hochberg FH, Miller DC. Primary central nervous system lymphoma. *J Neurosurg.* 1988; 68(6): 835–853, doi: [10.3171/jns.1988.68.6.0835](https://doi.org/10.3171/jns.1988.68.6.0835), indexed in Pubmed: [3286832](https://pubmed.ncbi.nlm.nih.gov/3286832/).
 53. Jellinger KA, Paulus W. Primary central nervous system lymphomas—an update. *J Cancer Res Clin Oncol.* 1992;

- 119(1): 7–27, doi: [10.1007/BF01209483](https://doi.org/10.1007/BF01209483), indexed in Pubmed: [1400570](https://pubmed.ncbi.nlm.nih.gov/1400570/).
54. Mendenhall NP, Thar TL, Agee OF, et al. Primary lymphoma of the central nervous system. Computerized tomography scan characteristics and treatment results for 12 cases. *Cancer*. 1983; 52(11): 1993–2000, doi: [10.1002/1097-0142\(19831201\)52:11<1993::aid-cn-cr2820521104>3.0.co;2-c](https://doi.org/10.1002/1097-0142(19831201)52:11<1993::aid-cn-cr2820521104>3.0.co;2-c), indexed in Pubmed: [6354420](https://pubmed.ncbi.nlm.nih.gov/6354420/).
 55. Murray K, Kun L, Cox J. Primary malignant lymphoma of the central nervous system. Results of treatment of 11 cases and review of the literature. *J Neurosurg*. 1986; 65(5): 600–607, doi: [10.3171/jns.1986.65.5.0600](https://doi.org/10.3171/jns.1986.65.5.0600), indexed in Pubmed: [3772445](https://pubmed.ncbi.nlm.nih.gov/3772445/).
 56. Reni M, Ferreri AJ, Garancini MP, et al. Therapeutic management of primary central nervous system lymphoma in immunocompetent patients: results of a critical review of the literature. *Ann Oncol*. 1997; 8(3): 227–234, doi: [10.1023/a:1008201717089](https://doi.org/10.1023/a:1008201717089), indexed in Pubmed: [9137790](https://pubmed.ncbi.nlm.nih.gov/9137790/).
 57. Oh DS, Vredenburgh JA, Reardon DA, et al. Low-dose whole brain radiotherapy combined with radiosurgery for primary CNS lymphoma achieving partial response to induction methotrexate-based chemotherapy. *J Radiosurg SBRT*. 2014; 3(1): 37–42, indexed in Pubmed: [29296383](https://pubmed.ncbi.nlm.nih.gov/29296383/).
 58. Kim BH, Kim IH, Park SH, et al. Low-dose whole brain radiotherapy with tumor bed boost after methotrexate-based chemotherapy for primary central nervous system lymphoma. *Cancer Res Treat*. 2014; 46(3): 261–269, doi: [10.4143/crt.2014.46.3.261](https://doi.org/10.4143/crt.2014.46.3.261), indexed in Pubmed: [25038761](https://pubmed.ncbi.nlm.nih.gov/25038761/).
 59. Park JSu, Lim DoH, Ahn YC, et al. Whole brain radiation dose reduction for primary central nervous system lymphoma patients who achieved partial response after high-dose methotrexate based chemotherapy. *Jpn J Clin Oncol*. 2017; 47(11): 995–1001, doi: [10.1093/jjco/hyx120](https://doi.org/10.1093/jjco/hyx120), indexed in Pubmed: [28973509](https://pubmed.ncbi.nlm.nih.gov/28973509/).
 60. Fisher B, Seiferheld W, Schultz C, et al. Secondary analysis of Radiation Therapy Oncology Group study (RTOG) 9310: an intergroup phase II combined modality treatment of primary central nervous system lymphoma. *J Neurooncol*. 2005; 74(2): 201–205, doi: [10.1007/s11060-004-6596-9](https://doi.org/10.1007/s11060-004-6596-9), indexed in Pubmed: [16193393](https://pubmed.ncbi.nlm.nih.gov/16193393/).
 61. Illerhaus G, Marks R, Ihorst G, et al. High-dose chemotherapy with autologous stem-cell transplantation and hyperfractionated radiotherapy as first-line treatment of primary CNS lymphoma. *J Clin Oncol*. 2006; 24(24): 3865–3870, doi: [10.1200/JCO.2006.06.2117](https://doi.org/10.1200/JCO.2006.06.2117), indexed in Pubmed: [16864853](https://pubmed.ncbi.nlm.nih.gov/16864853/).
 62. Ghesquieres H, Tilly H, Sonet A, et al. A Multicentric Prospective Phase 2 Study of Intravenous Rituximab and Intrathecal Liposomal Cytarabine in Combination with C5R Protocol Followed by Brain Radiotherapy for Immunocompetent Patients with Primary CNS Lymphoma: A Lymphoma Study Association (LYSA) Trial. *Blood*. 2012; 120(21): 796–796, doi: [10.1182/blood.v120.21.796.796](https://doi.org/10.1182/blood.v120.21.796.796).
 63. Lesueur P, Damaj G, Hoang-Xuan K, et al. P14.73 Toxicity and outcomes of reduced-dose whole brain radiotherapy as consolidation treatment for patients with CNS lymphoma in real life setting. *Neuro-Oncology*. 2019; 21(Supplement_3): iii84–iii85, doi: [10.1093/neuonc/noz126.308](https://doi.org/10.1093/neuonc/noz126.308).
 64. Abrey LE, Moskowitz CH, Mason WP, et al. Intensive methotrexate and cytarabine followed by high-dose chemotherapy with autologous stem-cell rescue in patients with newly diagnosed primary CNS lymphoma: an intent-to-treat analysis. *J Clin Oncol*. 2003; 21(22): 4151–4156, doi: [10.1200/JCO.2003.05.024](https://doi.org/10.1200/JCO.2003.05.024), indexed in Pubmed: [14615443](https://pubmed.ncbi.nlm.nih.gov/14615443/).
 65. Yoon DH, Lee DH, Choi DR, et al. Feasibility of BU, CY and etoposide (BUCYE), and auto-SCT in patients with newly diagnosed primary CNS lymphoma: a single-center experience. *Bone Marrow Transplant*. 2011; 46(1): 105–109, doi: [10.1038/bmt.2010.71](https://doi.org/10.1038/bmt.2010.71), indexed in Pubmed: [20383213](https://pubmed.ncbi.nlm.nih.gov/20383213/).
 66. Illerhaus G, Müller F, Feuerhake F, et al. High-dose chemotherapy and autologous stem-cell transplantation without consolidating radiotherapy as first-line treatment for primary lymphoma of the central nervous system. *Haematologica*. 2008; 93(1): 147–148, doi: [10.3324/haematol.11771](https://doi.org/10.3324/haematol.11771), indexed in Pubmed: [18166803](https://pubmed.ncbi.nlm.nih.gov/18166803/).
 67. Omuro A, Correa DD, DeAngelis LM, et al. R-MPV followed by high-dose chemotherapy with TBC and autologous stem-cell transplant for newly diagnosed primary CNS lymphoma. *Blood*. 2015; 125(9): 1403–1410, doi: [10.1182/blood-2014-10-604561](https://doi.org/10.1182/blood-2014-10-604561), indexed in Pubmed: [25568347](https://pubmed.ncbi.nlm.nih.gov/25568347/).
 68. Montemurro M, Kiefer T, Schüller F, et al. Primary central nervous system lymphoma treated with high-dose methotrexate, high-dose busulfan/thiotepa, autologous stem-cell transplantation and response-adapted whole-brain radiotherapy: results of the multicenter Ostdeutsche Studiengruppe Hamato-Onkologie OSHO-53 phase II study. *Ann Oncol*. 2007; 18(4): 665–671, doi: [10.1093/annonc/mdl458](https://doi.org/10.1093/annonc/mdl458), indexed in Pubmed: [17185743](https://pubmed.ncbi.nlm.nih.gov/17185743/).
 69. Young PA, Gaut D, Kimaiyo DK, et al. Durable Survival Outcomes in Primary and Secondary Central Nervous System Lymphoma After High-dose Chemotherapy and Autologous Stem Cell Transplantation Using a Thiotepa, Busulfan, and Cyclophosphamide Conditioning Regimen. *Clin Lymphoma Myeloma Leuk*. 2020; 20(7): 468–479, doi: [10.1016/j.clml.2020.02.009](https://doi.org/10.1016/j.clml.2020.02.009), indexed in Pubmed: [32229199](https://pubmed.ncbi.nlm.nih.gov/32229199/).
 70. Schorb E, Fox CP, Fritsch K, et al. High-dose thiotepa-based chemotherapy with autologous stem cell support in elderly patients with primary central nervous system lymphoma: a European retrospective study. *Bone Marrow Transplant*. 2017; 52(8): 1113–1119, doi: [10.1038/bmt.2017.23](https://doi.org/10.1038/bmt.2017.23), indexed in Pubmed: [28436974](https://pubmed.ncbi.nlm.nih.gov/28436974/).
 71. DeFilipp Z, Li S, El-Jawahri A, et al. High-dose chemotherapy with thiotepa, busulfan, and cyclophosphamide and autologous stem cell transplantation for patients with primary central nervous system lymphoma in first complete remission. *Cancer*. 2017; 123(16): 3073–3079, doi: [10.1002/cncr.30695](https://doi.org/10.1002/cncr.30695), indexed in Pubmed: [28369839](https://pubmed.ncbi.nlm.nih.gov/28369839/).
 72. Soussain C, Hoang-Xuan K, Houillier C, et al. Lymphomes primitifs du système nerveux central. Recommandations nationales de bonnes pratiques. 2014.
 73. Nabors LB, Portnow J, Ahluwalia M, et al. Central Nervous System Cancers, Version 3.2020, NCCN Clinical Practice Guidelines in Oncology. *J Natl Compr Canc Netw*. 2020; 18(11): 1537–1570, doi: [10.6004/jnccn.2020.0052](https://doi.org/10.6004/jnccn.2020.0052), indexed in Pubmed: [33152694](https://pubmed.ncbi.nlm.nih.gov/33152694/).
 74. Holdhoff M, Mrugala MM, Grommes C, et al. Challenges in the Treatment of Newly Diagnosed and Recurrent Primary Central Nervous System Lymphoma. *J Natl Compr Canc Netw*. 2020; 18(11): 1571–1578, doi: [10.6004/jnccn.2020.7667](https://doi.org/10.6004/jnccn.2020.7667), indexed in Pubmed: [33152700](https://pubmed.ncbi.nlm.nih.gov/33152700/).