



**HAL**  
open science

## **Extensive head and neck skin cancers: Carcinologic surgery as a cornerstone of treatment**

Thomas Bondi, André Chaine, Jean-Philippe Foy, Mourad Benassarou, Chloé Bertolus, Jebrane Bouaoud

► **To cite this version:**

Thomas Bondi, André Chaine, Jean-Philippe Foy, Mourad Benassarou, Chloé Bertolus, et al.. Extensive head and neck skin cancers: Carcinologic surgery as a cornerstone of treatment. *Journal of Stomatology, Oral and Maxillofacial Surgery*, 2024, 125 (4), pp.101737. 10.1016/j.jormas.2023.101737 . hal-04357889

**HAL Id: hal-04357889**

**<https://hal.sorbonne-universite.fr/hal-04357889v1>**

Submitted on 21 Dec 2023

**HAL** is a multi-disciplinary open access archive for the deposit and dissemination of scientific research documents, whether they are published or not. The documents may come from teaching and research institutions in France or abroad, or from public or private research centers.

L'archive ouverte pluridisciplinaire **HAL**, est destinée au dépôt et à la diffusion de documents scientifiques de niveau recherche, publiés ou non, émanant des établissements d'enseignement et de recherche français ou étrangers, des laboratoires publics ou privés.

**Title.** Extensive head and neck skin cancers: carcinologic surgery as a cornerstone of treatment

Thomas **BONDI**<sup>1</sup>, André **CHAINED**<sup>1</sup>, Jean-Philippe **FOY**<sup>1</sup>, Mourad **BENASSAROU**<sup>1</sup>, Chloé **BERTOLUS**<sup>1</sup>, Jebrane **BOUAOUD**<sup>1\*</sup>

### **Affiliations**

Sorbonne Université, Department of Maxillofacial Surgery and Stomatology, Pitié-Salpêtrière Hospital, Assistance Publique des Hôpitaux de Paris, Paris, France

\* **Corresponding author:** Jebrane Bouaoud, M.D. Ph.D., Sorbonne Université, Department of Maxillo-Facial Surgery, Hôpital Pitié-Salpêtrière, Assistance Publique des Hôpitaux de Paris, Paris, France; Email: [jebrane.bouaoud@aphp.fr](mailto:jebrane.bouaoud@aphp.fr)

**Abstract word count:** 257 words

**Word count:** 1934 words

**Figures and tables count:** n= 5 Figures and n= 4 Tables

**Funding:** No

### **Author contributions statement**

All authors have participated to the conception and design, acquisition, analysis, interpretation of data and to the drafting the article or revising it critically for important intellectual content; All authors have approved the final version to be published.

**Conflict of interest:** None

## Abstract

**Background and Objective.** The prevalence of extensive skin cancers increases with the aging of the population. Surgical management is the gold standard of curative treatment while morbidity is not negligible. There are few data in the literature concerning extensive head and neck cutaneous cancers. The aim of this article is to report our experience of curative management of head and neck extensive skin cancers.

**Method.** In this single-center retrospective observational study, we report a series of 17 patients with extensive skin facial cancers treated by surgery between 2013 and 2022 in the maxillofacial surgery department of the Pitié-Salpêtrière Hospital. We collected clinical, therapeutic, histological, and carcinologic data.

**Results.** The median age of the patients was 66 years [35-94]. There were 9 male and 8 women. Scalp (39%) and cheek (22%) locations were the most frequent ones. The most frequent histological types were squamous cell carcinoma (61%) and basal cell carcinoma (17%). Three patients received neoadjuvant treatment. The surgical treatment consisted mainly of carcinological resection followed by one-stage reconstruction by free flap for 5 (30%) patients and without reconstruction for primary for 12 (70%) patients, of whom 8 benefited from secondary reconstruction. Five patients received adjuvant radiotherapy or radio-chemotherapy. With a median follow-up of 40 months (2-72), the median overall survival was 40 months (12-72).

**Conclusion.** We know that extensive skin cancers of the face have a good prognosis on condition that the carcinological and reconstructive requirements are respected. Surgery remains the cornerstone of treatment while the improvement of adjuvant therapies, in particular the rise of immunotherapies or other targeted therapies, may allow to limit recurrences.

## Keywords

Head and neck; skin cancer; Maxillofacial; Microsurgery; Reconstruction.

## 1. Introduction

Skin cancers represent the majority of cutaneous tumors and are the most frequent cancers in human (1). Due to its high heliotropism, head and neck is usually involved. European and French guidelines are not specific to the head and neck localization whereas surgical treatment of this region remains challenging (2–11). Primary surgery is the gold standard in most indications. However, surgical resection of face cancers has technical imperatives, both aesthetic and functional, which may have an impact on the decision of the margin of carcinologic resection (12). The Mohs surgical technique has shown good results but in practice is only rarely feasible (13).

For patients who are not eligible for primary surgery, non-surgical alternatives are available such as immunotherapies for non-melanoma cancers (14,15), Hedgehog inhibitor for basal cell carcinoma (BCC) (16), radiotherapy alone in BCC (17) or with concomitant therapy (18), radiotherapy alone for other tumors (19) or brachytherapy (20). Nevertheless, as supported by recent guidelines, when feasible, primary surgery remain the cornerstone of treatment (2-11).

There is no consensual definition for head and neck's extensive skin tumors. One of the singularities of these tumors is that they develop in particularly frail elderly patients and/or with psycho-social risk factors, who are slow to seek treatment because they are often in denial of their disease (21) or patients suffering from immunodepression (22). Approval of surgical resection and compliance with treatment and are often not achieved (23,24). Reconstruction of the large defect remains challenging (23, 24). Overall, the curative management of extensive face skin cancers tumors require multidisciplinary expertise (25,26).

Herein, we present a retrospective case series of patients with extensive skin cancers of the face requiring large carcinologic surgical resection followed by reconstruction. Complications, outcomes and requirements that should be met are reported. Finally, we discuss our data comparing them with those previously reported in literature.

## **2. Method**

### **2.1 Case series**

In this single-center retrospective observational study, we report a series of patients with primitive extensive facial skin cancers treated by large carcinologic surgical resection between January 2013 and July 2022 in the Department of Maxillofacial Surgery and Stomatology of the Pitié-Salpêtrière Hospital (Sorbonne Université, Assistance Publique des Hôpitaux de Paris, APHP, Paris, France). We defined an extensive skin lesion of the head and neck histologically derived from the skin whose excision makes it necessary to discuss reconstruction of at least 2 subunits or to invade neighboring tissues deeper of the deep facia. Extensive skin lesions of a single scalp subunit were defined as invading the calvaria bone and therefore requiring at least one craniectomy (scalp lesions involving only the excision of the periosteum were excluded). Nasal subunits were defined as Burget's reconstruction subunits. Non-cancerous skin tumors, transient nodules, skin, and lymph node metastases were excluded.

Patients medical records were screened to collect clinical data (age, sex, medical-surgical history, way of life), data concerning the development of the skin cancer (localization of the tumor, duration of evolution before beginning of the treatment, histological type), the treatment (neo-adjuvant agent, type of surgical resection, reconstruction strategies, adjuvant treatments...), anatomopathological (histological type, resection margin) and oncologic outcomes (salvage surgery, progression, recurrence, second skin cancer). All data were collected prospectively.

### **2.2 Ethical approval**

This study was approved by the Institutional Review Board of Pitié-Salpêtrière University Hospital (Sorbonne University, APHP, Paris, France) and was performed in accordance with the Declaration of Helsinki. The collection of data and analysis were in accordance with the guidelines of the French National Committee for the Protection of Personal Data (Commission Nationale Informatique et Libertés, CNIL, declaration number 2229981 v 0).

### **2.3 Patient consent**

Written consent was not required from patients because of the retrospective non-interventional design, consistent with French standard regulations.

## 4. Results

### 4.1 Patients and tumor characteristics

From January 2013 to July 2022, 17 patients with histologically proved extensive face skin cancer were operated in our department [Table 1]. Briefly, there were 9 male and 8 women. The median age was 68 years old (29-93). Almost all patients (n=15, 88 %) had systemic medical conditions (diabetes or vascular disease or ischemic heart disease or arterial hypertension).

Regarding histology, cancers were mainly squamous cell carcinoma (SCC) (n=11, 64%) and BCC (n=3, 18%). Other histological subtypes were sarcomatoid carcinoma (n=1, 6%), trichoblastic carcinoma (n=1, 6%) and dermal angiosarcoma (n=1, 6%). The preferential locations were the scalp (n=7, 41%), and the cheek (n=4, 23%).

### 4.2 Extensive skin cancers treatments

Two patients (12%) received neoadjuvant treatment (basal cell carcinoma treated using an Hedgehog inhibitor *Vismodegib*<sup>®</sup> and squamous cell carcinoma with radiotherapy associated with chemotherapy) [Table 2]. One patient underwent preventive arterial embolization prior to surgery for a tumor invading the entire scalp and parietal bone.

Reconstruction strategy was systematically discussed at the multidisciplinary board meeting. [Figure 1]. Soft-tissue excisions were preferably reconstructed using musculocutaneous free flaps. When the skin surface to be reconstructed was very large, a 2-stage reconstruction technique was used: a muscular free flap and a thin skin graft. Resections involving interruptive bone continuity were preferably reconstructed using a single osteo-myocutaneous free flap or a mixed technique with a custom titanium implant and a muscular free flap for the vertex. Lastly, a specific surgical protocol was implemented for amputation of the nasal pyramid, in accordance with Burget and Mesnick rhinopoiesis technic. The final choice of reconstruction was made by the referring surgeon.

When carcinological resection surgery had to be performed as an emergency, a primary resection was performed with secondary reconstruction after anatomopathological examination. If feasible, excision with one-stage reconstruction was systematically preferred. In this cohort, carcinologic resection was realized for all patients. Five (30%) patients underwent cervical lymph nodes resection, at same as tumor resection if primary resection

was scheduled or during the secondary planned reconstruction. All these patients were pN0. Three (18%) patients benefit from a multidisciplinary surgical resection (Maxillofacial and Neurosurgical teams). Primary reconstruction was realized for five (30%) patients of which four using free flaps (two Lassitimus dorsi flaps, one chimeric Scapula and Latissimus dorsi flap and one Radial Forearm Free Flap) **[Figure 2-3]** and 1 using a Latissimus dorsi pedicle flap. Thus, most of surgical resections (n=12, 70%) were performed without primary reconstruction for carcinological purpose (to ensure that the resection margins were R0 clear before reconstruction) **[Figure 4]**. Among them, eight (47% of the whole cohort) patients benefited from secondary reconstruction of which n=5/8 using free flaps (three Lassitimus dorsi flaps, one chimeric Scapula and Serratus flap and one Radial Forearm Free Flap), and 3 patients using pedicled flaps (3 Paramedian associated with Nasolabial pedicle Flap). Overall, four (23%) patients underwent a directed and controlled wound healing protocol **[Figure 5]**, one in an elderly patient with tumors invading lateral canthus and cheek and 3 invading scalp with respect of the periosteum.

Following multidisciplinary tumor board discussion, most patients (n=11, 65%) received adjuvant treatment such external radiotherapy (n=8, 47%), radio-chemotherapy (n=2, 12%) or immunotherapy (n=1, 6%) **[Table 2]**.

Prophylactic tracheostomy was realized for all patients benefiting from immediate free flap reconstruction ensuring upper aerodigestive trach safety. All patients were hospitalized postoperatively for at least 3 days in the intensive care unit for close monitoring. The aim of the immediate postoperative medical protocol was to maintain a suboptimal systolic blood pressure, hemoglobin level and level III pain relief. Antibiotic prophylaxis was systematically carried out in accordance with current recommendations. When a free flap was performed, its perfusion was monitored clinically every 4 hours for 5 days by the surgical team, combined with a Cook® implantable arterial Doppler probe monitoring.

#### *4.3 Surgical and carcinologic outcomes*

Surgical complications were infection (n=2, 12%), hematoma (n=2, 12%) and microvascular anastomosis revision (n= 3, 18%). Sequelae management was necessary for 7 (41%) for functional correction (Ectropion, alteration of labial function) or aesthetic consideration.



Histological analysis revealed that most surgical resections were clear margins R0 (n=10, 59%) while 6 (35%) close R1 and one (6%) invaded R2 surgical margins were found. For R1 patients, surgical revision of margins was systematically realized. Patient R2 had a squamous cell carcinoma of the scalp with invasion of the superior sagittal sinus, making total excision impossible. Moreover, adjuvant treatment was realized as following: 3 (18%) patients underwent adjuvant radiotherapy and 1 (6%) patient received radio-immunotherapy with anti-PD1 monoclonal antibody (*Cemiplimab*<sup>®</sup>). Of note, only one of these patients had undergone primary reconstruction.

During the follow-up (median 40 months [3-72]), loco-regional recurrences as well as metastatic recurrences were observed in 4 (24%) and 1 (6%) patients, respectively. Loco-regional recurrences occurred in immunodeficient patients with history of multiple skin cancers. These recurrences were treated with salvage surgery and adjuvant radiotherapy. One (6%) patient presented lungs and bones metastases (primary: sarcomatoid carcinoma) treated with radio-chemotherapy. **[Table 3]**

## 5. Discussion

In this case series we present the management of extensive skin cancer with various histology and different facial anatomical locations. Head and neck extensive skin cancers are challenging both in terms of disease control and reconstruction. Our results suggest that surgery is the gold standard in the curative management of these cancers, as part of a multidisciplinary approach. A trained surgical team is essential to meet with the carcinologic, functional and aesthetic requirements of large facial excisions, given the many anatomical specificities of the facial subunits.

There are data in the literature about extensive cancers of the face of cutaneous origin [Table 4]. These studies are focused on a precise anatomical taking into account the corresponding reconstruction requirements (27–33) or the size of the tumor (34) and very of them focusing on skin cancer. Our study focuses on extensive cutaneous cancers (whose management differs greatly from smaller cancers) affecting all subunits of the face, and to study carcinological, functional and aesthetic outcomes. Beside the commonly encountered BCC and SCC, our study also reports tumors of various histology such as trichoblastic carcinoma (35), skin angiosarcoma (36,37), sarcomatoid carcinoma (38).

The improvement of non-surgical carcinological therapeutics arise in the official guidelines and may allow to limit post operative recurrences. Recent studies show that surgical carcinological management with reconstruction is increasingly well tolerated in frail and elderly patients (28,39,40). In our series, most patients did not undergo primary reconstruction allowing for margin revision in case of R1 or R2 histological margins.

Regarding reconstruction, there is a constant improvement in surgical technique adapted to large face's resection such as free flaps (41,42), local flaps (43) or facial prothesis. All these reconstruction technics can be associated in one or more stages as well-known rhinopoesis reconstructions (26,44–46). Surgical options aimed at improving post-reconstruction aesthetic results are emerging, such as the use of autologous epithelial cell sprays harvested from adjacent anatomical regions, or the use of anatomically close tissue expander before

harvesting (47). Alternative techniques to the use of autologous tissue such as biomaterials or tissue engineering (48) can provide solutions for the management of complex defects or rare reconstruction failures. Finally, the improvement in flap harvesting techniques makes these surgeries more reliable and limits the number of repeat surgeries, in association with the rise of innovative reconstructive surgeries (49).

Our study has several limitations. First, the various biases we identified in this study are those relating to its retrospective nature, to differences in follow-up, to the number of patients included and to the heterogeneity of their management. Moreover, data on predisposing factors such as phototype, sun exposure and tobacco smoking were also missing.

In summary, surgical management of extensive facial skin cancer is the cornerstone of the curative treatment. Adjuvant therapies may allow to limit the recurrence of cancer provided R0 clear resection. Different reconstruction strategies exist and are becoming more and more reliable allowing wide resection even in the case of locally advanced facial skin cancers.

## Bibliography

1. Sung H, Ferlay J, Siegel RL, Laversanne M, Soerjomataram I, Jemal A, et al. Global Cancer Statistics 2020: GLOBOCAN Estimates of Incidence and Mortality Worldwide for 36 Cancers in 185 Countries. *CA Cancer J Clin*. 2021 May;71(3):209–49.
2. Bernard G, Alain D, Marc P, Géraldine J, Elif H, Thomas J, et al. Update on stage III Melanoma : New recommandations from the cutaneous cancer group, french dermatology society, "article in french"
3. Guillot B, Dalac S, Denis M, Dupuy A, Emile JF, De La Fouchardiere A, et al. Update of recommendations for the management of stage I to III melanoma, "article in french", *Bull Cancer (Paris)*. 2016 Sep;103(9):743–52.
4. Agence Nationale d'Accreditation et Évaluation en Sante (ANAES). [Good clinical practices. Diagnostic and therapeutic management of basal cell carcinoma in adults (Extracts)]. *Rev Stomatol Chir Maxillofac*. 2005 Apr;106(2):83–8.
5. French Society of Dermatology. [Guidelines for the diagnosis and treatment of cutaneous squamous cell carcinoma and precursor lesions. Arguments - May 2009]. *Ann Dermatol Venerol*. 2009 Sep;136 Suppl 5:S189-242.
6. Haute Autorité de Santé. [Guidelines for the diagnosis and treatment of cutaneous squamous cell carcinoma and precursor lesions. Guidelines]. *Rev Stomatol Chir Maxillofac*. 2010 Sep;111(4):228–37.
7. Stratigos AJ, Garbe C, Dessinioti C, Lebbe C, Bataille V, Bastholt L, et al. European interdisciplinary guideline on invasive squamous cell carcinoma of the skin: Part 1. epidemiology, diagnostics and prevention. *Eur J Cancer Oxf Engl 1990*. 2020 Mar;128:60–82.
8. Stratigos AJ, Garbe C, Dessinioti C, Lebbe C, Bataille V, Bastholt L, et al. European interdisciplinary guideline on invasive squamous cell carcinoma of the skin: Part 2. Treatment. *Eur J Cancer Oxf Engl 1990*. 2020 Mar;128:83–102.
9. Peris K, Fargnoli MC, Garbe C, Kaufmann R, Bastholt L, Seguin NB, et al. Diagnosis and treatment of basal cell carcinoma: European consensus-based interdisciplinary guidelines. *Eur J Cancer Oxf Engl 1990*. 2019 Sep;118:10–34.
10. Garbe C, Amaral T, Peris K, Hauschild A, Arenberger P, Basset-Seguin N, et al. European consensus-based interdisciplinary guideline for melanoma. Part 1: Diagnostics: Update 2022. *Eur J Cancer Oxf Engl 1990*. 2022 Jul;170:236–55.
11. Garbe C, Amaral T, Peris K, Hauschild A, Arenberger P, Basset-Seguin N, et al. European consensus-based interdisciplinary guideline for melanoma. Part 2: Treatment - Update 2022. *Eur J Cancer Oxf Engl 1990*. 2022 Jul;170:256–84.
12. Brandt MG, Moore CC. Nonmelanoma Skin Cancer. *Facial Plast Surg Clin N Am*. 2019 Feb;27(1):1–13.
13. Schell AE, Russell MA, Park SS. Suggested excisional margins for cutaneous malignant lesions based on Mohs micrographic surgery. *JAMA Facial Plast Surg*. 2013 Oct;15(5):337–43.
14. Claveau J, Archambault J, Ernst DS, Giacomantonio C, Limacher JJ, Murray C, et al. Multidisciplinary management of locally advanced and metastatic cutaneous squamous cell carcinoma. *Curr Oncol Tor Ont*. 2020 Aug;27(4):e399–407.
15. Gross ND, Miller DM, Khushalani NI, Divi V, Ruiz ES, Lipson EJ, et al. Neoadjuvant Cemiplimab for Stage II to IV Cutaneous Squamous-Cell Carcinoma. *N Engl J Med*. 2022 Oct 27;387(17):1557–68.
16. Von Hoff DD, LoRusso PM, Rudin CM, Reddy JC, Yauch RL, Tibes R, et al. Inhibition of the hedgehog pathway in advanced basal-cell carcinoma. *N Engl J Med*. 2009 Sep 17;361(12):1164–72.

17. Cognetta AB, Howard BM, Heaton HP, Stoddard ER, Hong HG, Green WH. Superficial x-ray in the treatment of basal and squamous cell carcinomas: a viable option in select patients. *J Am Acad Dermatol*. 2012 Dec;67(6):1235–41.
18. Pollom EL, Bui TT, Chang ALS, Colevas AD, Hara WY. Concurrent Vismodegib and Radiotherapy for Recurrent, Advanced Basal Cell Carcinoma. *JAMA Dermatol*. 2015 Sep;151(9):998–1001.
19. Hennequin C, Rio E, Quéro L, Clavère P. Radiation therapy of cutaneous cancers. *Cancer Radiother J Soc Francaise Radiother Oncol*. 2022 Apr;26(1–2):397–403.
20. Krzysztofiak T, Kamińska-Winciorek G, Piłśniak A, Wojcieszek P. High dose rate brachytherapy in nonmelanoma skin cancer-Systematic review. *Dermatol Ther*. 2022 Sep;35(9):e15675.
21. Alam M, Goldberg LH, Silapunt S, Gardner ES, Strom SS, Rademaker AW, et al. Delayed treatment and continued growth of nonmelanoma skin cancer. *J Am Acad Dermatol*. 2011 May;64(5):839–48.
22. Bejar C, Basset-Seguin N, Faure F, Fieschi C, Frances C, Guenne C, et al. French ENT Society (SFORL) guidelines for the management of immunodeficient patients with head and neck cancer of cutaneous origin. *Eur Ann Otorhinolaryngol Head Neck Dis*. 2014 Apr;131(2):121–9.
23. Godoy A, Ishii M, Byrne PJ, Boahene KDO, Encarnacion CO, Ishii LE. How facial lesions impact attractiveness and perception: differential effects of size and location. *The Laryngoscope*. 2011 Dec;121(12):2542–7.
24. Godoy A, Ishii M, Dey J, Boahene KDO, Byrne PJ, Ishii LE. Facial lesions negatively impact affect display. *Otolaryngol--Head Neck Surg Off J Am Acad Otolaryngol-Head Neck Surg*. 2013 Sep;149(3):377–83.
25. Almadori G, De Corso E, Settimi S, Di Cintio G, Mele DA, Brigato F, et al. When is a surgical multidisciplinary approach required in the management of head and neck non-melanoma skin cancer and in advanced head and neck pathologies involving skin? *Acta Otorhinolaryngol Ital Organo Uff Della Soc Ital Otorinolaringol E Chir Cerv-facc*. 2021 Apr;41(Suppl. 1):S145–57.
26. Bouaoud J, Benmoussa N, Hennocq Q, Honart JF, Breuskin I, Gorphe P, et al. Locally advanced nasal pyramid squamous cell carcinoma: our 15 years' experience in a series of 35 total rhinectomies. *Rhinology*. 2020 Dec 1;58(6):638–40.
27. Cigna E, Minni A, Barbaro M, Attanasio G, Sorvillo V, Malzone G, et al. An experience on primary thinning and secondary debulking of anterolateral thigh flap in head and neck reconstruction. *Eur Rev Med Pharmacol Sci*. 2012 Aug;16(8):1095–101.
28. Every J, Subramaniam N, Dawson R, Ch'ng S, Low THH, Palme CE, et al. Microvascular reconstruction of head and neck defects in the elderly. *ANZ J Surg*. 2021 May;91(5):969–74.
29. Gal TJ, Futran ND, Bartels LJ, Klotch DW. Auricular carcinoma with temporal bone invasion: outcome analysis. *Otolaryngol--Head Neck Surg Off J Am Acad Otolaryngol-Head Neck Surg*. 1999 Jul;121(1):62–5.
30. Kesting MR, Maclver C, Wales CJ, Wolff KD, Nobis CP, Rohleder NH. Surface-optimized free flaps for complex facial defects after skin cancer. *J Cranio-Maxillo-fac Surg Off Publ Eur Assoc Cranio-Maxillo-fac Surg*. 2015 Nov;43(9):1792–7.
31. Lutz BS, Wei FC, Chen HC, Lin CH, Wei CY. Reconstruction of scalp defects with free flaps in 30 cases. *Br J Plast Surg*. 1998 Apr;51(3):186–90.

32. Pompucci A, G R, E F, M S, A C, E F. Combined treatment of advanced stages of recurrent skin cancer of the head. *J Neurosurg* [Internet]. 2004 Apr [cited 2022 Nov 18];100(4). Available from: <https://pubmed.ncbi.nlm.nih.gov/15070120/>
33. Wornom IL, Neifeld JP, Mehrhof AI, Young HF, Chinchilli VM. Closure of craniofacial defects after cancer resection. *Am J Surg*. 1991 Oct;162(4):408–11.
34. Schliephake H, Neukam FW, Schmelzeisen R, Reiche C. Reconstruction of facial soft tissues after resection of skin tumors. *J Cranio-Maxillo-fac Surg Off Publ Eur Assoc Cranio-Maxillo-fac Surg*. 1994 Dec;22(6):342–8.
35. Boettler MA, Shahwan KT, Abidi NY, Carr DR. Trichoblastic carcinoma: a comprehensive review of the literature. *Arch Dermatol Res*. 2022 Jul;314(5):399–403.
36. Ishida Y, Otsuka A, Kabashima K. Cutaneous angiosarcoma: update on biology and latest treatment. *Curr Opin Oncol*. 2018 Mar;30(2):107–12.
37. Mendenhall WM, Mendenhall CM, Werning JW, Reith JD, Mendenhall NP. Cutaneous angiosarcoma. *Am J Clin Oncol*. 2006 Oct;29(5):524–8.
38. Gómez-Espejo C, Herrera-Sabal A, Ríos-Martín JJ, Camacho-Martínez F. Basal cell carcinoma with sarcomatoid features (sarcomatoid carcinoma): report of a case and review of the literature. *J Dermatol*. 2003 Jul;30(7):543–9.
39. FI A, Gm M, Fj S, Gv B, Co N. Radical combined treatment of locally extensive head and neck cancer in the elderly. *Am J Otolaryngol* [Internet]. 2001 Feb [cited 2022 Nov 22];22(1). Available from: <https://pubmed.ncbi.nlm.nih.gov/11172217/>
40. Goh CSL, Kok YO, Yong CPC, Tan EWX, Goh LG, Chew KY, et al. Outcome predictors in elderly head and neck free flap reconstruction: A retrospective study and systematic review of the current evidence. *J Plast Reconstr Aesthetic Surg JPRAS*. 2018 May;71(5):719–28.
41. Irons GB, Witzke DJ, Arnold PG, Wood MB. Use of the omental free flap for soft-tissue reconstruction. *Ann Plast Surg*. 1983 Dec;11(6):501–7.
42. Strübing F, Wenz F, Etminan N, Bigdeli AK, Siegwart LC, Thomas B, et al. Scalp Reconstruction Using the Latissimus Dorsi Free Flap: A 12-Year Experience. *J Clin Med*. 2023 Apr 19;12(8):2953.
43. Becker GD, Adams LA, Levin BC. Secondary intention healing of exposed scalp and forehead bone after Mohs surgery. *Otolaryngol--Head Neck Surg Off J Am Acad Otolaryngol-Head Neck Surg*. 1999 Dec;121(6):751–4.
44. Burget GC, Walton RL. Optimal use of microvascular free flaps, cartilage grafts, and a paramedian forehead flap for aesthetic reconstruction of the nose and adjacent facial units. *Plast Reconstr Surg*. 2007 Oct;120(5):1171–207.
45. Menick FJ. Nasal reconstruction. *Plast Reconstr Surg*. 2010 Apr;125(4):138e–50e.
46. Menick FJ. Aesthetic and reconstructive rhinoplasty: a continuum. *J Plast Reconstr Aesthetic Surg JPRAS*. 2012 Sep;65(9):1169–74.
47. Topalan M, Guven E, Demirtas Y. Hemifacial resurfacing with prefabricated induced expanded supraclavicular skin flap. *Plast Reconstr Surg*. 2010 May;125(5):1429–38.
48. Fenberg R, vonWindheim N, Malara M, Ahmed M, Cowen E, Melaragno L, et al. Tissue Engineering: Current Technology for Facial Reconstruction. *Facial Plast Surg* [Internet]. 2023 Jun 8 [cited 2023 Sep 5]; Available from: <http://www.thieme-connect.de/DOI/DOI?10.1055/s-0043-1769808>
49. Fichter AM, Ritschl LM, Rau A, Schwarzer C, von Bomhard A, Wagenpfeil S, et al. Free flap rescue using an extracorporeal perfusion device. *J Cranio-Maxillo-fac Surg Off Publ Eur Assoc Cranio-Maxillo-fac Surg*. 2016 Dec;44(12):1889–95.

## Figures legends

### Figure 1. Reconstruction algorithm for head and neck extensive skin cancer resection

((1) Exception made of nose reconstruction; (2) Excluding partial resection without interruptive bone resection; (3) ASA: ASA Physical Status Classification system)

**Figure 2. (A)** Second recurrence of cutaneous squamous cell carcinoma previously treated using surgery and post-operative radiotherapy. **(B)** Tumor resection including right maxillectomy, Cheek and non-interruptive mandibular bone resection. **(C)** Latissimus dorsi and serratus musculo-fascio-cutaneous free flap after harvesting for immediate reconstruction. The double skin paddle was used to ensure internal and external cheek reconstruction **(D)** Immediate postoperative appearance after reconstruction.

**Figure 3. (A)** Lower lip epidermoid carcinoma. **(B)** Peri-operative view of inferior lip and bilateral lip commissure carcinologic resection and bilateral cervical lymphadenectomy. **(C)** Radial Forearm Free Flap design before harvesting for immediate reconstruction. **(D)** 6 years post-operative result.

**Figure 4. (A)** 71-year-old patient with psychotic disorder in discontinuous care, with denial of the illness evolving for 36 months admitted to the emergency department for septic shock with cutaneous origin. Examination revealed tumor extension to the maxillary and, zygomatic bones, as well as intra-orbital and intraocular invasion. **(B)** Primary surgical resection was realized in emergency and consisted in cutaneous tumor excision with 10 mm surgical margin with maxillectomy according to Brown IV classification and exenteration extended to the floor of the Frontal Sinus. Histological analysis found a trichoblastic carcinoma. **(C)** Complementary carcinological management with superficial parotidectomy and homolateral modified radical lymph node dissection and reconstruction with myo-fascio-cutaneous latissimus dorsi free flap. Of note, this patient has refused adjuvant radiotherapy as well as further secondary reconstruction to improve morphological outcomes.

**Figure 5. (A)** 92-year-old patient with cognitive dysfunction, heart failure and terminal kidney failure. Examination revealed a skin epidermoid carcinoma with no tumor extension beside the cheek skin. Carcinological excision with one-stage free flap reconstruction was proposed but the patient was ineligible for free flap surgery (from the anaesthetic approach). Excision with margin and direct wound healing were performed **(B)** Direct wound healing protocol two weeks after surgery **(C)** Direct wound healing protocol four weeks after surgery with skin retraction and sequelae ectropion. **(D)** Post-operative ectropion management with hetero-palpebral local flap.

## Tables

**Table 1.** Patient and cancer characteristics of patients with extensive head and neck skin cancer (n=17 patients)

<b>Variable</b>	<b>N (%)</b>
Median age	<b>68</b> [29 – 93]
Sex ratio M/F	<b>9/8</b>
Favoring Factors	
Social isolation	<b>11</b> (64)
Psychiatric history	<b>3</b> (18)
Immunodepression	<b>3</b> (18)
Histology	
SCC	<b>11</b> (64)
BCC	<b>3</b> (18)
Other <sup>(*)</sup>	<b>3</b> (18)
Location	
Scalp	<b>7</b> (41)
Cheek	<b>4</b> (23)
Nasal pyramid	<b>3</b> (18)
Lip	<b>2</b> (12)
External Ear	<b>1</b> (6)
Median duration of lesion evolution (months)	<b>24</b> [4 – 144]

BCC (Basal Cell Carcinoma), SCC (Spinocellular Cell Carcinoma)

(\*) Other: Trichoblastic carcinoma, dermal angiosarcoma, sarcomatoid carcinoma



**Table 2.** Management of the n=17 patients with surgically resected extensive head and neck skin cancer

<b>Variable</b>	<b>N (%)</b>
Neo-adjuvant Treatment	<b>2 (12)</b>
Adjuvant treatment	
Postoperative radiotherapy	<b>8 (47)</b>
Postoperative radio-chemotherapy	<b>2 (12)</b>
Postoperative immunotherapy	<b>1 (6)</b>
Reconstruction Strategies	
Primary	<b>5 (30)</b>
Secondary	<b>8 (47)</b>
Directed wound healing	<b>4 (23)</b>
Flap used in primary and secondary reconstruction	
Free Flap <sup>(1)</sup>	<b>8 (47)</b>
Pedicle Flap <sup>(2)</sup>	<b>2 (12)</b>
Association of Free and Pedicle Flap	<b>3 (18)</b>

(1) Free flap: osteo-myo-fascio-cutaneous Scapula, Musculo-fascio-cutaneous Latissimus dorsi, fascio-cutaneous Radial Forearm Free Flap

(2) Pedicled flap: Myo-fascio-cutaneous Latissimus dorsi, Rieger flap, Paramedian Myo-fascio-cutaneous Forehead Flap.

**Table 3.** Surgical and carcinologic outcomes of patients with extensive head and neck skin cancers

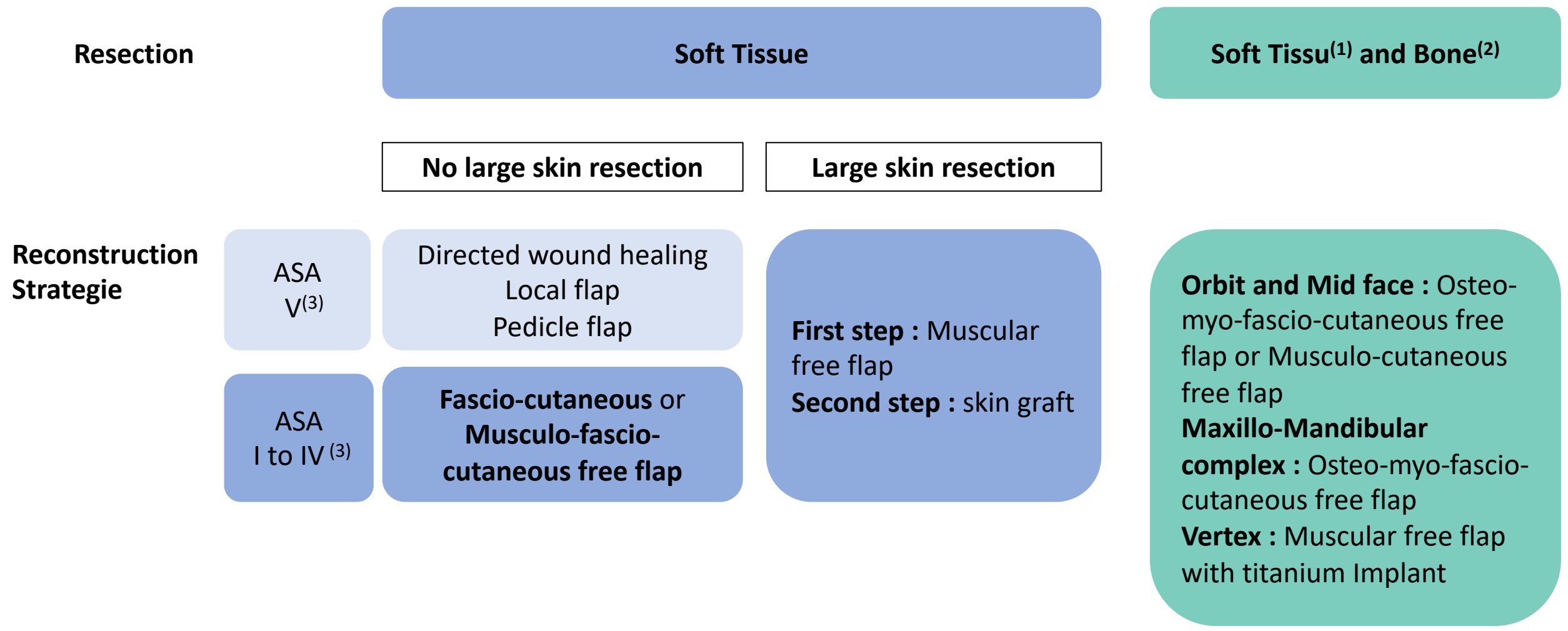
<b>Variable</b>	<b>N (%)</b>
Overall survival (months)	<b>39 [2 – 72]</b>
Histological margin	
R0	<b>10 (59)</b>
R1	<b>6 (35)</b>
R2	<b>1 (6)</b>
Recurrence	
Loco-regional	<b>4 (24)</b>
Metastatic	<b>1 (6)</b>
Secondary surgery	
Salvage surgery for loco-regional metastasis	<b>3 (23)</b>
Emergency surgical revision of reconstruction <sup>(1)</sup>	<b>3 (23)</b>
Reconstruction retouching	<b>8 (47)</b>

(1) 2 Free flap necrosis with removal for new flap and 1 free flap arterial ischemia reperfused

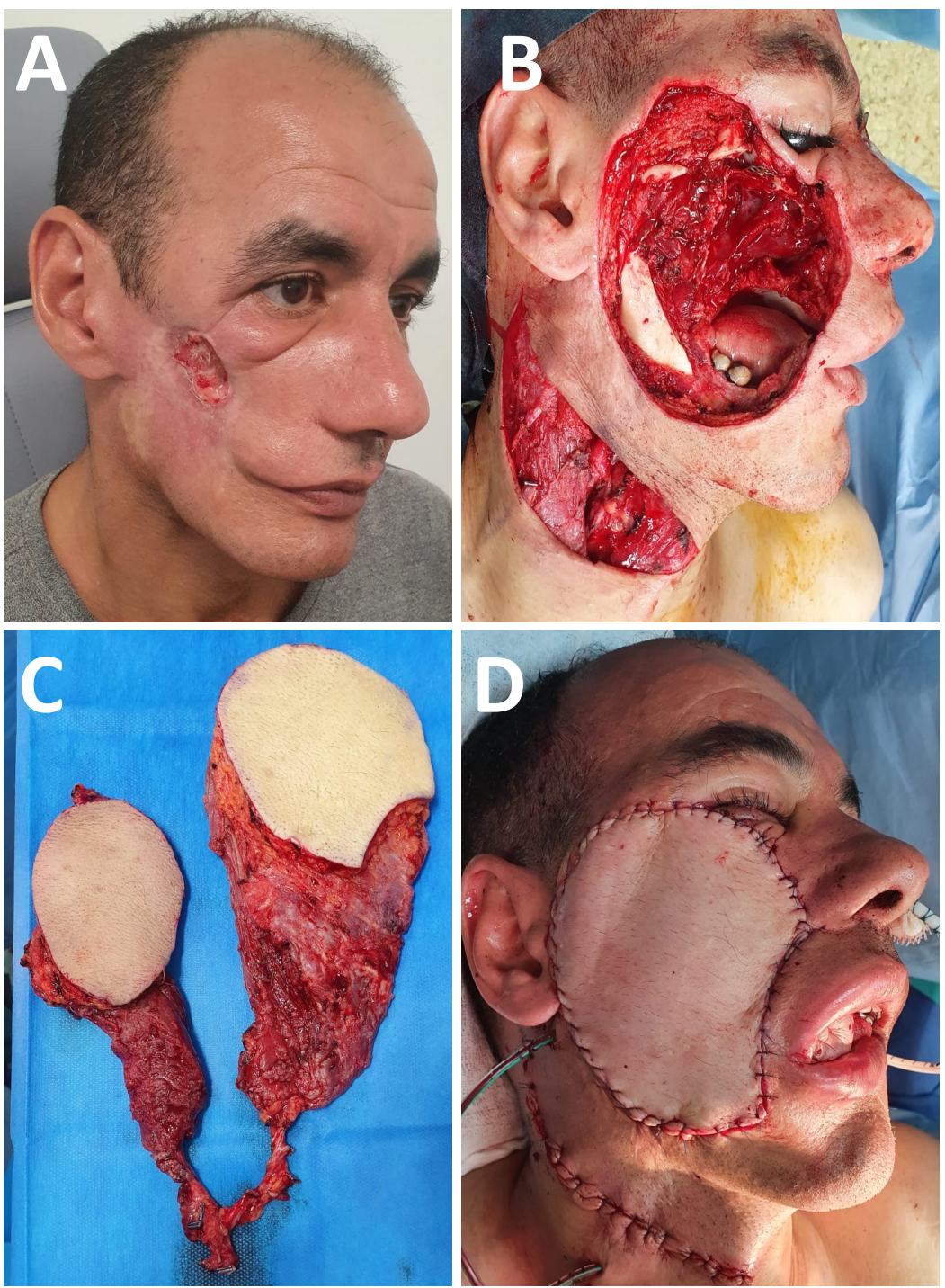
**Table 4.** Previously published series of facial extensive skin tumors.

<b>Author</b>	<b>year</b>	<b>Journal editor</b>	<b>title</b>	<b>number of patients</b>	<b>number of skin cancers</b>
<b>Wornom et al.,</b>	1991	The American Journal of Surgery	Closure of Craniofacial Defects After Cancer Resection	76	28
<b>Schliephake et al.,</b>	1994	Journal of Maxillo-Facial Surgery	Reconstruction of facial soft tissues after resection of skin tumors	273	273
<b>Lutz et al.,</b>	1998	British Journal of Plastic Surgery	Reconstruction of scalp defects with free flaps in 30 cases	29	8
<b>Gal et al.,</b>	1999	Otolaryngol Head Neck Surg	Auricular carcinoma with temporal bone invasion: Outcome analysis	21	21
<b>Cigna et al.,</b>	2012	European Review for Medical and Pharmacological Sciences	An experience on primary thinning and secondary debulking of anterolateral thigh flap in head and neck reconstruction	45	12
<b>Pompucci et al.,</b>	2004	Journal of Neurosurgery	Combined treatment of advanced stages of recurrent skin cancer of the head	18	18
<b>Kesting et al.,</b>	2015	European Association for Cranio-Maxillo-Facial Surgery	Surface-optimized free flaps for complex facial defects after skin cancer	4	4
<b>Every et al.,</b>	2021	Royal Australasian College of Surgeons	Microvascular reconstruction of head and neck defects in the elderly	344	118

**FIGURE 1**

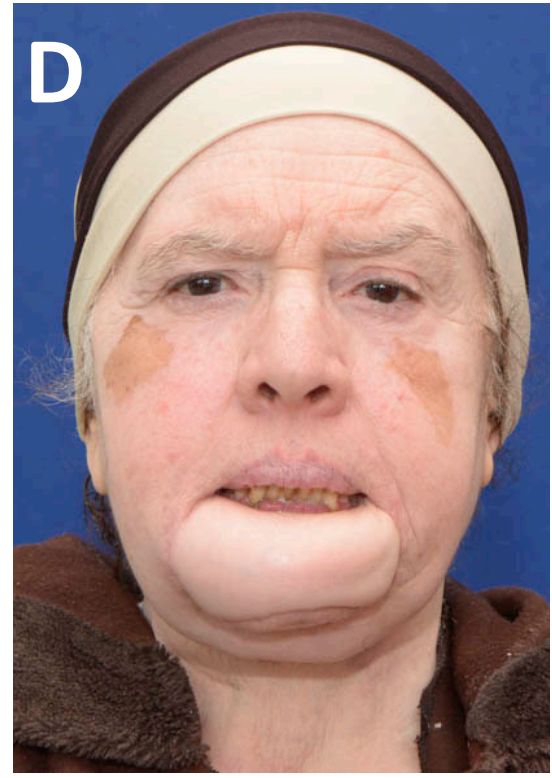
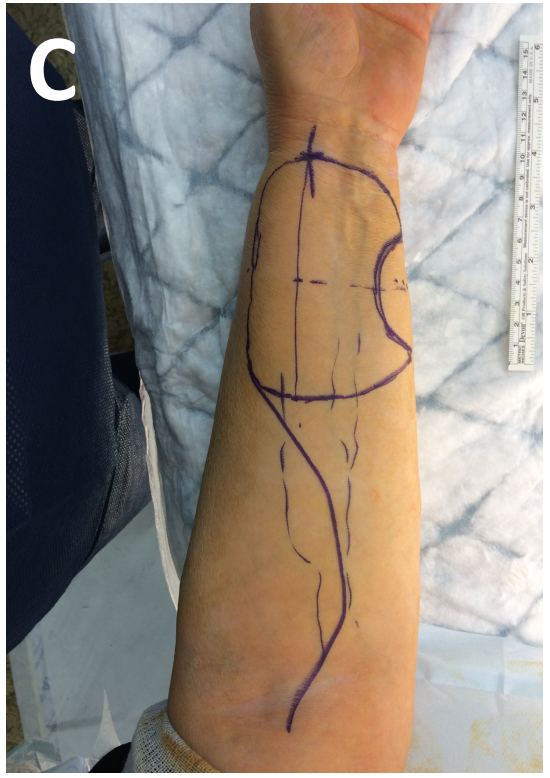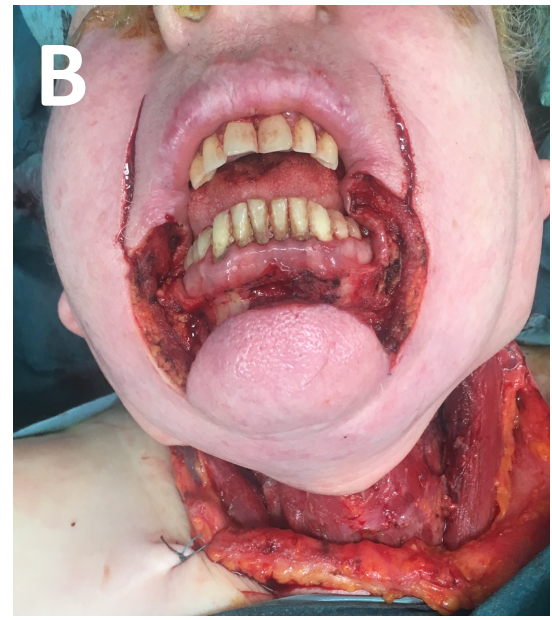
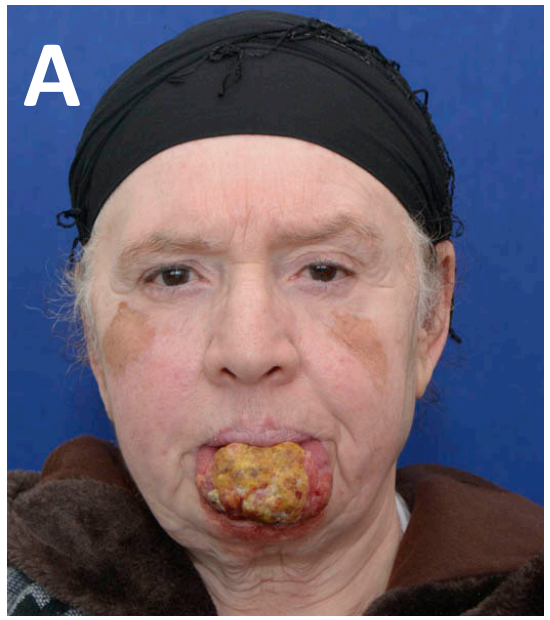


**FIGURE 2**



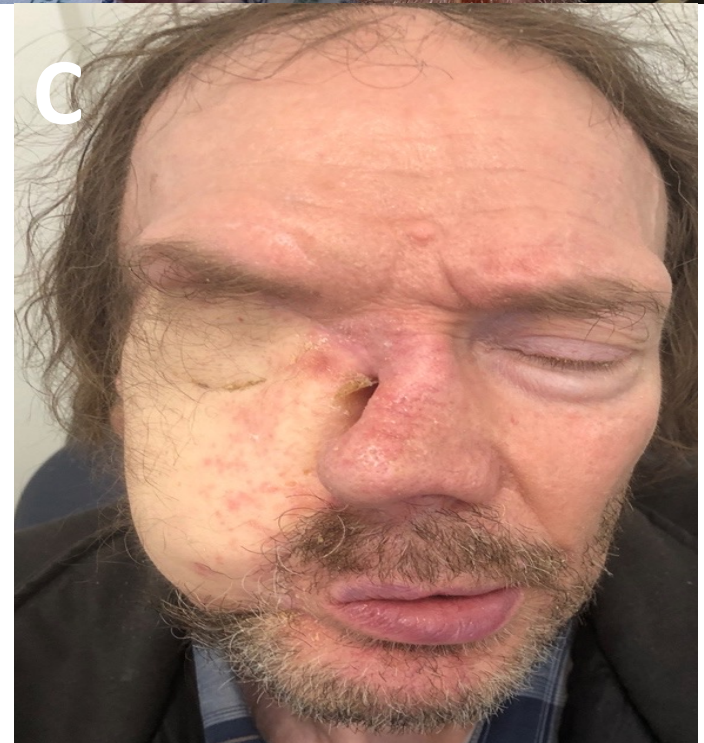
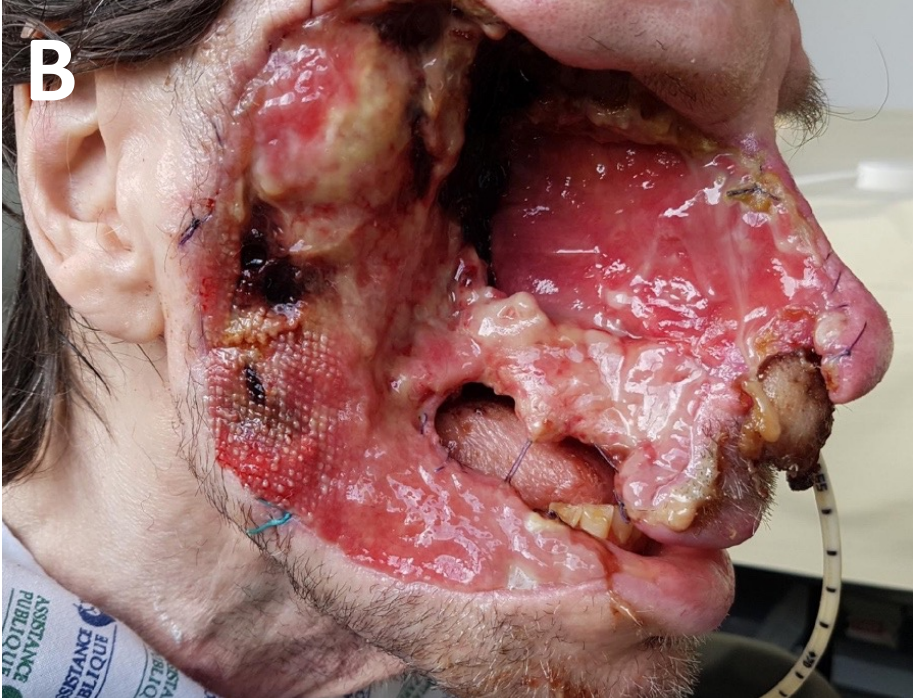
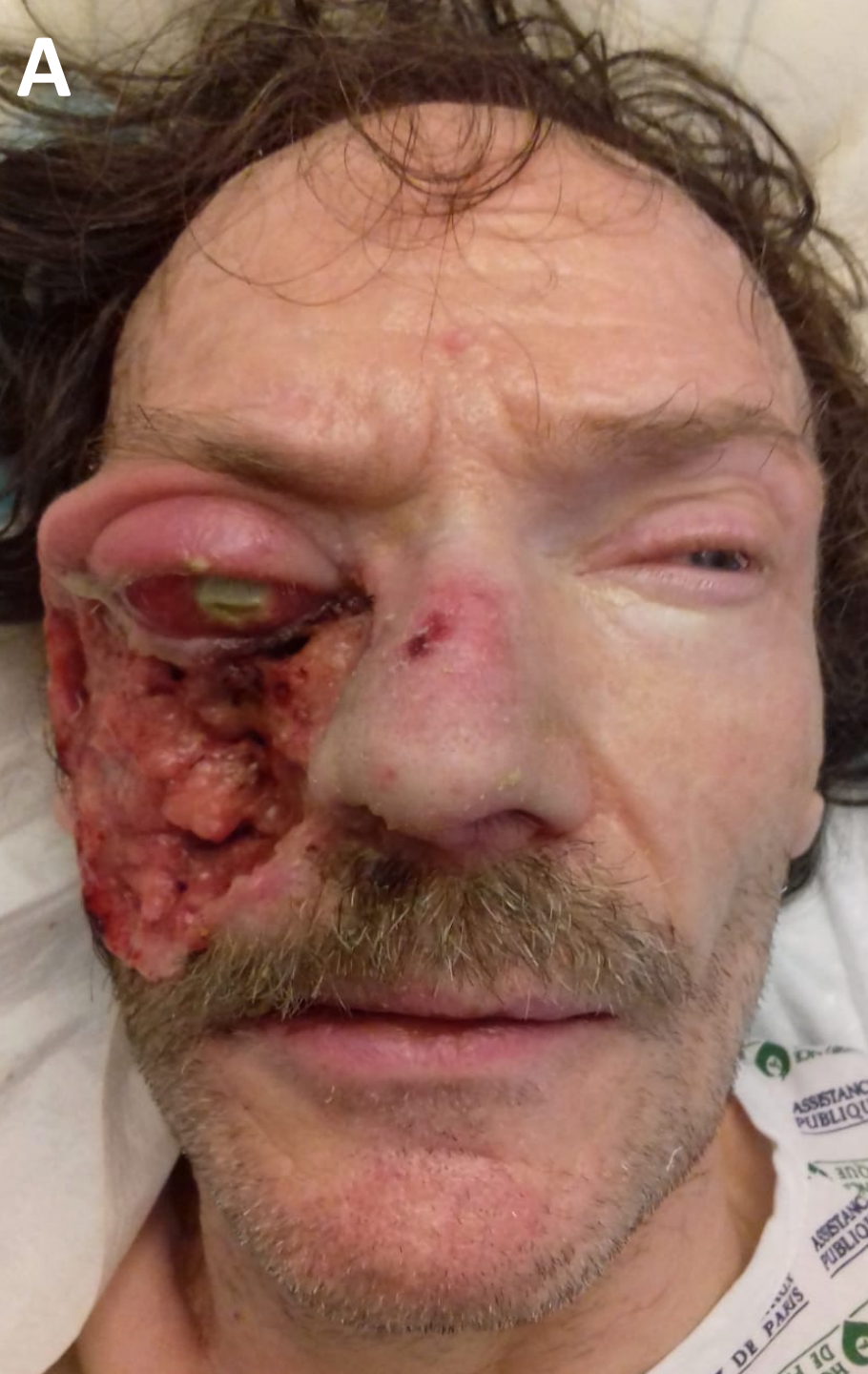**FIGURE 3**





**FIGURE 4**





**FIGURE 5**

